

HEALTH CHECKUP REPORT

Patient Name: NEHA KUMARI

DATE: 12/08/2022

Age/Gender: 31/F

Reg. No: 379419

Package: MEDIWHEEL

COMPLAINTS (IF ANY):

- Generalized weakness
- Gabhraman
- Perspiration
- On and off fever
- Pain and swelling on both foot
- Gastritis

HISTORY OF HEALTH STATUS: No

PRESENT MEDICATIONS:

- TAB. MONTHUS – L (0-0-1)
- INJ. HISTOGLOB (once in a 6 month)

HYPERSENSITIVITY TO ANY DRUG: No

PERSONAL HISTORY:

- | | | | | | |
|---------------|---|----------|-----------------------------|---|---------|
| - Bowel | : | Regular | Diet | : | Non-Veg |
| - Micturition | : | Normal | Habits | : | No |
| - Sleep | : | Adequate | Physical Activity/Exercise: | : | no |
| - Appetite | : | Adequate | | | |

HISTORY OF ILLNESS (WITH PAST MEDICATIONS):

- LMP :- 17/07/2022

FAMILY HISTORY: NO

VITAL SIGNS:

- | | | | |
|------------|-------|---------|------------|
| - Height : | ? cms | Pulse : | 72/min. |
| - Weight : | ? Kgs | B.P: | 102/62mmHg |





PHYSICIAN CONSULTATION:
Marengo CIMS

Hospital

1) Clinical Impression

- Mild hyperurimia
- Allergic bronchial asthma

2) Recommendations

- Healthy life style

OPHTHALMO CONSULTATION:

RE

Best corrected visual acuity

6/6

DENTAL CONSULTATION:

Adv:

- Cleaning

GYNEC CONSULTATION: Skip by patient

Please take regular medicine as prescribed by the Doctor. (If given)

cims.org

(Dr. Hardik Shah)

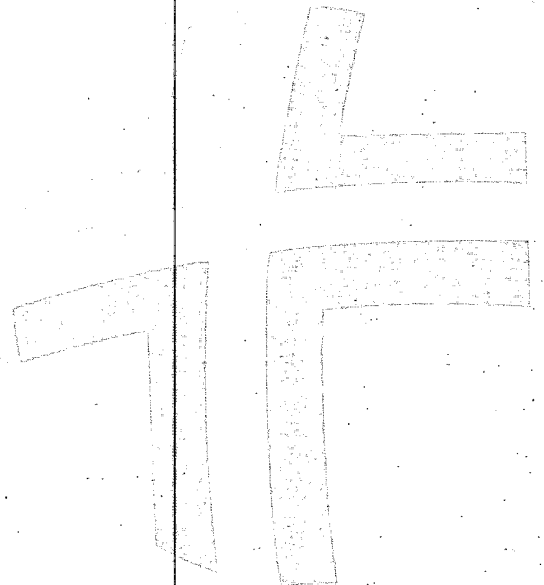
LE

6/6

(Dr. Jignesh Shah)

(Dr. Parvin Chandarana)

FOR OFFICE USE ONLY



Reg. No : CIMS/A/2022/379419	VisitNo : HC/110822/1 [HCV]
Patient Name : Mrs. NEHA KUMARI	Age(Y-M-D)/Sex : 31 Y 6 M 25 D. / Female
Referring Doctor : Dr. CIMS DOCTOR	Doctor : Bed :
Ward/Room :	
ORD/110822/332 Lab No : 2022121859 LSN : 908171 (Whole Blood)	Sample Quality : Normal
Collection Time : 11/08/2022 9:50:56 Arrival : 11/08/2022 10:05:57	Validation Time : 11/08/2022 12:49:26PM


	Result	Unit	Reference Range
CBC With ESR			
TOTAL COUNT			
Hemoglobin <i>(SLS Hemoglobin Detection method)</i>	12.5	g/dl	12.5 - 16.0 g/dl
Total RBC Count <i>(Hydro Dynamic Focusing Method)</i>	4.62	mill/Cmm	4.2 - 5.4 mill/Cmm
HCT <i>(Hydro Dynamic Focusing Method)</i>	39.1	%	37 - 47 %
Total WBC Count <i>(Flow Cytometry)</i>	8220	/Cmm	4000 - 10500 /Cmm
Platelet Count <i>(Hydro Dynamic Focusing Method)</i>	184000	/Cmm	150000 - 450000 /Cmm
DIFFERENTIAL COUNT (by Flow Cytometry)			
Polymorphs	55	%	40 - 70 %
Lymphocytes	37	%	22 - 45 %
Eosinophils	04	%	01 - 04 %
Monocytes	04	%	01 - 06 %
Basophils	00	%	00 - 01 %
Immature Granulocytes	00	%	0 - 2 %
Smear Study	RBCs are Normochromic & Normocytic. Platelets are adequate in number. Malarial Parasites are not seen. No Premature cells are seen.		
BLOOD INDICES (by Calculated Method)			
M.C.V	84.6	fl	78 - 100 fl
M.C.H	27.1	pg	27 - 31 pg
M.C.H.C.	32.0	gm/dl	32 - 36 gm/dl
RDW-CV	14.60	%	11.5 - 14.0 %
ESR (Red Cell Aggregation) After One Hour	53	mm	0 - 12 mm
Blood Group Rh ABO	"O"		



Dr. Kazumi Gondalia
M.D. (Path)
Consultant Pathologist
Reg. No. : G-21729

Dr. Manisha Shah
MD (Path & Bact)
Consultant Pathologist
Reg. No. : G-15496

Dr. Jitendra Nayak
MD (Path)
Consultant Pathologist
Reg. No. : G-14786





**Marengo CIMS
Hospital**

cims.org

Reg. No : CIMS/A/2022/379419	VisitNo : HC/110822/1 [HCV]
Patient Name : Mrs. NEHA KUMARI	Age(Y-M-D)/Sex : 31 Y 6 M 25 D. / Female
Referring Doctor : Dr. CIMS DOCTOR	Doctor :
Ward/Room :	Bed :

ORD/110822/332 Lab No : 2022121859 LSN : 908171 (Whole Blood) Sample Quality : Normal
 Collection Time : 11/08/2022 9:50:56 Arrival : 11/08/2022 10:05:57 Validation Time : 11/08/2022 12:49:26PM

Rh	POSITIVE		
HbA1c (Glycosylated Haemoglobin)			
TEST			
HbA1c (Glyco Hb) (Immuno Turbidimetric)	5.51	%	4.8-5.9% Normal 5.9-7.0% Good diabetic control 7.0-10.0% Fair diabetic control >10.0% Poor diabetic control
Mean Plasma Glucose	118.8	mg/dL	80 - 140 mg/dL
*** END OF REPORT ***			

FOR PATHOLOGY REPORT

[Signature]

Dr. Kazumi Gondalia
M.D. (Path)
Consultant Pathologist
Reg. No. : G-21729

Dr. Manisha Shah
 MD (Path & Bact)
 Consultant Pathologist
 Reg. No. : G-15496

Dr. Jitendra Nayak
 MD (Path)
 Consultant Pathologist
 Reg. No. : G-14786






Reg. No : CIMS/A/2022/379419	VisitNo : HC/110822/1 [HCV]
Patient Name : Mrs. NEHA KUMARI	Age(Y-M-D)/Sex : 31 Y 6 M 25 D. / Female
Referring Doctor : Dr. CIMS DOCTOR	Doctor :
Ward/Room :	Bed :

ORD/110822/332 Lab No : 2022121860 LSN : 908171 (SERUM) Sample Quality : Normal
 Collection Time : 11/08/2022 9:50:56 Arrival : 11/08/2022 10:05:57 Validation Time : 11/08/2022 11:33:34AM

Liver Function Test

	<u>Result</u>	<u>Unit</u>	<u>Reference Range</u>
Alkaline Phosphatase (PNPP, AMP Buffer Method, Colorimetric)	87.1	U/L	35 - 104 U/L
Billirubin			
Total Billirubin (Diazospecial Iazonium Iron with Blank)	0.70	mg/dL	0.0 - 1.0 mg/dL
Direct Billirubin (Diazo, (Evelyn Malloy) with Blank)	0.24	mg/dL	0.0 - 0.2 mg/dL
Indirect Billirubin (Calculated from Total and Direct Billirubin)	0.46	mg/dL	0.0 - 0.8 mg/dL
SGPT (ALT) (IFCC without pyridoxal phosphate)	17.7	U/L	0 - 33 U/L
SGOT (AST) (IFCC without pyridoxal 5 phosphate)	17.2	U/L	0 - 32 U/L
Total Protein			
Total Proteins (Biuret Method)	8.03	gm/dl	6.4 - 8.3 gm/dl
Albumin (Bromocresol Green Colorimetric)	4.35	gm/dl	3.97 - 4.95 gm/dl
Globulin	3.68	gm/dl	2.2 - 3.5 gm/dl
A/G Ratio	1.18		0.9 - 2.1


Dr. Kazumi Gondalia
 M.D. (Path)
 Consultant Pathologist
 Reg. No. : G-21729

Dr. Manisha Shah
 MD (Path & Bact)
 Consultant Pathologist
 Reg. No. : G-15496

Dr. Jitendra Nayak
 MD (Path)
 Consultant Pathologist
 Reg. No. : G-14786




Reg. No : CIMS/A/2022/379419	VisitNo : HC/110822/1 [HCV]
Patient Name : Mrs. NEHA KUMARI	Age(Y-M-D)/Sex : 31 Y 6 M 25 D. / Female
Referring Doctor : Dr. CIMS DOCTOR	Doctor : :
Ward/Room : :	Bed : :

ORD/110822/332 Lab No : 2022121860 LSN : 908171 (SERUM) Sample Quality : Normal
 Collection Time : 11/08/2022 9:50:56 Arrival : 11/08/2022 10:05:57 Validation Time : 11/08/2022 11:33:34AM

	Result	Unit	Reference Range
Creatinine <i>(Buffered Jaffe Reaction Kinetic Compensated)</i>	0.82	mg/dL	0.5 - 0.9 mg/dL
Estimated GFR	-	mL/min/1.73m ²	71 - 121 mL/min/1.73m ²
Fasting Glucose <i>(Hexokinase)</i>	90.7	mg/dL	70 - 100 mg/dL
Thyroid Function Test			
TOTAL T3 (T3) * <i>(Electrochemiluminescence Assay)</i>	1.31	ng/ml	0.846 - 2.02 ng/ml
TOTAL T4 (T4) * <i>(Electrochemiluminescence Assay)</i>	10.62	µg/dl	5.13 - 14.06 µg/dl
TSH <i>(Electrochemiluminescence Assay)</i>	2.4	µIU/ml	0.27- 4.20 µIU/ml
Total Protein			
Total Proteins <i>(Biuret Method)</i>	8.03	gm/dl	6.4 - 8.3 gm/dl
Albumin <i>(Bromocresol Green Colorimetric)</i>	4.35	gm/dl	3.97 - 4.95 gm/dl
Globulin	3.68	gm/dl	2.2 - 3.5 gm/dl
A/G Ratio	1.18		0.9 - 2.1
Uric Acid <i>(Uricase Colorimetric Enzymatic)</i>	6.1	mg/dL	2.4 - 5.7 mg/dL

*** END OF REPORT ***



**Dr. Kazumi Gondalia
M.D. (Path)
Consultant Pathologist
Reg. No. : G-21729**

Dr. Manisha Shah
MD (Path & Bact)
Consultant Pathologist
Reg. No. : G-15496

Dr. Jitendra Nayak
MD (Path)
Consultant Pathologist
Reg. No. : G-14786




Reg. No : CIMS/A/2022/379419	VisitNo : HC/110822/ [HCV]
Patient Name : Mrs. NEHA KUMARI	Age(Y-M-D)/Sex : 31 Y 6 M 25 D. / Female
Referring Doctor : Dr. CIMS DOCTOR	Doctor :
Ward/Room :	Bed :

ORD/110822/332 Lab No : 2022121861 LSN : 908171 (SERUM)	Sample Quality : Normal
Collection Time : 11/08/2022 9:50:56 Arrival : 11/08/2022 10:05:57	Validation Time : 11/08/2022 11:43:33AM

	<u>Result</u>	<u>Unit</u>	<u>Reference Range</u>
BUN * (Ureas with UV)	8.8	mg/dL	6 - 20 mg/dL
*** END OF REPORT ***			

Dr. Manisha Shah
MD (Path & Bact)
Consultant Pathologist
Reg. No. : G-15496

Dr. Jitendra Nayak
MD (Path)
Consultant Pathologist
Reg. No. : G-14786



Dr. Shreya Patel
MD(Path)
Consultant Pathologist





Reg. No : CIMS/A/2022/379419	VisitNo : HC/110822/ [HCV]
Patient Name : Mrs. NEHA KUMARI	Age(Y-M-D)/Sex : 31 Y 6 M 25 D. / Female
Referring Doctor : Dr. CIMS DOCTOR	Doctor : :
Ward/Room : :	Bed : :


ORD/110822/332 Lab No : 2022121862 LSN : 908171 (Urine)	Sample Quality : Normal
Collection Time : 11/08/2022 9:50:56 Arrival : 11/08/2022 10:05:57	Validation Time : 11/08/2022 2:33:20PM

	<u>Result</u>	<u>Unit</u>	<u>Reference Range</u>
Urine R & M			
PHYSICAL EXAMINATION			
Quantity	20 cc		
Colour	Yellow		
Transperancy	Slight Turbid		
Reaction (QDS-10 Strip)	5.0		
Sp. Gravity (QDS-10 Strip)	1.025		1.005 - 1.035
CHEMICAL EXAMINATION			
U. Albumin (QDS-10 Strip/Manual)	Present(++)		
U. Glucose (QDS-10 Strip/Manual)	Nil		
U. Acetone (QDS-10 Strip/Manual)	Absent		
BS/BP (QDS-10 Strip/Manual)	Absent		
MICROSCOPIC EXAMINATION			
Pus Cell	1-2	/H.P.F.	/H.P.F.
Red Blood Cell	6-8	/H.P.F.	/H.P.F.
Epithelial Cell	8-10	/H.P.F.	/H.P.F.
Cast	Not Seen		
Crystals	Not Seen		
Amorphous	Absent		
Monilia	Absent		
*** END OF REPORT ***			

FOR PATHOLOGY ONLY

Dr. Manisha Shah
MD (Path & Bact)
Consultant Pathologist
Reg. No. : G-15496

Dr. Jitendra Nayak
MD (Path)
Consultant Pathologist
Reg. No. : G-14786


Dr. Kazumi Gondalia
M.D. (Path)
Consultant Pathologist
Reg. No. : G-21729





**Marengo CIMS
Hospital**

cims.org

Reg. No : CIMS/A/2022/379419	VisitNo : HC/110822/ [HCV]
Patient Name : Mrs. NEHA KUMARI	Age(Y-M-D)/Sex : 31 Y 6 M 25 D. / Female
Referring Doctor : Dr. CIMS DOCTOR	Doctor :
Ward/Room :	Bed :

ORD/110822/332 Lab No : 2022122169 LSN :908171 (SERUM)	Sample Quality : Normal
Collection Time :12/08/2022 11:17:14 Arrival : 12/08/2022 11:25:58	Validation Time : 13/08/2022 5:04:02PM

	<u>Result</u>	<u>Unit</u>	<u>Reference Range</u>
P.P. Glucose (Hexokinase)	104.5	mg/dL	70 - 140 mg/dL
P.P. Urine Glucose	Nil		
*** END OF REPORT ***			

Dr. Kazumi Gondalia
M.D. (Path)
Consultant Pathologist
Reg. No. : G-21729

Dr. Manisha Shah
MD (Path & Bact)
Consultant Pathologist
Reg. No. : G-15496

Dr. Jitendra Nayak
MD (Path)
Consultant Pathologist
Reg. No. : G-14786





**Marengo CIMS
Hospital**

cims.org

Reg. No : CIMS/A/2022/379419	VisitNo : DP/120822/185 [DPV]
Patient Name : Mrs. NEHA KUMARI	Age(Y-M-D)/Sex : 31 Y 6 M 26 D. / Female
Referring Doctor :	Doctor : Dr. CIMS DOCTOR
	Bed :

ORD/120822/1255 Lab No : 2022122246	LSN : 908384 (SERUM)	Sample Quality : Normal
Collection Time : 12/08/2022 12:40:31	Arrival : 12/08/2022 12:52:32	Validation Time : 12/08/2022 2:59:11PM


	<u>Result</u>	<u>Unit</u>	<u>Reference Range</u>
Vitamin B-12 (Electrochemiluminescence Assay)	432.2	pg/ml	211-946 pg/ml
Vitamin D (25 OH) * (Electrochemiluminescence Assay)	11.52	ng/ml	Deficiency : ≤ 20 ng/ml Insuficiency : 21 - 29 ng/ml Normal : ≥ 30 ng/ml

*** END OF REPORT ***

FOR PATIENTS ONLY PLEASE

Dr. Manisha Shah
MD (Path & Bact)
Consultant Pathologist
Reg. No. : G-15496

Dr. Jitendra Nayak
MD (Path)
Consultant Pathologist
Reg. No. : G-14786


Dr. Kazumi Gondalia
M.D. (Path)
Consultant Pathologist
Reg. No. : G-21729





MARENGO ASIA NETWORK HOSPITAL



JCI (USA)



NABH



NABL
Certificate No. NC-3849



www.cims.org



CIMS Hospital

FOR ECHO / TMT REPORTS ONLY

ECHO Report

Dt : 12/08/2022

Patient Details

Patient ID 315756
Name Mrs. NEHA KUMARI
Age 31 Years
Gender Female
Blood Group
Referral Doctor

ECHO Identification Detail

Doctor Incharge Dr. URMIL SHAH

Clinical Status Of Patient

ECHO Code RP

- Finding Description**
1. Normal sized LA, LV, RA, RV.
 2. Normal LV systolic function, LVEF: 60%.
 3. No RWMA.
 4. Normal LV diastolic function.
 5. All cardiac valves are structurally normal.
 6. Mild MR, Mild TR, Trivial PR, No AR.
 7. Mild PAH, RVSP: 36 mmHg.
 8. IAS/IVS: Intact.
 9. No clot/vegetation/pericardial effusion.
 10. No coarctation of aorta.

Dr. URMIL SHAH

Patient's Name : NEHA KUMARI
Reg. No. (IP/OP): HC-379419
Referred By Dr. : CIMS

Age, Sex : 31Y/F
Date : 12/08/2022

USG OF ABDOMEN & PELVIS

LIVER: Liver is normal in size and echotexture. No evidence of focal SOL or dilatation of IHBR seen. Porta hepatis appear normal.

GALLBLADDER: Gallbladder appeared normal. No calculus or mass lesion seen.

PANCREAS: Visualised pancreas appeared normal in size and echotexture. No focal lesion, mass or pancreatitis.

SPLEEN: Spleen appears normal in size and echotexture.

PARAAORTIC REGION: Aorta grossly appeared normal. No paraaortic lymphnodes seen.

KIDNEYS: Both kidneys appear normal in size, shape and in position.

Right kidney shows presence of 9x9mm sized paracalyceal cyst at lower pole with intramural calcification.

Cortex and collecting system of both kidneys appeared normal.

No evidence of calculus or obstructive uropathy on either side.

Right kidney: 92x38mm. Left kidney: 104x40mm.

URINARY BLADDER: Bladder appeared normal. No calculus or mass lesion is seen.

UTERUS: Uterus appears normal in size and measures 70x50x42mm.

Uterus shows homogenous endometrial and myometrial echotexture.

Endometrial thickness appears normal and measures 7mm.

No fibroid or GS seen.

OVARIES: Both ovaries appear normal. No adnexal mass lesion seen on either side.

Presence of app. 31x28mm size ovarian cyst with internal debris is noted on right side ? Hemorrhagic cyst.

No evidence of free fluid or collection is seen in peritoneal spaces.

Normal small bowel peristalsis noted.

COMMENTS: Appearance suggests,

- > Small right renal simple cyst.
- > ? Right ovarian hemorrhagic cyst. Adv: Follow up.

Kindly correlate clinically.

DR KIRTAN SHAH DR DEEPA SHAH DR UMA MEHTA DR NIMISH SHARMA DR RAVINA CHAUHAN DR YASH PATEL
M.D. RADIODIAG. M.D., D.M.R.E D.M.R.D. F.R.C.R D.M.R.D. (D.N.B.) M.D. RADIODIAG. M.D., D.N.B.
CONS. RADIOLOGIST CONS. RADIOLOGIST CONS. RADIOLOGIST CONS. RADIOLOGIST CONS. RADIOLOGIST CONS. RADIOLOGIST

Note: This is only a radiological impression and not the final diagnosis. All diagnostic modalities have their own limitations. Therefore radiological modality report should be interpreted in correlation with clinical and pathological findings.

Dyp/msd

FOR OFFICE USE ONLY

Hospital
 Patient's Name : NEHA KUMARI
 Reg. No. (IP/OP): HC-379419
 Referred By Dr. : CIMS

Age, Sex : 31Y/F
 Date : 12/08/2022

USG OF ABDOMEN & PELVIS

LIVER: Liver is normal in size and echotexture. No evidence of focal SOL or dilatation of IHBR seen. Porta hepatis appear normal.

GALLBLADDER: Gallbladder appeared normal. No calculus or mass lesion seen.

PANCREAS: Visualised pancreas appeared normal in size and echotexture. No focal lesion, mass or pancreatitis.

SPLEEN: Spleen appears normal in size and echotexture.

PARAAORTIC REGION: Aorta grossly appeared normal. No paraaortic lymphnodes seen.

KIDNEYS: Both kidneys appear normal in size, shape and in position.

Right kidney shows presence of 9x9mm sized paracalyceal cyst at lower pole with intramural calcification.

Cortex and collecting system of both kidneys appeared normal.

No evidence of calculus or obstructive uropathy on either side.

Right kidney: 92x38mm. Left kidney: 104x40mm.

URINARY BLADDER: Bladder appeared normal. No calculus or mass lesion is seen.

UTERUS: Uterus appears normal in size and measures 70x50x42mm.

Uterus shows homogenous endometrial and myometrial echotexture.

Endometrial thickness appears normal and measures 7mm.

No fibroid or GS seen.

OVARIES: Both ovaries appear normal. No adnexal mass lesion seen on either side.

Presence of app. 31x28mm size ovarian cyst with internal debris is noted on right side ? Hemorrhagic cyst.

No evidence of free fluid or collection is seen in peritoneal spaces.

Normal small bowel peristalsis noted.

COMMENTS: Appearance suggests,

- > Small right renal simple cyst.
- > ? Right ovarian hemorrhagic cyst. Adv: Follow up.

Kindly correlate clinically.

DR KIRTAN SHAH M.D. RADIODIAG. CONS. RADIOLOGIST	DR DEEPA SHAH M.D., D.M.R.E CONS. RADIOLOGIST	DR UMA MEHTA D.M.R.D. F.R.C.R CONS. RADIOLOGIST	DR NIMISH SHARMA D.M.R.D. (D.N.B.) CONS. RADIOLOGIST	DR RAVINA CHAUHAN M.D. RADIODIAG. CONS. RADIOLOGIST	DR YASH PATEL M.D., D.N.B. CONS. RADIOLOGIST
--	---	---	--	---	--

Note: This is only a radiological impression and not the final diagnosis. All diagnostic modalities have their own limitations. Therefore radiological modality report should be interpreted in correlation with clinical and pathological findings.

Dyp/msd

Dr. Manisha Shah
 MD (Path & Bact)
 Consultant Pathologist
 Reg. No. : G-15496

Dr. Jitendra Nayak
 MD (Path)
 Consultant Pathologist
 Reg. No. : G-14786

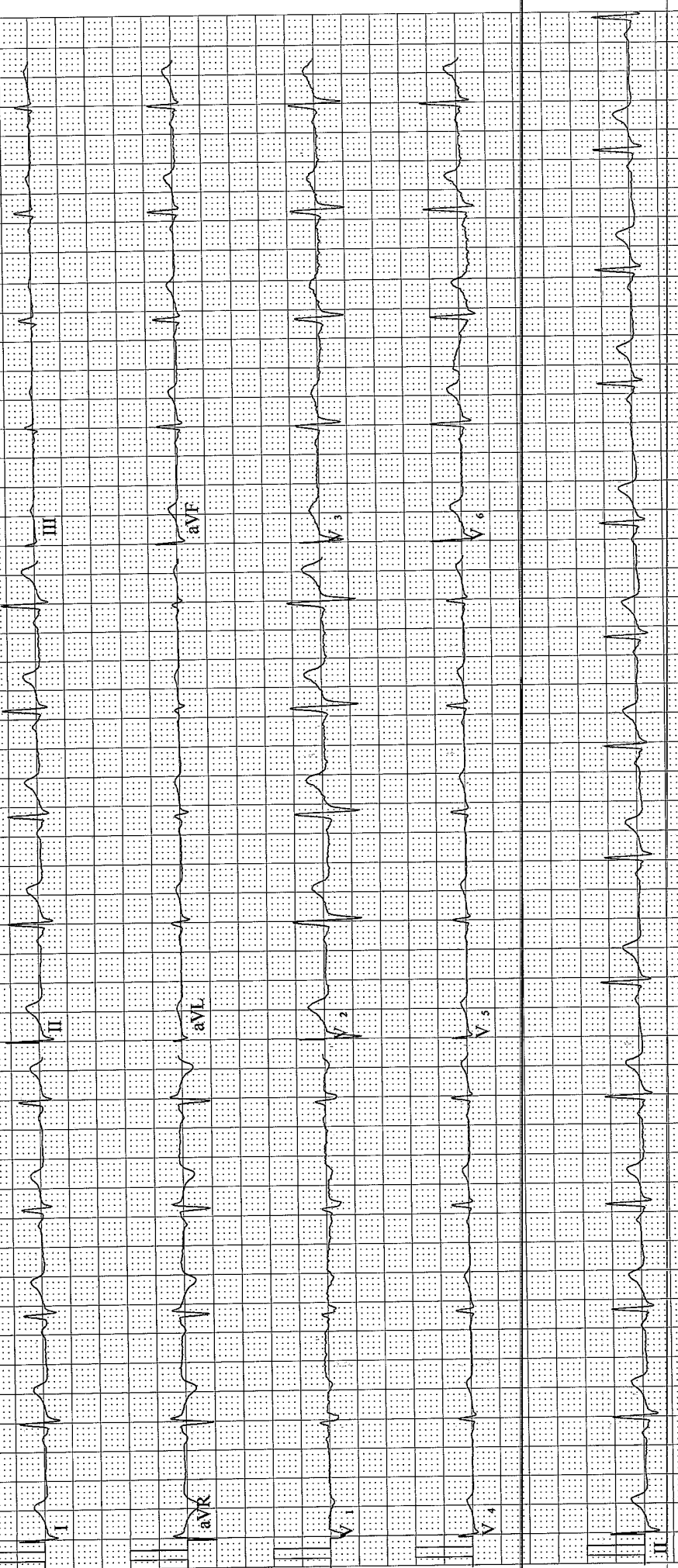


ECG

CIMS Hospital

Name : NEHA KUMARI ID : Sex : Female Age : Date : 8-12-2022

10mm/mV 25mm/s



Frequency :	1000 Hz	PR Interval :	94 ms
Sample Time :	16 s	QT Interval :	370 ms
Heart Rate :	74 bpm	QTc Interval :	411 ms
P Duration :	75 ms	P Axis :	36.8°
QRS Duration :	101 ms	QRS Axis :	50.6°
T Duration :	239 ms	T Axis :	39.7°

Suggestion :

Physician Signature:



Marengo CIMS

Patient's Name : NEHA KUMARI
Regd. Office (OP): HC-379419
Referred By Dr. : CIMS



JCI (USA)



NABH



Certificate No. NC-3149



www.cims.org



CIMS Hospita

Age, Sex : 31Y/F
Date : 12/08/2022

Plain Skiagram of Chest PA Standing View:
(Serial No-4190)

Both lung fields appear normal.

No evidence of pleural effusion or pneumothorax is seen on either side.

Mediastinal shadow appears normal.

Heart size and aorta appear normal.

Domes of diaphragm appear normal.

Bones under view appears normal.

Kindly correlate clinically.

DR KIRTAN SHAH
M.D. RADIOLOG.
CONS. RADIOLOGIST

DR DEEPA SHAH
M.D., D.M.R.E
CONS. RADIOLOGIST

DR UMA MEHTA
D.M.R.D. F.R.C.R
CONS. RADIOLOGIST

DR NIMISH SHARMA
D.M.R.D. (D.N.B.)
CONS. RADIOLOGIST

DR RAVINA CHAUHAN
M.D. RADIOLOG.
CONS. RADIOLOGIST

DR YASH PATEL
M.D., D.N.B.
CONS. RADIOLOGIST

Note: This is only a radiological impression and not the final diagnosis. All diagnostic modalities have their own limitations. Therefore radiological modality report should be interpreted in correlation with clinical and pathological findings.

Dyp/msd

FOR OFFICE USE ONLY