



# PARKLINE DIAGNOSTICS PVT. LTD.

L.G. 3, 4 & 5, Bhuvana Towers, S.D. Road, Secunderabad - 500 003.  
Tel : +91 40-2784 5852, 6649 1787, 7995421787, 7093445852, Fax : +91 40 2784 7864  
Email parklinediagnostics@gmail.com www.parklinediagnostics.com



NABL Accredited  
Certificate No.MC-2566

## MEDICAL EXAMINATION REPORT

Name	Mrs. Revathy. B		Date :	14/05/2022
Company	Clo: mediwhee1		Reg. No. :	2021118
Contact No.	8825577621		Sex	<input type="checkbox"/> M <input checked="" type="checkbox"/> F
			Age :	27
Type	Pre-Emp		Emp. No.:	Spouse
	Overseas		Height	158 cm
	Annual	<input checked="" type="checkbox"/>	Weight	44 kgs
Remarks	<p>US abdomen - Cholelithiasis Advised surgical Gastroenterology consultation and follow-up. Other parameters are within normal limits</p>			
Fitness Status	Medically Fit / Unfit		Physician's Signature	

*[Signature]*  
MBBS

Consultant Physician  
Reg. No. 6443

# COMPREHENSIVE MEDICAL EXAMINATION REPORT

NAME Ms. REVATHY. RAVI  
 AGE 27 yrs Female  
 MARITAL STATUS married CHILDREN : M  F   
 IDENTIFICATION (IF ANY) A mole on the (L) side of the cheek.

## PAST HISTORY

Any family H/o : High Blood Pressure, Heart Disease, Tuberculosis, Diabetes, Asthma, Cancer

Mother

Any personal H/o Major illness like : Typhoid.....NIL.....Jaundice.....NIL.....Etc.

Any H/o STD.....Skin infection.....NIL

H/o Blood Transfusion.....Recent Vaccination.....

H/o Epilepsy.....NIL.....Giddiness.....NIL

H/o Surgery.....Fracture in the past.....NIL

### Any Personal H/O.

High Blood Pressure, Heart Disease Tuberculosis, Diabetes, Asthma, Cancer

Drug Abuse, Drug Allergy, Micturition, Bowels, Alcohol, Smoking, Sleep, MC, Wt. Loss/Wt. Gain

Present illness / Medication

## GENERAL EXAMINATION

Conjunctiva :

Skin :

Ears :

Nose :

Throat & Oral Cavity :

Bone, Joints :

Nutritional Status :

Lymph Nodes :

Edema Feet :

Varicose Veins :

(N)  
 well Nourished  
 NPD  
 NPD  
 NIL

NPD

**Distant Vision : Near Vision :**

Right Eye: 6/6

With glasses / Without glasses

left Eye: 6/6

with glasses / without glasses

Colour Vision : OE normal

**Right Ear**

Hearing :

Rinee's Test ;

Weber Test :

Discharge :

(N)

the  
Central  
Absent

Right Eye: N6

With glasses / Without glasses

left Eye : N6

with glasses / without glasses

**Ophthalmologist's Signature**

**D. KATTA**  
M.B.B.S.,  
Regd: 8961 (AMC)

**Left Ear**

(N)

the  
Central  
Absent

**SYSTEMIC EXAMINATION**

Pulse : 86 bpm

B.P. : 100/60 mmHg

Lungs : A. Shape of Chest slc symmetrical  
B. Breath Sounds slc clear ⊕  
C. Adventitious Sounds No

Heart : A. Sounds S<sub>1</sub>, S<sub>2</sub> ⊕  
B. Murmurs No murmurs

Abdomen : A. Liver NPD  
B. Spleen NPD  
C. Piles NIC  
D. Any Lump NAD

**Nervous System**

A. Higher Function :  
B. Cranial Nerves :  
C. Sensory System :  
D. Motor System :  
E. Jerks :

(N)

General : A. Hernia  
B. Hydrocele  
C. Varicocele  
NAD

Breast : Rt \_\_\_\_\_ Lt. \_\_\_\_\_

## CANDIDATE'S DECLARATION

I hereby solemnly declare that I am not suffering from Asthma, Hypertension, Diabetes, Occult Psychological disorders or any other ailment which can be suppressed without my voluntary declaration.

Date :

*P. Revathy*

\_\_\_\_\_  
Signature

Place :

Note : General Physical Examination and Investigation included in the health check-up  
Have certain limitations and may not be able to detect all latent and asymptomatic diseases.  
Any new symptoms developing after the health check-up or persisting thereafter should be  
brought to the attention of the treating physician.



7799686970

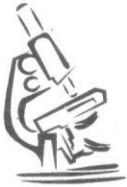Name : Devalthy R. ..... Sex : F ..... Age : 27 .....

Date : 14/5/22 .....

→ Advised oral prophylaxis  
and oral hygiene  
Instruction

OPD No : 629 .....

  
**Smilesss**   
MULTI SPECIALITY DENTAL CLINIC  
*Smile Confidentially... Not Confidentially...*  
B.D.S, IMPLANTOLOGIST (USA)  
1-3-1, Rajamudaliar Street, Kalasiguda,  
Secunderabad. Cell : 7799686970




# PARKLINE DIAGNOSTICS PVT. LTD.

L.G. 3, 4 & 5, Bhuvana Towers, S.D. Road, Secunderabad - 500 003. Tel :+91 40-2784 5852, 6649 1787, 7995421787,  
7093445852, Fax : +91 40 2784 7864 Email parklinediagnostics@gmail.com www.parklinediagnostics.com



NABL Accredited  
Certificate No.MC-2566

## ENT CONSULTATION

S.No. 2021418

Emp.No.

Date 14/5/22

Name Mrs. Revathy.R.

Age 27 Yrs

Sex M/F

### EARS :

### Right

### Left

EAC : patent, no Cerumen.

-dr-

TM : Intact, pearly white.

-dr-

TFT : Cone of light (+).  
Dinne's +ve

Dinne's +ve.

Weber's - centralised

NOSE : Septum (+). Bil. T'symmetry (+). Pns - (+). non tender

THROAT : Oropharynx (+). Bil. v.c's & } no moving  
Arytenoids } bil.

NECK : (+)

IMPRESSION: ENT clinically normal

Dr. D. Hari Krishna Reddy  
MS (ENT)  
Head & Neck Surgeon  
Reg. No: 88379



# PARKLINE DIAGNOSTICS PVT. LTD.

L.G. 3, 4 & 5, Bhuvana Towers, S.D. Road, Secunderabad - 500 003 Tel : 040-42038139, 27845852  
7995421787, 7093445852 Email : parklinediagnostics@gmail.com www.parklinediagnostics.com

## TEST REPORT

Name : Mrs . REVATHY R [SPOUSE]

TID : UMR0788754

Age / Gender : 27 Years / Female

Registered on : 14-May-2022 10:09 AM

Ref.By : Medi Wheel

Reported On : 14-May-2022 12:48 PM

Req. No : BIL2021418

### DEPARTMENT OF ULTRASOUND Ultrasound Whole Abdomen

**LIVER** : Normal in size and echotexture. No focal lesions.

No IHBD /CBD dilatation. Portal vein is normal.

**SPLEEN** : Normal in size and echotexture. No focal lesion seen.

**GALL BLADDER** : Well distended. No sludge /sol. Multiple gall stones each 5 to 6 mm.

Gall bladder - Wall thickness is normal.

No pericholecystic oedema.

**PANCREAS** : Normal in size and echotexture.No calcification / sol.

Pancreatic duct is normal. No peripancreatic fluid collection.

**RIGHT KIDNEY** : 9.22 x4.84 cms

Normal in size and echotexture.

Cortical thickness is normal.

No evidence of calculi / sol.

Pelvi calyceal system is normal.

**LEFT KIDNEY** : 9.36 x 4.74 cms

Normal in size and echotexture.

Cortical thickness is normal.

No evidence of calculi / sol.

Pelvi calyceal system is normal.

**URINARY BLADDER** : Well distended.Normal in contour.

Wall thickness is normal. No calculus / sol.

**UTERUS** : Anteverted measuring 7.83 x 3.45 x 2.80 cms - Normal in size and echotexture.

No space occupying lesion is seen.

Cervix is normal in size and echopattern.

**ENDOMETRIUM** : 8 mm -Normal.

The Test marked with\*are not accredited by NABL

Lab Timings (Weekdays) : 7.00 am to 8.30 pm

Radiologists Timings (Weekdays) : 7.30 am to 1.30 pm

Sundays & Holidays : 7.00 am to 1.00 pm

& 5.45 pm to 7.45 pm

Sundays & Holidays : 7.30 am to 9.30 am



# PARKLINE DIAGNOSTICS PVT. LTD.

L.G. 3, 4 & 5, Bhuvana Towers, S.D. Road, Secunderabad - 500 003 Tel : 040-42038139, 27845852  
7995421787, 7093445852 Email : parklinediagnostics@gmail.com www.parklinediagnostics.com

## TEST REPORT

Name : Mrs . REVATHY R [SPOUSE]

TID : UMR0788754

Age / Gender : 27 Years / Female

Registered on : 14-May-2022 10:09 AM

Ref.By : Medi Wheel


Reported On : 14-May-2022 12:48 PM

Req. No : BIL2021418

**OVARIES** : Right ovary : 2.31 x 2.09 cms Left ovary : 2.86 x 2.01 cms  
Both ovaries normal in size and echotexture.  
No adnexal mass seen.  
No fluid in POD.

**IMPRESSION** : Cholelithiasis.

Clinical correlation.

  
**Dr. PRAJAKTA SUKHADEVE**  
DNB RADIOLOGY  
Reg. No. 68493

The Test marked with\*are not accredited by NABL

**Lab Timings (Weekdays)** : 7.00 am to 8.30 pm

**Radiologists Timings (Weekdays)** : 7.30 am to 1.30 pm  
& 5.45 pm to 7.45 pm

**Sundays & Holidays** : 7.00 am to 1.00 pm

**Sundays & Holidays** : 7.30 am to 9.30 am





# PARKLINE DIAGNOSTICS PVT. LTD.

L.G. 3, 4 & 5, Bhuvana Towers, S.D. Road, Secunderabad - 500 003 Tel : 040-42038139, 27845852  
7995421787, 7093445852 Email : parklinediagnostics@gmail.com www.parklinediagnostics.com

## TEST REPORT

Name : Mrs . REVATHY R [SPOUSE]  
Age / Gender : 27 Years / Female  
Ref.By : Medi Wheel  
Req. No : BIL2021418

TID : UMR0788754  
Registered on : 14-May-2022 10:09 AM  
Reported On : 14-May-2022 12:19 PM

### X-RAY CHEST PA VIEW

Lung fields are clear.

Cardia is normal.


Hila are normal.

C P angles are free.

Bony cage is normal.

Soft tissues are normal.

**IMPRESSION : NORMAL CHEST X-RAY**

  
Dr. PRAJAKTA SUKHADEVE  
DNB RADIOLOGY  
Reg. No. 68493

The Test marked with\*are not accredited by NABL

**Lab Timings (Weekdays) :** 7.00 am to 8.30 pm

**Sundays & Holidays :** 7.00 am to 1.00 pm

**Radiologists Timings (Weekdays) :** 7.30 am to 1.30 pm

**Sundays & Holidays**

Page:1 of 1

& 5.45 pm to 7.45 pm

: 7.30 am to 9.30 am

ID: 2021418

14-05-2022 10:29:53 AM

BPL-12

MRS REVATHY R  
Female 27 Years

HR 76 bpm  
P 97 ms  
PR 161 ms  
QRS 75 ms  
QT/QTc 359/404 ms  
P/QRS/T 69/71/23 °  
RV5/SV1 0.795/0.380 mV

Diagnosis Information:  
Sinus Rhythm  
Low Voltage (Chest Leads)

Dr. SAMEER G. VANKAR  
MD., D.M.  
Consultant Interventional Cardiologist  
Reg. No. 8245



Report Confirmed by:

PATIENT SUMMARY REPORT

GF

REF. BY : MEDIWHEEL  
DONE BY : DR SAMEER G VANKAR  
TECHNICIAN : G.M.SURESH

DIAGNOSTICS PVT.LTD

2021418  
MRS REVATHI R  
27 / FEMALE

HEIGHT (cm) : 158  
WEIGHT (kg) : 44  
PROTOCOL : MODIFIED BRUCE

5-2022, 11:36::

TORY  
ION  
OF TEST  
CTOR  
Y  
INVESTIGATION  
N FOR TERMINATION  
ISE TOLERANCE  
ISE INDUCED ARRHYTHMIAS  
O RESPONSE  
NO RESPONSE  
L IMPRESSION  
COMMENTS

Routine Check Up.  
None.  
Very Active.  
E C G  
Dyspnea.  
Moderate (< 10 METS).  
No.  
Normal.  
Normal.

*Tmt negative*

*Dr. SAMEER G. VANKAR*  
MD., D.M.  
Consultant Interventional Cardiologist  
Reg.No.8245

Confirmed By : \_\_\_\_\_

Signature

Page No.: 1

BPL DYNATRAC

25mm/Sec

007 Tested On 14-05-2022, 11:36:24

