



Customer Name	MRS.SANGEETHA K P	Customer ID	MED120924509
Age & Gender	28Y/FEMALE	Visit Date	26/03/2022
Ref Doctor	MediWheel		

**DEPARTMENT OF CARDIOLOGY**  
**TRANSTHORACIC RESTING ECHO CARDIOGRAPHY REPORT**

**ECHO INDICATION: Assessment  
M MODE & 2-D PARAMETERS:**

**ACOUSTIC WINDOW : GOOD**

**LV STUDY**

IVS(d)	cm	0.4
IVS(s)	cm	1.0
LPW(d)	cm	0.7
LPW(s)	cm	1.0
LVID(d)	cm	4.8
LVID(s)	cm	3.0
EDV	ml	116
ESV	ml	28
SV	ml	88
EF	%	75
FS	%	37

**DOPPLER PARAMETERS**

Parameters	Patient Value
LA cm	2.7
AO cm	2.0

Valves	Velocity max(m/sec mm/Hg)
AV	0.8/3 m/s
PV	1.0/4 m/s
MV (E)	0.8 m/s
(A)	0.6 m/s
TV (E)	1.3/7 m/s

**FINDINGS:**

- ❖ High heart rate during study.
- ❖ No regional wall motion abnormality.
- ❖ Normal left ventricle systolic function. (EF: 75%).
- ❖ Normal chambers dimension.
- ❖ Normal valves.
- ❖ Normal pericardium/Intact septae.
- ❖ No clot/aneurysm.

**IMPRESSION:**

- ▶ HIGH HEART RATE DURING STUDY.
- ▶ NO REGIONAL WALL MOTION ABNORMALITY.
- ▶ NORMAL LEFT VENTRICLE SYSTOLIC FUNCTION.

*S. Vignesh*

**S. VIGNESH M.Sc.  
ECHO TECHNICIAN**



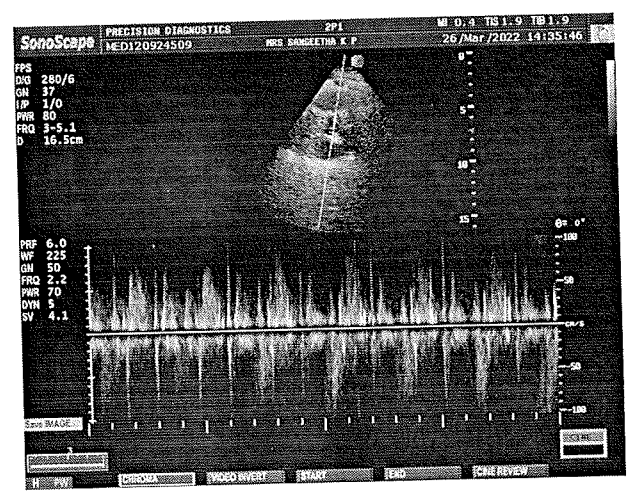
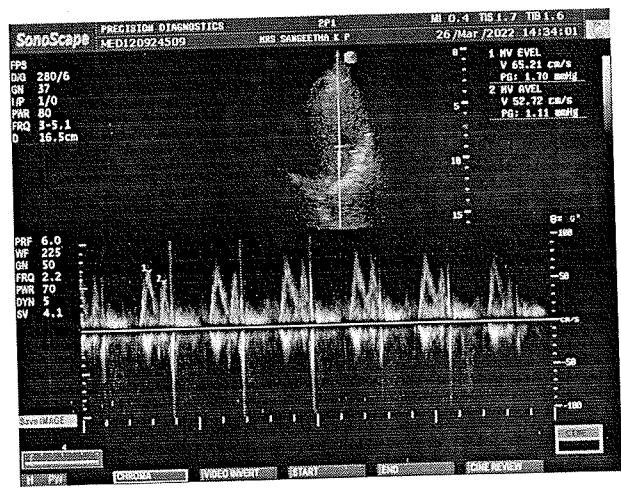
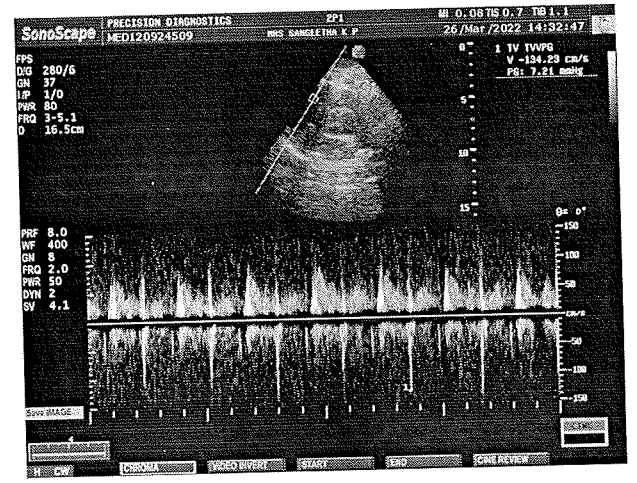
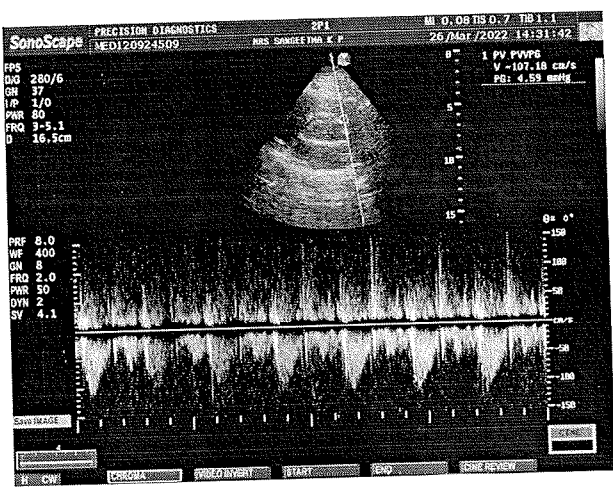
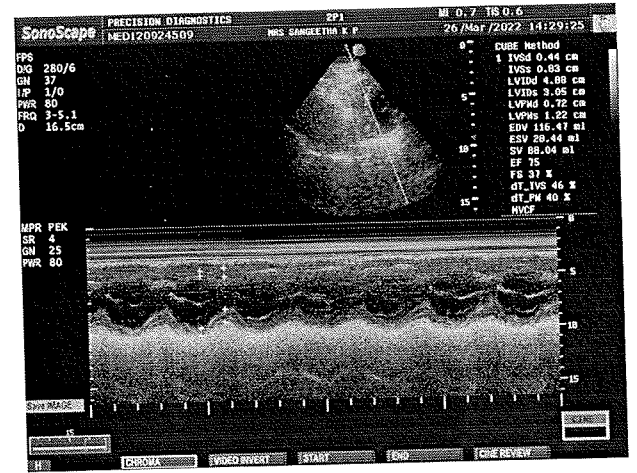
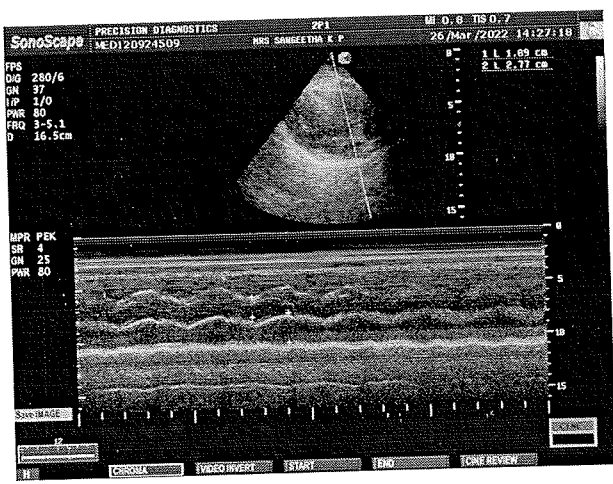


**MEDALL**

Precision Diagnostics-vadapalani

58/6, Revathy street, Jawarlal nehru road, 100 feet Road, (Former State Election Commission Office),

Customer Name	MRS.SANGEETHA K P	Customer ID	MED120924509
Age & Gender	28Y/FEMALE	Visit Date	26/03/2022
Ref Doctor	MediWheel		



You can also conveniently view the reports and trends through our App. Scan QR code to download the App.



Please produce bill copy at the time of collecting the reports. Request you to provide your mobile number or customer id during your subsequent visits.

Name	SANGEETHA K P	Customer ID	MED120924509
Age & Gender	28Y/F	Visit Date	Mar 26 2022 12:38PM
Ref Doctor	MediWheel		

**X- RAY CHEST PA VIEW**

Trachea appears normal.

Cardiothoracic ratio is within normal limits.

Bilateral lung fields appear normal.


Costo and cardiophrenic angles appear normal.

Visualised bony structures appear normal.

Extra thoracic soft tissues shadow grossly appears normal.

**IMPRESSION:**

- *Chest x-ray shows no significant abnormality.*



**Dr. Rama Krishnan. MD, DNB.,  
Consultant Radiologist.  
Medall Healthcare Pvt Ltd.**



AGE  
 Measurement Results:  
 QRS 86 ms  
 QT/QTcB 348 / 453 ms  
 PP 130 ms  
 P 94 ms  
 RR/PP 586 / 585 ms  
 P/QRS/T 59 / 48 / 27 degrees

III +90  
 II  
 aVF

< P  
 < T  
 < QRS  
 Interpretation:  
 WSL - Interpretation  
 Sinus tachycardia  
 Nonspecific ST abnormality  
 Abnormal ECG

Unconfirmed report

