

DEPARTMENT OF RADIO-DIAGNOSIS & IMAGING

Report : XRAY

Patient Name	: MRS. SHWETA KUMARI	IPD No.	:
Age	: 30 Yrs	UHID	: APH000014334
Gender	: FEMALE	Bill No.	: APHHC230000433
Ref. Doctor	: MEDIWHEEL	Bill Date	: 08-04-2023 08:34:47
Ward	:	Room No.	:
		Print Date	: 08-04-2023 12:45:25


CHEST PA VIEW:

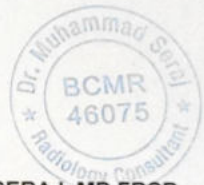Cardiac shadow appears normal.
Both lung fields appear clear.
Both domes of diaphragm and both CP angles are clear.
Both hila appear normal.
Soft tissues and bony cage appear normal.

Please correlate clinically.

.....End of Report.....

Prepare By.
MD.SERAJ


DR. MUHAMMAD SERAJ, MD,FCR
(London) Radiodiagnosis
CONSULTANT



Note : The information in this report is based on interpretation of images. This report is not the diagnosis and should be correlated with clinical details and other investigation.

DEPARTMENT OF RADIO-DIAGNOSIS & IMAGING

Report : ULTRASOUND

Patient Name	: MRS. SHWETA KUMARI	IPD No.	:
Age	: 30 Yrs	UHID	: APH000014334
Gender	: FEMALE	Bill No.	: APHHC230000433
Ref. Doctor	: MEDIWHEEL	Bill Date	: 08-04-2023 08:34:47
Ward	:	Room No.	:
		Print Date	: 08-04-2023 11:37:52

WHOLE ABDOMEN:

Both the hepatic lobes are normal in size and echotexture (Liver measures 11.8 cm)
 No focal lesion seen. Intrahepatic biliary radicals are not dilated.
 Portal vein is normal in calibre.
 Gall bladder is well distended. Wall thickness is normal. No calculus seen.
 CBD is normal in calibre.
 Pancreas is normal in size and echotexture.
 Spleen is normal in size (7.5 cm) and echotexture.
 Both kidneys are normal in size and echotexture (Right kidney (8.8 cm), Left kidney (9.3 cm). Cortico-medullary distinction is maintained. No calculus or hydronephrosis seen.
 Urinary bladder appears normal.
 Uterus is anteverted (measures 7.1 x 4.2 x 3.7 cm) and appears normal in size and echotexture. No focal lesion seen. Cervix and vagina are unremarkable.
 Endometrial echo is central and normal in thickness (5.5 mm).
 Both ovaries are normal in size and echotexture. Right ovary measures 2.1 x 1.3 cm, left ovary measures 2.6 x 1.4 cm.
 No free fluid or collection seen. No pleural effusion seen.
 No significant lymphadenopathy seen.
 No dilated bowel loop seen.

IMPRESSION: Normal study.

Please correlate clinically.....

.....End of Report.....



Prepare By.
MD.SERAJ

DR. MUHAMMAD SERAJ, MD,FRCC
(London) Radiodiagnosis
CONSULTANT

Note : The information in this report is based on interpretation of images. This report is not the diagnosis and should be correlated with clinical details and other investigation.