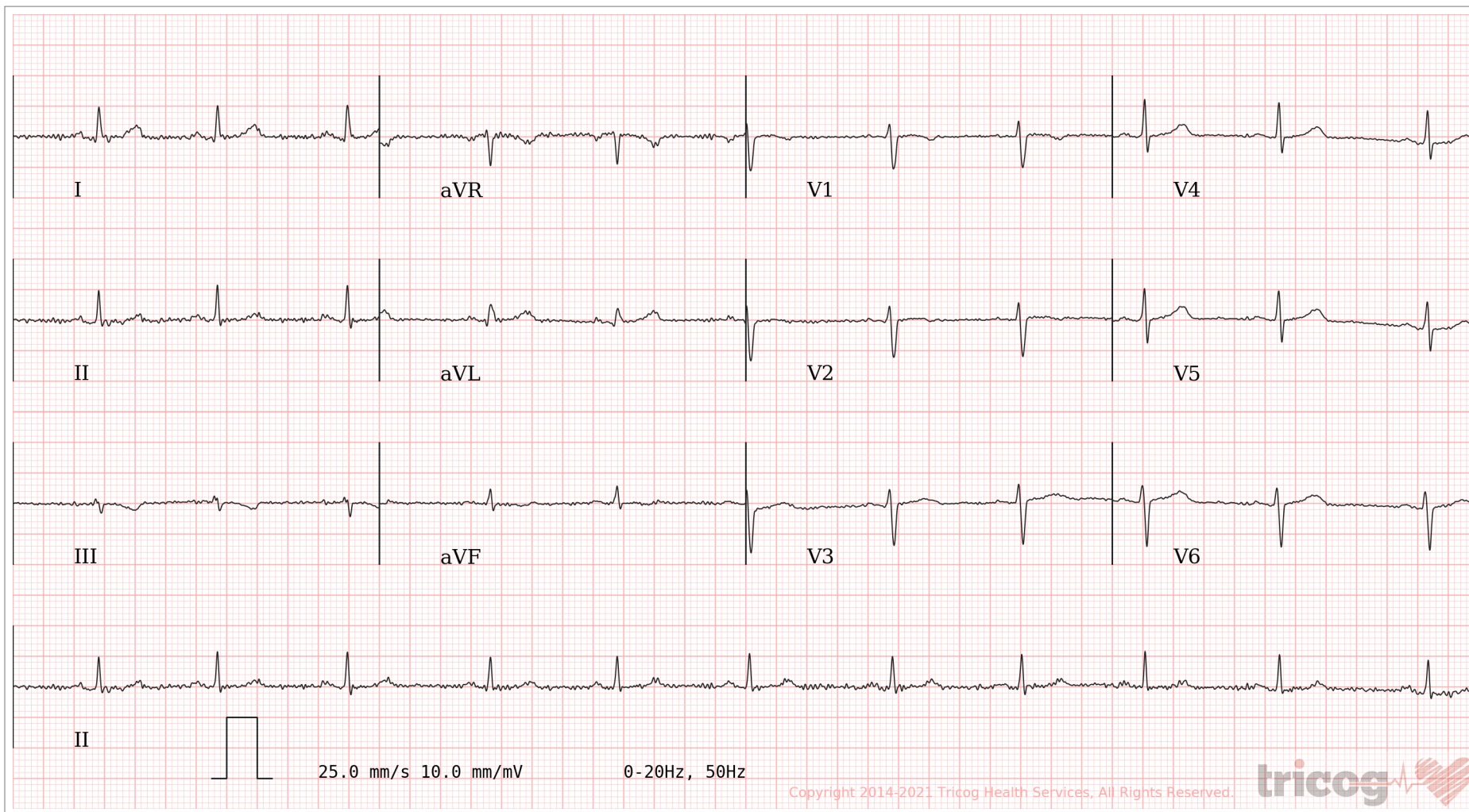




Age / Gender: 31/Female
Patient ID: CHFD0352402122
Patient Name: Mrs.SHASHIBALA

Date and Time: 31st Oct 21 10:15 AM



AR: 69 bpm VR: 69 bpm QRSD: 70 ms QT: 364 ms QTc: 390 ms PRI: 136 ms P-R-T: 43° 28° -1°

ECG Within Normal Limits: Sinus Rhythm, Normal Axis, with Sinus Arrhythmia. Please correlate clinically.

AUTHORIZED BY

Dr. Charit
MD, DM: Cardiology

REPORTED BY

Dr Prathima S.K