



To,

The Coordinator,  
Mediwheel (Arcofemi Healthcare Limited)  
Helpline number: 011- 41195959

Dear Sir / Madam,

**Sub: Annual Health Checkup for the employees of Bank of Baroda**

This is to inform you that the following spouse of our employee wishes to avail the facility of Cashless Annual Health Checkup provided by you in terms of our agreement.

PARTICULARS OF HEALTH CHECK UP BENEFICIARY	
NAME	SUNANDA SHARMA
DATE OF BIRTH	19-06-1983
PROPOSED DATE OF HEALTH CHECKUP FOR EMPLOYEE SPOUSE	02-07-2022
BOOKING REFERENCE NO.	22S181646100021020S
SPOUSE DETAILS	
EMPLOYEE NAME	MR. SHARMA CHANDAN
EMPLOYEE EC NO.	181646
EMPLOYEE DESIGNATION	HEAD CASHIER "E" _II
EMPLOYEE PLACE OF WORK	DUDHI
EMPLOYEE BIRTHDATE	30-12-1977

This letter of approval / recommendation is valid if submitted along with copy of the Bank of Baroda employee id card. This approval is valid from **27-06-2022** till **31-03-2023**. The list of medical tests to be conducted is provided in the annexure to this letter. Please note that the said health checkup is a **cashless facility** as per our tie up arrangement. We request you to attend to the health checkup requirement of our employee's spouse and accord your top priority and best resources in this regard. The EC Number and the booking reference number as given in the above table shall be mentioned in the invoice, invariably.


We solicit your co-operation in this regard.

Yours faithfully,

Sd/-


**Chief General Manager**  
**HRM Department**  
**Bank of Baroda**

(Note: This is a computer generated letter. No Signature required. For any clarification, please contact Mediwheel (Arcofemi Healthcare Limited))

 **બંક ઓફ બરોડા**  
**Bank of Baroda**

નામ: **ચંદન કુમાર**  
Name: **CHANDAN KUMAR**

કર્મચારી ક્રમ નં: **181646**  
E.C. No. **181646**

   
જાણીતી પ્રતિષ્ઠા ધરાવતી વેબસાઇટ (જા.વે.સાઇટ)  
Issuing Authority: Regional Manager (M.R.)

સહી: **CHANDAN KUMAR**  
Signature of Holder

**HOSPITAL LIMITED**  
**DHARBAD**



भारत सरकार  
GOVERNMENT OF INDIA



सुनंदा शर्मा

Sunanda Sharma

जन्म तिथि/DOB: 19/06/1983

महिला/ FEMALE

2119 3370 8551

VID : 9158 3863 8924 8445

मेरा आधार, मेरी पहचान



भारतीय विशिष्ट पहचान प्राधिकरण  
UNIQUE IDENTIFICATION AUTHORITY OF INDIA

पता:


द्वारा: चन्दन शर्मा, फ्लैट न 2बी स्नेह आश्रया अप्पत,  
पोस्ट नामकुम, थाना नामकुम, नामकुम, रांची,  
झारखण्ड - 834010

Address:

C/O: Chandan Sharma, flat no 2b sneh  
ashraya appt, post namkum, thana namkum,  
Namkum, Ranchi,  
Jharkhand - 834010

2119 3370 8551

VID : 9158 3863 8924 8445



1947



help@uidai.gov.in

www

www.uidai.gov.in

9564239891





### Asarfi Hospital Limited.

Baramuri, P.O.-Bishunpur Polytechnic, Dhanbad(Jharkhand)

Phone : 03262295147 Fax : 08817844529

Email: asarfihospital@hotmail.com



### Medi Wheel Full Body Health Checkup

Bill No: AHL/Medi Wheel/2022/52

Bill Date :16.07.2022

TIN NO.20861605701

#### Patient Details

Registration no : JUL22-21825

Patient Name : MRS.SUNANDA SHARMA

Gende : FEMALE

Age : 38 Yrs

Phone No.

Address : FLT-2B,SNEHASHRAYA,DHANBAD, JHARKHAND, INDIA

Mobile No : 9564239891

Sl.No.	Service(s) Name	Rate	Quantity	Discount	Total.
1	Medi Wheel Full Body Health Checkup Below 40 Years (PACKAGE)	1800.00	1	0.00	1800.00
				<b>Total Rs.</b>	<b>1800.00</b>
<b>(Rupees One Thousand Eight Hundred Only)</b>				<b>Net Amount.</b>	<b>1800.00</b>
<b>Prepared By :</b>			<b>Mr. Anikesh paul</b>		







# MEDICA Heart Institute

caring for life

A Unit of Asarfi Hospital Limited, Dhanbad



Mediwheel

## OUT PATIENT DEPARTMENT

Department of Cardiology

Regd. No. : JUL22-21825 Visit : OPD/160722/10723  
 Patient Name : MRS. SUNANDA SHARMA Mobile : 9564239891  
 Age Sex : 38 Y 0 M 27 D / Female Date : 16-Jul-2022 3:08 pm  
 Address : FLT NO-2B, SNEHASHRAYA APPT, P.O-NAMKUN, RANCHI - Jharkhand, INDIA  
 Doctor : Dr. Suraj Chavan MBBS, DNB (Cardiology) OPD Timing : MON-SAT (11AM - 2PM)  
 Referred By :

Allergies :

Height : Ft In Temp. : C SPO2 : 97 %  
 Weight : 78 Kg Pulse : 120 bpm B.P. : 100/90 mm/Hg

History and complaints :

*Routine check up*

Examination:

*Asymptomatic*

Diagnosis:

*OPD ->*

*ECG - ST T V<sub>1</sub>-V<sub>6</sub>*

*Asymptomatic*

Investigations:

*ECG - (M)*

*TMT - false positive*

Medicines Prescribed:

Follow up:

Days

Advice  
(Diet/ Lifestyle / Rehab)

Date :

Time :

Signature of Doctor

39 Years

MRS SUNANDA SHARMA  
Female

16-Jul-22 11:52:15  
MEDICA DEARBAD

Rate 82 Sinus rhythm.....normal  
PR 145 Abnorm T, consider ischemia, anterolateral lds.....normal  
QRSD 98 P axis, V-rate 50-99  
QT 354 T <-0.20mV, I aVL V2-V6  
QTc 414

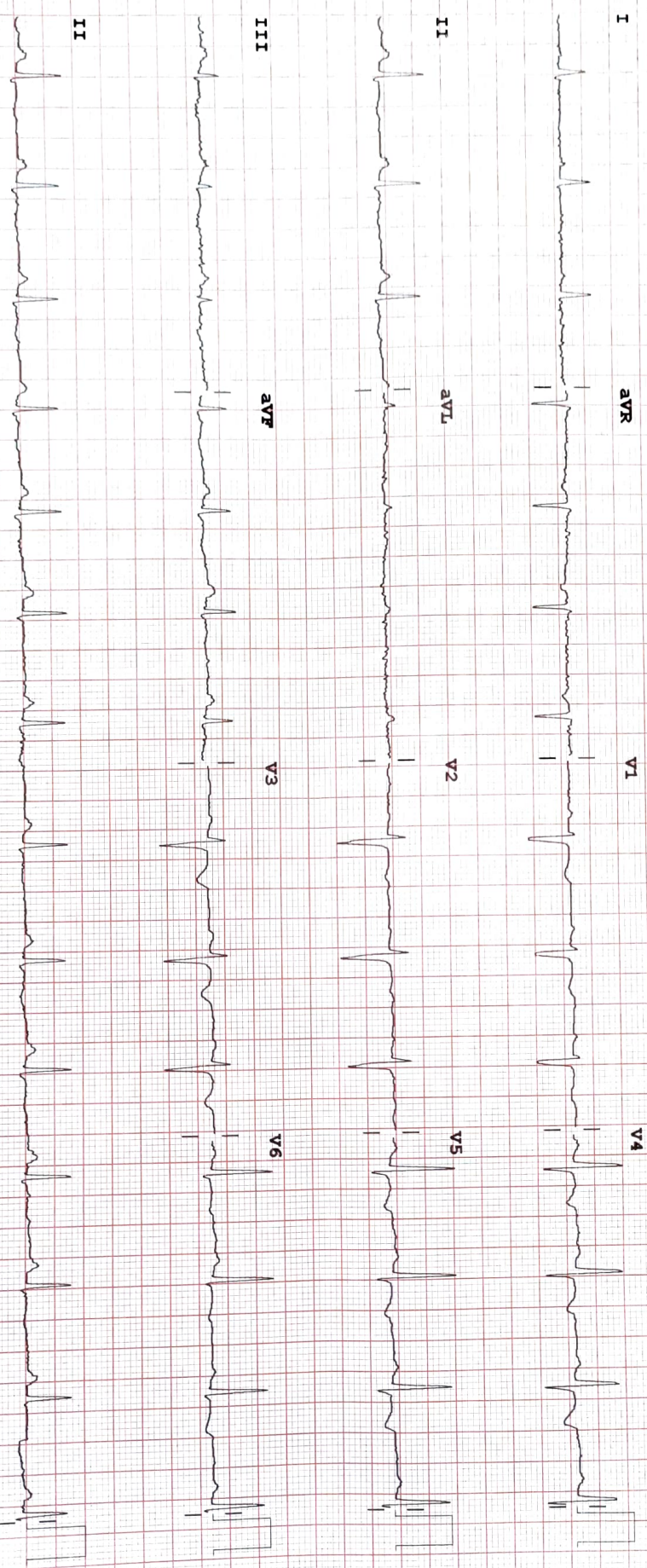
--AXIS--  
P 74  
QRS 39  
T -81



- ABNORMAL ECG -

Unconfirmed Diagnosis

12 Lead; Standard Placement



Device:

Speed: 25 mm/sec

Limb: 10 mm/mV

Chest: 10.0 mm/mV

F 50~ 0.50-100 Hz W

PH100B CL

P?

INFORMANTS




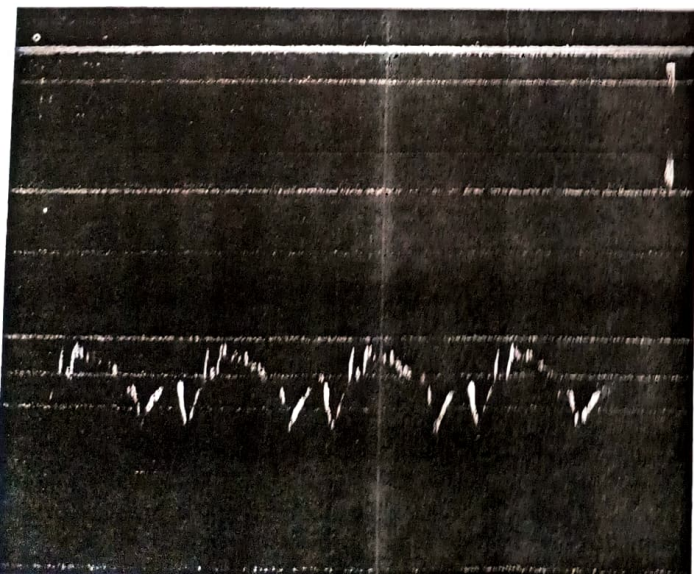
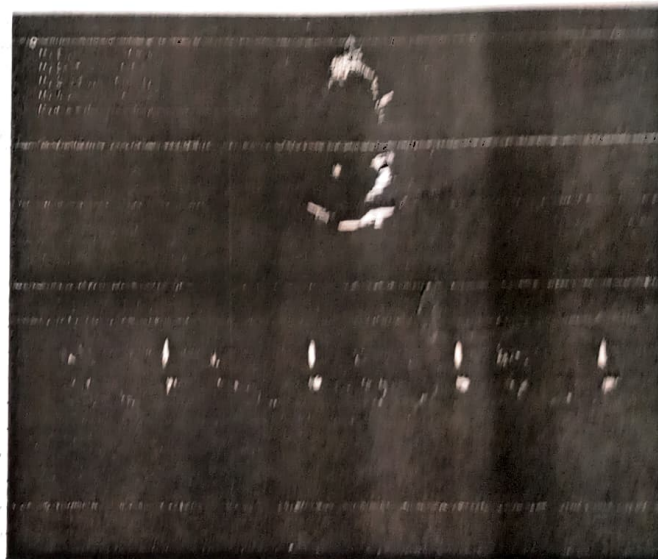
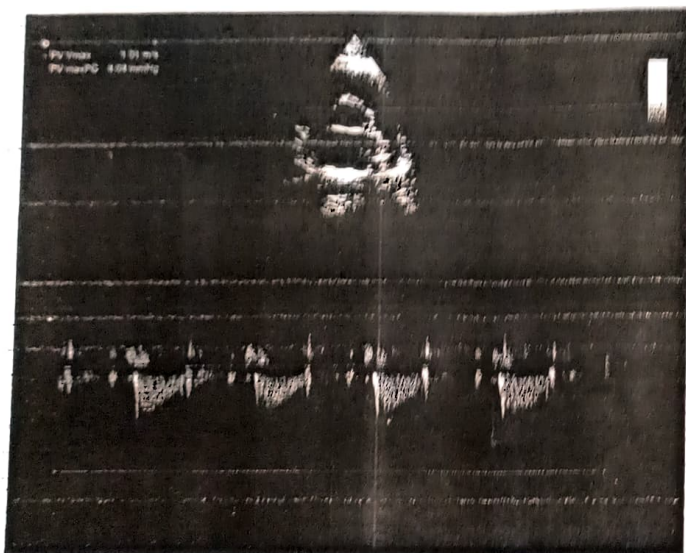


# MEDICA HEART INSTITUTE, DHANBAD HOSPITAL



Name : MRS SUNANDA SHARMA

Date : 07/16/2022

Patient Id : MRS S54\_54076



**ECHOCARDIOGRAPHY REPORT**  
**Reports**

Name: **MRS SUNANDA SHARMA**

Age: **39**

Sex: **Female**

Date: **07/16/2022**

**2D & M-MODE MEASUREMENTS**

IVSd	0.9 cm
LVIDd	5.2 cm
LVPWd	1.0 cm
IVSs	1.4 cm
LVIDs	3.4 cm
Ao Diam	3.0 cm
LA Diam	4.1 cm

**2D & M-MODE CALCULATIONS**

EDV(Teich)	130 ml
ESV(Teich)	46 ml
EF(Teich)	65%
%FS	36%
SV(Teich)	84 ml
LVd Mass	214.68 g
RWT	0.38
LA/Ao	1.36

**MITRAL VALVE**

MV E Vel	0.91 m/s
MV DecT	191 ms
MV Dec Slope	4.8 m/s <sup>2</sup>
MV A Vel	0.69 m/s
MV E/A Ratio	1.32
E'	0.10 m/s
E/E'	9.09

**AORTIC VALVE**

**TRICUSPID VALVE**

**PULMONARY VALVE**

PV Vmax	1.01 m/s
PV maxPG	4.04 mmHg

**COMMENTS:**

- NORMAL SIZE CARDIAC CHAMBERS
- NO LVRWMA
- GOOD LV SYSTOLIC FUNCTION (EF- 63%)
- NO MR, AR, NO TR
- IAS, IVS INTACT
- NO CLOT, PE
- IVC NORMAL

**IMPRESSION:**

- NORMAL SIZE CARDIAC CHAMBERS
- NO LVRWMA
- GOOD LV SYSTOLIC FUNCTION (EF- 63%)

DR. S.H CHAVAN  
(CONSULTANT CARDIOLOGIST)

TECH. SIG



GRADED EXERCISE SUMMARY

MRS SUNANDA, SHIRMA

ID: 000021825

Visit:

39years

Caucasian

Female

Total Exercise time: 6:14

Max HR: 183bpm 101% of max predicted 181bpm

Max BP: \*\*\*/\*\*

Maximum workload: 7.3METS

Reason for Termination: Leg discomfort

Comments:

16-Jul-2022

14:11:58

Referred by: DR.S.H.CHAVAN

Test ind:

BASELINE

EXERCISE STAGE 1  
0:00 1.6METS

ST @ 10mm/mV  
80ms postJ

Lead  
ST(mm)  
Slope(mV/s)

I	aVR	-0.0	-0.1	-0.3
	aVL	0.1	-0.5	
II	aVL	0.0	0.2	-0.4
	aVF	-0.3	-0.9	0.0
III	aVF	-0.3	0.0	
	V1	0.2	-0.2	-0.8
	V2	0.2	-0.4	
	V3	-0.2	-0.9	0.0
	V4	-0.1	-0.5	
	V5	-0.2	0.1	
	V6	0.0	0.3	

MAX ST

EXERCISE STAGE 2  
3:33 5.2METS

ST @ 10mm/mV  
80ms postJ

Lead  
ST(mm)  
Slope(mV/s)

I	aVR	0.0	0.2	-0.2
II	aVL	-0.9	0.0	0.1
III	aVF	-1.9	-1.0	-0.2
	V1	0.2	0.4	
	V2	-0.1	0.4	
	V3	-0.6	-0.6	0.1
	V4	-1.0	-0.4	
	V5	-1.6	0.5	
	V6	-0.7	-0.3	



Unconfirmed

Technician:

MAC55-010B



Baramun, P.O - Bishunpur Polytechnic, Dhanbad (Jharkhand) 826130  
Regd. Office : Phulantand Kharkarea, Dhanbad (Jharkhand) 826126  
Mob: 78083 68088  
CIN : U05110JH2005PLC011673

# RADIOLOGY REPORT



Reg. No.	21825	Ref. Dr.	SELF
Name	MRS. SUNANDA SHARMA	Study	USG W/A
Age & Sex	39Y /F	Reporting Date	15.07.2022

## USG WHOLE ABDOMEN

- LIVER** : Liver is normal in size. It appears bright in echotexture. No obvious focal lesion is seen. IHBR are not dilated.
  - GALL BLADDER** : GB is well distended. No obvious calculus or mass lesion is seen. The wall thickness is normal.
  - CBD** : CBD is normal in course & caliber.
  - PV** : PV is normal in course & caliber.
  - PANCREAS** : Pancreas is normal in size, shape & echotexture. Peripancreatic soft tissues appear normal. MPD is not dilated.
  - SPLEEN** : Spleen is normal in shape, size & echotexture. It measures 10.7 cm in size.
  - KIDNEYS** : The right kidney measures 10.1 x 4.5cm. The left kidney measures 10.5 x 4cm. Both kidneys are normal in shape, size & position. The pelvicalyceal system is normal. Corticomedullary differentiation is maintained. No focal lesion is seen.
  - URINARY BLADDER** : Urinary bladder is well distended. No obvious calculus or mass lesion is seen. The wall thickness is normal.
  - UTERUS** : Uterus is normal in size, shape & echotexture. It measures 9.2 x 3.8 x 5cm. Endometrium is central and measures 7.6 mm.
  - OVARIES** : The right ovary measures 2.7 x 1.9cm. The left ovary measures 2.6 x 1.5cm. Both ovaries are normal in shape, size & position.
  - OTHERS** : No ascites or retroperitoneal lymphadenopathy is seen.
  - IMPRESSION** :
    - Grade I diffuse fatty infiltration of liver.
- Clinical correlation is suggested.

Dr. VAISHALI PATEL  
MBBS, DNB (Radio-diagnosis)  
Consultant Radiologist

24 HOUR EMERGENCY

GAJULURAI/14/2226/PP/22



"KEEP THE REPORTS CAREFULLY AND BRING THEM ALONG DURING YOUR NEXT VISIT TO OUR HOSPITAL"

## RADIOLOGY REPORT



Patient Name	MRS SUNANDA SHARMA	IP No.	21825
Age / Gender	39Y/FEMALE	Exam Date	JUL 16 2022
Referring Doctor	SELF	Request Date	JUL 16 2022

### CHEST RADIOGRAPH FRONTAL VIEW

#### TECHNIQUE:

Frontal projections of the chest were obtained

#### FINDINGS

- Both lung fields are clear.
- Both costophrenic angles appear normal.
- The tracheal lucency is centrally placed.
- The mediastinal and diaphragmatic outlines appear normal.
- The heart shadow is normal.
- The bony thoracic cage and soft tissues are normal.

#### IMPRESSION

- The study is within normal limits.

*Suggested Clinical Correlation.*

*N. Sunil Kumar*

**Dr. Sunil Kumar N**

MD Radiodiagnosis (APMC-50941)

Consultant Radiologist

