

Facilities:
 All clinical Biomedical & Hematology Investigations
 including Bone Marrow Examination
 VPT, Podiascan & Complete Foot Care (First Time in Purvanchal)
 All Hormonal Investigation by Chemiluminescent Method
 Visceral Fat by (AB-140) Ambulatory BP Monitoring
 CGMS & Insulin Pump Available
 PFT, 2D-ECHO (Color Doppler), Holter, TMT, Cardiac-3 available
 VIA, VILI, Colposcopy available
 Special Endocrinological Investigation Protocols.

ISO 9001:2008 Certified
 Mobile: 9389994334, 9554572190, 9453837595



Panacea Pathology

Clinical Reference Lab

Persistence, Preparedness and Precision
 EQAS (CMC Vellore Attached) & IQAS System
 पूर्वांचल की सर्वोत्तम गुणवत्ता वाली पैथोलॉजी

PATIENT NAME : RENU SINGH	AGE/GENDER : 46 YRS/FEMALE
REFD BY DR. : ARCO FEMI HEALTHCARE LTD.	RECEIVED DATE : 25-11-2022 (11:15 AM)
SAMPLE : BLOOD & URINE	REPORT DATE : 25-11-2022 (07:15 PM)

PATHOLOGY REPORT

COMPLETE BLOOD COUNT (CBC)

TEST	LAB TEST VALUES	NORMAL RANGE
HEMOGRAM		
HEMOGLOBIN (FLOW CYTOMETRY)	13.0	13 – 16 gm/dl
TOTAL LEUCOCYTE COUNT (TLC)	5,800	4000 – 11000
RBC COUNT	4.31	3.5 – 5.5
PCV (HCT)	40.0	37 – 47
MCV	92.8	80 – 95
MCH	30.2	28 – 34
MCHC	32.2	30 – 36
PLATELET COUNT	1,43,000	1,50,000 – 4,00,000
E.S.R. (WINTROBE FIRST HOURS)	12.0	20 mm/1 st hr
DIFFERENTIAL LEUCOCYTE		
NEUTROPHILS	68	40 – 75%
LYMPHOCYTES	25	20 – 45%
EOSINOPHILS	04	1 – 6%
MONOCYTES	03	2 – 8%
BASOPHILS	00	< 2 %

RENAL & KIDNEY PROFILE, SERUM

TEST	LAB TEST VALUES	NORMAL RANGE
RENAL FUNCTION TESTS		
BLOOD UREA NITROGEN (BUN)	9.8	10 – 50 mg/dl
SERUM CREATININE	0.62	0.60 – 1.60 mg/dl
URIC ACID	3.96	3.60 – 7.70 mg/dl
ALKALINE PHOSPHATASE (ALP)	110.0	142 – 353 mg/dl
TOTAL PROTIENS	7.25	0 – 39 mg/dl
ALBUMIN	4.00	3.8 – 5.4 mg/dl
SERUM GLOBULIN	3.25	2.1 – 3.5 mg/dl
CALCIUM	9.8	8.80 – 10.20
PHOSPHORUS	3.92	2.50 – 5.00
SERUM SODIUM NA+	139.8	135.00 – 155.00 mEq/Ltr
SERUM POTASIUM K+	4.28	3.60 – 5.50 mEq/Ltr
ICALCIUM	1.25	1.10 – 1.35 mmol/L
SERUM CHLORIDE CL+	103.3	98.00 – 110.00 mEq/Ltr

PAGE 1

Lab Technician

PANACEA HOSPITAL
 (A UNIT OF AAROH HEALTH CARE PVT. LTD.)

M.D. Pathology

B-36/44, B-4, KABIR NAGAR

DURGAKUND, VARANASI

Timing : 8.00 a.m. to 9.00 p.m. (Sunday 8.00 a.m. to 3.00 p.m.)

This Report is not valid for medico-legal purpose

Note: These tests have technical limitations. Clinico-pathological interpretation is necessary. In case of any disparity test may be repeated immediately.

Address : 36/44 FK Kabir Nagar, Durgakund, Varanasi – 221005

Email: dramishra@gmail.com, drpallaviojha@gmail.com Website: panaceahospital.org

Facilities:

All clinical Biomedical & Hematology Investigations
 including Bone Marrow Examination
 VPT, Podiascan & Complete Foot Care (First Time in Purvanchal)
 All Hormonal Investigation by Chemiluminescent Method
 Visceral Fat by (AB-140) Ambulatory BP Monitoring
 CGMS & Insulin Pump Available
 PFT, 2D-ECHO (Color Doppler), Holter, TMT, Cardiac-3 available
 VIA, VILI, Colposcopy available
 Special Endocrinological Investigation Protocols.

ISO 9001:2008 Certified
 Mobile: 9389994334, 9554572190, 9453837595



Panacea Pathology

Clinical Reference Lab

Persistence, Preparedness and Precision
 EQAS (CMC Vellore Attached) & IQAS System
 पूर्वांचल की सर्वोत्तम गुणवत्ता वाली पैथोलॉजी

PATIENT NAME : RENU SINGH	AGE/GENDER : 46 YRS/FEMALE
REFD BY DR. : ARCO FEMI HEALTHCARE LTD.	RECEIVED DATE : 25-11-2022 (11:15 AM)
SAMPLE : BLOOD & URINE	REPORT DATE : 25-11-2022 (07:15 PM)

PATHOLOGY REPORT

LIPID PROFILE, SERUM

TEST	LAB TEST VALUES	NORMAL RANGE
BLOOD CHEMISTRY		
TOTAL CHOLESTEROL (SERUM)	170.0	Desirable:- < 200 mg/dl Borderline:- 200 – 239 mg/dl High:- > 240 mg/dl
TRIGLYCERIDES (SERUM)	156.0	35 – 170 mg/dl
HDL CHOLESTEROL (SERUM)	44.0	35.30 – 79.50 mg/dl
LDL CHOLESTEROL (SERUM)	94.8	< 130 mg/dl
VLDL	31.2	< 40 mg/dl
NON HDL	72.0	0.00 – 100.00 mg/dl
CHOLESTROL/HDL RATIO	4.10	< 3.0 Low Risk Ratio 3.0 – 5.0 Avg Risk > 5.0 High Risk
LDL/HDL RATIO	2.34	< 3 Ratio

ESR

TEST	LAB TEST VALUES
BLOOD GROUP ABO & RH FACTOR	
BLOOD GROUP	"B"
RH FACTOR	POSITIVE

GLYCOSYLATED HEMOGLOBIN (HBA1C)

TEST	LAB TEST VALUES	NORMAL RANGE
HBA1C	5.8	Normal : < 5.97 % Good Control : 5.97 – 6.81% Fair Control : 6.81 – 7.65% Poor Control : > 7.65%

THYROID PROFILE (T3, T4, TSH)

TEST	LAB TEST VALUES	NORMAL RANGE
THYROID FUNCTION TEST		
T3	0.98	0.60 – 1.81 ng/ml
T4	8.15	4.50 – 10.90 ug/dl
TSH	2.16	0.39 – 6.10 uIU/mL

PAGE 2

Lab Technician

Timing : 8.00 a.m. to 9.00 p.m. (Sunday 8.00 a.m. to 3.00 p.m.)

This Report is not valid for medico legal purpose

Note: These tests have technical limitations. Clinico-pathological interpretation is necessary. In case of any disparity test may be repeated immediately.

Address : 36/44 FK Kabir Nagar, Durgakund, Varanasi – 221005

Email: dramishra@gmail.com, drnallavioiha@gmail.com, Website: www.panaceahospital.com

PANACEA HOSPITAL
 A UNIT OF AAROH HEALTH CARE PVT. LTD.,
 MED. Pathology
 B-36/44, B-4, KABIR NAGAR
 DURGAKUND, VARANASI



Panacea Pathology

Clinical Reference Lab

Persistence, Preparedness and Precision
EQAS (CMC Vellore Attached) & IQAS System
पूर्वांचल की सर्वोत्तम गुणवत्ता वाली पैथोलॉजी

Facilities:

All clinical Biomedical & Hematology Investigations
including Bone Marrow Examination
VPT, Podiascan & Complete Foot Care (First Time in Purvanchal)
All Hormonal Investigation by Chemiluminescent Method
Visceral Fat by (AB-140) Ambulatory BP Monitoring
CGMS & Insulin Pump Available
PFT, 2D-ECHO (Color Doppler), Holter, TMT, Cardiac-3 available
VIA, VILI, Colposcopy available
Special Endocrinological Investigation Protocols.

PATIENT NAME : RENU SINGH	AGE/GENDER : 46 YRS/FEMALE
REFD BY DR. : ARCO FEMI HEALTHCARE LTD.	RECEIVED DATE : 25-11-2022 (11:15 AM)
SAMPLE : BLOOD & URINE	REPORT DATE : 25-11-2022 (07:15 PM)

PATHOLOGY REPORT

LIVER PROFILE TEST, SERUM

TEST	LAB TEST VALUES	NORMAL RANGE
BIO CHEMISTRY		
TOTAL BILIRUBIN	0.79	0.0 – 1.1 mg/dl
DIRECT BILIRUBIN	0.27	0.0 – 0.2 mg/dl
INDIRECT BILIRUBIN	0.52	< 0.90 mg/dl
SGOT (AST)	26.6	0 – 52 mg/dl
SGPT (ALT)	30.2	0 – 39 mg/dl
GGT (GYT)	21.0	< 55 U/L
AG RATIO	1.96	-

URINE ROUTINE EXAMINATION

TEST	LAB TEST VALUES	NORMAL RANGE
PHYSICAL EXAMINATION		
QUANTITY	29	ML
COLOUR	STRAW	PALE YELLOW
APPEARANCE	CLEAR	CLEAR
SPECIFIC GRAVITY	1.015	1.01 – 1.03
PH	5.5	4.7 – 7.5
CHEMICAL EXAMINATION		
GLUCOSE	Not Detected	Not Detected
PROTEIN	NIL	Not Detected
MICROSCOPIC EXAMINATION		
PUS CELLS	1-2	0-5
RBC	Not Detected	Not Detected
EPITHELIAL CELLS	1-2	0-5
CASTS	Not Detected	Not Detected
CRYSTALS	Not Detected	Not Detected
BACTERIA	Not Detected	Not Detected

PAGE 3

Lab Technician

Timing : 8.00 a.m. to 9.00 p.m. (Sunday 8.00 a.m. to 3.00 p.m.)

This Report is not valid for medico legal purpose

Note: These tests have technical limitations. Clinico-pathological interpretation is necessary. In case of any disparity test may be repeated immediately.

Address : 36/44 FK Kabir Nagar, Durgakund, Varanasi – 221005

Email: dramishra@gmail.com, drpallaviojha@gmail.com Website: panaceahospital.org

PANACEA HOSPITAL
A UNIT OF AARON HEALTH CARE PVT. LTD.,
M.D.C. Pathology 1500
B-36/44, B-4, KABIR NAGAR
DURGAKUND, VARANASI

FACILITIES:

All clinical Biomedical & Hematology Investigations
 including Bone Marrow Examination
 VPT, Podiascan & Complete Foot Care (First Time in Purvanchal)
 All Hormonal Investigation by Chemiluminescent Method
 Visceral Fat by (AB-140) Ambulatory BP Monitoring
 CGMS & Insulin Pump Available
 PFT, 2D-ECHO (Color Doppler), Holter, TMT, Cardiac-3 available
 VIA, VILI, Colposcopy available
 Special Endocrinological Investigation Protocols

ISO 9001:2008 Certified
 Mobile: 9389994334, 9554572190, 9453837565



Panacea Pathology

Clinical Reference Lab

Persistence, Preparedness and Precision
 EQAS (CMC Vellore Attached) & IQAS System
 पूर्वांचल की सर्वोत्तम गुणवत्ता वाली पैथोलॉजी

PATIENT NAME : RENU SINGH	AGE/GENDER : 46 YRS/FEMALE
REFD BY DR. : ARCO FEMI HEALTHCARE LTD.	RECEIVED DATE : 25-11-2022 (11:15 AM)
SAMPLE : BLOOD & URINE	REPORT DATE : 25-11-2022 (07:15 PM)

FASTING/RANDOM BLOOD SUGER

TEST	LAB TEST VALUES	NORMAL RANGE
FBS/RBS		
FASTING BLOOD SUGER	112.5	110-125 mg/dl
RANDOM BLOOD SUGER	113.0	125-140 mg/dl

----- End of Report -----

Lab Technician

[Signature]
PANACEA HOSPITAL
 UNIT OF AARORA HEALTH CARE PVT. LTD.
 M.D. Pathology
 REG. NO. 118800
 B-36/44, B-4, KABIR NAGAR
 DURGAKUND, VARANASI

Timing : 8.00 a.m. to 9.00 p.m. (Sunday 8.00 a.m. to 3.00 p.m.)

This Report is not valid for use in any other hospital.

Note: These tests have technical limitations. Clinico-pathological interpretation is necessary. In case of any disparity test may be repeated immediately.

Address : 36/44 FK Kabir Nagar, Durgakund, Varanasi – 221005

Email: dramishra@gmail.com, drpallaviojha@gmail.com Website: panaceahospital.org

निवास स्थान Lane.no. 07 Gautam Nagar Colony Shushwahi
Resi. Address Varanasi 221011

जन्म तिथि 05.12.1976
Date of Birth

रक्त समूह AB+ve
Blood Group

पहचान चिन्ह
Identification Mark cut mark on forehead

दूरभाष कार्यालय 7753996042 निवास
Tel. No. Office Resi.
अनुदेश _____

1. स्थानांतरण या सेवानिवृत्ति होने पर इसे लौटाया जाये।

Return on Transfer/retirement.

2. इस पहचान पत्र के खो जाने पर कार्यालय तथा सीमावर्ती पुलिस स्टेशन को तत्काल रिपोर्ट की जाये।

In case of loss, report to the office and P.S. Immediately.

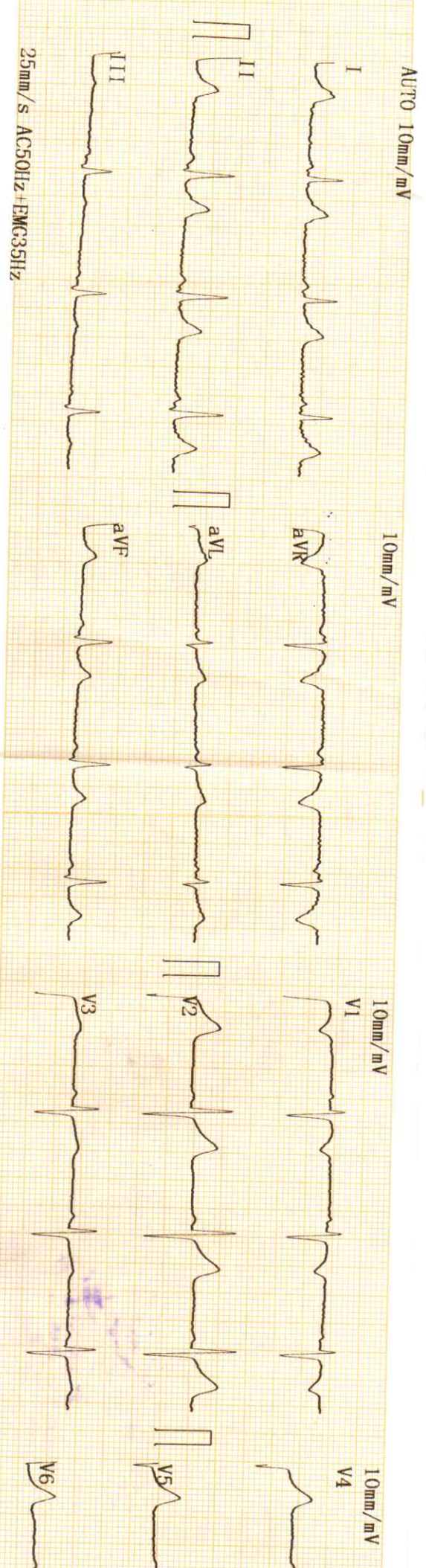
3. इस के खो जाने पर नये पहचान पत्र का मूल्य धारक को देना होगा।

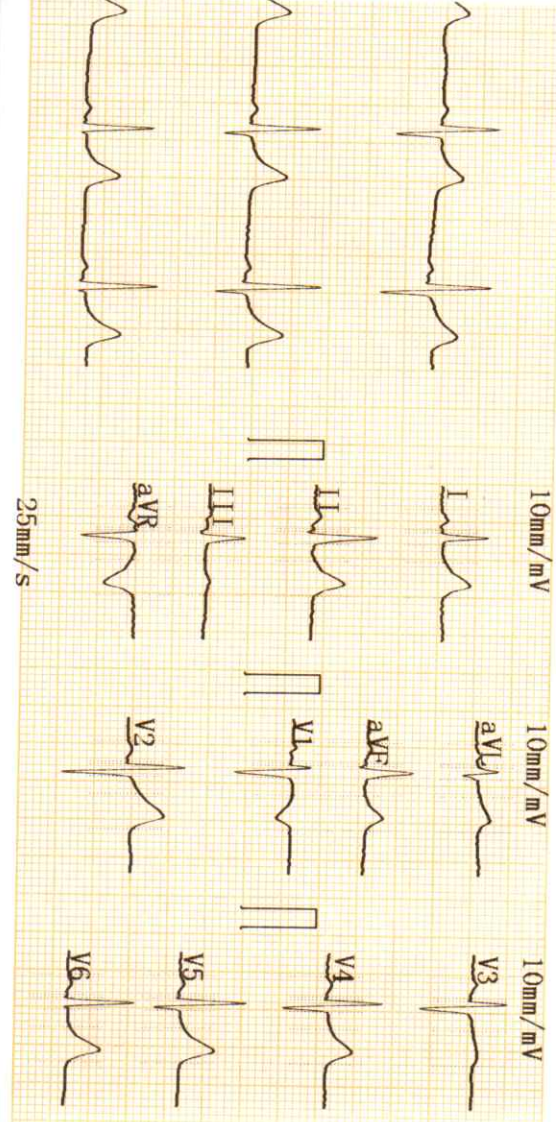
In case of loss of I/Card, Holder will bear the cost of new I/Card.

4. यह परिचय पत्र निर्गम तिथि से 05 वर्ष के लिए वैध है।

This I/Card is valid for 05 years from date of issue

2011-09-29





2022-11-25 09:15

ID :
 Name : Renu Singh
 Sex : F
 Height :
 SYS :
 DIA :
 HR [bpm] : 70
 PR Interval [ms] : 126
 P Duration [ms] : 111
 QRS Duration [ms] : 67
 T Duration [ms] : 189
 QT/QTc [ms] : 351/377
 P/QRS/T Axis [deg] : 63.2/55.6/30.8
 R(V5)/S(V1) [mV] : 0.87/0.75
 R(V5)+S(V1) [mV] : 1.62

<< Conclusions >>

Cardiac electric axis normal

**Report need physician

DR. PALLAVI KUMAR
 MBBS, MCI Reg. No. 5203

Pammi

Physician

CARDIOPRI



भारत सरकार

Govt. of India

रेल मंत्रालय

Ministry of Railways

ब.रे.का.

वाराणसी

Banaras Locomotive Works

VARANASI



परिचय पत्र संख्या
I/Card No. 1707

कर्मचारी संख्या
Emp. No. 15768

नाम
Name

: श्रीमती रेनु देवी
: SM. RENU DEVI

पिता/पति का नाम
Father/Husband's name

: Mr. Ravi Shankar Rai

पद
Designation

: Prg. man-I Fitter

विभाग
Department

: Mechanical

Renu

कर्मचारी के हस्ताक्षर
Sign. of Employee

निर्गम तिथि: 19.01.2022

[Signature]
स. सुरक्षा आयुक्त/रे.सु.ब.



PANACEA HOSPITAL

A shelter for many hearts A Home for many lives

(An ISO 9001:2008 Certified Organisation)

Lab Attached with CMC Vellore Under EQAS Scheme

Name	MRS.RENU SINGH	Sex /Age	42Y/F	Date	25/11/2022
Ref. by	SELF	BSA - m ²		Echo window	fair

Echo - Cardiography

MITRAL VALVE Doppler	AML - normal morphology MV Flow - E - 0.4 A-0.2 E/A=1.46	PML - normal morphology MVA - 3.0 cm2 Mitral Regurgitation - No
TRICUSPID VALVE Doppler	Normal TV Flow -No	Tricuspid Regurgitation - No
PULMONARY VALVE Doppler	Normal PV Flow -No	Pulmonary Regurgitation - No
AORTIC VALVE Doppler	Trileaflet-No AV Flow - no	Aortic Regurgitation - No
MEASUREMENT	Aorta - 23.4 (20-38) mm IVS ed - 10.9 (6 -12) mm LVID ed - 36.0 (35 - 55) mm LVPW ed - 19.6 (6 -12) mm OA - 7 (> 5) mm	LA -26.8 (24-32) mm IVS es -14.8 (6 - 12) mm LVID es - 24.6 (24 - 40) mm LVPW es - 14.3 (6 -12) mm EPSS - 08 (< 9) mm


CONCLUSION

All cardiac chamber dimensions are WNL
No valvular abnormalities
Good LV systolic function present Modified Simpson's method (4C, 2C) (LVEF-61%)
No diastolic dysfunction present (E/A = 1.46) by tissue Doppler (E/e'=6.2)
No RWMA
No pericardial effusion
Intact IAS / IV
No PAH
No intra cardiac mass /thrombus /vegetation

IMPRESSION

Normal Echocardiogram

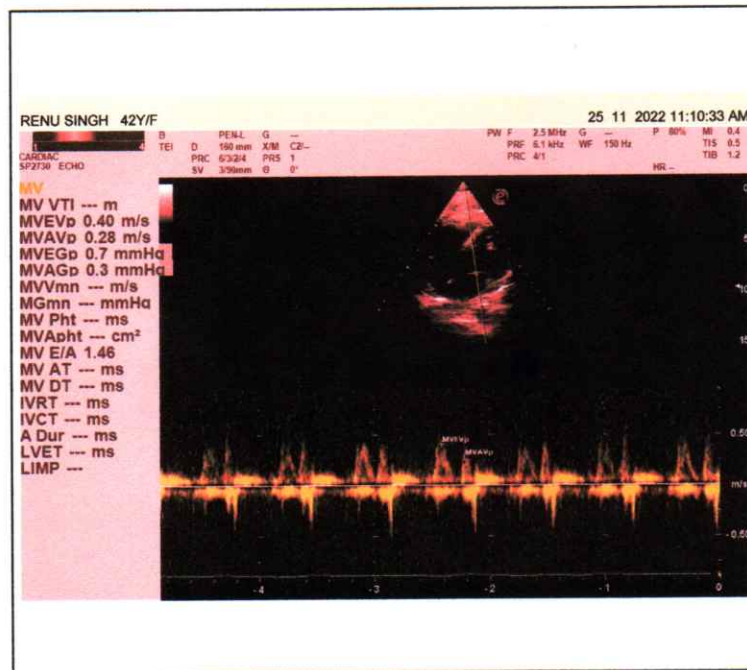
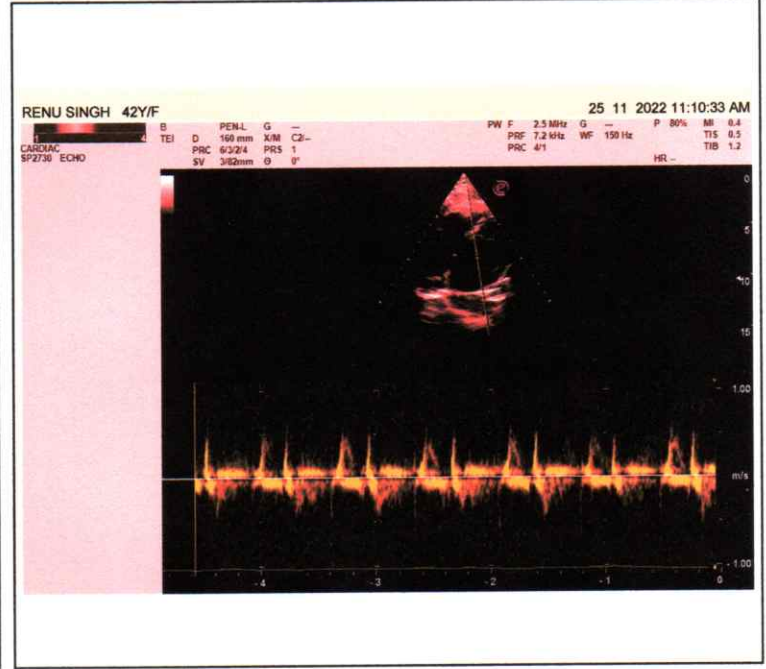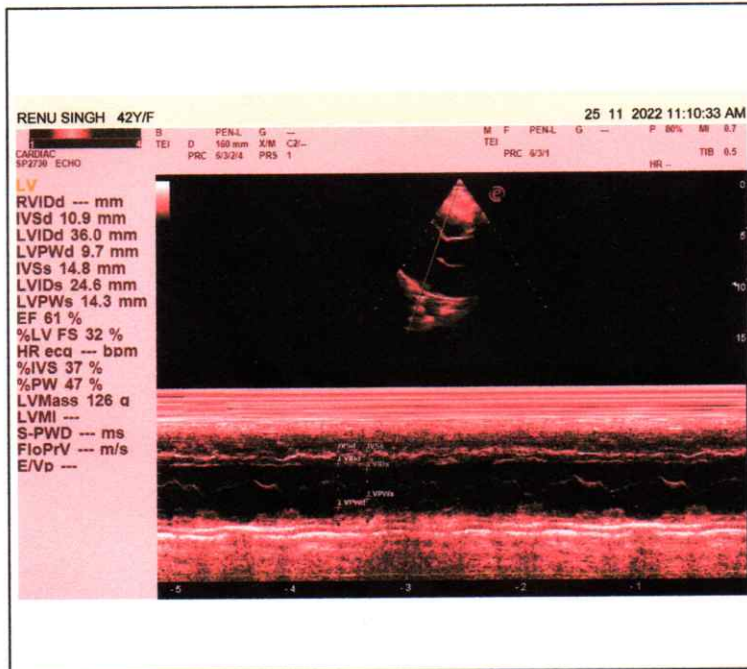
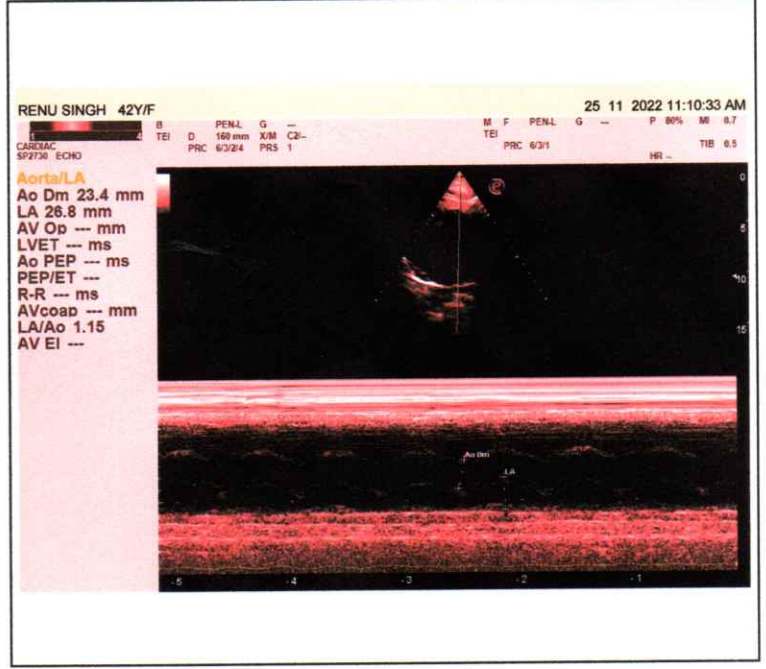

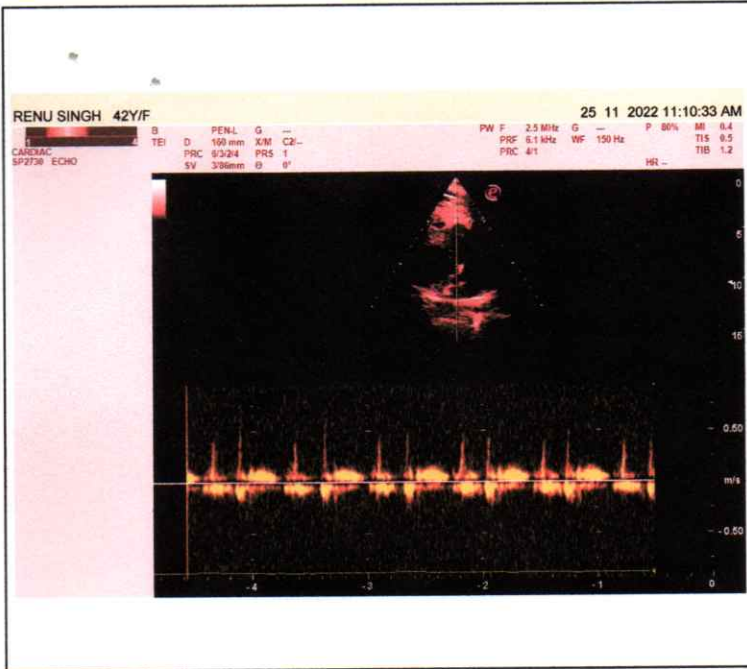Nijraj Mishra
Physician Assistant
(PIIRE)


DR. PALLAVI MISHRA
MBBS, MD (GENERAL MEDICINE)
MCI Reg. No. 52033
Dr. Pallavi Mishra
MBBS, MD (MED) Lucknow
Echocardiography Specialist, MIAE
Non-invasive cardio Women Cardiologist

Address : Kabir Nagar (Near Sanjay Shiksha Niketan), Durgakund, Varanasi

Mobile : 9554572190 / 9453837595 / Recpn. 9389994334

E-mail : dramishra@gmail.com, drpallaviojha@gmail.com, Website: www.piire.org





PANACEA HOSPITAL

A shelter for many hearts A Home for many lives

(An ISO 9001:2008 Certified Organisation)

Lab Attached with CMC Vellore Under EQAS Scheme

NAME: MRS. RENU SINGH

AGE/SEX: 42 YRS / FEMALE

REF BY: DR. ASHUTOSH MISHRA (MD)

DATE: 25/11/2022

ULTRA SOUND FOR ABDOMAN REPORT

Liver: Normal in shape and size (11.0cm) and shows smooth and regular margin.
No diffuse/focal lesion seen.

Gall bladder Contracted.

CBD Visualized part normal in course & caliber.

Pancreas: Normal in size, shape & echogenicity.
Margins are smooth & regular.
No diffuse/ focal lesion seen. Pancreatic tail obscured.

Spleen: Normal in size(8.9 cm) shape & echogenicity.
Margins are smooth & regular. No diffuse / focal lesion seen.
Splenic vessels at hilum is normal.

Kidney: Right kidney: 8.8 X 4.6cm
Left kidney: 8.3 X3.9 cm
Normal cortical echogenicity with well maintained Cortical-medullary differentiation.
Pelvicalyceal system normal.
No calculus/mass lesion seen.
No hydronephrosis/ hydroureter seen.

Address : Kabir Nagar (Near Sanjay Shiksha Niketan), Durgakund, Varanasi

Mobile : 9554572190 / 9453837595 / Recpn. 9389994334

E-mail : dramishra@gmail.com, drpallaviojha@gmail.com, **Website:** www.piire.org



PANACEA HOSPITAL

A shelter for many hearts A Home for many lives

(An ISO 9001:2008 Certified Organisation)

Lab Attached with CMC Vellore Under EQAS Scheme

inary bladder: Normally distended, wall thickness is normal.
No echogenic foci lumen or diverticula seen.
Both VUJ appears normal.
No E.R. calculus / mass lesion seen.

Uterus: Uterus normal in size shape, & echogenicity.
Margins are smooth & regular.
Endometrial thickness within normal limits

Ovary: Right ovary normal in size and shows normal morphology.
Left ovary normal in size and shows normal morphology.

Others: No free fluid in peritoneal cavity.
No free fluid in bilateral pleural cavity.

IMPRESSION:

- NO SIGNIFICANT SONOLOGICAL ABNORMALITY DETECTED.

Please correlate clinically and further investigations.

DR. PALLAVI MISHRA
MBBS, MD(GENERAL MEDICINE)
MCH Reg No: 2033

DR. PALLAVI MISHRA

MBBS MD(MED) Lucknow

Echocardiography specialist, MIAE

Non invasive cardiologist

Women cardiologist

Radiologist

Dr. Tusharika Rai

MBBS MS

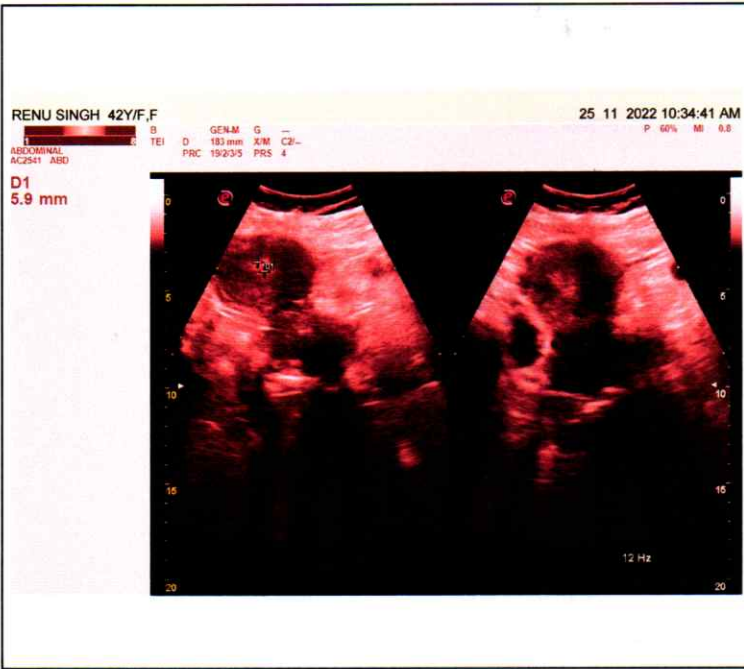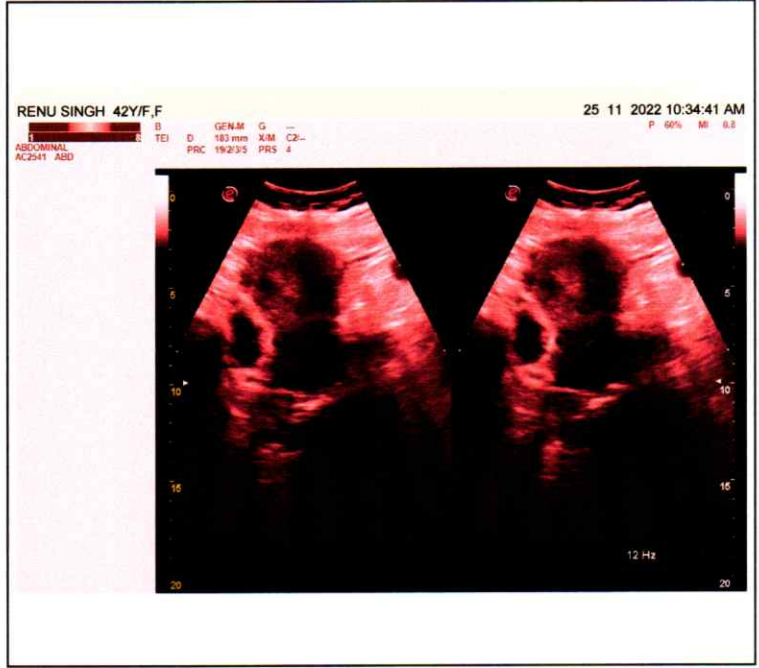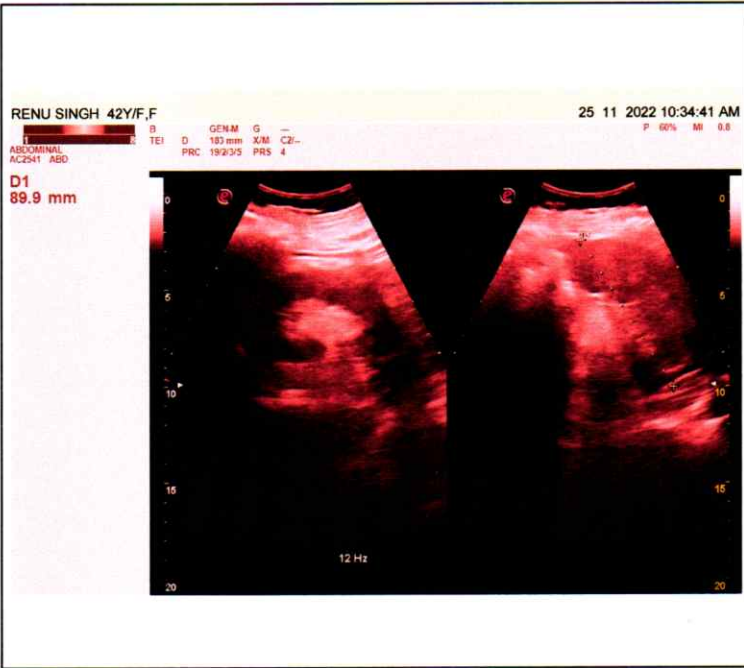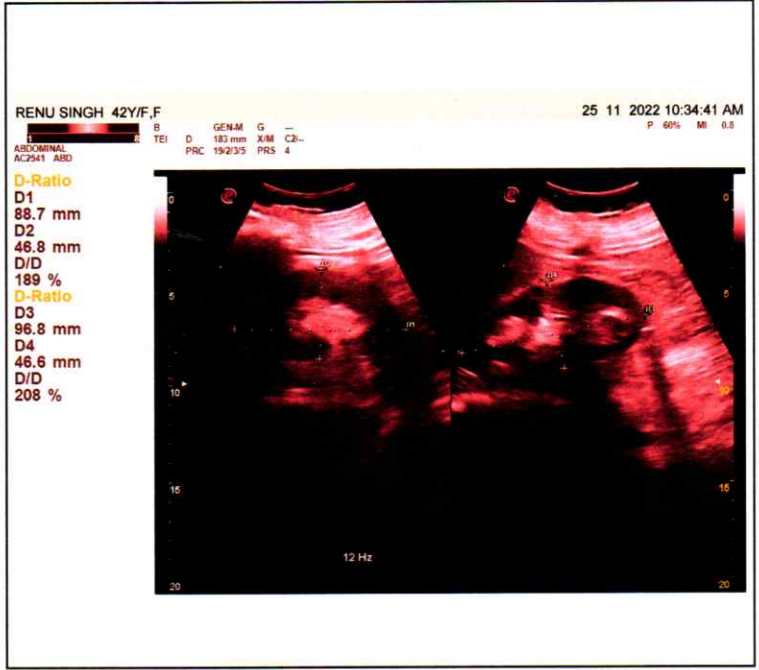
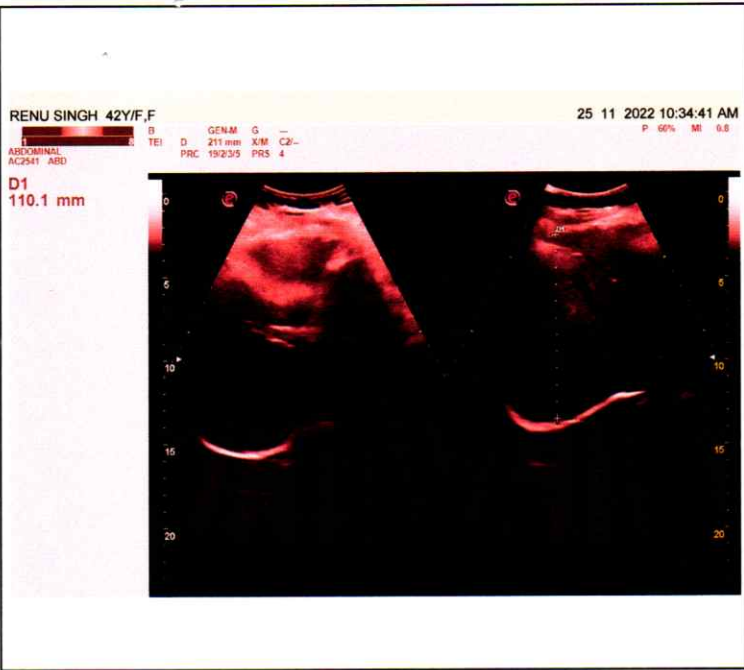Note: (1) This report is not valid for medico-legal purposes.

(2) In case of any discrepancy due typing error, please get it Rectified immediately.

Address : Kabir Nagar (Near Sanjay Shiksha Niketan), Durgakund, Varanasi

Mobile : 9554572190 / 9453837595 / Recpn. 9389994334

E-mail : dramishra@gmail.com, drpallaviojha@gmail.com, Website: www.piire.org





PANACEA HOSPITAL

A shelter for many hearts A Home for many lives

(An ISO 9001:2008 Certified Organisation)

Lab Attached with CMC Vellore Under EQAS Scheme

NAME: MRS. RENU SINGH

AGE/SEX: 42 YRS / FEMALE

REF BY: DR.ASHUTOSH MISHRA(MD)

DATE: 25/11/2022

X-RAY CHEST PA

BOTH LUNG FIELDS AND PLEURAE:

Both lungs show normal bronchovascular pattern.

Right & left hila are normal

No focal mass or calcification is seen

There is no evidence of any fluid in the both the pleural cavities.

Both domes of diaphragms are normal in position.

MEDIASTINUM:

Trachea is central in position.

Cardiac silhouette is of normal size and configuration.

No evidence of pericardial effusion.

No significant lymphadenopathy is seen.

Visualized skeleton is normal.

NO SIGNIFICANT RADIOGRAPHIC ABNORMALITY.

REPORTED BY

DR. ALPANA PATHAK

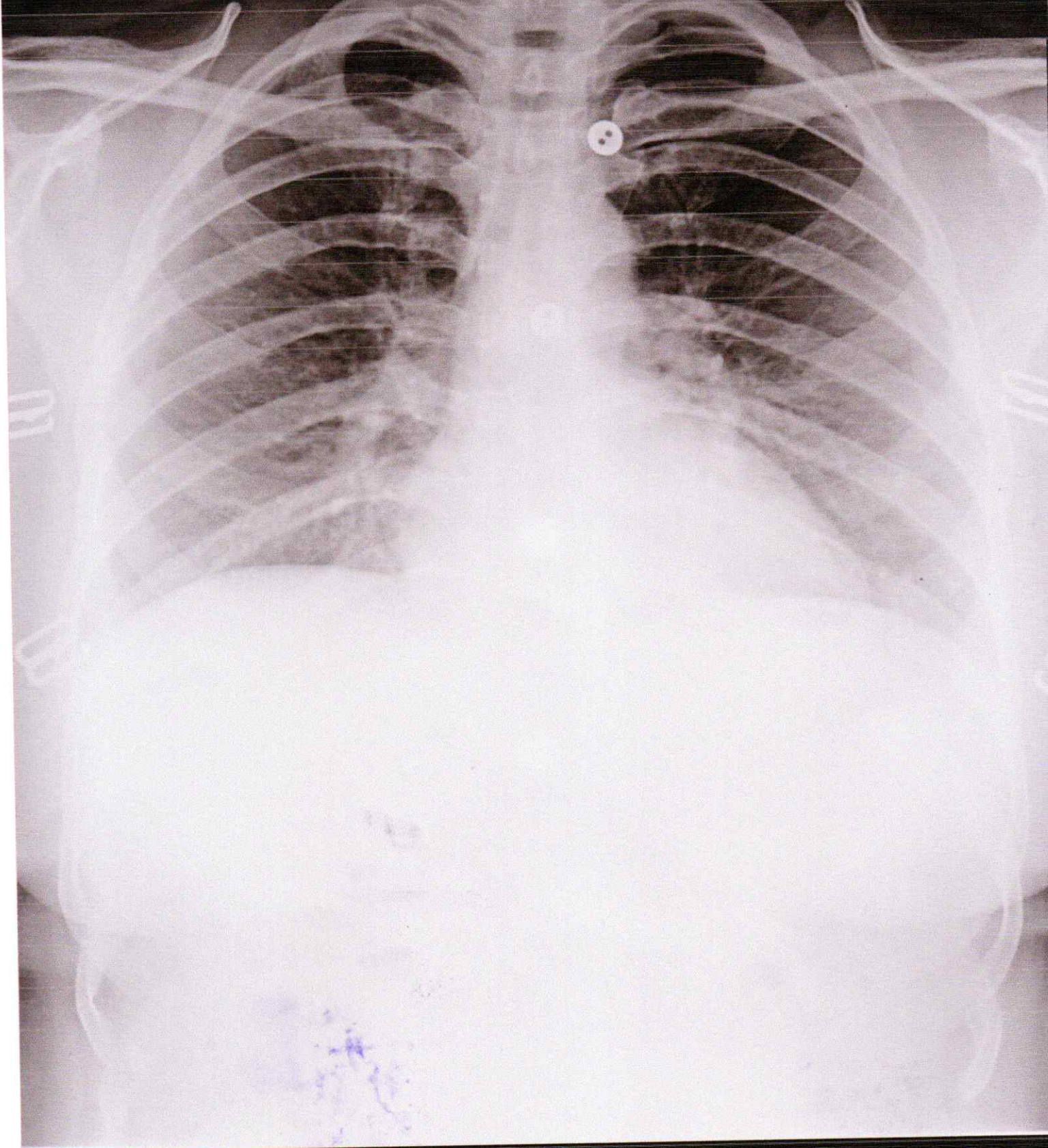
**MBBS (HONS, GOLD MEDALIST) PMCH , PATNA
MD RADIODIAGNOSIS (GOLD MEDALIST) IMS BHU
EX-SR, IMS BHU, VARANASI**

Address : Kabir Nagar (Near Sanjay Shiksha Niketan), Durgakund, Varanasi

Mobile : 9554572190 / 9453837595 / Recpn. 9389994334

E-mail : dramishra@gmail.com, drpallaviojha@gmail.com, Website: www.piire.org

R



RENU SINGH 42Y/F 5214 O CHEST P.A. 25-Nov-22 11:15 AM

PANACEA HOSPITAL, KABIR NAGAR, DURGAKUND, VARANASI