

CERTIFICATE OF MEDICAL FITNESS

This is to certify that I have conducted the clinical examination

of Abhijeet Sontwane on 14/10/23

After reviewing the medical history and on clinical examination it has been found that he/she is

	Tick
<ul style="list-style-type: none"> • Medically Fit 	<input type="checkbox"/>
<ul style="list-style-type: none"> • Fit with restrictions/recommendations <p>Though following restrictions have been revealed, in my opinion, these are not impediments to the job.</p> <p>1. <u>Sugar levels are high</u> } <u>Need to exercise & diet control</u></p> <p>2. <u>lipid profile is high</u> }</p> <p>3. _____</p> <p>However the employee should follow the advice/medication that has been communicated to him/her.</p> <p>Review after _____</p>	<input checked="" type="checkbox"/>
<ul style="list-style-type: none"> • Currently Unfit. <p>Review after _____ recommended</p>	<input type="checkbox"/>
<ul style="list-style-type: none"> • Unfit 	<input type="checkbox"/>

Dr. _____
 Medical Officer *AAJ*
 The Apollo Clinic, (Location)

APOLLO CLINIC
Dr. SUKESH BUDHWANI
 M.D. (PHYSICIAN/ DIABETOLOGIST)
 Mob.: 9422805559 (Pl. SMS Only)
 Reg. No.- 2019010071

This certificate is not meant for medical/legal purposes

Mr. Abhijeet Sonware.

Height :	Weight :	BMI :	Waist Circum :
Temp :	Pulse :	Resp :	B.P :

General Examination / Allergies
History

Clinical Diagnosis & Management Plan

Shu

ENT] HAS

(Handwritten Signature)

Follow up date:

Doctor Signature

EYE EXAMINATION

DATE:-

NAME:- Abhijeet Soudane

MO :- 7249443944

AGE:- 34yrs

CORPORATE:- Bank of Baroda

	Right Eye	Left Eye
Distant vision	6/6	6/6
Near vision	N/6	N/6
Color vision	Normal	Normal
Fundus examination	Normal	Normal
Intraocular pressure	Normal	Normal
Slit lamp exam.	Normal	Normal

Handwritten signature

Impression - Normal Eye Check Up.

Handwritten signature

(Ophthalmology)



The Apollo Clinic
DR. B. D. ALAVAND
MBBS, D.M.O.
Consulting Eye Surgeon
Reg. No.: 36319

NAME : ABHIJEET SONAWANE

AGE : 34 Y/M

DATE : 16/10/2023

ECHOCARDIOGRAPHY REPORT

MITRAL VALVE : has thin leaflets, normal subvalvular apparatus. No MR / MS

AORTIC VALVE : Thin trileaflets, normal gradients across the valve. No AR / AS

PULMONARY VALVE : normal.

TRICUSPID VALVE: normal gradients . Trivial tricuspid regurgitation. RVSP 28 mm Hg, No pulmonary hypertension.

Left Ventricle : LV is normal in size with normal wall thickness. No regional wall motion abnormality. No LV diastolic dysfunction. Good LV systolic function. LVEF 65%.

Left Atrium : is normal and free of clots.

RA/RV : are normal

IAS/IVS : intact.

No clot/veg/ pericardial effusion.

MEASUREMENTS

AORTA	:24MM
LEFT ATRIUM	:25 MM
IVSd	:09 MM
PWd	:09 MM
LVIDd	:40 MM
LVIDs	: 24 MM
LVEF	: 65 %

IMPRESSION:

NORMAL CARDIAC VALVES

NORMAL CARDIAC CHAMBERS

GOOD LV SYSTOLIC FUNCTION, LVEF 65%



DR.PRAMOD NARKHEDE

DNB(Medicine), DNB(Cardiology)

Consultant Interventional Cardiologist

Apollo clinic, Viman Nagar

Apollo Health and Lifestyle Limited

ICIN - U85110TG2005PLC115819

Regd. Office: 1-10-60/62, Ashoka Raghupathi Chambers, 5th Floor, Begumpet, Hyderabad, Telangana - 500 016.

Ph No: 040-4904 7777, Fax No: 4904 7744 | Email ID: enquiry@apollohl.com | www.apollohl.com

APOLLO CLINICS NETWORK MAHARASHTRA

Pune (Aundh) | Kharadi | Nigdi Pradhikaran | Viman Nagar | Wanowrie

Online appointments: www.apolloclinic.com

TO BOOK AN APPOINTMENT

 **1860 500 7788**

231370
34 Years

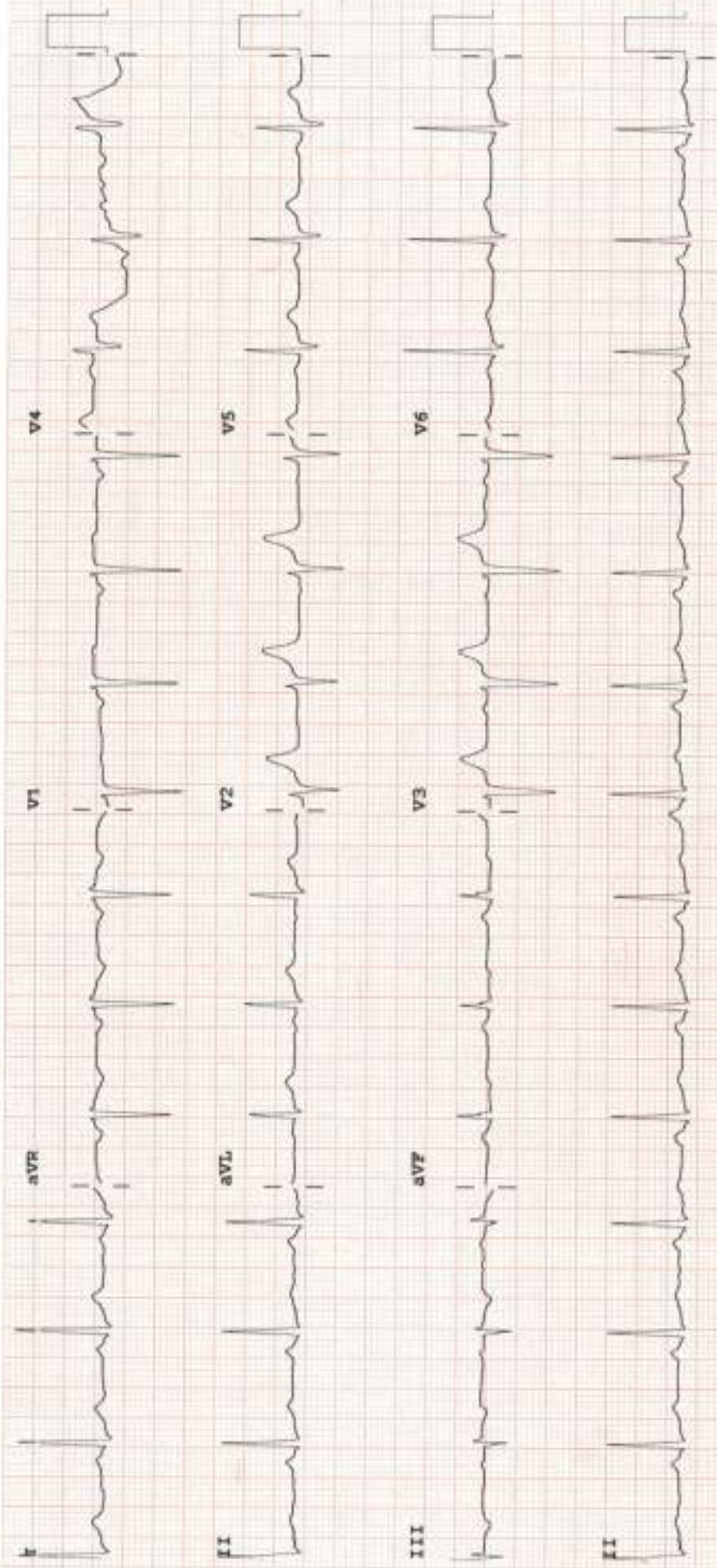
MR ABHIJEET SONAWANE (VN)
Male

14-Oct-23 9:04:46 AM

Rate 83 Sinus rhythm.....normal P axis, V-rate 50- 99
PR 154
QRSD 98
QT 360
QTc 423

--AXIS--
P 64
QRS 21
T 4
12 Lead: Standard Placement

✓ - NORMAL ECG *AKB*
Unconfirmed Diagnosis



Device: Speed: 25 mm/sec Limb: 10 mm/mV Chest: 10.0 mm/mV

F 50- 0.50- 40 Hz W

PH100B CL? P?

PHILIPS

REORDER NUMBER

Patient Name : Mr. ABHIJEET SONWANE Age : 34 Y M
UHID : CVIM.0000231370 OP Visit No : CVIMOPV567825
Reported on : 14-10-2023 09:39 Printed on : 17-10-2023 08:11
Adm/Consult Doctor : Ref Doctor : SELF

DEPARTMENT OF RADIOLOGY

X-RAY CHEST PA

X-RAY CHEST PA

Trachea appears normal.

Both the lung fields are clear.

Cardiac shadows appear apparently normal.

Both domes of diaphragm appear normal.

Both costophrenic angles are clear.

Bony thoracic cage shows no deformity. Visualised bones appear normal.

Soft tissues appear normal.

Impression: Essentially Normal Study.

Printed on:14-10-2023 09:39

---End of the Report---

Preeti

Dr. PREETI P KATHE
DMRE, MD, DNB
Radiology

Patient Name	: Mr. ABHIJEET SONWANE	Age	: 34 Y M
UHID	: CVIM.0000231370	OP Visit No	: CVIMOPV567825
Reported on	: 14-10-2023 09:57	Printed on	: 17-10-2023 08:11
Adm/Consult Doctor	:	Ref Doctor	: SELF

DEPARTMENT OF RADIOLOGY

ULTRASOUND - WHOLE ABDOMEN

Liver appears normal in size and bright in echotexture. No focal lesion is seen. PV and CBD normal. No dilatation of the intrahepatic biliary radicals.

Gall bladder is well distended. No evidence of calculus. Wall thickness appears normal. No evidence of periGB collection. No evidence of focal lesion is seen.

Spleen appears normal. No focal lesion seen. Splenic vein appears normal.

Pancreas appears normal in echopattern. No focal/mass lesion/calcification. No evidence of peripancreatic free fluid or collection. Pancreatic duct appears normal.

Both the kidneys appear normal in size, shape and echopattern. Cortical thickness and CM differentiation are maintained. No calculus / hydronephrosis seen on either side.

Urinary Bladder is well distended and appears normal. No evidence of any wall thickening or abnormality. No evidence of any intrinsic or extrinsic bladder abnormality detected.

Prostate is normal in size and echo texture. No evidence of necrosis/calcification seen.

Bowel loops and Retroperitoneum appear normal. Aorta and IVC appear normal. No abnormal lymphadenopathy noted.

IMPRESSION:-

Grade II fatty liver

(The sonography findings should always be considered in correlation with the clinical and other investigation finding where applicable.) It is only a professional opinion, Not valid for medico legal purpose.

Patient Name : Mr. ABHIJEET SONWANE
UHID : CVIM.0000231370
Reported on : 14-10-2023 09:57
Adm/Consult Doctor :

Age : 34 Y M
OP Visit No : CVIMOPV567825
Printed on : 17-10-2023 08:11
Ref Doctor : SELF

Printed on:14-10-2023 09:57

---End of the Report---

Preeti

Dr. PREETI P KATHE
DMRE, MD, DNB
Radiology

Patient Name : Mr.ABHJEET SONWANE	Collected : 14/Oct/2023 08:40AM
Age/Gender : 34 Y 3 M 27 D/M	Received : 14/Oct/2023 12:51PM
UHID/MR No : CVIM.0000231370	Reported : 14/Oct/2023 03:56PM
Visit ID : CVIMOPV567825	Status : Final Report
Ref Doctor : Dr.SELF	Sponsor Name : ARCOFEMI HEALTHCARE LIMITED
Emp/Auth/TPA ID : 24765	

DEPARTMENT OF HAEMATOLOGY

ARCOFEMI - MEDIWHEEL - FULL BODY ANNUAL CHECKUP MALE - 2D ECHO - PAN INDIA - FY2324

Test Name	Result	Unit	Bio. Ref. Range	Method
-----------	--------	------	-----------------	--------

BLOOD GROUP ABO AND RH FACTOR , WHOLE BLOOD EDTA

BLOOD GROUP TYPE	O			Microplate Hemagglutination
Rh TYPE	Positive			Microplate Hemagglutination



Patient Name : Mr.ABHJEET SONWANE	Collected : 14/Oct/2023 08:40AM
Age/Gender : 34 Y 3 M 27 D/M	Received : 14/Oct/2023 01:08PM
UHID/MR No : CVIM.0000231370	Reported : 14/Oct/2023 04:24PM
Visit ID : CVIMOPV567825	Status : Final Report
Ref Doctor : Dr.SELF	Sponsor Name : ARCOFEMI HEALTHCARE LIMITED
Emp/Auth/TPA ID : 24765	

DEPARTMENT OF BIOCHEMISTRY

ARCOFEMI - MEDIWHEEL - FULL BODY ANNUAL CHECKUP MALE - 2D ECHO - PAN INDIA - FY2324

Test Name	Result	Unit	Bio. Ref. Range	Method
-----------	--------	------	-----------------	--------

RENAL PROFILE/KIDNEY FUNCTION TEST (RFT/KFT) , SERUM				
CREATININE	0.78	mg/dL	0.72 - 1.18	Modified Jaffe, Kinetic
UREA	19.08	mg/dL	17-43	GLDH, Kinetic Assay
BLOOD UREA NITROGEN	8.9	mg/dL	8.0 - 23.0	Calculated
URIC ACID	4.71	mg/dL	3.5-7.2	Uricase PAP
CALCIUM	9.51	mg/dL	8.8-10.6	Arsenazo III
PHOSPHORUS, INORGANIC	2.77	mg/dL	2.5-4.5	Phosphomolybdate Complex
SODIUM	137.66	mmol/L	136-146	ISE (Indirect)
POTASSIUM	4.8	mmol/L	3.5-5.1	ISE (Indirect)
CHLORIDE	99.04	mmol/L	101-109	ISE (Indirect)



Patient Name : Mr.ABHJEET SONWANE	Collected : 14/Oct/2023 08:40AM
Age/Gender : 34 Y 3 M 27 D/M	Received : 14/Oct/2023 01:08PM
UHID/MR No : CVIM.0000231370	Reported : 14/Oct/2023 04:24PM
Visit ID : CVIMOPV567825	Status : Final Report
Ref Doctor : Dr.SELF	Sponsor Name : ARCOFEMI HEALTHCARE LIMITED
Emp/Auth/TPA ID : 24765	

DEPARTMENT OF BIOCHEMISTRY

ARCOFEMI - MEDIWHEEL - FULL BODY ANNUAL CHECKUP MALE - 2D ECHO - PAN INDIA - FY2324

Test Name	Result	Unit	Bio. Ref. Range	Method
GAMMA GLUTAMYL TRANSPEPTIDASE (GGT) , SERUM	62.65	U/L	<55	IFCC



Patient Name : Mr.ABHIJEET SONWANE	Collected : 14/Oct/2023 08:40AM
Age/Gender : 34 Y 3 M 27 D/M	Received : 14/Oct/2023 01:19PM
UHID/MR No : CVIM.0000231370	Reported : 14/Oct/2023 01:59PM
Visit ID : CVIMOPV567825	Status : Final Report
Ref Doctor : Dr.SELF	Sponsor Name : ARCOFEMI HEALTHCARE LIMITED
Emp/Auln/TPA ID : 24765	

DEPARTMENT OF CLINICAL PATHOLOGY

ARCOFEMI - MEDIWHEEL - FULL BODY ANNUAL CHECKUP MALE - 2D ECHO - PAN INDIA - FY2324

Test Name	Result	Unit	Bio. Ref. Range	Method
URINE GLUCOSE(POST PRANDIAL)	NEGATIVE		NEGATIVE	Dipstick
URINE GLUCOSE(FASTING)	NEGATIVE		NEGATIVE	Dipstick

*** End Of Report ***



Dr Sneha Shah
MBBS, MD (Pathology)
Consultant Pathologist



DR.Sanjay Ingle
M.B.B.S,M.D(Pathology)
Consultant Pathologist



(3)

Name : Mr. ABHIJEET SONWANE

Age: 34 Y

UHID:CVIM.0000231370

Sex: M



Address : pune

OP Number:CVIMOPV567825

Plan : ARCOFEMI MEDIWHEEL MALE AHC CREDIT PAN
INDIA OP AGREEMENT

Bill No :CVIM-OCR-60132

Date : 14.10.2023 08:21

Sno	Service Type/ServiceName	Department
1	ARCOFEMI - MEDIWHEEL - FULL BODY ANNUAL CHECKUP MALE - 2D ECHO - PAN INDIA - FY2324	
1	URINE GLUCOSE(FASTING)	
2	GAMMA GLUTAMYL TRANSFERASE (GGT)	
3	D ECHO	
4	LIVER FUNCTION TEST (LFT)	
5	X-RAY CHEST PA	
6	GLUCOSE, FASTING	
7	HEMOGRAM - PERIPHERAL SMEAR	
8	ENT CONSULTATION	
9	FITNESS BY GENERAL PHYSICIAN	
10	HFA SPEECH AUDIOMETRY	
11	DIET CONSULTATION	
12	COMPLETE URINE EXAMINATION	
13	URINE GLUCOSE(POST PRANDIAL) - 2 hrs -	
14	PERIPHERAL SMEAR	
15	ECG	
16	BLOOD GROUP ABO AND RH FACTOR	
17	LIPID PROFILE	
18	BODY MASS INDEX (BMI)	
19	OPHTHAL BY GENERAL PHYSICIAN	
20	RENAL PROFILE/RENAL FUNCTION TEST (RFT/KFT)	
21	ULTRASOUND - WHOLE ABDOMEN	
22	DENTAL CONSULTATION	
23	GLUCOSE, POST PRANDIAL (PP), 2 HOURS (POST MEAL) - 2 hrs -	

NO SAMPLE GIVEN

TO,
apollo clinic
viman nagar

dear sir/ madam

I Mr. Abhijeet Sonwane working at company name
ARCOREMI have not given the AUD sample do not
wish to given it

I AGREE.....

UHID =

SIGN-