

Health Check up Booking Request(bobS6844),Package Code(PKG1000243),Beneficiary Code(79454)

1 message

Mediwheel <santosh@policywheel.com>

20 January 2022 at 12:10

To: "vidhidiagnostics@gmail.com" <vidhidiagnostics@gmail.com>

Cc: Mediwheel CC <customercare@mediwheel.in>, Mediwheel CC <mediwheelwellness@gmail.com>



Mediwheel
...Your wellness partner



011-41195959

Email:wellness@mediwheel.in

Dear Vidhi Diagnostics,
City : Ahmedabad . Location : .New Wadaj,

We have received the following request for Health Check up from

Name : PATEL LAXMIBEN JAYANTILAL
Age : 46
Gender : Female
Member Relations : Spouse
Package Name : Metro Full Body Health Checkup Female Above 40
Package Code : PKG1000243
User Location : Gujarat,HIMMATNAGAR,383001
Contact Details : 9978813451
Booking Date : 20-01-2022
Appointment Date : 25-01-2022

Member Information			
Booked Member Name	Age	Gender	Cost(In INR)
PATEL LAXMIBEN JAYANTILAL	46	Female	Cashless
Total amount to be paid		Cashless	

Please login to your account to confirm the same. Also you mail us for confirmation

Package Name : Metro Full Body Health Checkup Female Above 40 - Includes (41) Tests

Tests included in this Package

Ecg, TSH, X-ray Chest, Stress Test (tmt)/ 2d Echo, Gynec Consultation, Blood Sugar Postprandial, Dental Consultation, A:g Ratio, Blood Group, Total Cholesterol, Triglycerides, Pap Smear, Fasting Blood Sugar, Ultrasound Whole Abdomen , Glycosylated Haemoglobin (hba1c), Mammography, Hdl, Vldl, Urine Analysis, LDL, Total Protine, General Consultation, HDL/ LDL ratio, GGT(Gamma-glutamyl Transferase), Eye Check-up consultation, ALP (ALKALINE PHOSPHATASE), Uric Acid, AST/ALT Ratio, Serum Protein, CBC with ESR, Stool Analysis, Urine Sugar Fasting, Urine Sugar PP, T3, T4, Cholesterol Total / HDL Ratio, BUN, BUN/Creatinine Ratio, Bilirubin Total & Direct and Indirect, Albumin, Globulin



ભારત સરકાર

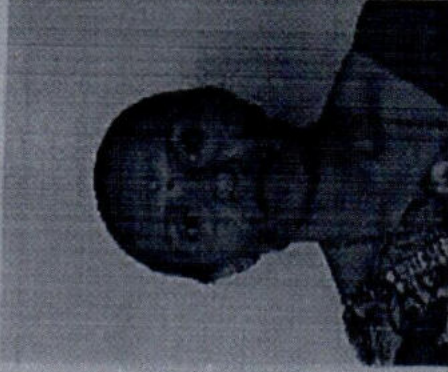Government of India

લક્ષ્મીબેન જયંતિભાઈ પટેલ

Laxmiben Jayantibhai Patel

જન્મ તારીખ / DOB : 01/06/1976

સ્ત્રી / Female



3358 2723 8521

આધાર - સામાન્ય માણસનો અધિકાર

Dr. Dinesh S. Modh

M.D., D.M.R.E. (Radiodiagnosis)
Consultant Radiologist & Sonologist
Ex. Junior Lecturer, B.J. Medical College, Civil Hospital, A'bad.
Panel Doctor of L.I.C.



25/1/22

Laxmiben / 45

mt/a of Many Accidents 1970
Dm, TB thymus & major m

TA
Pnk, Bpnt

Aav

Tr Telmiside (40) - 100 - 1 month
& then 1/2

Bp: 162/90 mmHg

Ri
Cw

Dr. Avinash Bhaskar
M.D. D-Cardio
G-33946

ISO 9001:2015 Certified Diagnostics Center
Vidhi Imaging Center

L-86, Swatantra Senani Nagar, Opp. Akhbarnagar Petrol Pump, Nr. Akhbarnagar Circle, Nava-Vadaj, Ahmedabad - 380 013.
Phone : 079-2762 1406, Mobile : 98799 29406, 98250 09406, E-mail : vidhidiagnostics@gmail.com, Website : www.vidhidiagnostics.com
Time : Mon. to Sat. 9.00 am to 2.00 pm, 5.00 pm to 9.00 pm, Sunday 9.00 am to 12.00 Noon

EMPANNELLED WITH HEALTH INDIA TPA & APOLLO HEALTH CHECK NETWORK

FACILITIES : Live 3D-4D Sonography | Colour Doppler | Echo Cardiography | Interventional Radiology | Fetal Medicine | Digital X-Ray
Digital Mammography | Digital OPG / TMJ | ECG / TMT / PFT / EEG / EMG | Pathology Laboratory | Health Check Up Plans | Pre Employment Check Up

25-01-2022 10:39:08

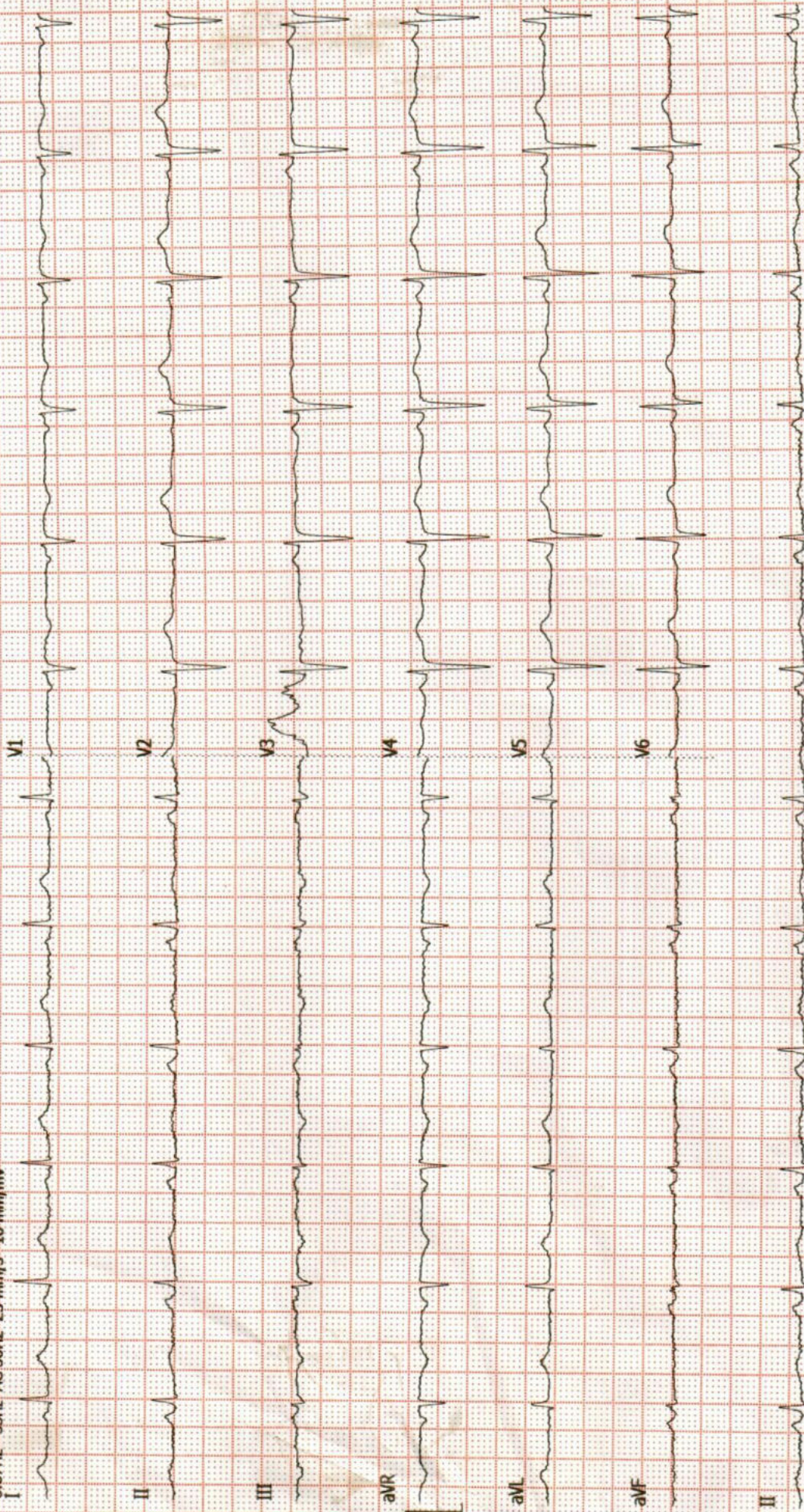
<< Analysis Result >>

HR : 71 bpm
 PR : 154 ms
 QRS : 86 ms
 QT/QTc : 420/456 ms
 P/QRS/T : 65/22/18 deg.
 RV5/SV1 : 0.420/-0.519 mv

ID: 3474
 Name: laxmiben, patel
 Age: 46yrs
 Sex: Female
 Hospital:

Department: _____
 Need to be confirmed by doctor. Doctor Name: _____

0.67Hz - 35Hz AC 50Hz 25 mm/s 10 mm/mv



Dr. Dinesh S. Modh

M.D., D.M.R.E. (Radiodiagnosis)

Consultant Radiologist & Sonologist

Ex. Junior Lecturer, B.J. Medical College, Civil Hospital, A'bad.

Panel Doctor of L.I.C.



Patient's name : LAXMIBEN JAYANTILAL PATEL

Reg. ID : R-10485-21

Referred by : Dr. MEDIWHEEL

Age/Sex : 46 Years/Female

Accession : 6966

Date : 25/01/2022

Report of ECG

Conclusion

- Normal sinus rhythm.
- HR - 70/per minute.
- Normal PR interval.
- Normal QRS interval.
- Normal QT interval.

Dr. Avinash Bhaskar
DR.AVINASH BHASKAR

ISO 9001:2015 Certified Diagnostics Center

Vidhi Imaging Center

L-86, Swatantra Senani Nagar, Opp. Akhbarnagar Petrol Pump, Nr. Akhbarnagar Circle, Nava-Vadaj, Ahmedabad - 380 013.

Phone : 079-2762 1406, Mobile : 98799 29406, 98250 09406, E-mail : vidhidiagnostics@gmail.com, Website : www.vidhidiagnostics.com

Time : Mon. to Sat. 9.00 am to 2.00 pm, 5.00 pm to 9.00 pm, Sunday 9.00 am to 12.00 Noon

EMPANNELLED WITH HEALTH INDIA TPA & APOLLO HEALTH CHECK NETWORK

FACILITIES : Live 3D-4D Sonography | Colour Doppler | Echo Cardiography | Interventional Radiology | Fetal Medicine | Digital X-Ray
Digital Mammography | Digital OPG / TMJ | ECG / TMT / PFT / EEG / EMG | Pathology Laboratory | Health Check Up Plans | Pre Employment Check Up

Dr. Dinesh S. Modh

M.D., D.M.R.E. (Radiodiagnosis)
Consultant Radiologist & Sonologist
Ex. Junior Lecturer, B.J. Medical College, Civil Hospital, A'bad.
Panel Doctor of L.I.C.



Patient's name : LAXMIBEN JAYANTILAL PATEL
Reg. ID : R-10485-21
Referred by : Dr. MEDIWHEEL

Age/Sex : 46 Years/Female
Accession : 6966
Date : 25/01/2022

2D- ECHO REPORT

FINAL CONCLUSION:

LV IS NORMAL SIZE. GOOD LV SYSTOLIC FUNCTION NO RWMA.
LVEF - 60%. NO CONCENTRIC LVH.
NORMAL LV COMPLIANCE.
LA IS NORMAL SIZE. NO LA CLOT.
RV IS NORMAL SIZE. GOOD RV SYSTOLIC FUNCTION.
RA IS NORMAL SIZE.
MITRAL VALVE IS NORMAL. NO MS. MILD MR (10%). NO MVP.
AORTIC VALVE IS NORMAL. NO AS. NO AR.
TRICUSPID VALVE IS NORMAL. MILD TR. RVSP-24 mmHg. NO PAH.
NO CLOT, NO VEGETATION, NO PERICARDIAL EFFUSION.

DIMENSIONS:

AORTA	2.6 C.M
LEFT ATRIUM	2.7 C.M
LVDD	4.2 C.M.
IVSD	1.0 C.M
PWD	1.0 C.M
LVDS	2.7 C.M.

COLOUR DOPPLER FINDING:

STRUCTURE	VELOCITY m/sec
	Max
PULMONARY VALVE	0.8
MITRAL VALVE	E : 0.8 A: 0.5
AORTIC VALVE	1.2

DR AVINASH BHASKAR
Dr. Avinash Bhaskar
MD - D-Cardio
G-43946

ISO 9001:2015 Certified Diagnostics Center

Vidhi Imaging Center

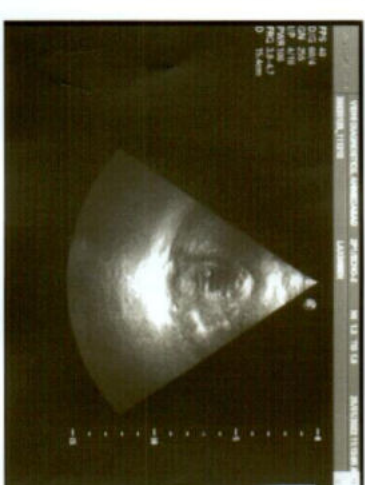
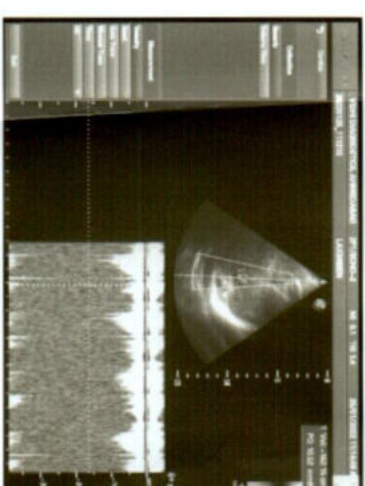
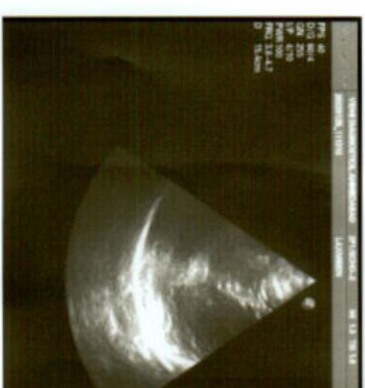
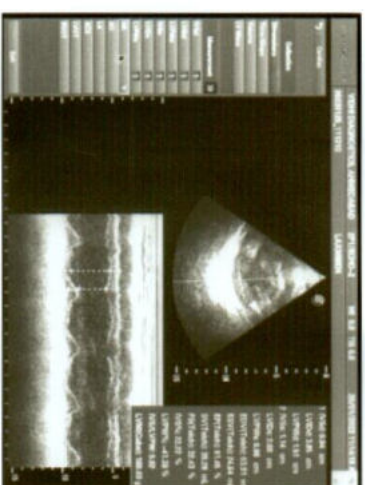
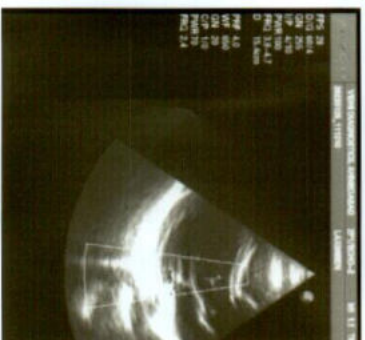
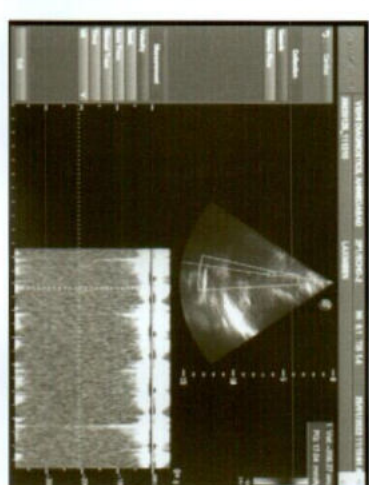
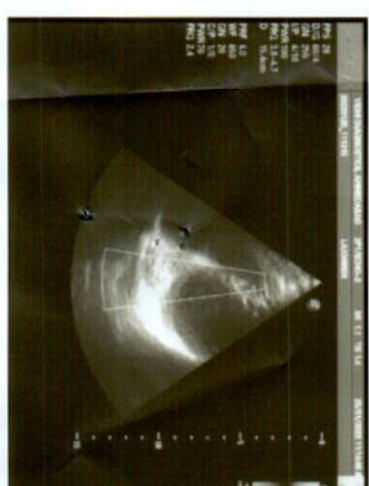

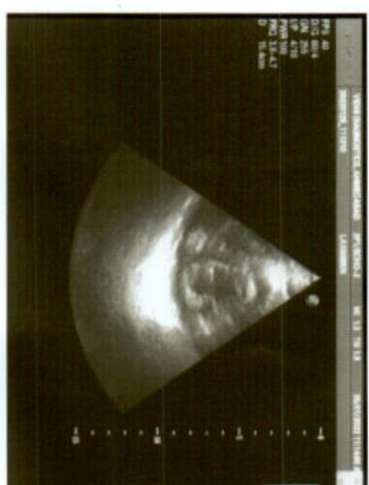
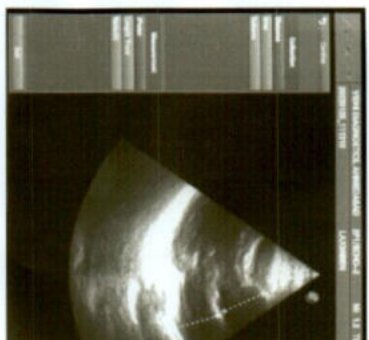
L-86, Swatantra Senani Nagar, Opp. Akhbarnagar Petrol Pump, Nr. Akhbarnagar Circle, Nava-Vadaj, Ahmedabad - 380 013.

Phone : 079-2762 1406, Mobile : 98799 29406, 98250 09406, E-mail : vidhidiagnostics@gmail.com, Website : www.vidhidiagnostics.com

Time : Mon. to Sat. 9.00 am to 2.00 pm, 5.00 pm to 9.00 pm, Sunday 9.00 am to 12.00 Noon

EMPANNELLED WITH HEALTH INDIA TPA & APOLLO HEALTH CHECK NETWORK

FACILITIES : Live 3D-4D Sonography | Colour Doppler | Echo Cardiography | Interventional Radiology | Fetal Medicine | Digital X-Ray
Digital Mammography | Digital OPG / TMJ | ECG / TMT / PFT / EEG / EMG | Pathology Laboratory | Health Check Up Plans | Pre Employment Check Up



Dr. Dinesh S. Modh

M.D., D.M.R.E. (Radiodiagnosis)

Consultant Radiologist & Sonologist

Ex. Junior Lecturer, B.J. Medical College, Civil Hospital, A'bad.

Panel Doctor of L.I.C.



Patient's name : LAXMIBEN JAYANTILAL PATEL

Reg. ID : R-10485-21

Referred by : Dr. MEDIWHEEL

Age/Sex : 46 Years/Female

Accession : 6966

Date : 25/01/2022

USG ABDOMEN

LIVER: - Liver appears normal in size & show normal echotexture. No evidence of diffuse or focal lesion is seen. Intrahepatic biliary radicals appear normal. Portal vein and CBD appear normal. No e/o calculus is seen in bile duct.

GALL BLADDER: - Gall bladder is distended & appears normal. No evidence of calculus or cholecystitis is seen. No evidence of pericholecystic fluid is seen.

SPLEEN: - Spleen appears normal in size & shows normal echotexture. No evidence of diffuse or focal lesion is seen.

PANCREAS: - Pancreas appears normal size and echopattern. No e/o diffuse or focal lesion is seen. Main pancreatic duct appears normal.

KIDNEY: - Both Kidneys appear normal in size & echotexture.

No e/o calculus or hydronephrosis or hydroureter is seen in either side.

Cortico-medullary differentiation is maintained on either side.

Both suprarenal regions appear normal.

RIF & BOWEL LOOPS (By high frequency probe): - Normal.

No evidence of pre & para aortic lymphadenopathy is seen.

No evidence of free fluid is seen in abdomen.

No evidence of dilated or thickened bowel loops is seen.

Urinary bladder: - appears normal. No e/o calculus or mass lesion is seen in bladder.

Uterus appears normal in size and echopattern.

No evidence of diffuse or focal lesion is seen.

Cervical region appears normal.

Endometrial thickness is 6.4mm.

Both ovaries and adnexal regions appear normal.

No e/o free fluid is seen in pouch of Douglas.

Thanks for reference.

DR DINESH S. MODH

M.D. DMRE(RADIODIAGNOSIS)



ISO 9001:2015 Certified Diagnostics Center

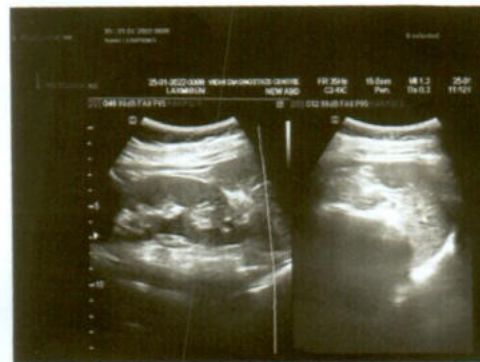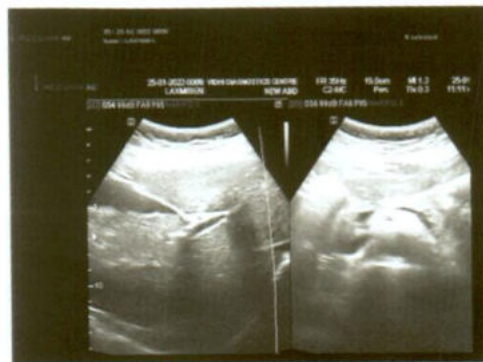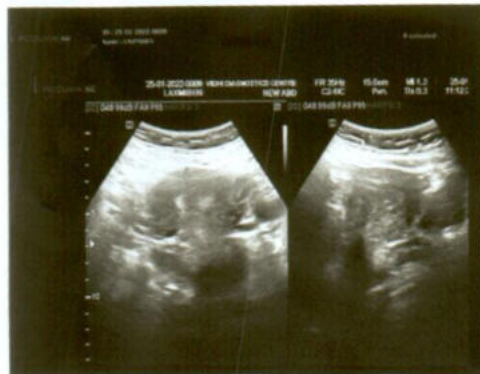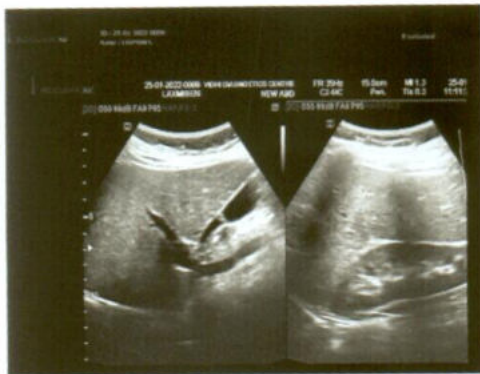Vidhi Imaging Center

L-86, Swatantra Senani Nagar, Opp. Akhbaragar Petrol Pump, Nr. Akhbaragar Circle, Nava-Vadaj, Ahmedabad - 380 013.

Phone : 079-2762 1406, Mobile : 98799 29406, 98250 09406, E-mail : vidhidiagnostics@gmail.com, Website : www.vidhidiagnostics.com

Time : Mon. to Sat. 9.00 am to 2.00 pm, 5.00 pm to 9.00 pm, Sunday 9.00 am to 12.00 Noon

FACILITIES : Live 3D-4D Sonography | Colour Doppler | Echo Cardiography | Interventional Radiology | Fetal Medicine | Digital X-Ray
Digital Mammography | Digital OPG / TMJ | ECG / TMT / PFT / EEG / EMG | Pathology Laboratory | Health Check Up Plans | Pre Employment Check Up



Dr. Dinesh S. Modh

M.D., D.M.R.E. (Radiodiagnosis)
Consultant Radiologist & Sonologist
Ex. Junior Lecturer, B.J. Medical College, Civil Hospital, A'bad.
Panel Doctor of L.I.C.



Patient's name : LAXMIBEN JAYANTILAL PATEL
Reg. ID : R-10485-21
Referred by : Dr. MEDIWHEEL

Age/Sex : 46 Years/Female
Accession : 6966
Date : 25/01/2022

DIGITAL MAMMOGRAPHY

Digital mammography was done on Siemens mammomat-3000.

Reason for exam: - Screening.

Bilateral digital cranio-caudal and medio-lateral oblique views were taken.
The breast tissue is homogeneously dense with fibro-fatty tissue on both sides.
No masses, no architectural distortion, no suspicious calcifications, no asymmetries or other abnormalities are seen.
No e/o radio-opaque or radiolucent mass lesion is seen.
No e/o skin thickening is seen.
Nipple and sub-areolar tissue appear normal.
Axillary tail appears normal.

USG:-Normal.


Assessment:-Negative (BI-RADS category-1)

BI-RADS category

- 0- incomplete
- 1- Negative
- 2- Benign
- 3- Probably benign
- 4- Suspicious abnormality.
- 5- Highly suggestive of malignancy
- 6- Known biopsy-proven malignancy.

The false negative mammography is approximately 10%. Management of palpable abnormality must be based upon clinical grounds.

Thanks for reference.


DR DINESH S. MODH
M.D. DMRE(RADIODIAGNOSIS)

ISO 9001:2015 Certified Diagnostics Center

Vidhi Imaging Center

L-86, Swatantra Senani Nagar, Opp. Akhbarnagar Petrol Pump, Nr. Akhbarnagar Circle, Nava-Vadaj, Ahmedabad - 380 013.

Phone : 079-2762 1406, Mobile : 98799 29406, 98250 09406, E-mail : vidhidiagnostics@gmail.com, Website : www.vidhidiagnostics.com

Time : Mon. to Sat. 9.00 am to 2.00 pm, 5.00 pm to 9.00 pm, Sunday 9.00 am to 12.00 Noon

FACILITIES : Live 3D-4D Sonography | Colour Doppler | Echo Cardiography | Interventional Radiology | Fetal Medicine | Digital X-Ray
Digital Mammography | Digital OPG / TMJ | ECG / TMT / PFT / EEG / EMG | Pathology Laboratory | Health Check Up Plans | Pre Employment Check Up

Dr. Dinesh S. Modh

M.D., D.M.R.E. (Radiodiagnosis)

Consultant Radiologist & Sonologist

Ex. Junior Lecturer, B.J. Medical College, Civil Hospital, A'bad.

Panel Doctor of L.I.C.



Patient's name : LAXMIBEN JAYANTILAL PATEL

Reg. ID : R-10485-21

Referred by : Dr. MEDIWHEEL

Age/Sex : 46 Years/Female

Accession : 6966

Date : 25/01/2022

X-RAY CHEST (PA VIEW)

Both lung fields appear normal.
No e/o consolidation or cavitations is seen.
Both costo-phrenic angles appear clear.
Cardiac size is with in normal limits.
Both domes of diaphragm appear normal.
Bony thoracic cage appears normal.

Thanks for reference.

DR DINESH S. MODH
M.D. DMRE(RADIO DIAGNOSIS)



ISO 9001:2015 Certified Diagnostics Center

Vidhi Imaging Center

L-86, Swatantra Senani Nagar, Opp. Akhbarnagar Petrol Pump, Nr. Akhbarnagar Circle, Nava-Vadaj, Ahmedabad - 380 013.

Phone : 079-2762 1406, Mobile : 98799 29406, 98250 09406, E-mail : vidhidiagnostics@gmail.com, Website : www.vidhidiagnostics.com

Time : Mon. to Sat. 9.00 am to 2.00 pm, 5.00 pm to 9.00 pm, Sunday 9.00 am to 12.00 Noon

FACILITIES : Live 3D-4D Sonography | Colour Doppler | Echo Cardiography | Interventional Radiology | Fetal Medicine | Digital X-Ray
Digital Mammography | Digital OPG / TMJ | ECG / TMT / PFT / EEG / EMG | Pathology Laboratory | Health Check Up Plans | Pre Employment Check Up



Pathology Department

Patient's name : LAXMIBEN J. PATEL
Age/Sex : 46 Years/Female
Referred by : -
Collection Time : 10:00

Reg. ID : P-7367-21
Accession : 6969
Order Dt/time : 25/01/2022 10:00

Complete Blood Count

Sample Type: EDTA

Test Name	Result	Units	Biological Reference Interval
<u>Blood Counts</u>			
Haemoglobin :	13.2	Gms%	12.5 - 16.0
Total R.B.C. :	3.75	mill/c.mm	4.2 - 5.4
Total W. B. C. :	7,640	/cu mm	4000 - 10500
Platelet Count :	2,43,000	/cu.mm	1,50,000 - 4,50,000
<u>Differential Count</u>			
Neutrophils :	50	%	40 - 70
Lymphocytes :	45	%	20 - 40
Eosinophils :	02	%	1 - 4
Monocytes :	03	%	2 - 6
Basophils :	00	%	0 - 01
<u>Blood Indices</u>			
P. C. V :	36.2	%	37 - 47
M. C. V. :	96.6	fl	78 - 100
M.C.H :	35.3	pg	27 - 31
M. C. H. C :	36.4	%	32 - 36
R.D.W :	14.9	%	11.5 - 14.0

E.S.R.(Westergren Method)

After one hour : 10 mm/hr 3 - 12

TESTS DONE ON FULLY AUTOMATED HEMATOLOGY ANALYZER.

DR GAYATRI MEHTA
MD(PATHOLOGY)

Dr. Gayatri M. Mehta
M.D. (Patho)
Reg. No. G-30215

DR. ANAND D. PARIKH
MD(PATHOLOGY)

LAB USE ONLY (Entered by :AP Enter Date/Time:25/01/2022 11:23:00) (Verify by :DM Verify Date/Time:25/01/2022 16:23:00)

ISO 9001:2015 Certified Diagnostics Center

Vidhi Imaging Center | Pathology Department

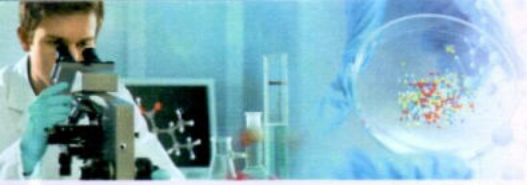L-86, Swatantra Senani Nagar, Opp. Akhbarnagar Petrol Pump, Nr. Akhbarnagar Circle, Nava-Vadaj, Ahmedabad - 380 013.

Ph. (Pathology) : 079-2764 5405, 8849893954 M. 98799 29406, 98250 09406, E-mail : vidhidiagnostics@gmail.com, Web. : www.vidhidiagnostics.com

Time (Pathology) : Mon. to Sat. 8.30 am to 8.00 pm, Sunday 9 am to 12 Noon

Pathology means science behind medicine

CT SCAN & CBCT FACILITY NOW AVAILABLE



Creating Life in Science

Pathology Department

Patient's name : LAXMIBEN J. PATEL
Age/Sex : 46 Years/Female
Referred by : -
Collection Time : 10:00

Reg. ID : P-7367-21
Accession : 6969
Order Dt/time : 25/01/2022 10:00

Blood Group

Sample Type: EDTA sample.

Test Name	Result
BG :	" B "
RH :	POSITIVE
Remarks	Done by forward grouping method.

DR GAYATRI MEHTA
MD(PATHOLOGY)

Dr. Gayatri M. Mehta
(M. D. Patho)
Reg. No. G-32215

DR. ANAND D. PARIKH
MD(PATHOLOGY)

LAB USE ONLY (Entered by :DM Enter Date/Time:25/01/2022 16:22:00) (Verify by :DM Verify Date/Time:25/01/2022 16:22:00)

ISO 9001:2015 Certified Diagnostics Center

Vidhi Imaging Center | Pathology Department

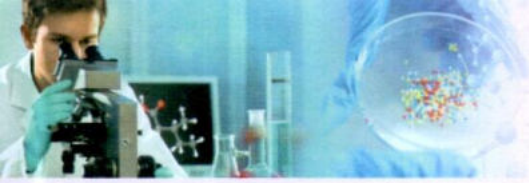L-86, Swatantra Senani Nagar, Opp. Akhbarnagar Petrol Pump, Nr. Akhbarnagar Circle, Nava-Vadaj, Ahmedabad - 380 013.

Ph. (Pathology) : 079-2764 5405, 8849893954 M. 98799 29406, 98250 09406, E-mail : vidhidiagnostics@gmail.com, Web. : www.vidhidiagnostics.com

Time (Pathology) : Mon. to Sat. 8.30 am to 8.00 pm, Sunday 9 am to 12 Noon

Pathology means science behind medicine

CT SCAN & CBCT FACILITY NOW AVAILABLE



Pathology Department



Patient's name : LAXMIBEN J. PATEL
Age/Sex : 46 Years/Female
Referred by : -
Collection Time : 10:00

Reg. ID : P-7367-21
Accession : 6969
Order Dt/time : 25/01/2022 10:00

Blood Glucose

Sample Type: Serum

Test Name	Result	Units	Biological Reference Interval
Fasting Blood Glucose : <i>GOD-POD Method.</i>	96.8	mg/dl	70 - 110

Blood Glucose

Sample Type: Serum

Test Name	Result	Units	Biological Reference Interval
Post Prandial Blood Glucose After 2hr. : <i>GOD-POD Method.</i>	105.3	mg/dl	80 - 140

DR GAYATRI MEHTA
MD(PATHOLOGY)

Dr. Gayatri M. Mehta
M. D. Pathology
Reg. No. G-92215

DR. ANAND D. PARIKH
MD(PATHOLOGY)

LAB USE ONLY (Entered by :DM Enter Date/Time:25/01/2022 16:24:00) (Verify by :DM Verify Date/Time:25/01/2022 16:24:00)

ISO 9001:2015 Certified Diagnostics Center

Vidhi Imaging Center | Pathology Department

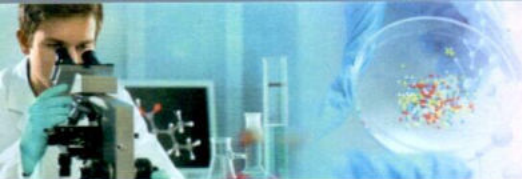L-86, Swatantra Senani Nagar, Opp. Akhbarnagar Petrol Pump, Nr. Akhbarnagar Circle, Nava-Vadaj, Ahmedabad - 380 013.

Ph. (Pathology) : 079-2764 5405, 8849893954 M. 98799 29406, 98250 09406, E-mail : vidhidiagnostics@gmail.com, Web. : www.vidhidiagnostics.com

Time (Pathology) : Mon. to Sat. 8.30 am to 8.00 pm, Sunday 9 am to 12 Noon

Pathology means science behind medicine

CT SCAN & CBCT FACILITY NOW AVAILABLE



Creating Life in Science



Pathology Department

Patient's name : LAXMIBEN J. PATEL
 Age/Sex : 46 Years/Female
 Referred by : -
 Collection Time : 10:00

Reg. ID : P-7367-21
 Accession : 6969
 Order Dt/time : 25/01/2022 10:00

HbA1C

Sample Type: Serum

Test Name	Result	Units	Biological Reference Interval
HbA1C :	5.3	%	Non-diabetic: 4.2-6.2 Pre-diabetic : 6.3-7.2 Diabetic : 7.3-8.2
Mean Blood Glucose of Last 03 months.	105.41	mg/dl	

Comment

*As per the new 2009 update of American Diabetes Association regarding HbA1C & Mean Blood Glucose relationship.
 This test is used to monitor diabetic patients compliance with the therapeutic regimen and logo It's level is proportional to both the average blood glucose concentration and the life span of the red blood cells (RBC) in circulation. HbA1c values are free of day to day glucose fluctuations and are unaffected by exercise or recent food intake.

NOTE:

DR GAYATRI MEHTA
 MD(PATHOLOGY)
Dr. Gayatri M. Mehta
 M. D. (Pathology)
 REG. NO. G-32215

DR. ANAND D. PARIKH
 MD(PATHOLOGY)

LAB USE ONLY (Entered by :DM Enter Date/Time:25/01/2022 16:23:00) (Verify by :DM Verify Date/Time:25/01/2022 16:23:00)

ISO 9001:2015 Certified Diagnostics Center
 Vidhi Imaging Center | Pathology Department

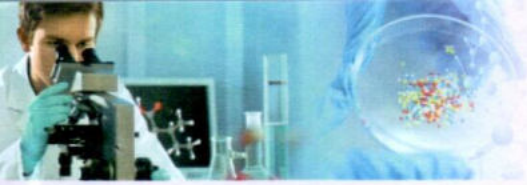L-86, Swatantra Senani Nagar, Opp. Akhbarnagar Petrol Pump, Nr. Akhbarnagar Circle, Nava-Vadaj, Ahmedabad - 380 013.

Ph. (Pathology) : 079-2764 5405, 8849893954 M. 98799 29406, 98250 09406, E-mail : vidhidiagnostics@gmail.com, Web. : www.vidhidiagnostics.com

Time (Pathology) : Mon. to Sat. 8.30 am to 8.00 pm, Sunday 9 am to 12 Noon

Pathology means science behind medicine

CT SCAN & CBCT FACILITY NOW AVAILABLE



Pathology Department

Patient's name : LAXMIBEN J. PATEL
Age/Sex : 46 Years/Female
Referred by : -
Collection Time : 10:00

Reg. ID : P-7367-21
Accession : 6969
Order Dt/time : 25/01/2022 10:00

Lipid Profile

Sample Type: Serum

Test Name	Result	Units	Biological Reference Interval
S. Cholesterol : Oxidase-esterase method.	166.0	mg/dl	0 - 200
S. Triglyceride : Enzymatic Colorimetry method	123.1	mg/dL	0 - 200
S. HDL - Cholesterol : Serum by Enzymatic method.	49.0	mg/dL	35 - 65
S. LDL - Cholesterol : Serum by Enzymatic method	92.38	mg/dL	0 - 130
S. VLDL - Cholesterol :	24.62	mg/dL	0 - 30
S. Chole/HDL.Ratio :	3.39		1 - 6
S. LDL/ HDL Cholesterol Ratio :	1.89		0 - 3.5

Dr. Gayatri M. Mehta

DR GAYATRI MEHTA
MD(PATHOLOGY)

M.D. (Patho)
Reg. No. G-32215

DR. ANAND D. PARIKH
MD(PATHOLOGY)

LAB USE ONLY (Entered by :DM Enter Date/Time:25/01/2022 16:24:00) (Verify by :DM Verify Date/Time:25/01/2022 16:24:00)

ISO 9001:2015 Certified Diagnostics Center

Vidhi Imaging Center | Pathology Department

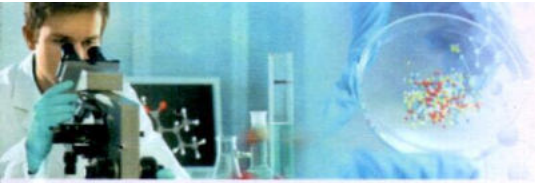L-86, Swatantra Senani Nagar, Opp. Akhbarnagar Petrol Pump, Nr. Akhbarnagar Circle, Nava-Vadaj, Ahmedabad - 380 013.

Ph. (Pathology) : 079-2764 5405, 8849893954 M. 98799 29406, 98250 09406, E-mail : vidhidiagnostics@gmail.com, Web. : www.vidhidiagnostics.com

Time (Pathology) : Mon. to Sat. 8.30 am to 8.00 pm, Sunday 9 am to 12 Noon

Pathology means science behind medicine

CT SCAN & CBCT FACILITY NOW AVAILABLE



Patient's name : LAXMIBEN J. PATEL
Age/Sex : 46 Years/Female
Referred by : -
Collection Time : 10:00

Reg. ID : P-7367-21
Accession : 6969
Order Dt/time : 25/01/2022 10:00

BIOCHEMISTRY

Sample type :Serum

Test Name	Result	Units	Biological Reference Interval
Urea , (Serum by GLDH method) :	19.5	mg/dl	10 - 50
S.Uric acid , (Serum by Uricase method) :	4.4	mg/dl	2.4-5.7
Bun :	9.1	mg/dl	6-20
Creatinine , (Serum by Enzymatic reaction) :	0.58	mg/dl	0.5-1.2
S.G.P.T (ALT) : (Serum by IFCC method)	14.1	U/L	0 - 40
S.G.O.T (AST) : (Serum by IFCC method)	23.8	U/L	0 - 37
ALK.PHOSPHATASE : (Serum by PNP method)	69.0	U/L	35-104
G.G.T :	16.2	U/L	8 - 78
<u>BILIRUBIN</u>			
Total :	0.43	mg/dl	Up to 1.2
Direct :	0.21	mg/dl	0-0.7
Indirect :	0.22	mg/dl	0 - 0.5
<u>SERUM PROTEINS</u>			
Total Protein (Serum by Biuret method) :	7.70	gms/dl	
Albumin (Serum by BCG method) :	4.24	gms/dl	3.97-4.94
Globulins :	3.46	gms/dl	2.3 - 3.5
A/G Ratio :	1.225		0.9 - 2.9

DR GAYATRI MEHTA
MD(PATHOLOGY)

Dr. Gayatri M. Mehta
(M.D. Pathology)
Reg. No. G-32215

DR. ANAND D. PARIKH
MD(PATHOLOGY)

LAB USE ONLY (Entered by:DM Enter Date/Time:25/01/2022 16:23:00) (Verify by:DM Verify Date/Time:25/01/2022 16:23:00)

ISO 9001:2015 Certified Diagnostics Center

Vidhi Imaging Center | Pathology Department

L-86, Swatantra Senani Nagar, Opp. Akhbarnagar Petrol Pump, Nr. Akhbarnagar Circle, Nava-Vadaj, Ahmedabad - 380 013.

Ph. (Pathology) : 079-2764 5405, 8849893954 M. 98799 29406, 98250 09406, E-mail : vidhidiagnostics@gmail.com, Web. : www.vidhidiagnostics.com

Time (Pathology) : Mon. to Sat. 8.30 am to 8.00 pm, Sunday 9 am to 12 Noon

Pathology means science behind medicine

CT SCAN & CBCT FACILITY NOW AVAILABLE



Pathology Department

Name: LAXMIBEN J. PATEL
Referred by: -
Date : 25-01-2022

Age: 46 Years
Sex: Female

AST : ALT RATIO

Test	Result	Unit	Normal Value
AST:ALT	1.688	Ratio	0.8-1.2

BUN : CREAT RATIO

Test	Result	Unit	Normal Value
BUN:CREAT	15.68	Ratio	13-20

Dr. Gayatri M. Mehta
(M. A. Pathology)
Reg. No. G-92215

For Dr. GAYATRI MEHTA

ISO 9001:2015 Certified Diagnostics Center
Vidhi Imaging Center | Pathology Department

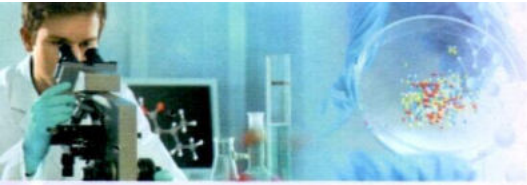L-86, Swatantra Senani Nagar, Opp. Akhbarnagar Petrol Pump, Nr. Akhbarnagar Circle, Nava-Vadaj, Ahmedabad - 380 013.

Ph. (Pathology) : 079-2764 5405, 8849893954 M. 98799 29406, 98250 09406, E-mail : vidhidiagnostics@gmail.com, Web. : www.vidhidiagnostics.com

Time (Pathology) : Mon. to Sat. 8.30 am to 8.00 pm, Sunday 9 am to 12 Noon

Pathology means science behind medicine

CT SCAN & CBCT FACILITY NOW AVAILABLE



Patient's name : LAXMIBEN J. PATEL
Age/Sex : 46 Years/Female
Referred by : -
Collection Time : 10:00

Reg. ID : P-7367-21
Accession : 6969
Order Dt/time : 25/01/2022 10:00

Thyroid Function Test

Sample Type: Serum

Test Name	Result	Units	Biological Reference Interval
TOTAL T3 :	1.23	ng/ml	0.84 - 2.0
TOTAL T4 :	10.3	ug/dl	5.1 - 14.0
TSH(Ultra sensitive) :	3.790	mIU/L	0.27 - 4.2

Method Electrochemiluminescence Immunoassay "ECLIA"

Test done on Roche Cobas e411 Immunoassay Analyser

DR GAYATRI MEHTA
MD(PATHOLOGY)

Dr. Gayatri M. Mehta
MD (Patho)
Reg. No. G-32215

DR. ANAND D. PARIKH
MD(PATHOLOGY)

LAB USE ONLY (Entered by :DM Enter Date/Time:25/01/2022 16:25:00) (Verify by :DM Verify Date/Time:25/01/2022 16:25:00)

ISO 9001:2015 Certified Diagnostics Center

Vidhi Imaging Center | Pathology Department

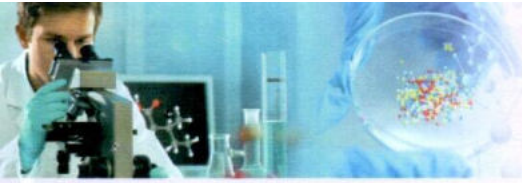L-86, Swatantra Senani Nagar, Opp. Akhbarnagar Petrol Pump, Nr. Akhbarnagar Circle, Nava-Vadaj, Ahmedabad - 380 013.

Ph. (Pathology) : 079-2764 5405, 8849893954 M. 98799 29406, 98250 09406, E-mail : vidhidiagnostics@gmail.com, Web. : www.vidhidiagnostics.com

Time (Pathology) : Mon. to Sat. 8.30 am to 8.00 pm, Sunday 9 am to 12 Noon

Pathology means science behind medicine

CT SCAN & CBCT FACILITY NOW AVAILABLE



Patient's name : LAXMIBEN J. PATEL
Age/Sex : 46 Years/Female
Referred by : -
Collection Time : 10:00

Reg. ID : P-7367-21
Accession : 6969
Order Dt/time : 25/01/2022 10:00

Urine Analysis

Sample Type: Urine

Test Name	Result	Units	Biological Reference Interval
-----------	--------	-------	-------------------------------

Physical Examination

Quantity :	30	ml	0 - 500 ml
Colour :	Pale Yellow		Pale Yellow
Transparency :	Slight Turbid.		Clear
Reaction :	Acidic		4.6 - 8.0
Specific Gravity :	1.025		1.016 - 1.022
Sediment :	Present		

Chemical Examination

Albumin :	Present (Trace)		Absent
Sugar :	NIL		Absent
Acetone :	Absent		Absent
Bile Salts :	Absent		Absent
Bile Pigments :	Absent		Absent
Urobilogen :	Absent		Absent
Nitrites :	Absent		Absent

Microscopic Examination

Red blood Cells :	2-3	/h.p.f	Absent
Pus Cells :	2-3	/h.p.f	Absent
Epithelial Cells :	1-2	/h.p.f	< 10.0
Amorphous :	Absent	/h.p.f	Absent
Bacteria :	Absent	/h.p.f	Absent
Crystals :	Absent	/h.p.f	Absent
Casts :	Absent	/h.p.f	Absent
Fungus :	Not seen	/h.p.f	Absent

DR GAYATRI MEHTA
MD(PATHOLOGY)

Dr. Gayatri M. Mehta
Reg. No. 021215

DR. ANAND D. PARIKH
MD(PATHOLOGY)

LAB USE ONLY (Entered by :DM Enter Date/Time:25/01/2022 16:24:00) (Verify by :DM Verify Date/Time:25/01/2022 16:24:00)

ISO 9001:2015 Certified Diagnostics Center

Vidhi Imaging Center | Pathology Department

L-86, Swatantra Senani Nagar, Opp. Akhbarnagar Petrol Pump, Nr. Akhbarnagar Circle, Nava-Vadaj, Ahmedabad - 380 013.

Ph. (Pathology) : 079-2764 5405, 8849893954 M. 98799 29406, 98250 09406, E-mail : vidhidiagnostics@gmail.com, Web. : www.vidhidiagnostics.com

Time (Pathology) : Mon. to Sat. 8.30 am to 8.00 pm, Sunday 9 am to 12 Noon

Pathology means science behind medicine

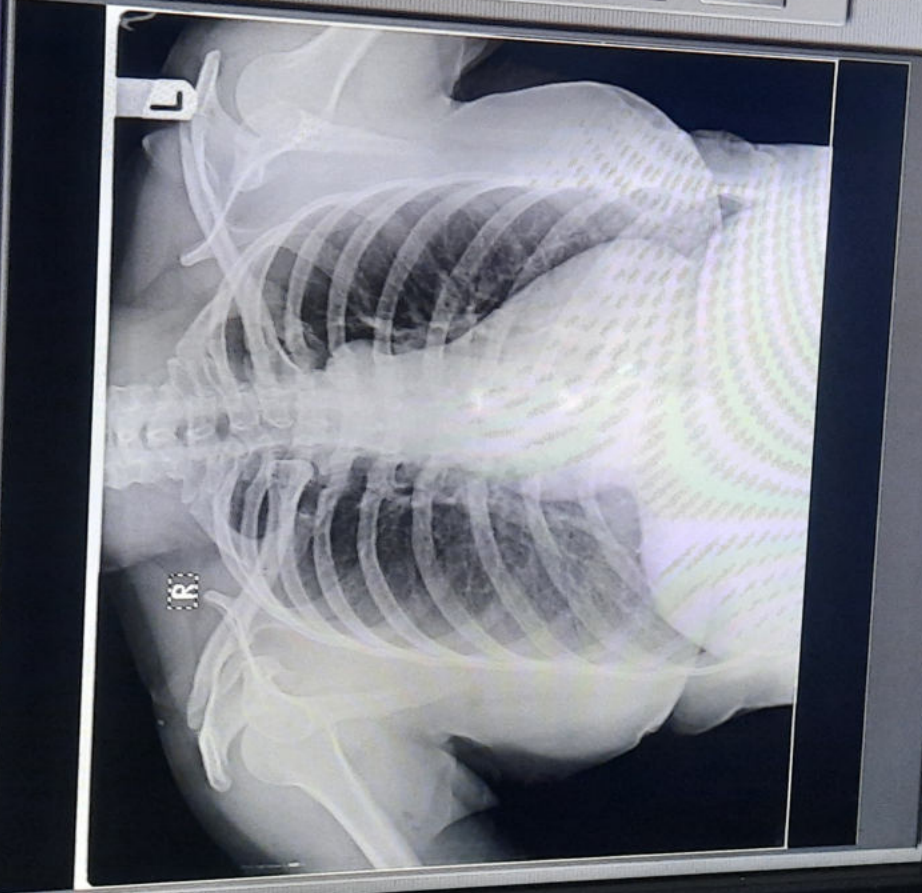
CT SCAN & CBCT FACILITY NOW AVAILABLE

IP
TRANSFER
PHONE
RETAIL

FLASH+NO
0
*

25012204

LAXMIBEN J. PATEL / 46 Y F



MAIN PROCESS Delivery

CHEST,FRN P->A

GA 0.9 S/L

GS -0.35 SS/CS

S 196 L/R

Navigation icons: Home, Back, Forward, Refresh, Zoom, Rotate, etc.

DELL

