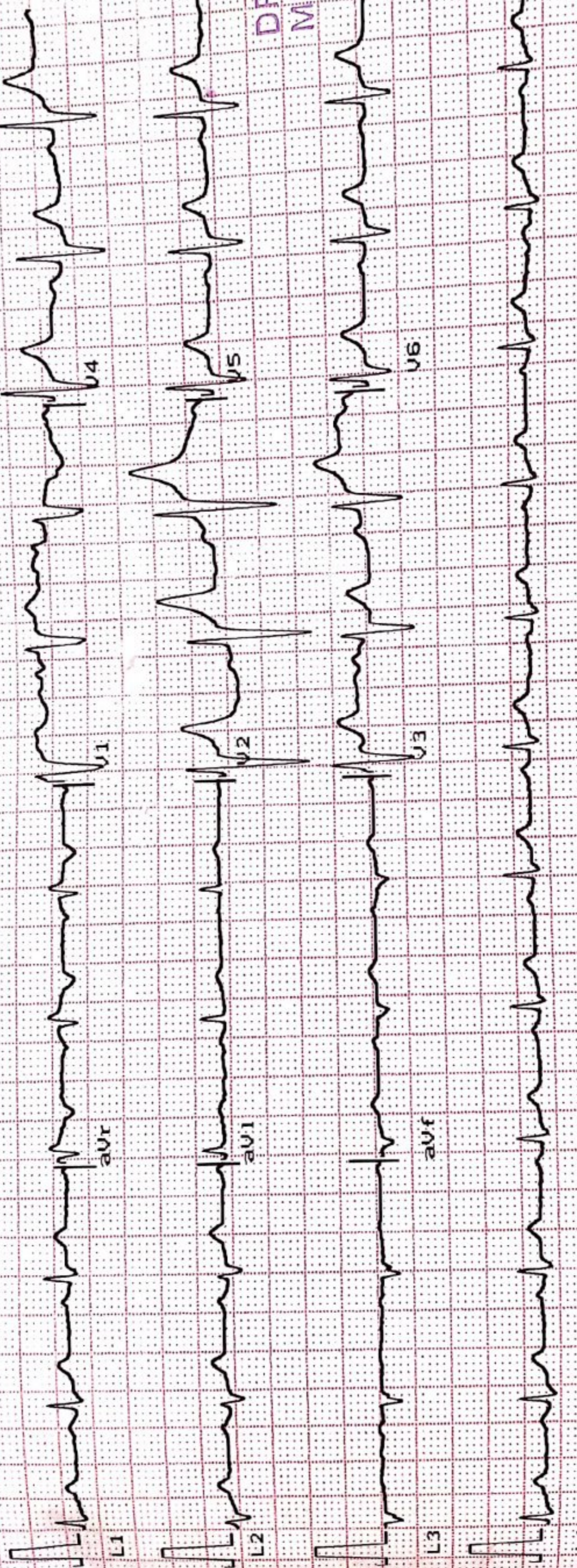


Name: Sampath Hal Dabgar

60 yrs cm K9 BP

Handwritten signature

Heart Rate : 87 bpm



INTERVAL (ms)  
 PR: 135 QRS: 27  
 QT: 320 QTc: 389  
 ST: 150

AXIS (deg)  
 P : 39 QRS: -7  
 T : 30

DR. VIMAL TAILOR  
 MBBS - C41306



10mm/mV Time:  
 1.9 25mm/sec Date: 12/06/2021



# SHREEJI Multispeciality Hospital

Inspiring better health...

SHREEJI OCCUPATIONAL CENTRE SHREEJI PATHOLOGY LABORATORY

108, Tower-B, Senate Square, Opp. Gangotri Apartment, Vuda Char rasta, Gotri, Vadodara-390021.  
M. : 9157022510, Email : shreejihospital19@yahoo.com, smh31082015@gmail.com

NAME	Sampatlal Dabher	DATE	12/06/2024
		SR. NO.	13
		SEX.	male
		AGE	60 yrs
		HEIGHT	161 cm
		WEIGHT	65 kg

### HISTORY

Present History : DM since 10 yrs, HT, TB, Asthma, Epilepsy  
 Past Illness History : Diabetes/Hypertension/Tuberculosis/Asthma/Epilepsy N/A  
 Past Occupational History :  
 Family History : N/A  
 Personal History :  
 Addiction : both knee replacement before 7 yrs, both side  
 Tobacco/Gutkha/Smoking/Alcohol : Hemorrhage before 2 yrs, both eye cataract before 10 yrs

### GENERAL EXAMINATION

T.P.R. : N/A  
 B.P. : 124/86 mm Hg  
 Pallor/Icterus/Cyanosis/Varicosity/Lymph Nodes/Thyroid/Oedema/NVE/Other : N/A

### SYSTEMIC EXAMINATION

R.S. :  
 C.V.S. :  
 C.N.S. :  
 A.S. :  
 Musculo-skelet System : N/A

E.N.T. Ex. Dental Ex. Skin Ex. Psychic Ex.	ACUITY OF VISION		
	Without Glass	DISTANT	RT EYE 6/ — LT EYE 6/ —
		Near	6/ —
	With Glass	DISTANT	6/ 6
Near		6/ 6	
COLOUR BLINDNESS			

REMARK : N/A

ADVICE :

The Worker is **FIT/UNFIT** for the assigned job.

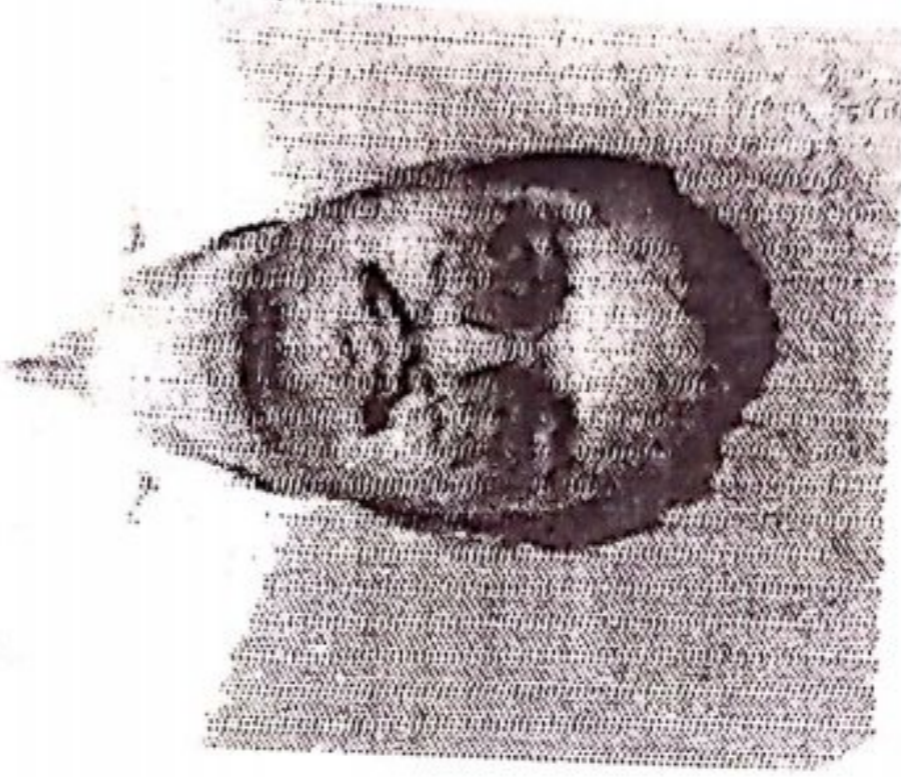

DR VIMAL TAILOR  
MBBS- G41306

DR. VIMAL TAILOR  
Occupational Physician  
(M.B.B.S, CIH)  
REG NO.: G-41306

स्पाई लेखा संख्या

/PERMANENT ACCOUNT NUMBER



ACGPD8788G

नाम /NAME

SAMPATLAL GANESHBHAI DABGAR



पिता का नाम /FATHER'S NAME

GANESHBHAI RATNABHAI DABGAR

जन्म तिथि /DATE OF BIRTH

02-06-1961

*Meeer*

हस्ताक्षर /SIGNATURE

*V. Lal*

आयकर आयुक्त, बड़ौदा  
COMMISSIONER OF INCOME-TAX, BARODA

*V. Lal*





बँक ऑफ बरोडा  
Bank of Baroda



नाम

संपतलाल गणेशभाई दबगर

Name

SAMPATLAL GANESHBHAI DABGAR

ए.सी. क्र.:

E.C. No.

42829

*[Handwritten signature]*

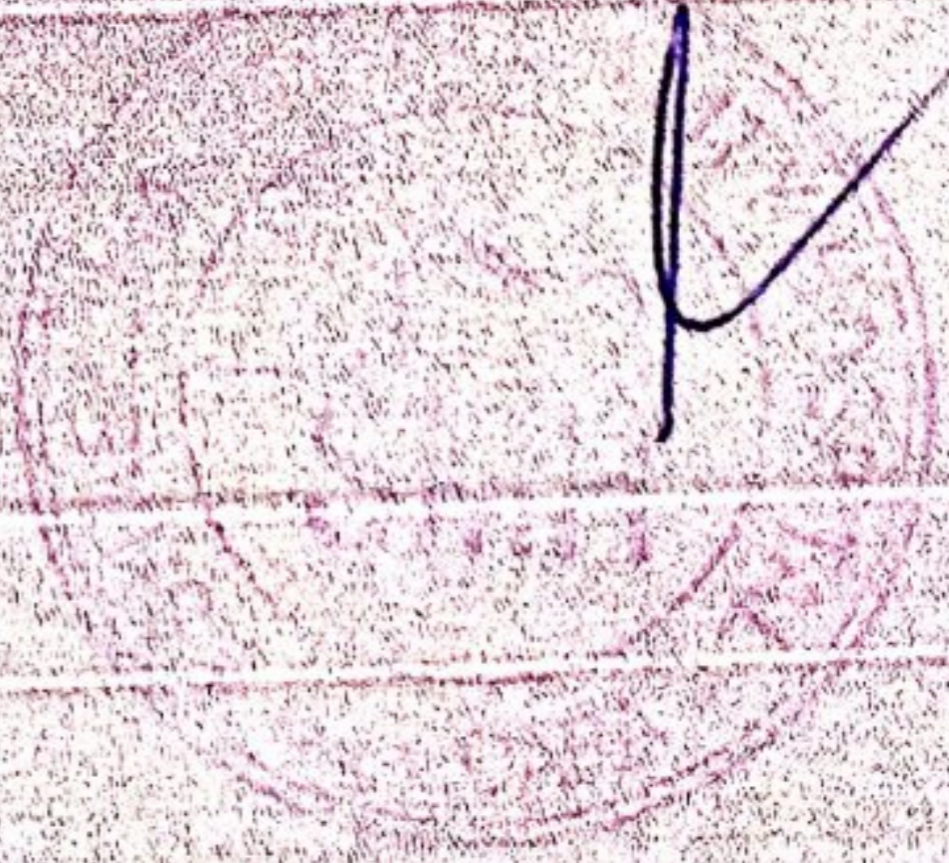
*[Handwritten signature]*

संपतलाल गणेशभाई दबगर  
संपतलाल गणेशभाई दबगर

संपतलाल गणेशभाई दबगर  
संपतलाल गणेशभाई दबगर



*[Handwritten signature]*



  
**Heart & General Clinic**

**2D Echocardiography & Color Doppler Report**

iCure Hear care, 402, Epsilon tower, opp Pasha bhai park, Race course, Vadodara

**Patient Name: Mr. Sampatlal Dabgar**

**Date: 12 / 06 / 2021**

**Age, Gender: Male - 60 Years**

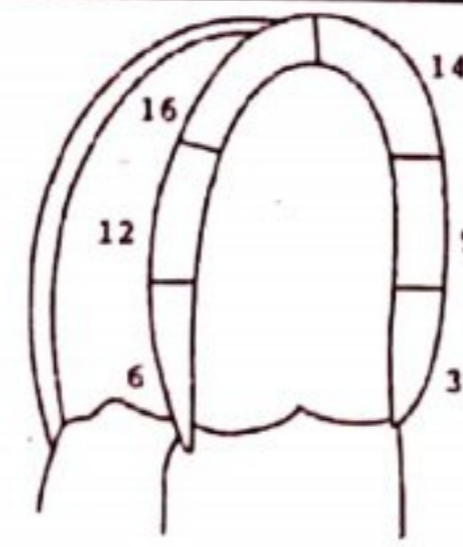
**Ref. by : Shreeji Multispeciality Hospital**

**M. Mode Study:**

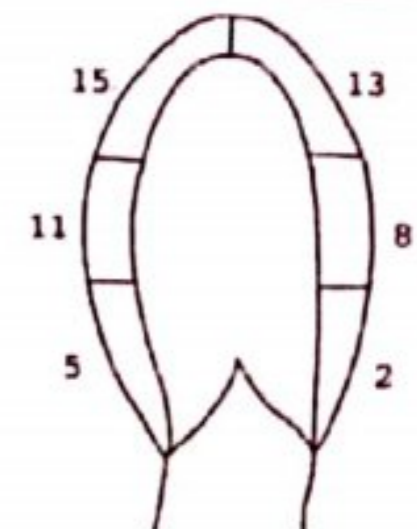
<b>LA</b>	<b>28</b>	<b>IVS</b>	<b>9</b>	<b>PWD</b>	<b>9</b>
<b>AO</b>	<b>24</b>	<b>LVDs</b>	<b>30</b>	<b>LVDd</b>	<b>46</b>

**Doppler Study:**

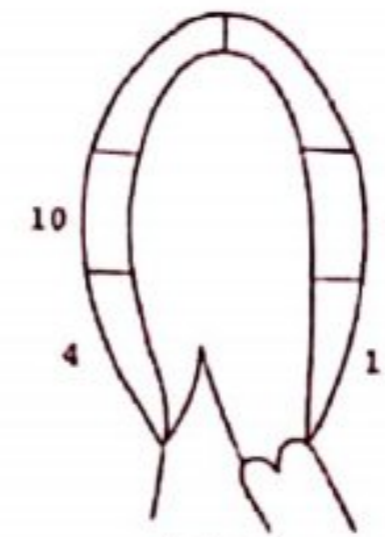
<b>Mitral Valve</b>	<b>E: 1.77 A: 2.22</b>
<b>Aortic Valve</b>	<b>NAD</b>
<b>Tricuspid Valve</b>	<b>NAD</b>
<b>Pulmonary Valve</b>	<b>NAD</b>



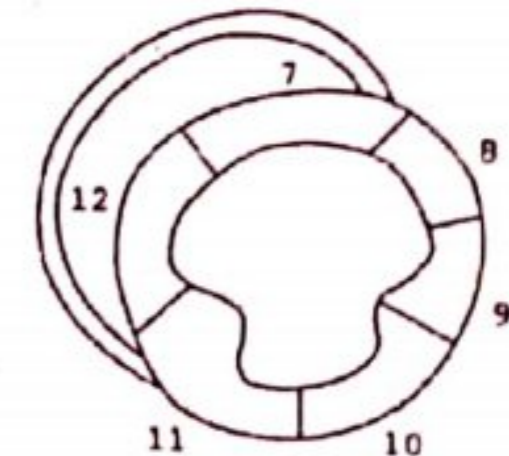
Apical 4 chamber view



Apical 2 chamber view



Apical 3 chamber view



Parasternal short axis view

**Conclusion:**

- **Normal LV Systolic function**
- **LVEF: 60 % ,No RWMA**
- **Cardiac Chambers: Normal**
- **Diastolic function: Diastolic Dysfunction Grade I**
- **TR: No PAH: No , RVSP: 12 mmhg**
- **No MR, No MS**
- **No AR , No AS**
- **ASD/VSD/PDA/Co-A : No**
- **No Clots or vegetations found**
- **IVC: Normal**



**Signed**

**Dr. Krish P Vaidy**  
Consultant Cardiologist, Diabetologi  
& General Physicia

Note:

Normal 2D echo report does not rule out cardiac diseases  
this report shall not be used for Medico legal purposes,  
Clinical Correlation advisable.



# SHREEJI Multispeciality Hospital

Inspiring better health...

SHREEJI OCCUPATIONAL CENTRE SHREEJI PATHOLOGY LABORATORY

112F, Tower-A, Senate Square, Opp. Gangotri Apartment, Vuda Char rasta, Gotri, Vadodara-390021.  
M. : 9157022510, Email : shreejihospital19@yahoo.com, smh31082015@gmail.com

Name : SAMPATLAL DABGAR

Ref By : DR. SMH

Age/Sex : 60 Yrs./M

Date : 12/06/2021

Report ID. : 2

## HAEMOGRAM PROFILE

TEST	RESULT	UNIT	METHOD	REFERENCE INTERVAL
<b>BLOOD COUNTS &amp; INDICES</b>				
Haemoglobin	: 13.00	gm%		13.5 - 17.0 gm%
Total RBC	: 5.00	mill/cmm		4.6 - 6.2 mill/cmm
PCV	: 48.00	%		40 - 54 %
MCV	: 96.00	fL		80 - 96 fL
MCH	: 25.80	pg		27 - 31 pg
MCHC	: 26.87	%		32 - 36 %
Total WBC	: 8,400	/cmm		4,000 - 11,000/cmm
Platelet Count	: 3,32,000	/cmm		1.5 - 4.0 Lac/cmm.
<b>DIFFERENTIAL LEUCOCYTES COUNT</b>				
Band Cells	: 00	%		00 - 06 %
Neutrophils	: 63	%		55 - 70 %
Lymphocytes	: 26	%		20 - 40 %
Eosinophils	: 05	%		01 - 06 %
Monocytes	: 06	%		02 - 08 %
Basophils	: 00	%		00 - 01 %
Platelet In Smear	: ADEQUATE			
<b>ERYTHROCYTES SEDIMENTATION RATE</b>				
ESR After 1st Hour	: 7	mm	Westergren	01 - 07 mm
Blood Group	: "B"			
Rh Factor (Anti D.)	: "POSITIVE"			

(By Fully Automated Cell Counter Sysmex KX-21, Japan)

END OF REPORT



DR. YOGESH (MLT)  
DR. JIGAR SHAH (MD PATHO)  
G-23327



# Shreeji Multispeciality Hospital

Inspiring better health...

SHREEJI OCCUPATIONAL CENTRE SHREEJI PATHOLOGY LABORATORY

112F, Tower-A, Senate Square, Opp. Gangotri Apartment, Vuda Char rasta, Gotri, Vadodara-390021.  
M. : 9157022510, Email : shreejihospital19@yahoo.com, smh31082015@gmail.com

Name : SAMPATLAL DABGAR  
Ref By : DR. SMH

Age/Sex : 60 Yrs./M  
Date : 12/06/2021  
Report ID. : 2

## BIOCHEMISTRY

TEST	RESULT	UNIT	REFERENCE INTERVAL
Blood Urea Nitrogen - BUN	: 19.00	mg/dL	4.5 - 19.0 mg/dL
Serum Creatinine	: 1.00	mg/dL	0.6 - 1.4 mg/dL
Serum Uric Acid	: 3.70	mg/dL	3.4 - 7.0 mg/dL
<b>SERUM PROTEIN</b>			
Serum Protein Total	: 7.90	g/dL	6.6 - 8.3 g/dL
Albumin	: 5.00	g/dL	3.5 - 5.0 g/dL
Globulin	: 2.90	g/dL	2.3 - 3.5 g/dL
A/G Ratio	: 1.7	: 1	1.5 - 2.5 : 1
Bilirubin - Total	: 0.7	mg/dL	0.00 - 1.00 mg/dL
Bilirubin - Direct	: 0.2	mg/dL	Upto 0.30 mg/dL
Bilirubin - Indirect	: 0.5	mg/dL	0.1 - 1.0 mg/dL
SGPT	: 37.0	IU/L	10 - 40 IU/L
SGOT	: 30.0	IU/L	Upto 40 IU/L
Serum Alkaline Phosphatase	: 105.0	U/L	37 - 147 U/L
<b>LIPID PROFILE</b>			
Serum Cholesterol	: 184.00	mg/dL	130 - 200 mg/dL
Serum Triglyceride	: 126.00	mg/dL	60 - 165 mg/dL
HDL Cholesterol	: 61.00	mg/dL	30 - 70 mg/dL
LDL Cholesterol	: 97.80	mg/dL	Upto 150 mg/dL
VLDL	: 25.20	mg/dL	Upto 30 mg/dL
<b>FASTING (FBS)</b>			
Blood Glucose	: <b>121.0</b>	mg/dL	70 - 110 mg/dL
Urine Glucose	: NIL		
<b>POST-PRANDIAL</b>			
Blood Glucose	: <b>180.0</b>	mg/dL	80 - 140 mg/dL
Urine Glucose	: NIL		
<b>SPECIAL TESTS</b>			
GGTP	: 50	U/L	05 - 85 U/L
Gamma Glutamyltransferase			

Done By Fully Auto Analyzer MIURA, A-1004

END OF REPORT



DR.YOGESH (MLT)  
DR JIGAR SHAH (MD PATHO)  
G-23327



# SHREEJI Multispeciality Hospital

Inspiring better health...

SHREEJI OCCUPATIONAL CENTRE SHREEJI PATHOLOGY LABORATORY

112F, Tower-A, Senate Square, Opp. Gangotri Apartment, Vuda Char rasta, Gotri, Vadodara-390021.  
M. : 9157022510, Email : shreejihospital19@yahoo.com, smh31082015@gmail.com

Name : SAMPATLAL DABGAR  
Ref By : DR. SMH

Age/Sex : 60 Yrs./M  
Date : 12/06/2021  
Report ID. : 2

### EXAMINATION OF URINE

Sample : RANDOM  
**PHYSICAL EXAMINATION**

Colour : YELLOW  
Specific Gravit : 1.030  
Deposits : ABSENT

#### CHEMICAL EXAMINATION

Sugar : NIL  
Bile Salts : ABSENT  
Urobilinogen : NORMAL : ~ < 1.0 mg/dL  
Nitrate : ABSENT

#### MICROSCOPIC EXAMINATION

RBC : NIL  
Crystals : NIL

Quantity : 10 mL  
Transparency : CLEAR  
Reaction : ACIDIC

Albumin : NIL  
Acetone : ABSENT  
Bile Pigments : ABSENT  
Occult Blood : ABSENT

Pus Cells : NIL  
Epithelial Cell : NIL  
Amorphous Phosp : NIL

### THYROID FUNCTIONS

TEST	RESULT	UNIT	REFERENCE INTERVAL
Total Triiodothyronine - T3	: 1.10	ng/mL	0.58 - 1.59 ng/mL
Total Thyroxine - T4	: 7.80	ng/mL	4.87 - 11.72 microgram%
Thyroid Stim. Hormone -TSH	: 2.40	ng/mL	0.35 - 4.94 IU/mL

### PROSTATE SPECIFIC ANTIGEN

P. S. A.	: <u>&lt;4.10</u>	ng/ml	0.0 - 4.0 ng / ml (I) 04 - 15 ng/ml Possibly Benign Prostate Hyperplasia (II) > 20 ng/ml Suspected Prostate Carcinoma
----------	-------------------	-------	---

END OF REPORT



DR. YOGESH (MLT)  
DR. JIGAR SHAH (MD PATHO)  
G-23327





# Shreeji Multispeciality Hospital

Inspiring better health...

Shreeji Occupational Centre Shreeji Pathology Laboratory

112F, Tower-A, Senate Square, Opp. Gangotri Apartment, Vuda Char rasta, Gotri, Vadodara-390021.

M. : 9157022510, Email : shreejihospital19@yahoo.com, smh31082015@gmail.com

Name : SAMPATLAL DABGAR

Ref By : DR. SMH

Age/Sex : 60 Yrs./M

Date : 12/06/2021

Report ID. : 2

## Hb A1C REPORT

<u>TEST</u>	<u>RESULT</u>	<u>UNIT</u>	<u>REFERENCE INTERVAL</u>
Hb A1C - Glycated Hb Glycated Haemoglobin	: <b>8.1</b>	%	Non Diabetic : 4.3 - 6.3 % Good Control : 6.4 - 7.5 % Moderate Control : 7.5 - 9.0 % Poor Control : 9.0 % & Above
Avg. Blood Glucose Level	: 211	mg/dL	
Estimated Average Glucose eAG	: 186	mg%	

END OF REPORT



DR.YOGESH (MLT)  
DR JIGAR SHAH (MD PATHO)  
G-23327



# Shreeji Multispeciality Hospital

Inspiring better health...

Shreeji Occupational Centre Shreeji Pathology Laboratory

112F, Tower-A, Senate Square, Opp. Gangotri Apartment, Vuda Char rasta, Gotri, Vadodara-390021.  
M. : 9157022510, Email : shreejihospital19@yahoo.com, smh31082015@gmail.com

NAME : SHANTILAL DABGAR

AGE : 60 Y/M

DATE : 12/06/2021

## ULTRASOUND WHOLE ABDOMEN

(Screening Only)

**Liver** is normal in size and shows normal parenchymal reflectivity. No focal lesion is seen. Hepatic veins appear normal. There is no evidence of any dilated intra hepatic biliary radicals.

**Portal Vein** appears normal in diameter. **Common Bile Duct** is of normal diameter.

**Gallbladder** is distended with normal wall thickness. There is no evidence of gallstones. No evidence of peri-cholecystic fluid or probe tenderness.

**Pancreas** is normal in size and shows homogenous reflectivity. There is no evidence of any calcification or ductal dilatation.

**Spleen** is normal size and shows a homogenous echotexture. There is no evidence of any focal lesion.

**Both Kidneys** are normal in position and size. They show normal cortical reflectivity and cortico-medullary distinction. Right kidney measures 82x41mm. Left kidney measures 94x46mm. There is no evidence of renal calculi, hydronephrosis or mass seen.

**Bladder** is well distended and shows normal wall thickness. No evidence of intra-luminal mass or calculi.

**Prostate gland** is normal in size. It has smooth outlines and normal reflectivity.

There is no evidence of ascites.

No evidence of any gross bowel mass seen.

No evidence of any aorto-caval or mesenteric root lymphadenopathy.

Appendix cannot be imaged. No mass or collection in right iliac fossa.

**CONCLUSION:** No sonographic abnormality is seen.

*Mehul Prajapati*

DR. MEHUL PRAJAPATI  
CONSULTANT RADIOLOGIST





# SHREEJI Multispeciality Hospital

Inspiring better health...

SHREEJI OCCUPATIONAL CENTRE SHREEJI PATHOLOGY LABORATORY

112F, Tower-A, Senate Square, Opp. Gangotri Apartment, Vuda Char rasta, Gotri, Vadodara-390021.  
M. : 9157022510, Email : shreejihospital19@yahoo.com, smh31082015@gmail.com

NAME : SHANTILAL DABGAR	AGE : 60 Y/M	DATE : 12/06/2021
-------------------------	--------------	-------------------

## X RAY CHEST (PA)

### OBSERVATIONS:

Both the lung fields and apices appear clear.

Both the hilar shadow appears normal.

Cardiac silhouette appears normal.

Both the costophrenic sinuses are clear.

Mediastinal and tracheal shadows are normal.

Both the domes of diaphragm are normal.

Visualized rib cage and clavicle are normal.

### COMMENTS:

- No significant abnormality is seen.

*Mehul Prajapati*

**DR. MEHUL PRAJAPATI**  
**CONSULTANT RADIOLOGIST**

