


CLUMAX DIAGNOSTICS

MEDALL

--- A MEDALL COMPANY ---

Date 26-Feb-2022 9:21 AM

Customer Name : **MR.RAJU MEHER**DOB : **16 Jul 1988**Ref Dr Name : **MediWheel**Age : **33Y/MALE**Customer Id : **MED110999468**Visit ID : **422012361**




Email Id :

Phone No : **9853208565**Corp Name : **MediWheel**

Address :

Package Name : **Mediwheel Full Body Health Checkup Male Below 40**

S.No	Modality	Study	Accession No	Time	Seq	Signature
1	LAB	BLOOD UREA NITROGEN (BUN)				
2	LAB	CREATININE				
3	LAB	GLUCOSE - FASTING				
4	LAB	GLUCOSE - POSTPRANDIAL (2 HRS)				
5	LAB	GLYCOSYLATED HAEMOGLOBIN (HbA1c)				
6	LAB	URIC ACID				
7	LAB	LIPID PROFILE				
8	LAB	LIVER FUNCTION TEST (LFT)				
9	LAB	THYROID PROFILE/ TFT(T3, T4, TSH)				
10	LAB	URINE GLUCOSE - FASTING				
11	LAB	URINE GLUCOSE - POSTPRANDIAL (2 Hrs)				
12	LAB	COMPLETE BLOOD COUNT WITH ESR				
13	LAB	STOOL ANALYSIS - ROUTINE				
14	LAB	URINE ROUTINE				
15	LAB	BUN/CREATININE RATIO				
16	LAB	BLOOD GROUP & RH TYPE (Forward Reverse)				
17	OTHERS	Treadmill / 2D Echo ✓	IND129584114690			
18	OTHERS	physical examination	IND129584115279			

19	US	ULTRASOUND ABDOMEN	IND129584115292			
20	OTHERS	EYE CHECKUP	IND129584117756			
21	X-RAY	X RAY CHEST	IND129584118659			
22	ECG	ELECTROCARDIOGRAM ECG	IND129584118721			
23	OTHERS	Consultation Physician	IND129584118736			

Ht - 165
Wt - 66.9
BP - 130/84
Pulse - 72
Waist - 1.07
Hgt - 97

Registered By
(PREETHA.R)

NAME:
DATE: 26/02/2022 13:04
No. 0484
CHAROPS CR-1
0.00.10A

REF: VD: 12.00
Cyl. Form: MIX

<R> SPH CYL AX
-0.75 -1.00 177
-0.75 -1.00 177
-0.75 -1.00 176

AVG: -0.75 -1.00 176
S.E: -1.25

<L> SPH CYL AX
+0.00 -1.25 17
+0.00 -1.25 16
+0.00 -1.00 16

AVG: +0.00 -1.25 16
S.E: -0.63

PD: 62mm

SRI PARVATHI OPTICS
8618385220 9901569756



ಶ್ರೀ ಪಾರ್ವತಿ ಆಪ್ಟಿಕ್ಸ್

Mahesh
Mob:8618385220
9901569756

SRI PARVATHI OPTICS

Multi Branded Optical Store

Computerized Eye Testing & Spectacles Clinic

333.8th Main 5th Cross Near Cambridge & Miranda School HAL 3rd Stage
Behind Vishveshvariah Park New Thippasandra, Bangalore - 560075,
Email: parvathiopticals@gmail.com

SPECTACLE PRESCRIPTION

Name: Rajee Meher

No. 238

Mobil No: 9853208565

Date: 26-02-2022

Age / Gender 33yrs/M

Ref. No.

	RIGHT EYE				LEFT EYE			
	SPH	CYL	AXIS	VISION	SPH	CYL	AXIS	VISION
DISTANCE	-0.75	-	-	6/6	plano			6/6
NEAR								

PD 62mm

Advice to use glasses for:

- DISTANCE FAR & NEAR READING COMPUTER PURPOSE

We Care Your Eyes

Customer Name	MR.RAJU MEHER	Customer ID	MED410999468
Age & Gender	33Y/MALE	Visit Date	26/02/2022
Ref Doctor	MediWheel		

2 D ECHOCARDIOGRAPHIC STUDY

M mode measurement:

AORTA		: 2.1cms
LEFT ATRIUM		: 3.2cms
AVS		: ---
LEFT VENTRICLE	(DIASTOLE)	: 4.3cms
	(SYSTOLE)	: 2.9cms
VENTRICULAR SEPTUM	(DIASTOLE)	: 0.9cms
	(SYSTOLE)	: 1.2cms
POSTERIOR WALL	(DIASTOLE)	: 0.9cms
	(SYSTOLE)	: 1.2cms
EDV		: 84ml
ESV		: 31ml
FRACTIONAL SHORTENING		: 34%
EJECTION FRACTION		: 63%
EPSS		: ---
RVID		: 1.8cms

DOPPLER MEASUREMENTS:

MITRAL VALVE	: 'E' 0.67 m/s	'A' 0.50 m/s	NO MR
AORTIC VALVE	: 1.19 m/s		NO AR
TRICUSPID VALVE	: 'E' 1.95 m/s	'A' - m/s	NO TR
PULMONARY VALVE	: 0.87 m/s		NO PR



Customer Name	MR.RAJU MEHER	Customer ID	MED110999468
Age & Gender	33Y/MALE	Visit Date	26/02/2022
Ref Doctor	MediWheel		

2D ECHOCARDIOGRAPHY FINDINGS:

Left ventricle : Normal size, Normal systolic function.
No regional wall motion abnormalities.

Left Atrium : Normal.

Right Ventricle : Normal.

Right Atrium : Normal.

Mitral valve : Normal, No mitral valve prolapsed.

Aortic valve : Normal, Trileaflet.

Tricuspid valve : Normal.

Pulmonary valve : Normal.

IAS : Intact.

IVS : Intact.

Pericardium : No pericardial effusion.

IMPRESSION:

- NORMAL SIZED CARDIAC CHAMBERS.
- NORMAL LV SYSTOLIC FUNCTION. EF: 63%.
- NO REGIONAL WALL MOTION ABNORMALITIES.
- NORMAL VALVES.
- NO CLOTS / PERICARDIAL EFFUSION / VEGETATION.

DR. K.S. SUBRAMANI MBBS, MD, DM (CARDIOLOGY) FESC, FICC
SENIOR CONSULTANT INTERVENTIONAL CARDIOLOGIST
Kss/an

SUBRAMANI.K.S
Consultant Cardiologist
KMC REG No : 46604
Clumax-Diagnostics

Note:

- * Report to be interpreted by qualified medical professional.
- * To be correlated with other clinical findings.
- * Parameters may be subjected to inter and intra observer variations.



Customer Name	MR.RAJU MEHER	Customer ID	MED110999468
Age & Gender	33Y/MALE	Visit Date	26/02/2022
Ref Doctor	MediWheel		

ABDOMINO-PELVIC ULTRASONOGRAPHY

LIVER is normal in shape, size and has uniform echopattern. No evidence of focal lesion or intrahepatic biliary ductal dilatation. Hepatic and portal vein radicals are normal.

GALL BLADDER shows normal shape and has clear contents. Gall bladder wall is of normal thickness. CBD is of normal calibre.

PANCREAS has normal shape, size and uniform echopattern. No evidence of ductal dilatation or calcification.

SPLEEN shows normal shape, size and echopattern. Spleen measures 9.3cms in long axis and 2.4cms in short axis. No demonstrable Para -aortic lymphadenopathy.

KIDNEYS move well with respiration and have normal shape, size and echopattern. Cortico- medullary differentiations are well madeout. No evidence of calculus or hydronephrosis.

The kidney measures as follows:

	Bipolar length (cms)	Parenchymal thickness (cms)
Right Kidney	9.4	1.1
Left Kidney	11.2	1.3

URINARY BLADDER is partially distended. It has clear contents. No evidence of diverticula.

PROSTATE shows normal shape, size and echopattern. It measures 3.5 x 3.1 x 3.5cms (Vol:20cc).

No evidence of ascites / pleural effusion.

IMPRESSION:

➤ **NO SIGNIFICANT ABNORMALITY.**

DR. H.K. ANAND
CONSULTANT RADIOLOGISTS
MS/vp


DR. MEERA S



Name	RAJU MEHER	Customer ID	MED110999468
Age & Gender	33Y/M	Visit Date	Feb 26 2022 9:21AM
Ref Doctor	MediWheel		

X - RAY CHEST PA VIEW

Bilateral lung fields appear normal.

Cardiac size is within normal limits.


Bilateral hilar regions appear normal.

Bilateral domes of diaphragm and costophrenic angles are normal.

Visualised bones and soft tissues appear normal.

IMPRESSION:

No significant abnormality detected.



DR. H.K. ANAND

DR. SHWETHA S

DR. CHARUL

DR. APARNA

CONSULTANT RADIOLOGISTS



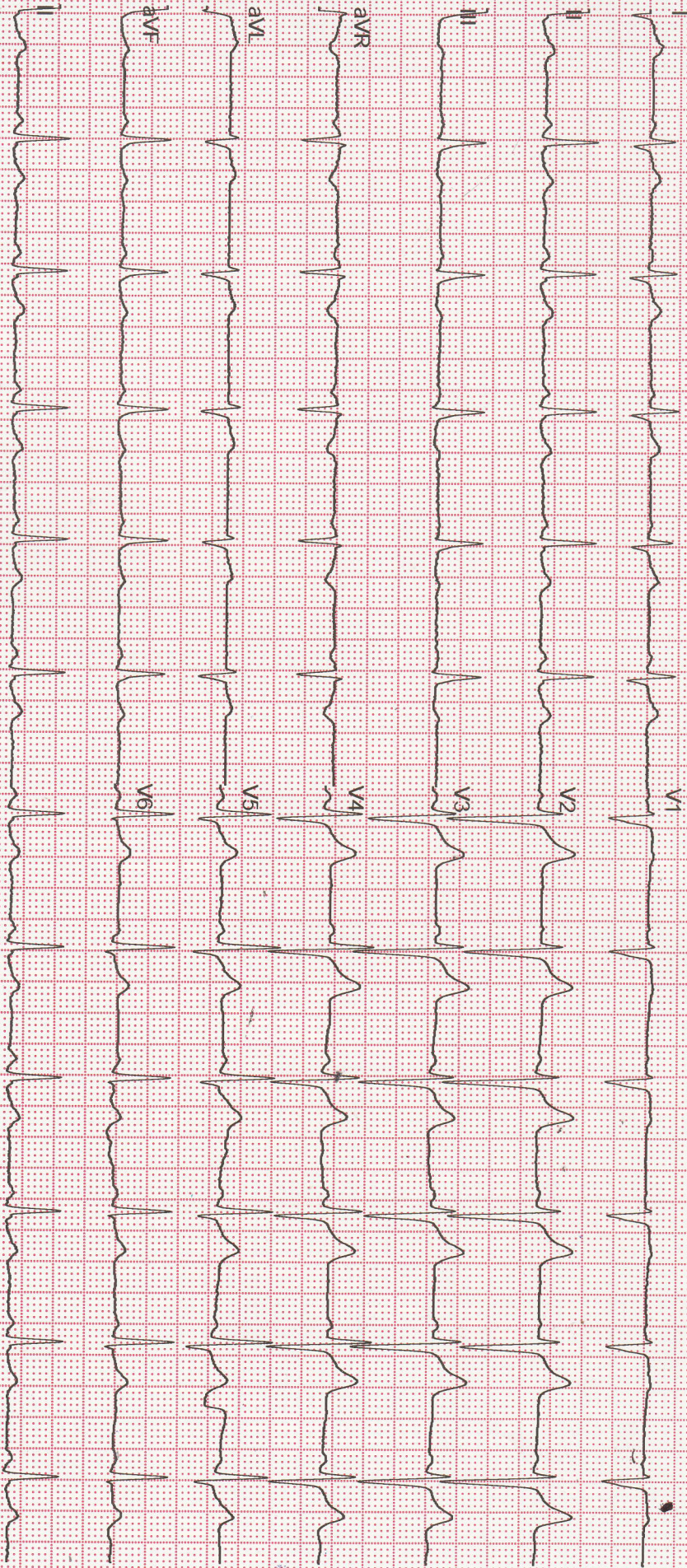


A22012361-P
MR. RAJU MEHER(33Y/M)

26.02.2022 10:33:53
CLUMAX DIAGNOSTICS
THIRUPASANDRA
BANGALORE

70 bpm
-- / -- mmHg

QRS 98 ms
QT/QTcBaz 384 / 414 ms
PR 118 ms
P 82 ms
RR/PP 858 / 857 ms
P/ORS/T 53 / 74 / 23 degrees



Normal ECG

SUBRAMANICK S
MD DPL (CARDIOLOGY)
Consultant Cardiologist
KMC REG NO: 46604
Clumax Diagnostics