



# डॉ. सविता क्लिनिक

34, भूतल, मोहिनी अदिति आर्केड, शाहपुरा मस्जिद के पास  
भरत नगर रोड, ई-7/194, अरेरा कॉलोनी, भोपाल - 462038

Mob. : 8989649694, 9516333619

Clinic Registration : CL/5392/Jun/2017

PNDT Registration : MPPCPNDT/BPL/2017/206



Name : Mrs. Shanti' 56/Female Age.....YRS./F

R/B Health check-up No. .... Date 2/6/2022

## WHOLE ABDOMES ULTRASOUND REPORT

### Indication:

Liver appears normal in size and shape with normal outline. ~~Normal/~~ increased parenchymal echogenicity is noted. No E/O focal lesion/ IHBR dilatation is seen. Hepatic veins and portal veins appear normal. gr II fatty liver.

No E/O subdiaphragmatic Collection.

Gall Bladder is physiologically well distended. No. E/O echogenic foci in GB lumen. GB wall is normal / ~~thickened~~. No E/O pericholecystic collection. Common duct reveals normal course and caliber.

~~Pancreas appear normal in size, shape and echo texture with smooth contour. No peripancreatic pathology seen. (Not seen due to gases)~~

Spleen is normal in size and echo texture.

IVC and aorta appear to be normal.

No evidence of lymphadenopathy is noted.

No evidence of free fluid is noted.

Right Kidney is normal in size. size, shape and position. Corticomedullary differentiation (CMD) is well maintained. Normal cortical thickness is noted. No E/O hydronephrosis or calculus is noted.

PTO

Dr. P. Savita, MD

MBBS, MD (O&G) Reg. No. 9971

स्त्री रोग विशेषज्ञ

Dr. Jayant Yadav, MD

MBBS, MD (Radiologist) Reg. No. 4166

रेडियोलॉजिस्ट



Left Kidney is normal in size, shape and position. CMD is well maintained. Normal cortical thickness is noted. No E/O hydronephrosis or calculus is noted.

Urinary Bladder is well distended (physiological). its contents are echo free. No E/O bladder wall thickening is noted. Post-void residue is insignificant.

~~Prostate is normal in size. Shape and echo texture with smooth outline. No E/O focal lesion is noted.~~

Uterus is ante/~~retro~~ verted and normal in size, shape and echotexture with smooth outline. No E/O focal lesion is noted. Endometrial echo appear normal. Cervical and vaginal shadows appear normal. *menopausal uterus*

*linear & thin*

Right Ovary appears ~~enlarged~~ / Normal in size, shape and echo texture.

*Small.*

Left Ovary appears ~~enlarged~~ / Normal in size, shape and echo texture.

Impression : Normal study. *Grade II fatty liver.*

### Advised clinical Correlation.

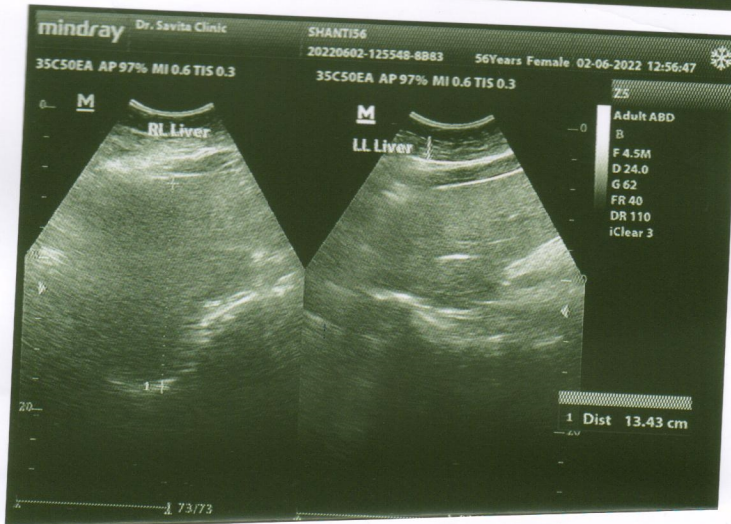
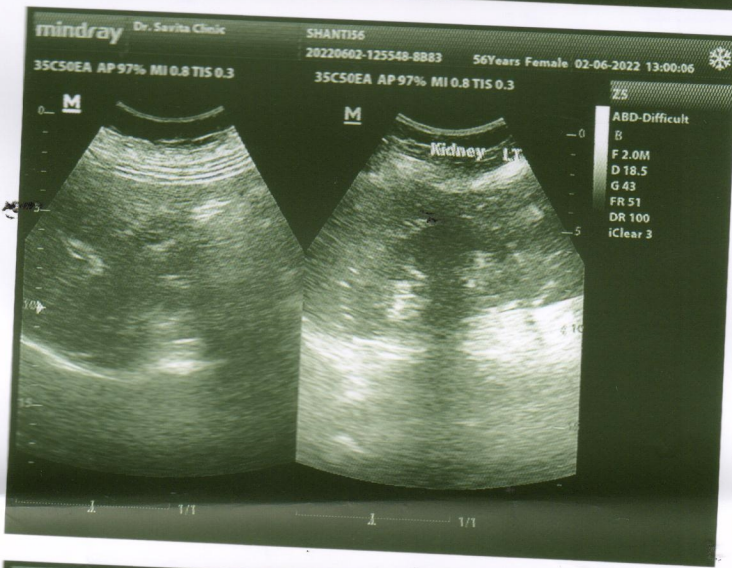
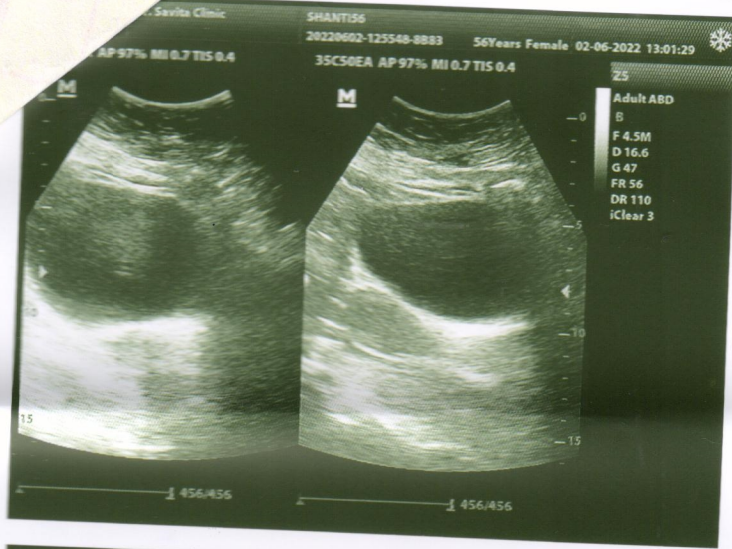
*Real*

Dr. P. Savita, MD  
MBBS, MD (O&G) Reg. No. 9971  
स्त्री रोग विशेषज्ञ

Dr. Jayant Yadav, MD  
MBBS, MD (Radiologist) Reg. No. 4166  
रेडियोलॉजिस्ट



aintained.  
alculus is







# दिवकर डायग्नोस्टिक सेंटर

E-7/636, पंजाब नेशनल बैंक के पास, मैन रोड, अरेरा कॉलोनी भोपाल ( म.प्र. )


फोन: 0755-2465288, 0755-3520545 मो: 9826340190

Pt Name :	Mrs. Shanti Mandral
Age :	57/F
Ref.By :	BOB
Lab. No. :	231
Date :	02/06/2022

## EXAMINATION OF BLOOD

TEST	RESULT	NORMAL VALUE
Haemoglobin	10.9mgs%	Female 12-16gms%, Male 14-18gms%
Red Cell count	4.4	4.5-5.6 million /cumm
Platelate Count	1.92	1.5-5.6 Lac/cumm
Leucocytes per.cu.mm	6100/cumm	5000-11000/cumm
Neutrophils	55%	50-70%
Lymphocytes	32%	20-40%
Eosinophils	09%	0-7%
Monocytes	04%	2-8%
PCV	36.5	37-47
MCV	74.3	76-96
MCH	28.9	27-32
MCHC	31.0	31-35
ESR	12	Male 0-9, Female 0-20mm/FHR
Blood Group	"B" Positive	By Slide Method
S.Bilirubin(Total)	0.74	0.2-1.0mg/dl
Direct	0.30	0.0-0.25mg/dl
Indirect	0.44	
SGOT	18.9	5-35U/L
SGPT	25.0	8-40U/L
Alk Phosphatase	8.8	3-13 KA units
S. Protein(Total)	6.8	6.0-8.0mg%
Albumin	4.0	3.7-5.3mg%
Globulin	3.2	1.5 to 3.5 mg%
AG Ratio	1.25	1.-2.0
Blood Urea Nitrogen (BUN)	12.8	7-20 mg/dl
S.Creatine	0.90	0.5-1.4mg/dl
Uric Acid	4.9	4.8 to 7.5 mg/dl
Calcium	8.3	8.5-10.5 gm/dl
GGTP	28.5	5-35 UL/dl
Fasting Blood Sugar	87.8	up to 150mg/dl
Total Serum Cholesterol	152.5	100-250 mg%
Serum Triglyceride	120.6	Up to 160 mg%
Serum Cholesterol HDL	39.2	Up to 65 mg%
Serum Cholesterol LDL	89.2	Up to 125 mg%
VLDL	24.1	Up to 30 mg%
TC/HDL Ratio	3.28	Bellow 5
Glycosylated Hemoglobin HBA1c	5.6	Below - 6.0 % -Non Diabetic control 6-7 % -Excellent control Above- 8 % -Poor control

All test have technical limitation. Collaborative clinic pathological interpretation is mandatory. In case of disparity test may be repeated immediately. Typographical mistakes should be get correct instantly. This report is not valid for medico legal purpose.



Pathologist

M. Agarwal  
MBBS, Ed  
Insultant Pathologist





# दिवकर डायग्नोस्टिक सेंटर

E-7/636, पंजाब नेशनल बैंक के पास, मैन रोड, अरेा कॉलोनी भोपाल ( म.प्र. )

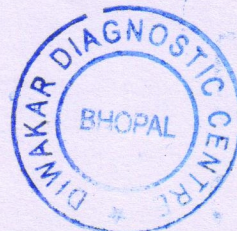
फोन: 0755-2465288, 0755-3520545 मो: 9826340190

Pt Name :	Mrs. Shanti Mandral
Age :	57/F
Ref.By :	BOB
Lab. No. :	231
Date :	02/06/2022

## URINE ANALYSIS

<u>A. PHYSICALEXAMINATION</u>		<u>C. MICROSCOPIEXAMINATION</u>	
1. Colour	Yellow	Pus Cells	3-4/HPF
2. Appearance	Clear	R.B.C.	Nil
3. Specific Gravity	Q.N.S.	Epithelial Cell	occ/HPF
<u>B. CHEMICAL EXAMINATION</u>		Cast	Nil
1.Reaction	Acidic	Crystals(Cal.Oxa)	Nil
2.Albumin	Absent	Bacteria	Nil
3.Sugar	Nil	Amorphous	Nil
4.Bile Salts	Absent	T. Vaginitis	Nil

URINE COTININE	Negative	By Card method
----------------	----------	----------------




Dr. B. M. Agarwal  
MBBS, DCP  
Consultant Pathologist





आधार - आम आदमी का अधिकार

6406 9442 6432



*Dr. B. M. Agarwal*  
MBBS, DCP  
Consultant Pathologist

शान्ति मन्द्रा







# दिवकर डायग्नोस्टिक सेंटर

E-7/636, पंजाब नेशनल बैंक के पास, मैन रोड, अरेरा कॉलोनी भोपाल ( म.प्र. )

फोन: 0755-2465288, 0755-3520545 मो: 9826340190

Pt Name :	Mrs. Shanti Mandral
Age :	57/F
Ref.By :	BOB
Lab. No. :	231
Date :	02/06/2022


## EXAMINATION OF BLOOD

### Thyroid profile

<u>TEST</u>	<u>RESULT</u>	<u>NORMAL VALUE</u>
T3 - TOTAL	110.6	82-213 ng/dL
T4 - TOTAL	8.35	6.09-12.23 ug/dL
THYROID STIMULATING HORMONE (TSH)	3.10	0.45-4.25 ul/mL

#### Interpretation:

TSH Levels will be elevated in primary hypothyroidism, TSH levels will be low in Hyperthyroidism there is decreased production of thyroid hormones by the thyroid hence the person may experience symptoms such as weight gain, constipation, cold intolerance and fatigue. Iodine deficiency and Hashimoto thyroiditis is the most common cause of hypothyroidism It makes Thyroid stimulating hormone. If TSH levels are abnormally high it could mean you have an underactive thyroid or hypothyroidism.

  
Dr. B. M. Agarwal  
MBBS, DCP  
Consultant Pathologist

All test have technical limitation. Collaborative clinic pathological interpretation is mandatory. In case of disparity test may be repeated immediately. Typographic mistakes should be get correct instantly. This report is not valid for medico legal purpose







# दिवाकर डायग्नोस्टिक सेंटर

E-7/636, पंजाब नेशनल बैंक के पास, मैन रोड, अरेरा कॉलोनी भोपाल ( म.प्र. )

फोन: 0755-2465288, 0755-3520545 मो: 9826340190

Pt Name :	Mrs. Shanti Mandral
Age :	57/F
Ref.By :	BOB
Lab. No. :	231
Date :	02/06/2022
Skigram	X Ray Chest PA View
Radiologist	Dr. B.M.Agarwal MD (Radiology)

## REPORT

Tricia Central

Thoracic cage normal

Both Lungs Field Clear.

Both hilers normal

Cardiac border normal

Both cp angles clear


Both domes and diaphragm normal

## IMPRESSION

\*\*\*\*\*

-NO CARDIO PULMONARY PATHOLOGY

-COORELATE WITH CLINICAL FINDINGS.



*Dr. B. M. Agarwal*  
MD, Radiology  
Consultant Radiologist  
Radiologist



**Allengers Global Healthcare Pvt Ltd.**

121 / MRS. SHANTI MANDRAI / 57 Yrs / F / 150Cms / 74Kgs.

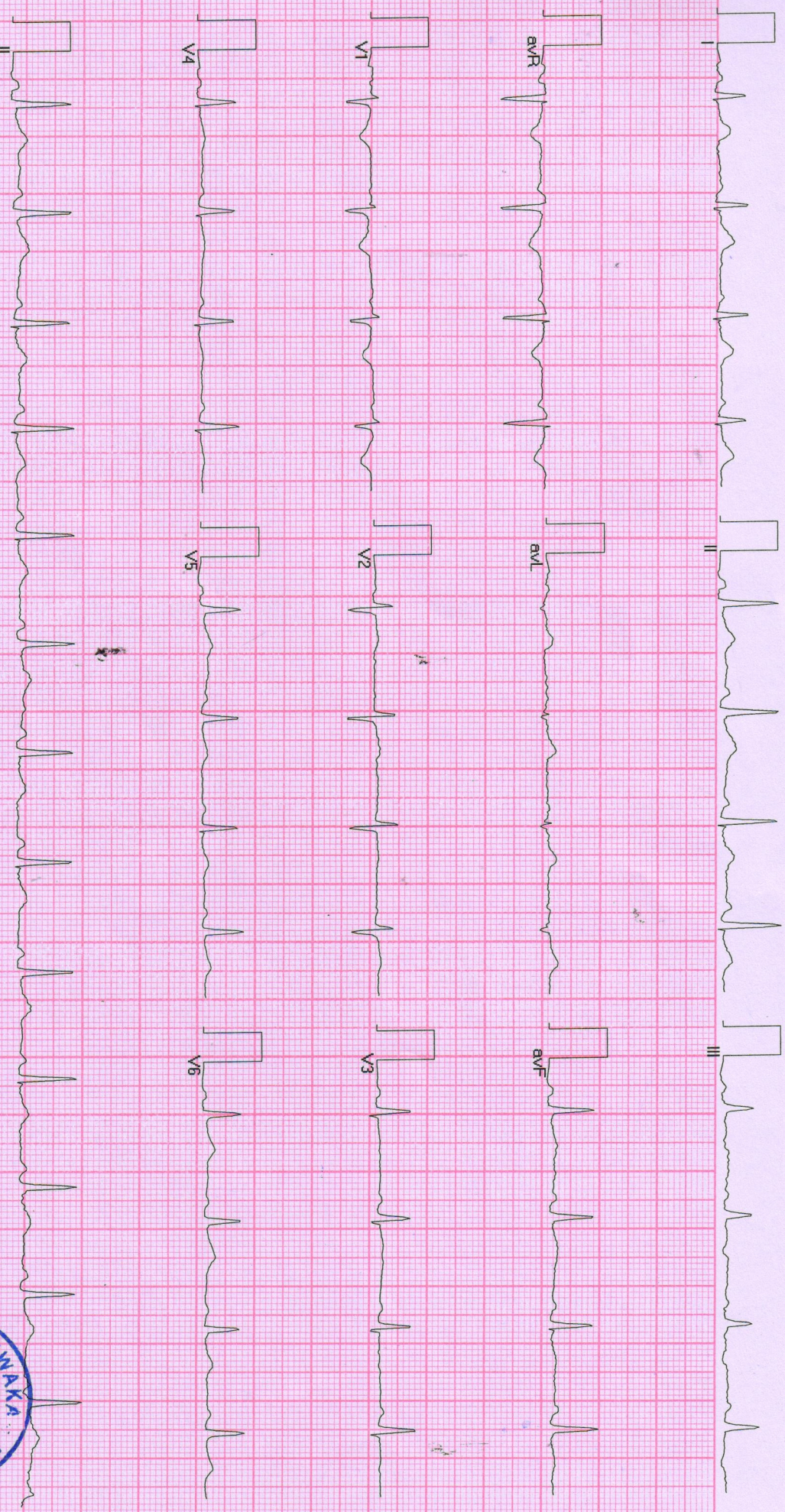
Heart Rate : 80 bpm / Tested On : 02-Jun-22 10:17:52 / HF 0.05 Hz - LF 100 Hz / Notch 50 Hz / Sn 1.00 Cm/mV / Sw 25 mm/s

/ Refd By: BOB

ECG



**BPL-DYNATRAC**



श्री शर्मा

Allengers ECG (Piscos)(PIS213180317)







# Diwakar Diagnostic Centre

पैथोलोजी | टी.एँम.टी. | एक्स-रे | ई.सी.जी. | एको कार्डियो ग्राफी | सोनोग्राफी





BINX101N

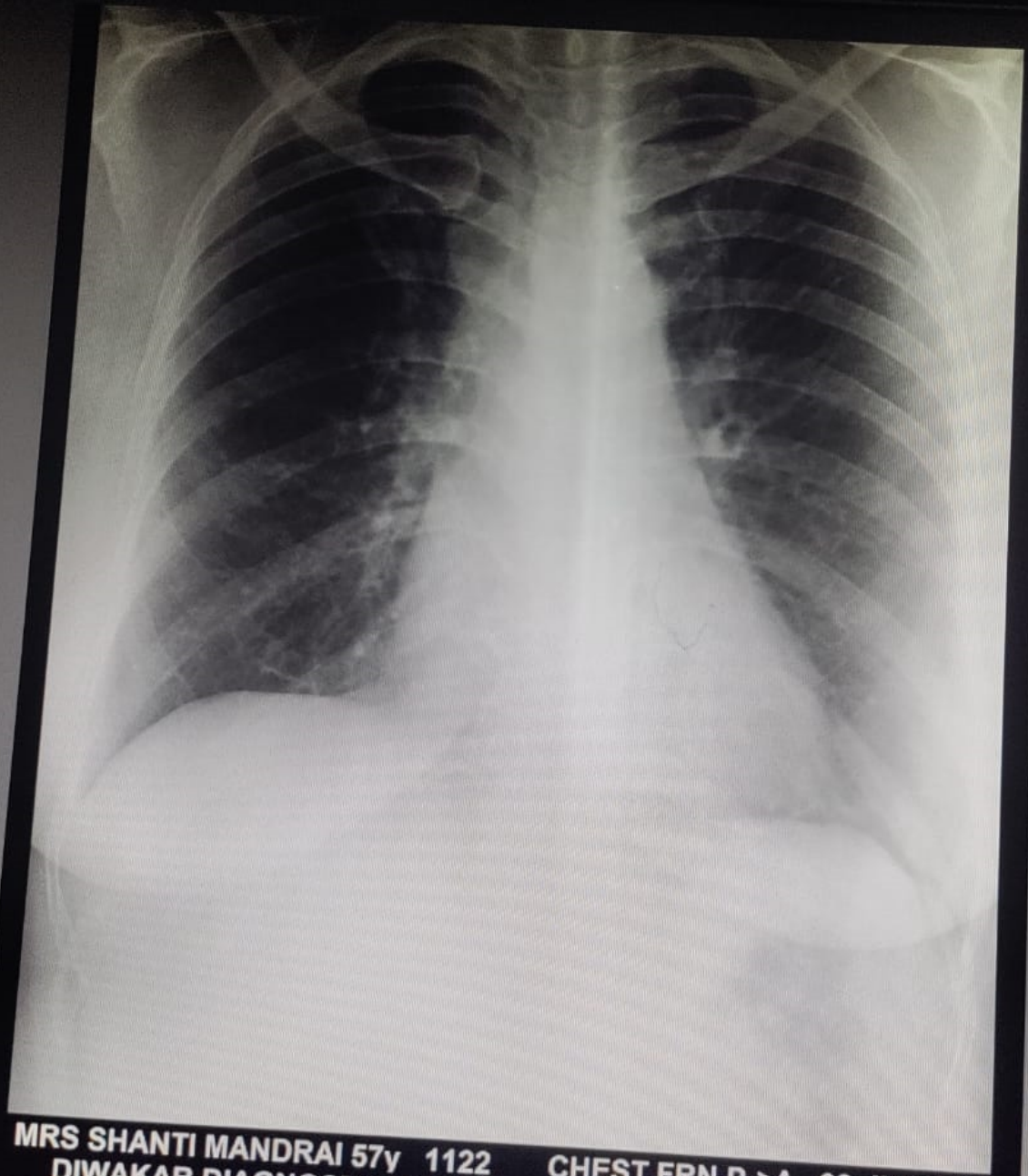
PORTRAIT

ve DICOM

Save

Print

Close



MRS SHANTI MANDRAI 57y 1122 CHEST,FRN P->A 02-JUN-22  
DIWAKAR DIAGNOSTIC CENTRE , ARERA COLONY ,BHOPAL

Shot on OnePlus

By 🤖