



As

Ear - B/L TM intact -  
Nose - NAD  
Throat - NAD.

Vitals :

Chief Complaints :

BP - 100/60 mm

HR - 55 / min

HT - 5'4"

H/O Present Illness :

Past History :

Investigation :

Drug Allergies : (if any)

Treatment :

28/10/23





c/c: Routine dental checkup.

**Vitals :**

Chief Complaints : O/E: Root stumps  $\frac{\quad}{\quad} / 8$

Caries  $\frac{57}{7} / 7$

H/O Present Illness :

Plaque / Calculus ++ / ++

Past History :

Adv. extraction  $\frac{\quad}{\quad} / 8$

Restorations  $\frac{57}{7} / 7$

**Investigation :**

Drug Allergies : (if any)

Sealing & Polishing.

Treatment :

*[Handwritten signature]*





Preeti Sharma 54y/o/f 28/10/2023

Vitals :

Chief Complaints :

PA 2 @ (R) @ paronychia  
Dermoid cyst  
came for health  
check up

CA 18/10/2023  
CA 5/30 days  
@ flow  
28/10/2023  
W/O W/A

H/O Present Illness :

Breast - NAD

PIA - soft

Past History :

PIA - Co hypochromic  
discharge @

Investigation :

Drug Allergies : (if any)

Treatment :

PIA - Oteron 10  
AIO  
Ble fornicies  
pel  
No formal  
treatment

Oteron 210  
6.1 x 4.2 x 4.2 cm  
Rou bulky  
41 x 30 mm  
Dermoid cyst  
@ Nulaf.  
vacuolanty

IP

- PAPS  
- HbS - 15  
- CA 125, CEA,  
AFP, CAH,  
Beta HCG,  
CA 19-9



Gurgaon

Q Block South City 11, Sohna Road, Main Sector-47, Gurgaon, Haryana Ph.: 0124-4900000 Fax : 0124-2218733  
E-mail : parkmedcenters@gmail.com

● West Delhi ● South Delhi ● Faridabad ● Panipat ● Karnal



1

① TAB ZENOLUX 20MG TWICE  
DAILY AFTER MEALS X 7 DAYS

② TAB PANTOP 40MG EMPTY  
STOMACH IN MORNING X 7 DAYS

③ CANBOLT CE PERRARY FOR VAGINAL  
INSERTION AT BED TIME X  
6 NIGHTS

9000



689423

Ms. Leekati Sharma  
34/f

ROUTINE checkup

**Vitals :**

**Chief Complaints :**

VV } 6/6  
        } 6/6 unadeled

**H/O Present Illness :**

MV } M6  
        } M6

MCT } 15  
        } 14

**Past History :**

**Investigation :**

**Drug Allergies : (if any)**

Colony Urison - Normal BE

**Treatment :**

fundus Examination - Normal

*[Signature]*  
PARK HOSPITAL  
SURGEON



PREETI Sharma

Dermatology

28/10/23

NO skin lesions are present

Vitals :

Chief Complaints :

H/O Present illness :

Jan :-

Past History :

No intervention required at present

Investigation :

Drug Allergies : (if any)

&

Treatment :





### DEPARTMENT OF BIOCHEMISTRY

<b>Patient Name</b> :	Ms. PREETI SHARMA	<b>Bill Date</b> :	28/10/2023
<b>MR No</b> :	689423	<b>Reporting Date</b> :	28/10/2023
<b>Age/Sex</b> :	34 Years 8 Months 15 Days / Female	<b>Sample ID</b> :	208369
<b>Type</b> :	OPD	<b>Bill/Req. No.</b> :	24192070
<b>TPA/Corporate</b> :	MEDIWHEEL PVT LTD	<b>Ref Doctor</b> :	Dr.RMO

Test	Result	Bio. Ref. Interval	Units	Method
<b>BLOOD SUGAR FASTING</b>				
PLASMA GLUCOSE FASTING	85	60 - 110	mg/dl	GOD TRINDERS
null				

\*\*\*\* END OF THE REPORT \*\*\*\*



Sample no.

**Dr. SONIA KUMARI**  
MBBS, MD (PATHOLOGY) Gold medalist

**Dr. ISHA RASTOGI**  
MD, MBBS MICROBIOLOGY  
CONSULTANT CLINICAL MICROBIOLOGIST



USER NM      ARUN



(This is only professional opinion and not the diagnosis, please correlate clinically)

Q Block, South City -II, Sohna Road, Sector-47, Gurgaon, Haryana Page 1 of 1

Ph.: 0124-4900000 (100 Lines), Toll Free No. : 1800-102-6767, Mob.: 62 62 82 82 35, Email: [customercare@parkhospital.in](mailto:customercare@parkhospital.in)

**PARK GROUP OF HOSPITALS** : West Delhi - Gurugram - Faridabad - Sonapat - Panipat - Karnal - Ambala - Patiala - Behror - Jaipur





**DEPARTMENT OF BIOCHEMISTRY**

<b>Patient Name</b> :	Ms. PREETI SHARMA	<b>Bill Date</b> :	28/10/2023
<b>MR No</b> :	689423	<b>Reporting Date</b> :	28/10/2023
<b>Age/Sex</b> :	34 Years 8 Months 15 Days / Female	<b>Sample ID</b> :	208369
<b>Type</b> :	OPD	<b>Bill/Req. No.</b> :	24192070
<b>TPA/Corporate</b> :	MEDIWHEEL PVT LTD	<b>Ref Doctor</b> :	Dr.RMO

Test	Result	Bio. Ref. Interval	Units	Method
------	--------	--------------------	-------	--------

**BLOOD SUGAR 2 HR. PP**

BLOOD SUGAR P.P.	103.45	80 - 150	mg/dl	
------------------	--------	----------	-------	--

null

\*\*\*\*\* END OF THE REPORT \*\*\*\*\*



Sample no.

*[Signature]*

**Dr. SONIA KUMARI**  
MBBS, MD (PATHOLOGY) Gold medalist

**Dr. ISHA RASTOGI**  
MD, MBBS MICROBIOLOGY  
CONSULTANT CLINICAL MICROBIOLOGIST



USER NM      ARUN



(This is only professional opinion and not the diagnosis, please correlate clinically)

Q Block, South City -II, Sohna Road, Sector-47, Gurgaon, Haryana Page 1 of 1

Ph.: 0124-4900000 (100 Lines), Toll Free No. : 1800-102-6767, Mob.: 62 62 82 82 35, Email: [customercare@parkhospital.in](mailto:customercare@parkhospital.in)

**PARK GROUP OF HOSPITALS** : West Delhi - Gurugram - Faridabad - Sonapat - Panipat - Karnal - Ambala - Patiala - Behror - Jaipur





## DEPARTMENT OF PATHOLOGY

**Patient Name** : Ms. PREETI SHARMA  
**MR No** : 689423  
**Age/Sex** : 34 Years 8 Months 15 Days / Female  
**Type** : OPD  
**TPA/Corporate** : MEDIWHEEL PVT LTD

**Bill Date** : 28/10/2023  
**Reporting Date** : 28/10/2023  
**Sample ID** : 208369  
**Bill/Req. No.** : 24192070  
**Ref Doctor** : Dr.RMO


Test	Result	Bio. Ref. Interval	Units	Method
<b>URINE ROUTINE AND MICROSCOPY</b>				
<b>PHYSICAL CHARACTERSTICS</b>				
QUANTITY	30ml	5 - 100	ml	
COLOUR	Pale Yellow	Pale Yellow		Vishal
TURBIDITY	Clear	clear		
SPECIFIC GRAVITY	1.015	1.000-1.030		urinometer
PH - URINE	6.5	5.0 - 9.0		PH PAPER
<b>CHEMICAL EXAMINATION-1</b>				
UROBILINOGEN	Negative	NIL		Ehrlich
URINE PROTEIN	Absent	NIL	mg/dl	Protein error indicator
BLOOD	NIL	NIL		
URINE BILIRUBIN	NIL	NIL		
GLUCOSE	NIL	NIL	mg/dL	GOD-POD/Benedicts
URINE KETONE	NIL	NIL		SOD.
<b>MICRO.EXAMINATION</b>				
PUS CELL	2-4	0-5	cells/hpf	Microscopic
RED BLOOD CELLS	Not Seen	0-2	cells/hpf	
EPITHELIAL CELLS	1-2	0-5	cells/hpf	
CASTS	NIL	NIL	/lpf	
CRYSTALS	NIL	NIL	/hpf	
OTHER	NIL			

null

\*\*\*\*\* END OF THE REPORT \*\*\*\*\*



Sample no.

  
**Dr. SONIA KUMARI**  
 MBBS, MD (PATHOLOGY) Gold medalist

**Dr. ISHA RASTOGI**  
 MD, MBBS MICROBIOLOGY  
 CONSULTANT CLINICAL MICROBIOLOGIST



USER NM ARUN



MC - 4830

(This is only professional opinion and not the diagnosis, please correlate clinically)

Q Block, South City -II, Sohna Road, Sector-47, Gurgaon, Haryana

Page 1 of 1

Ph.: 0124-4900000 (100 Lines), Toll Free No. : 1800-102-6767, Mob.: 62 62 82 82 35, Email: [customercare@parkhospital.in](mailto:customercare@parkhospital.in)

**PARK GROUP OF HOSPITALS** : West Delhi - Gurugram - Faridabad - Sonapat - Panipat - Karnal - Ambala - Patiala - Behror - Jaipur

the health care providers

the health care providers



**DEPARTMENT OF HAEMATOLOGY**

Patient Name : Ms. PREETI SHARMA  
 MR No : 689423  
 Age/Sex : 34 Years 8 Months 15 Days / Female  
 Type : OPD  
 TPA/Corporate : MEDIWHEEL PVT LTD

Bill Date : 28/10/2023  
 Reporting Date : 28/10/2023  
 Sample ID : 208369  
 Bill/Req. No. : 24192070  
 Ref Doctor : Dr.RMO

Test	Result	Bio. Ref. Interval	Units	Method
------	--------	--------------------	-------	--------

**BLOOD GROUPING AND RH FACTOR**

BLOOD GROUP	" B " RH POSITIVE			ABO/Rh (D) SLIDE
Result	Result	Bio. Ref. Interval	Units	Method
Result	Result	Bio. Ref. Interval	Units	Method

null

\*\*\*\*\* END OF THE REPORT \*\*\*\*\*



Sample no.

Dr. SONIA KUMARI  
MBBS, MD (PATHOLOGY) Gold medalist

Dr. ISHA RASTOGI  
MD, MBBS MICROBIOLOGY  
CONSULTANT CLINICAL MICROBIOLOGIST



USER NM

GAURAV



(This is only professional opinion and not the diagnosis, please correlate clinically)

Q Block, South City -II, Sohna Road, Sector-47, Gurgaon, Haryana

Page 1 of 1

Ph.: 0124-4900000 (100 Lines), Toll Free No. : 1800-102-6767, Mob.: 62 62 82 82 35, Email: [customercare@parkhospital.in](mailto:customercare@parkhospital.in)

**PARK GROUP OF HOSPITALS** : West Delhi - Gurugram - Faridabad - Sonapat - Panipat - Karnal - Ambala - Patiala - Behror - Jaipur





## DEPARTMENT OF HAEMATOLOGY

Patient Name : Ms. PREETI SHARMA  
 MR No : 689423  
 Age/Sex : 34 Years 8 Months 15 Days / Female  
 Type : OPD  
 TPA/Corporate : MEDIWHEEL PVT LTD

Bill Date : 28/10/2023  
 Reporting Date : 28/10/2023  
 Sample ID : 208369  
 Bill/Req. No. : 24192070  
 Ref Doctor : Dr.RMO

Test	Result		Bio. Ref. Interval	Units	Method
<b>CBC</b>					
HAEMOGLOBIN	11.4	L	12 - 15	gm/dL	COLORIMETRY
TOTAL LEUCOCYTE COUNT	4380		4000-11000	/ $\mu$ L	LASER FLOW
<b>DIFFERENTIAL COUNT</b>					
NEUTROPHILS	65		40.0 - 70.0	%	FLOW CYTOMETRY
LYMPHOCYTES	25		20.0 - 40.0	%	FLOW CYTOMETRY
MONOCYTES	08		3.0 - 8.0	%	FLOW CYTOMETRY
EOSINOPHILS	02		0.5 - 5.0	%	FLOW CYTOMETRY
BASOPHILS	00		0.0 - 2.0	%	FLOW CYTOMETRY
RED BLOOD CELL COUNT	3.6		3.5 - 5.5	millions/ $\mu$ L	ELECTRICAL
PACKED CELL VOLUME	31.7	L	35.0 - 50.0	%	ELECTRICAL
MEAN CORPUSCULAR VOLUME	85.8		83 - 101	fL	ELECTRICAL
MEAN CORPUSCULAR HAEMOGLOBIN	30.9		27 - 31	Picogrammes	CALCULATED
MEAN CORPUSCULAR HB CONC	36.0		33 - 37	g/dl	CALCULATED
PLATELET COUNT	184		150 - 450	thou/ $\mu$ L	ELECTRICAL
RDW	14.4		11.6 - 14.5	%	CALCULATED
SAMPLE TYPE FOR C.B.C	Whole Blood EDTA				

null

\*\*\*\*\* END OF THE REPORT \*\*\*\*\*



Sample no.

Dr. SONIA KUMARI  
 MBBS, MD (PATHOLOGY) Gold medalist

Dr. ISHA RASTOGI  
 MD, MBBS MICROBIOLOGY  
 CONSULTANT CLINICAL MICROBIOLOGIST



USER NM ARUN



MC-4830

(This is only professional opinion and not the diagnosis, please correlate clinically)

Q Block, South City -II, Sohna Road, Sector-47, Gurgaon, Haryana

Page 1 of 1

Ph.: 0124-4900000 (100 Lines), Toll Free No. : 1800-102-6767, Mob.: 62 62 82 82 35, Email: [customercare@parkhospital.in](mailto:customercare@parkhospital.in)

PARK GROUP OF HOSPITALS : West Delhi - Gurugram - Faridabad - Sonapat - Panipat - Karnal - Ambala - Patiala - Behror - Jaipur





## DEPARTMENT OF HAEMATOLOGY

**Patient Name** : Ms. PREETI SHARMA  
**MR No** : 689423  
**Age/Sex** : 34 Years 8 Months 15 Days / Female  
**Type** : OPD  
**TPA/Corporate** : MEDIWHEEL PVT LTD

**Bill Date** : 28/10/2023  
**Reporting Date** : 28/10/2023  
**Sample ID** : 208369  
**Bill/Req. No.** : 24192070  
**Ref Doctor** : Dr.RMO

Test	Result	Blo. Ref. Interval	Units	Method
<b>ESR (WESTERGREN)</b>				
E.S.R. - I HR.	35	H 0 - 20	mm/Hr.	Westergren


**Note :** Note

1. C-Reactive Protein (CRP) is the recommended test in acute inflammatory conditions.
2. Test conducted on EDTA whole blood at 37C.
3. ESR readings are auto- corrected with respect to Hematocrit (PCV) values

\*\*\*\*\* END OF THE REPORT \*\*\*\*\*



Sample no.

  
**Dr. SONIA KUMARI**  
 MBBS, MD (PATHOLOGY) Gold medalist

**Dr. ISHA RASTOGI**  
 MD, MBBS MICROBIOLOGY  
 CONSULTANT CLINICAL MICROBIOLOGIST



USER NM ARUN



MC - 4830

(This is only professional opinion and not the diagnosis, please correlate clinically)

Q Block, South City -II, Sohna Road, Sector-47, Gurgaon, Haryana

Ph.: 0124-4900000 (100 Lines), Toll Free No. : 1800-102-6767, Mob.: 62 62 82 82 35, Email: [customercare@parkhospital.in](mailto:customercare@parkhospital.in)

**PARK GROUP OF HOSPITALS** : West Delhi - Gurugram - Faridabad - Sonapat - Panipat - Karnal - Ambala - Patiala - Behror - Jaipur



## DEPARTMENT OF IMMUNOLOGY

**Patient Name** : Ms. PREETI SHARMA  
**MR No** : 689423  
**Age/Sex** : 34 Years 8 Months 15 Days / Female  
**Type** : OPD  
**TPA/Corporate** : MED/WHEEL PVT LTD

**Bill Date** : 28/10/2023  
**Reporting Date** : 28/10/2023  
**Sample ID** : 208369  
**Bill/Req. No.** : 24192070  
**Ref Doctor** : Dr.RMO

Test	Result	Bio. Ref. Interval	Units	Method
<b>THYROID PROFILE</b>				
TRI-IODOETHYRONINE (T3)	1.16	0.60 - 1.81	ng/ml	Chemiluminescence
THYROXINE (T4)	6.5	5.01 - 12.45	µg/dL	Chemiluminescence
THYROID STIMULATING HORMONE	2.17	0.5-5.50	µIU/ml	
SPECIMEN TYPE	SERUM			

**Method** : chemiluminescent immunoassay

**Note : Clinical Significance:**


Thyroid function tests (TFTs) is a collective term for blood tests used to check the function of the thyroid. TFTs may be requested if a patient is thought to suffer from hyperthyroidism (overactive thyroid) or hypothyroidism (underactive thyroid), or to monitor the effectiveness of either thyroid-suppression or hormone replacement therapy. It is also requested routinely in conditions linked to thyroid disease, such as atrial fibrillation and anxiety disorder. A TFT panel typically includes thyroid hormones such as thyroid-stimulating hormone (TSH, thyrotropin) and thyroxine (T4), and triiodothyronine (T3) depending on local laboratory policy.

Note: Please correlate with clinical condition

\*\*\*\*\* END OF THE REPORT \*\*\*\*\*



Sample no.

  
**Dr. SONIA KUMARI**  
 MBBS, MD (PATHOLOGY) Gold medalist

**Dr. ISHA RASTOGI**  
 MD, MBBS MICROBIOLOGY  
 CONSULTANT CLINICAL MICROBIOLOGIST



USER NM DINE3H



(This is only professional opinion and not the diagnosis, please correlate clinically)

Q Block, South City-II, Sohna Road, Sector-47, Gurgaon, Haryana

Page 1 of 1

Ph.: 0124-4900000 (100 Lines), Toll Free No. : 1800-102-6767, Mob.: 62 62 82 82 35, Email: [customercare@parkhospital.in](mailto:customercare@parkhospital.in)

**PARK GROUP OF HOSPITALS** : West Delhi - Gurugram - Faridabad - Sonapat - Panipat - Karnal - Ambala - Patiala - Behror - Jaipur



## DEPARTMENT OF BIOCHEMISTRY

**Patient Name** : Ms. PREETI SHARMA  
**MR No** : 689423  
**Age/Sex** : 34 Years 8 Months 15 Days / Female  
**Type** : OPD  
**TPA/Corporate** : MEDIWHEEL PVT LTD

**Bill Date** : 28/10/2023  
**Reporting Date** : 28/10/2023  
**Sample ID** : 208369  
**Bill/Req. No.** : 24192070  
**Ref Doctor** : Dr.RMO

Test	Result	Bio. Ref. Interval	Units	Method
<b>LFT (LIVER FUNCTION TEST)</b>				
<b>LFT</b>				
TOTAL BILIRUBIN	0.7	0 - 1.2	mg/dL	DIAZO
DIRECT BILIRUBIN	0.2	0 - 0.4	mg/dL	DIAZO
INDIRECT BILIRUBIN	0.5	0.10 - 0.6	mg/dL	CALCULATED
SGOT (AST)	21	0 - 45	U/L	IFCC WITHOUT
SGPT (ALT)	18	0 - 45	U/L	IFCC WITHOUT
ALKALINE PHOSPHATASE	160	30 - 170	IU/L	MODIFIED IFCC
TOTAL PROTEINS	6.4	6.4 - 8.0	g/dL	BIURET
ALBUMIN	3.4	3.3 - 5.5	g/dL	BCG DYE
GLOBULIN	3.0	2.3 - 4.5	g/dL	CALCULATED
A/G RATIO	1.13	1.1 - 2.2		CALCULATED

**SAMPLE TYPE** Spot Urine

null

\*\*\*\*\* END OF THE REPORT \*\*\*\*\*



Sample no.

**Dr. SONIA KUMARI**  
 MBBS, MD (PATHOLOGY) Gold medalist

**Dr. JSHA RASTOGI**  
 MD, MBBS MICROBIOLOGY  
 CONSULTANT CLINICAL MICROBIOLOGIST



USER NM ARUN



(This is only professional opinion and not the diagnosis, please correlate clinically)

Q Block, South City -II, Sohna Road, Sector-47, Gurgaon, Haryana Page 1 of 1

Ph.: 0124-4900000 (100 Lines), Toll Free No.: 1800-102-6767, Mob.: 62 62 82 82 35, Email: [customercare@parkhospital.in](mailto:customercare@parkhospital.in)

**PARK GROUP OF HOSPITALS** : West Delhi - Gurugram - Faridabad - Sonapat - Panipat - Karnal - Ambala - Patiala - Behror - Jaipur





## DEPARTMENT OF BIOCHEMISTRY

**Patient Name** : Ms. PREETI SHARMA  
**MR No** : 689423  
**Age/Sex** : 34 Years 8 Months 15 Days / Female  
**Type** : OPD  
**TPA/Corporate** : MEDIWHEEL PVT LTD

**Bill Date** : 28/10/2023  
**Reporting Date** : 28/10/2023  
**Sample ID** : 208369  
**Bill/Req. No.** : 24192070  
**Ref Doctor** : Dr.RMO


Test	Result	Bio. Ref. Interval	Units	Method
<b>KFT (RENAL PROFILE)</b>				
<b>KFT</b>				
SERUM UREA	16	10 - 45	mg/dL	UREASE-GLDH
SERUM CREATININE	0.8	0.4 - 1.4	mg/dL	MODIFIED JAFFES
SERUM URIC ACID	3.4	2.5 - 7.0	mg/dL	URICASE
SERUM SODIUM	138	135 - 150	mmol/L	ISE
SERUM POTASSIUM	4.0	3.5 - 5.5	mmol/L	ISE
SERUM CALCIUM	8.8	8.5 - 10.5	mg/dL	ARSENazo III
SERUM PHOSPHORUS	3.5	2.5 - 4.5	mg/dL	AMMONIUM

null

\*\*\*\*\* END OF THE REPORT \*\*\*\*\*



Sample no.

  
**Dr. SONIA KUMARI**  
 MBBS, MD (PATHOLOGY) Gold medalist

**Dr. JSHA RASTOGI**  
 MD, MBBS MICROBIOLOGY  
 CONSULTANT CLINICAL MICROBIOLOGIST



USER NM ARUN



(This is only professional opinion and not the diagnosis, please correlate clinically)

Q Block, South City -II, Sohna Road, Sector-47, Gurgaon, Haryana Page 1 of 1

Ph.: 0124-4900000 (100 Lines), Toll Free No. : 1800-102-6767, Mob.: 62 62 82 82 35, Email: [customercare@parkhospital.in](mailto:customercare@parkhospital.in)

**PARK GROUP OF HOSPITALS** : West Delhi - Gurugram - Faridabad - Sonapat - Panipat - Karnal - Ambala - Patiala - Behror - Jaipur



## DEPARTMENT OF BIOCHEMISTRY

Patient Name : Ms. PREETI SHARMA  
 MR No : 689423  
 Age/Sex : 34 Years 8 Months 15 Days / Female  
 Type : OPD  
 TPA/Corporate : MEDIWHEEL PVT LTD

Bill Date : 28/10/2023  
 Reporting Date : 28/10/2023  
 Sample ID : 208369  
 Bill/Req. No. : 24192070  
 Ref Doctor : Dr.RMO

Test	Result	Bio. Ref. Interval	Units	Method
<b>LIPID PROFILE</b>				
TOTAL CHOLESTEROL	151	0 - 250	mg/dL	CHOD -Trinder
SERUM TRIGLYCERIDES	114	60 - 165	mg/dl	GPO-TRINDER
HDL-CHOLESTEROL	55	30 - 70	mg/dl	DIRECT
VLDL CHOLESTEROL	22.8	6 - 32	mg/dL	calculated
LDL	73.2	50 - 135	mg/dl	calculated
LDL CHOLESTEROL/HDL RATIO	1.33	1.0 - 3.0	mg/dL	calculated
TOTAL CHOLESTEROL/HDL RATIO	2.75	2.0 - 5.0	mg/dl	calculated

SAMPLE TYPE: SERUM

Note : ATP III Guidelines At-A-Glance Quick Desk Reference

Step 1 - Determine lipoprotein levels obtain complete lipoprotein profile after 9- to 12-hour fast.

ATP III Classification of LDL, Total, and HDL Cholesterol (mg/dL):-

LDL Cholesterol Primary Target of Therapy  
 <100 Optimal  
 130-159 Borderline high  
 >190 Very high.

Total Cholesterol  
 <200 Desirable  
 200-239 Borderline high  
 >240 High

HDL Cholesterol  
 <40 Low  
 <60 High

\*\*\*\*\* END OF THE REPORT \*\*\*\*\*



Sample no.

Dr. SONIA KUMARI  
 MBBS, MD (PATHOLOGY) Gold medalist

Dr. ISHA RASTOGI  
 MD, MBBS MICROBIOLOGY  
 CONSULTANT CLINICAL MICROBIOLOGIST



USER NM ARUN



(This is only professional opinion and not the diagnosis, please correlate clinically)

Q Block, South City -II, Sohna Road, Sector-47, Gurgaon, Haryana Page 1 of 1

Ph.: 0124-4900000 (100 Lines), Toll Free No. : 1800-102-6767, Mob.: 62 62 82 82 35, Email: customercare@parkhospital.in

PARK GROUP OF HOSPITALS : West Delhi - Gurugram - Faridabad - Sonapat - Panipat - Karnal - Ambala - Patiala - Behror - Jaipur



Name : Mrs . PREETI SHARMA 24192070  
Age/Gender : 34 Y(s) /Female  
VID : 281023515  
KPID : KP0373809  
Referred By : PARK HOSPITAL  
Sample Id : 10766740

Location : KPL A43  
Registered On : 28-10-2023 17:00  
Release Date : 30-Oct-2023 16:37  
ClientId :  
Histo Id : A23/10862



**AW-CYTOLOGY**

**Test**                      **Result/Unit**

Pap Smear

CYTOPATHOLOGY NO.: C-1865/23

SPECIMEN SUBMITTED: 2 Conventional cervical smears.

SPECIMEN ADEQUACY: Satisfactory for evaluation; Endocervical /transformation zone component present.

**MICROSCOPIC EXAMINATION:**

Squamous cell population:

Superficial – Present.

Intermediate – Present.

Metaplastic squamous cells – Present.

Inflammation – Moderate.

Atypical cells – Not present.

Background bacterial flora – Shift in flora suggestive of bacterial vaginosis.

**INTERPRETATION:**

- Negative for squamous intraepithelial lesion or malignancy.
- Inflammation with associated reactive cellular changes with bacterial vaginosis.

**COMMENT:**

1. The smears are reported using the Bethesda system (2014) for reporting cervical cytology.
2. Cervical cytology is a screening test primarily for squamous cancer and its precursors and has associated false-negative and false-positive results. Technologies such as liquid-based preparations may decrease but will not eliminate all false negative results. Follow-up of unexplained clinical signs and symptoms is recommended to minimize false-negative results.
3. In patients with squamous or glandular intraepithelial abnormalities, further

Print Date : 31-10-2023 13:44

Page:1 of 2



ON PANEL : C.G.H.S., D.G.E.H.S., ECHS, B.H.E.L, INDIAN RAILWAY, E.S.I., NDMC, DELHI JAL BOARD, ONGC, NTPC, SAIL, NIFT

1. All reports are for interpretation by the treating doctor only and have to be viewed and correlated with clinical examination and other investigations. 2. All investigations have their limitation which is imposed by the limits to sensitivity and specificity of individual assay procedures as well as the quality of the specimen received by the laboratory. Isolated laboratory investigations never confirm the final diagnosis of the disease. 3. If the result(s) of tests are alarming or unexpected the doctor is advised to contact the lab immediately for re-eval and necessary action.  
This Report is not subject to use for any medico-legal purpose

Customer Care No.  
011-46123456  
7235960000  
9785712222  
9312210534

E-8A, HAUZ KHAS, MAIN MARKET, NEW DELHI - 16 • E-5A, HAUZ KHAS, MAIN MARKET, NEW DELHI - 16  
A-43, Hauz Khas (Near Hauz Khas Police Stn.), New Delhi - 16, C.S. Rana Complex, I block, Sector 22, Noida (UP)  
Email : info@pathcareindia.com Website : www.pathcareindia.com



Name : Mrs . PREETI SHARMA 24192070  
Age/Gender : 34 Y(s) /Female  
VID : 281023515  
KPID : KP0373809  
Referred By : PARK HOSPITAL  
Sample Id : 10766740

Location : KPL A43  
Registered On : 28-10-2023 17:00  
Release Date : 30-Oct-2023 16:37  
ClientId :  
Histo Id : A23/10862



diagnostic follow-up procedures, such as HPV testing, colposcopy / biopsy with endocervical sampling are suggested, as clinically indicated.



*N. Magoon*

**Dr.N.Magoon**  
**M.D. (Path)**  
Consulting Pathologist DMC Reg.No-  
97859

Print Date : 31-10-2023 13:44

Page:2 of 2



ON PANEL : C.G.H.S., D.G.E.H.S., ECHS, B.H.E.L, INDIAN RAILWAY, E.S.I., NDMC, DELHI JAL BOARD, ONGC, NTPC, SAIL, NIFT

1. All reports are for interpretation by the treating doctor only and have to be viewed and correlated with clinical examination and other investigations. 2. All investigations have their limitation which is imposed by the limits to sensitivity and specificity of individual assay procedures as well as the quality of the specimen received by the laboratory. Isolated laboratory investigations never confirm the final diagnosis of the disease. 3. If the result (x) of tests are alarming or unexpected the doctor is advised to contact the lab immediately for useful and necessary action.  
This Report is not subject to use for any medico-legal purpose

E-8A, HAUZ KHAS, MAIN MARKET, NEW DELHI - 16 • E-5A, HAUZ KHAS, MAIN MARKET, NEW DELHI - 16  
A-43, Hauz Khas (Near Hauz Khas Police Stn.), New Delhi - 16, C.S. Rana Complex, I block, Sector 22, Noida (UP)  
Email : [info@pathcareindia.com](mailto:info@pathcareindia.com) Website : [www.pathcareindia.com](http://www.pathcareindia.com)

Customer Care No.  
011-46123456  
723990000  
9785712222  
9912210534



Vitals :

Chief Complaints :

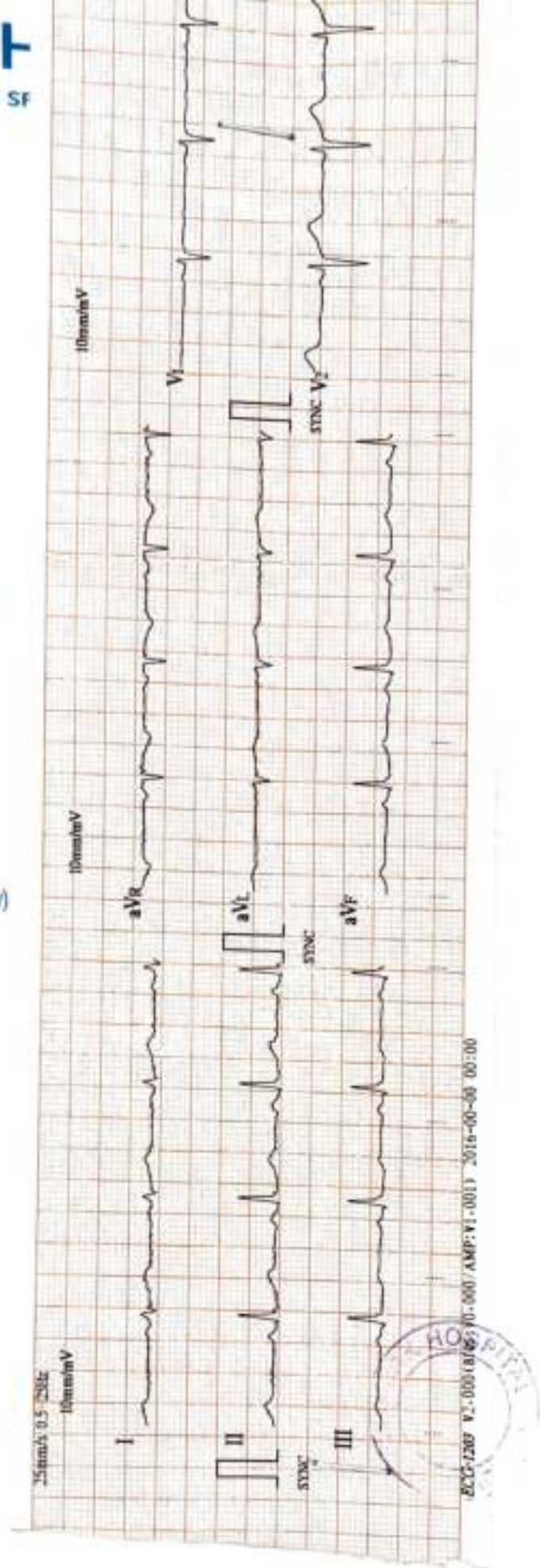
H/O Present Illness :

Past History :

Investigation :

Drug Allergies : (if any)

Treatment :



Gurgaon

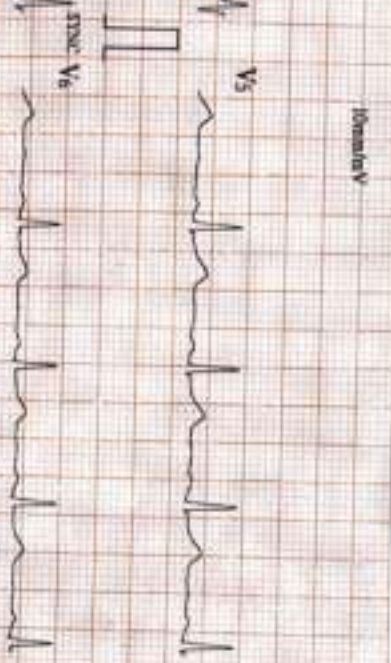
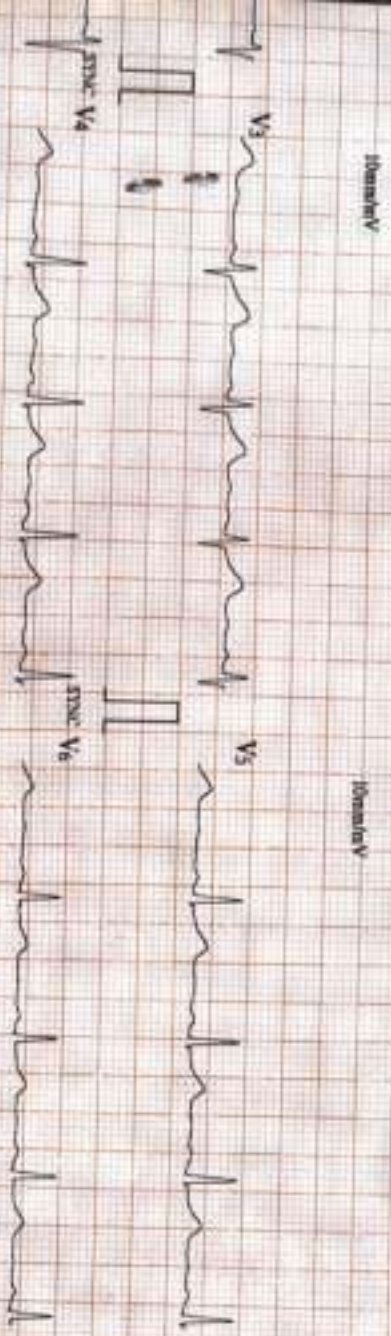
Q Block South City 11, Sohna Road, Main Sector-47, Gurgaon, Haryana Ph.: 0124-4900000 Fax : 0124-2218733  
E-mail : parkmedcenters@gmail.com

● West Delhi ● South Delhi ● Faridabad ● Panipat ● Karnal

the **health** care providers

the **health** care providers





ID : 0002

Name :

*Prithi*

Sex :

*34y/f*

Age :

*28/10/23*

Sinus Arrhythmia

HR : 74  
 PR : 809  
 P-R : 115  
 QRS : 83  
 QT/QTc : 356/395  
 P/QRS/T : 62/79/48  
 RV5/SV1 : 0-100/0-500mV  
 RV5/SV1 : 1.100  
 mV

Unconfirmed report verified by:

*10:54Am*





**DEPARTMENT OF RADIOLOGY**

Patient Name	Ms. PREETI SHARMA	Billed Date	28/10/2023
Reg No	689423	Reported Date	28/10/2023
Age/Sex	34 Years 8 Months 15Days / Female	Req. No.	24192070
Type	OPD	Consultant Doctor	Dr. RMO

**USG WHOLE ABDOMEN**

The real time, B mode, gray scale sonography of the abdominal organs was performed.

**LIVER** : The liver is normal in size (12.5cm), shape and echotexture. No evidence of any focal lesion. IHBR is not dilated.

**GALL BLADDER** : The gall bladder is well distended. No evidence any calculus or mass seen. GB wall thickness within normal limits. No evidence of pericholecystic fluid is seen.

**BILE DUCT** : The common bile duct is normal in caliber. No evidence of calculus is noted in common bile duct.

**SPLEEN** : The spleen is normal in size (8.2cm) and shape. Its echotexture is homogeneous. No evidence of focal lesion is noted.

**PANCREAS** : The pancreas is normal in size, shape, contours and echotexture. No evidence of solid or cystic mass lesion is noted. MPD is not dilated. No evidence of peripancreatic collection.

**KIDNEYS** : The bilateral kidneys are normal in size and echotexture. Cortico-medullary differentiation is maintained. There is no evidence of obvious calculus or hydronephrosis.

**URINARY BLADDER** : The urinary bladder is well distended. It shows uniformly thin walls and sharp mucosa. No evidence of calculus is seen. No evidence of mass or diverticulum is noted.

**UTERUS** : The uterus is retroverted. It measures 6.1 x 4.3 x 4.2 cms. in the longitudinal, anteroposterior and transverse dimensions respectively. The uterine margins are smooth and does not reveal any contour abnormalities.

The uterine endometrium shows homogeneous echotexture.



H-2015-0188

(This is only professional opinion and not the diagnosis, please correlate clinically)

Q Block, South City -II, Sohna Road, Sector-47, Gurgaon, Haryana

Ph.: 0124-4900000 (100 Lines), Toll Free No. : 1800-102-6767, Mob.: 62 62 82 82 35, Email: [customercare@parkhospital.in](mailto:customercare@parkhospital.in)

**PARK GROUP OF HOSPITALS** : West Delhi - Gurugram - Faridabad - Sonapat - Panipat - Karnal - Ambala - Patiala - Mohali - Behror - Jaipur





No evidence of leiomyoma is noted. No solid or cystic mass lesion is noted.

The endometrial echo is in the midline and measures 5.0 mm.

**Right ovary appears bulky in size and shows echogenic lesion of size 41 x 30 mm with mild vascularity s/o ? Dermoid cyst.**

Left ovary is normal in size and echotexture.

No evidence of ascites or interbowel free fluid is seen.

No evidence of obvious retroperitoneal or mesentric lymphadenopathy is seen.

**IMPRESSION- ? Right ovarian dermoid cyst.**

To be correlated clinically.

*MS*

Dr. ANSHU K. SHARMA  
MBBS, MD  
CONSULTANT RADIOLOGIST



Dr. MANJEET SEHRAWAT  
MBBS, MD, PDCC  
CONSULTANT RADIOLOGIST



Dr. NEENA SIKKA  
MBBS, DNB  
CONSULTANT RADIOLOGIST

(This is only professional opinion and not the diagnosis, please correlate clinically)

Q Block, South City -II, Sohna Road, Sector-47, Gurgaon, Haryana

Ph.: 0124-4900000 (100 Lines), Toll Free No. : 1800-102-6767, Mob.: 62 62 82 82 35, Email: [customer.care@parkhospital.in](mailto:customer.care@parkhospital.in)

**PARK GROUP OF HOSPITALS** : West Delhi - Gurugram - Faridabad - Sonapat - Panipat - Karnal - Ambala - Patiala - Mohali - Behror - Jaipur





## DEPARTMENT OF RADIOLOGY

Patient Name	Ms. PREETI SHARMA	Billed Date	: 28/10/2023
Reg No	689423	Reported Date	: 28/10/2023
Age/Sex	34 Years 8 Months 15Days / Female	Req. No.	: 24192070
Type	OPD	Consultant Doctor	: Dr. RMO

### X-RAY CHEST AP/PA

Bilateral lungs appears normal.

No focal lung lesion seen.

No evidence of free fluid is seen.

Both hila are normal in size, have equal density and bear normal relationship.

The heart and trachea are central in position and no mediastinal abnormality is visible.

The cardiac size is normal for patient age and view.

The domes of the diaphragms are normal in position, and show smooth outline.

To be correlated clinically

Dr. ANSHU K. SHARMA  
MBBS, MD  
CONSULTANT RADIOLOGIST

Dr. MANJEET SEHRAWAT  
MBBS, MD, PDCC  
CONSULTANT RADIOLOGIST



Dr. NEENA SIKKA  
MBBS, DNB  
CONSULTANT RADIOLOGIST



H-2016-0388

(This is only professional opinion and not the diagnosis, please correlate clinically)

Q Block, South City -II, Sohna Road, Sector-47, Gurgaon, Haryana

Ph.: 0124-4900000 (100 Lines), Toll Free No. : 1800-102-6767, Mob.: 62 62 82 82 35, Email: [customer@parkhospital.in](mailto:customer@parkhospital.in)

PARK GROUP OF HOSPITALS : West Delhi - Gurugram - Faridabad - Sonapat - Panipat - Karnal - Ambala - Patiala - Mohali - Behror - Jaipur