



SUBHAM IMAGING & A.L.C. DIAGNOSTICS CENTRE

H.O. : Ajoy, Bank of Baroda Building, East Ashok Nagar, Kankarbagh, Patna - 20

B.O. : Khanpura Road (Below Gyan Sharowar School), Paliganj, Patna.

e-mail : shubham.pat.usg@gmail.com # website : www.pkarogayamhealthcheckup.com

OPINION MUST BE CORRELATES WITH CLINICAL & OTHER INVESTIGATION FOR DIAGNOSIS NOT FOR MEDICO LEGAL PURPOSE

Pt. Name :- **AMRITESH KUMAR SINGH**

Ref. By :- **DR. B O B**

Date:- **14-Mar-22**

Age / Sex - **41 Yrs. M.**

Thanks for your kind referral

X-RAYCHEST (P.A.VIEW)

The lungs on the either side show equal translucency.

The peripheral pulmonary vasculature is normal.

No focal lung lesion is seen.

The pleural spaces are normal.

Both hila are normal in size, have equal density and bear normal relationship.

The heart and trachea are central in position and no mediastinal abnormality is visible.

The cardiac size is normal.

The domes of the diaphragms are normal in position, and show smooth outline.

IMPRESSION

- NO EVIDENCE OF PULMONARY OR CARDIAC PATHOLOGY IS NOTED.



ESTD BY:-

Dr. P. K. Tiwari

MD, M.Sc (Radio Imaging)

Ph.D (Alt Nuclear Medicine)

Consultant Imagianologist & Sonologist

Dr. S. Kumar

MD. (Pat)

Consultant Pathologist

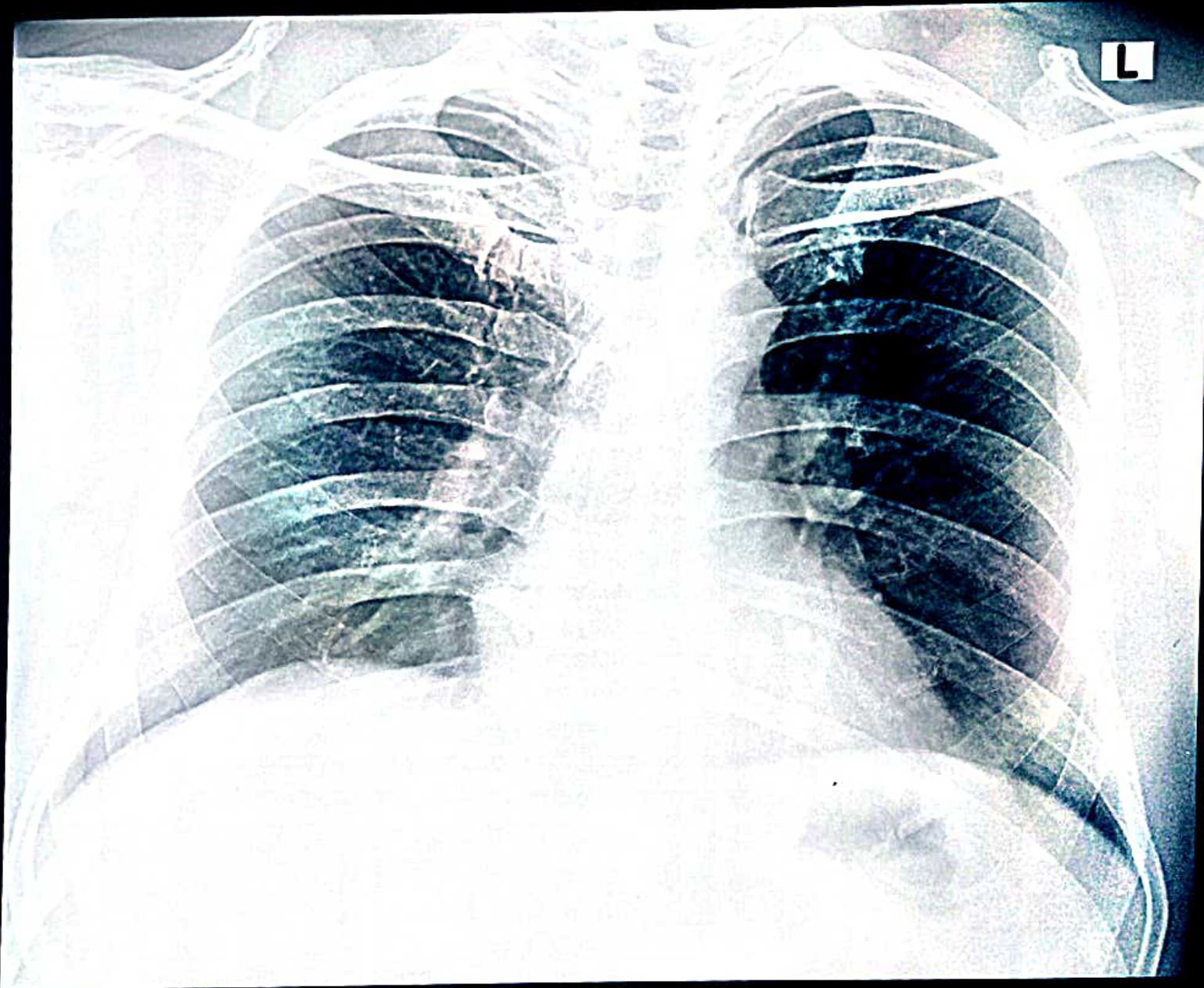
Dr. A. K. Singh
MBBS, PGDMCH
Consultant Radiologist
Consultant Radiologist

Dr. A. K. Singh

MBBS, PGDMCH

Consultant Radiologist & Sonologist

PRINTING MISTAKE SHOULD BE REPORTED BACK IMMEDIATELY/ यहाँ जन्म से पहले भ्रूण का लिंग जाँच नहीं होता है ।



REF BY DR. MEDIWHEEL AMRITESH KUMAR SINGH AGE 41 YEARS M
2022.MAR.12
A.L.C. Advance Imaging Diagnostics Centre PATNA - 20



A.L.C. Advance Imaging Dignostics

ISO 9001:2015 Certified center

(A Unit of P.K.Arogyam Health & Wellness Center)

E-95, P.C. Colony, Near Sai Netryalaya Transformer, Kankarbagh, Patna - 20

alcdiagnostics@gmail.com

www.pkarogayamhealthcheckup.com

7050037694, 8271206196

OPINION MUST BE CORRELATES WITH CLINICALLY & OTHER INVESTIGATION FOR FINAL DIAGNOSIS. NOT FOR MEDICO LEGAL PURPOSE

ECHOCARDIOGRAPHY & COLOR DOPPLER REPORT

Patient's Name : Mr.AMRITESH KUMAR

Age/Sex : 42 Yrs /M

Ref. by : B O B

Date : 14-Mar-22

ECHOCARDIOGRAPHIC WINDOW: Fair

2D & M MODE ECHOCARDIOGRAPHY

Left ventricle

EDD:	39	mm (20 - 28 mm / m ²)	ESD:	27	mm (13 - 21 mm / m ²)
IVS :	10	mm (6 - 11 mm)	PW:	10	mm (6 - 11 mm)
Ejection fraction:	60%	(61 ± 8%)	FS:	30	% (34 - 44 %)
IVS:	Intact		LV clot	Absent	

Left atrium/ Aorta 35/26 mm

Right ventricle Normal

Right atrium Normal

Pericardium Normal with no pericardial effusion

2D:

Normal LA/LV Size and normally contracting left ventricle. No RWMA, concentric LVH

Mitral valve

AML/ PML: Normal

Tricuspid valve Normal

Aortic valve Normal

Pulmonary valve Normal

Continuous & Pulse Wave Doppler study

Valve	Velocity (m/sec)			Gradient (mmHg)			Valve area (PHT Method)	Regurg.
	Peak	Mean	EDV	Peak	Mean	EDG		
Mitral	E=0.6 A=0.7			2.2	2.0			Nil
Tricuspid	E=0.7 A=0.5			2.2	0.2			Nil
Aortic	1.0			4.0	2.5			Nil
Pulmonary	3.4			3.5	1.7			Nil

ESTB BY:-

Dr. P. K. Tiwari
MD, M.Sc (Radio Imaging)
Ph.D (AI Nuclear Medicine)
Consultant Imaginologist & Sonologist

Dr. S. Kumar
MD (Pat)
Consultant Pathologist

Dr. Abhishek Kumar
MBBS, MD
Consultant Neuropatho Physiologist



Consultant Radiologist

Dr. Kumari Suman
MBBS, DGO, MD
Consultant (TVS & HSG Specialist)

PRINTING MISTAKE SHOULD BE REPORTED BACK IMMEDIATELY

Colour Flow Imaging

No TR, No MR/PR, No AR

No flow shunt

COMMENTS :

- ◆ Normal size all chamber
- ◆ Normal LV filling Pressure
- ◆ No RWMA
- ◆ Normal LV systolic function
- ◆ Grade I LV diastolic dysfunction.
- ◆ Global LVEF = 60%
- ◆ All cardiac valves are normal
- ◆ No PAH, Mild concentric LVH
- ◆ No MS / TS / AS / PS / PR
- ◆ No clot / vegetation / pericardial effusion.

IMPRESSION:

All chambers are normal

No RWMA, No PAH

Grade I LV diastolic dysfunction.

Normal LV systolic function, LVEF – 60%

Please correlate clinically

DR. SANDEEP KUMAR MBBS MD



DR. SANDEEP KUMAR
M.B.B.S., M.D. (Med.)
Reg. No.-BCMR33225

ESTD BY:-

Dr. P. K. Tiwari
MD, M.Sc (Radio Imaging)
Ph.D (A/I Nuclear Medicine)

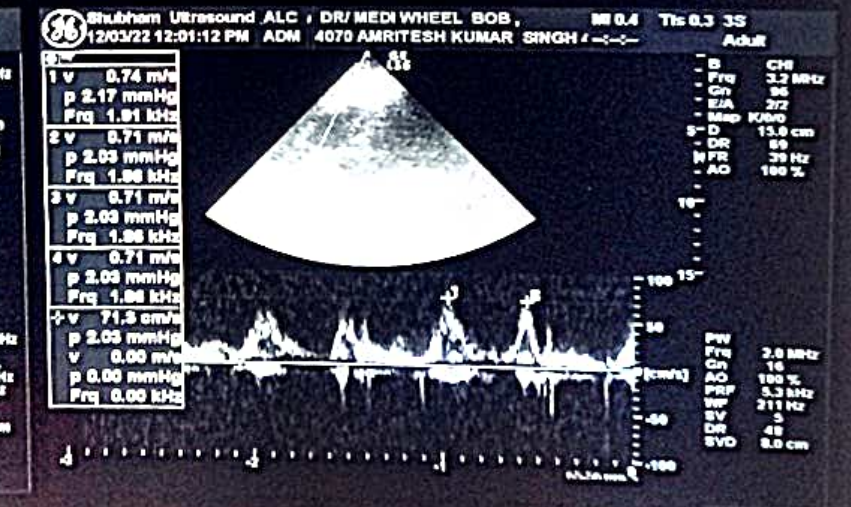
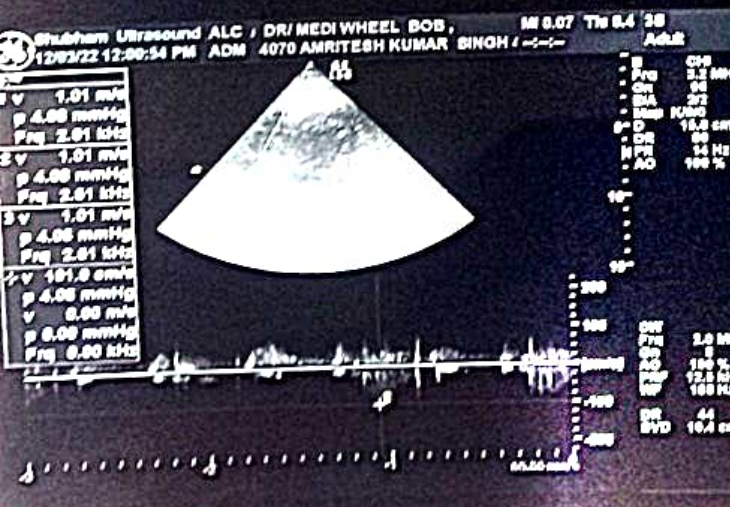
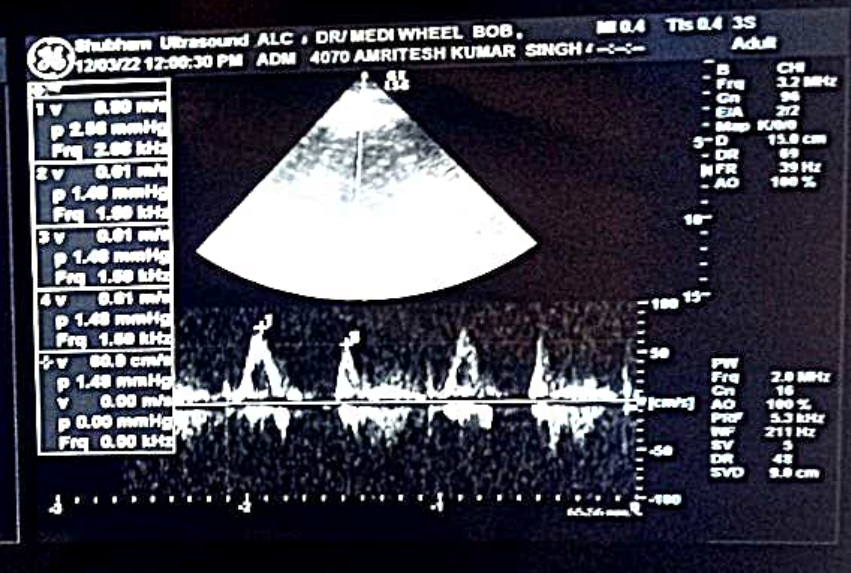
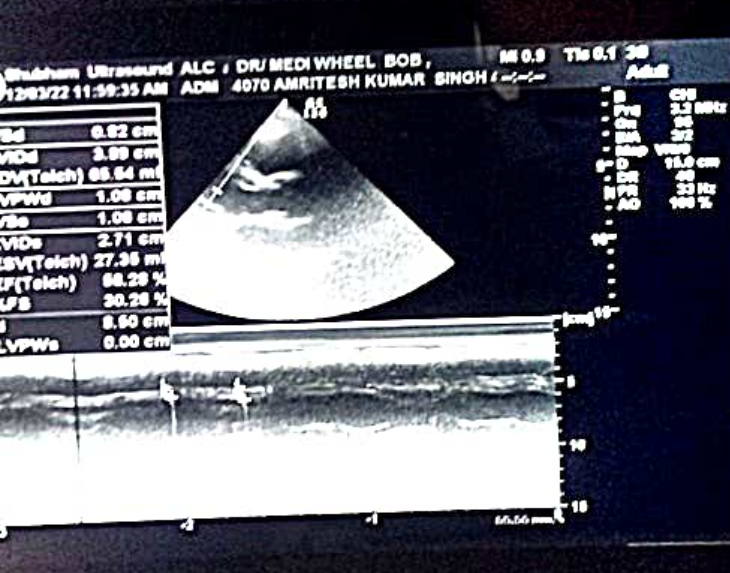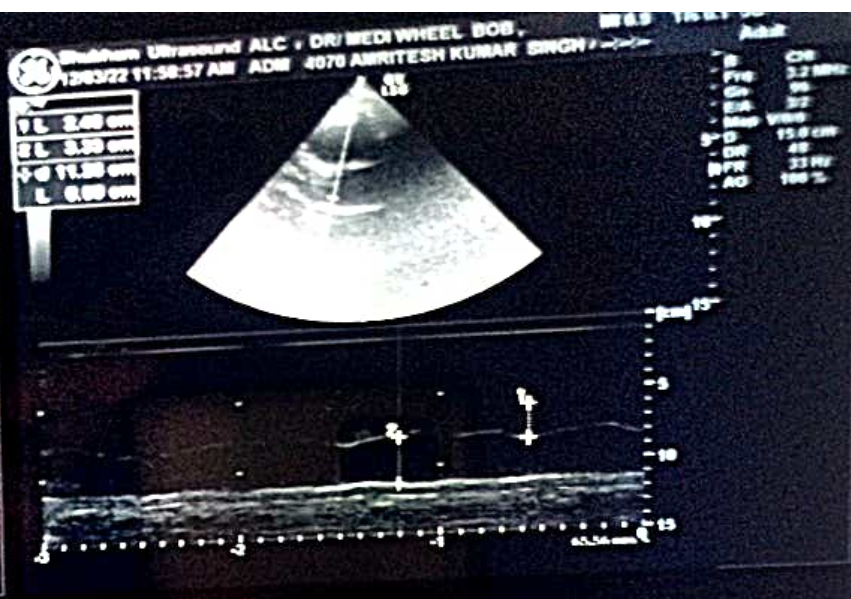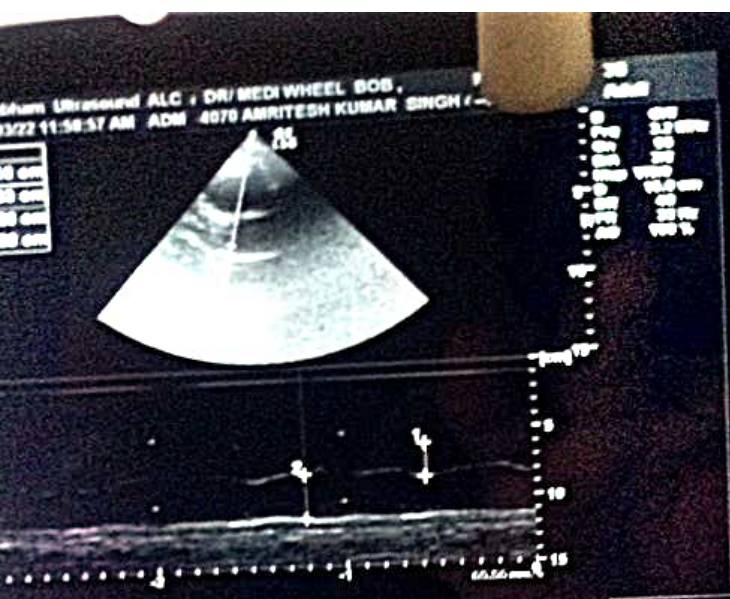
Dr. S. Kumar
MD (Pat)
Consultant Pathologist

Dr. Abhishek Kumar
MBBS, MD
Consultant Neurophysiologist

Dr. Anjali
MBBS, MD

Consultant Radiologist

Dr. Kumari Sumo





SUBHAM IMAGING & A.L.C. DIAGNOSTICS CENTRE

H.O. : Ajay Market, Bank of Baroda Building, East Ashok Nagar, Kankarbagh, Patna - 20

B.O. : Khanpura Road (Below Gyan Sharowar School), Paliganj, Patna.

e-mail : shubham.pat.usg@gmail.com # website : www.pkarogayamhealthcheckup.com

OPINION MUST BE CORRELATES WITH CLINICAL & OTHER INVESTIGATION FOR DIAGNOSIS NOT FOR MEDICO LEGAL PURPOSE

Pt. Name :- **AMRITESH KUMAR SINGH**
Ref. By :- **DR. / MEDI WHEEL / BOB**

Date:- **12-Mar-22**
Age / Sex - **Yrs. M.**

REAL TIME U.S.G. OF WHOLE ABDOMEN Thanks for your kind referral

(Report.)

- LIVER** :- Measures 13.75 cm. Normal in shape, size and echo texture. I.H.B.R. are not dilated. Hepatic veins are normal. No SOL seen.
- G.BL.** :- Lumen is echo free. Wall thickness appears normal.
- C.B.D.** :- Measures 3.3 mm in diameter with echo free lumen. No calculi or mass seen.
- P.V.** :- Measures 7.2 mm in diameter. Appears normal. No thrombus seen.
- PANCREAS** :- Normal in shape, size and echo texture. No calcification mass seen.
- SPLEEN** :- Measures 10.0 cm. Normal in shape, size and echo texture. No SOL seen.
- KIDNEY** :- Both kidney shows normal shape, size & echotexture. C.M.D.intact. P.C.S.is not dilated. No calculi, cyst or hydronephrosis seen on either side.
Right Kidney :- Measures 9.10 X 4.1 cm.
Left Kidney :- Measures 9.9 X 4.2 cm.
- URETER** :- Not dilated. No apparent calculi seen.
- U.BLADDER**:- Shows normal in outline with echo free lumen. No calculi or mass seen.
Pre void - 280 ml. Post void - is in significant
- PROSTATE** :- Measures 15 gms.(approx). Appears Normal in size, shape, and echo texture. No calcification, mass, growth seen. capsule is intact.
- R.I.F.** :- Son graphically no appendicular mass or collection seen.
- OTHERS** :- No Ascites. no Lymph Adenopathy. No pleural effusion seen on either side.

IMPRESSION

➤ **Son graphically normal scan no detectable lesion seen**



ESTD BY:-

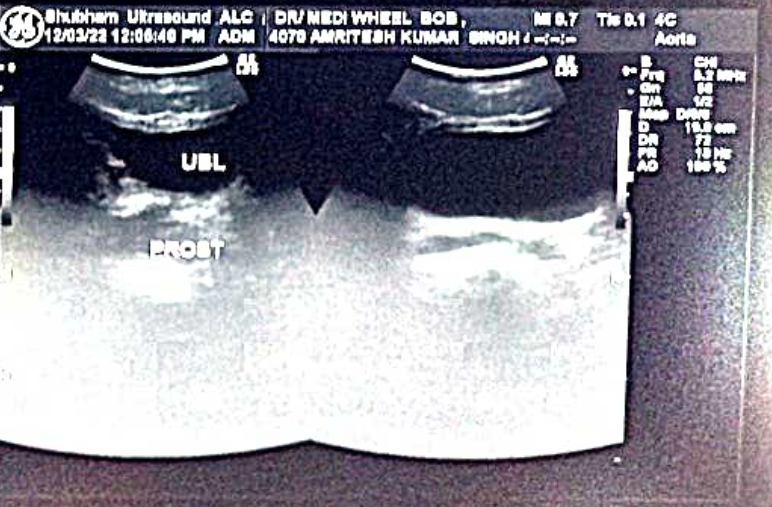
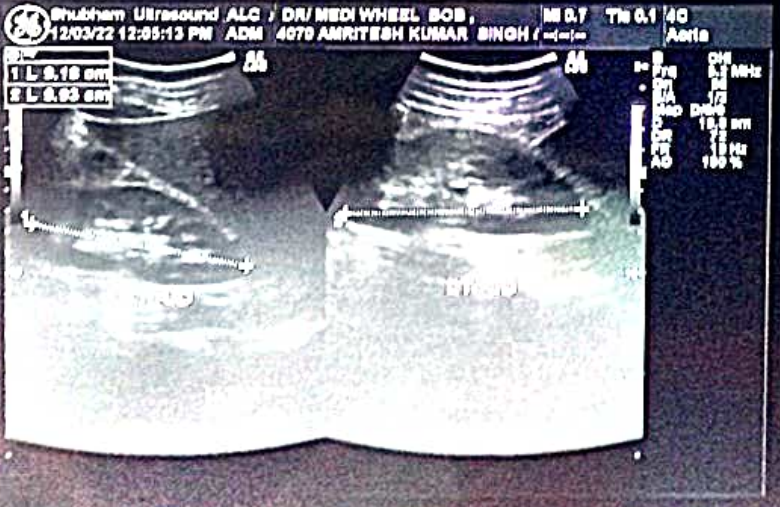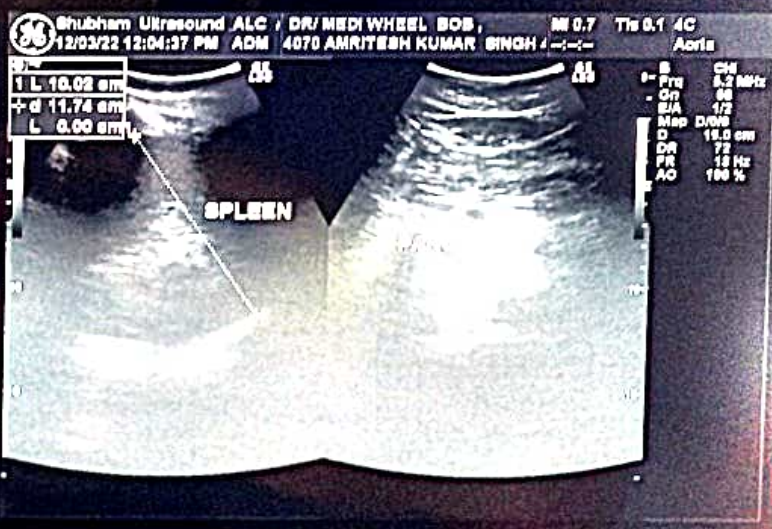
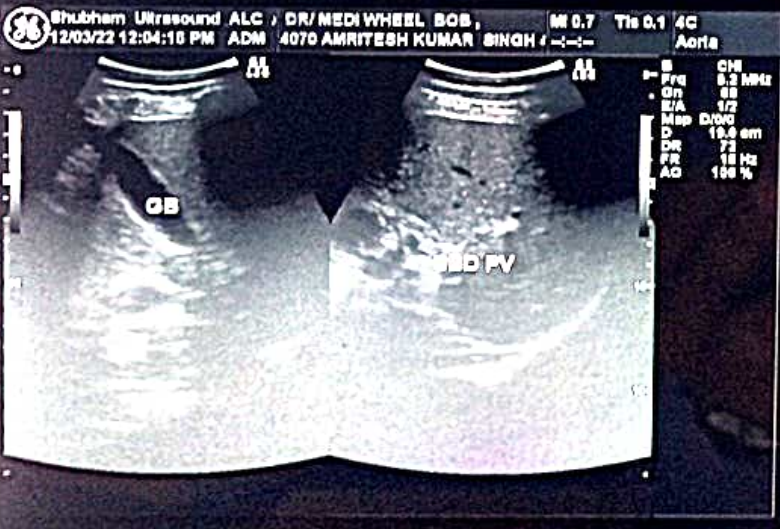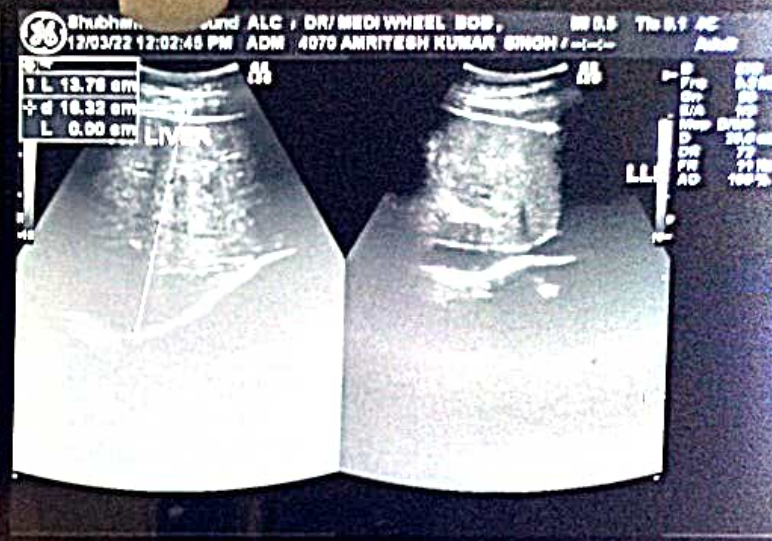
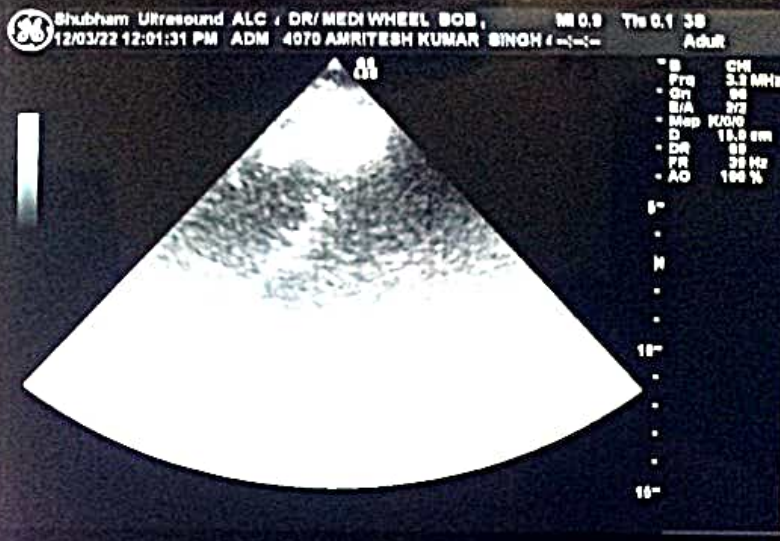Dr. P. K. Tiwari
MD, M.Sc (Radio Imaging)
Ph.D (Alt Nuclear Medicine)
Consultant Imagiologist & Sonologist

Dr. S. Kumar
MD. (Pat)
Consultant Pathologist

Dr. A. K. Singh
MBBS, PGDMCH
Consultant Radiologist
12/3/22
Consultant Radiologist

Dr. A. K. Singh
MBBS, PGDMCH
Consultant Radiologist & Sonologist

PRINTING MISTAKE SHOULD BE REPORTED BACK IMMEDIATELY/ यहाँ जन्म से पहले भ्रुण का लिंग जाँच नहीं होता है ।





A.L.C. Advance Imaging Diagnostics

ISO 9001:2015 Certified center

(A Unit of P.K.Arogyam Health & Wellness Center)

E-95, P.C. Colony, Near Sai Netryalaya Transformer, Kankarbagh, Patna - 20

alcdiagnostics@gmail.com

www.pkarogyamhealthcheckup.com

7050037694, 8271206196

OPINION MUST BE CORRELATES WITH CLINICALLY & OTHER INVESTIGATION FOR FINAL DIAGNOSIS. NOT FOR MEDICO LEGAL PURPOSE

PATIENT NAME : Mr. SINGH AMRITESH KUMAR

PATIENT ID: 4070

COL DATE : 12/03/2022 REPORTING DATE: 12/03/2022 AGE SEX : 41 YRS/M

REF.BY : DR. /MEDIWHEEL.

TEST NAME	RESULT	Unit	REF.RANGE
BLOOD SUGAR (F)	72.0 mg/dl		70 - 110 mg/dl

LIPID PROFILE:-

TOTAL CHOLESTROL	170.9 mg/dl		130 -250 mg/dl
TRIGLYCERIDE	245.5 mg/dl		50 -160 mg/dl
HDL CHOLESTROL	43.0 mg/dl		30 - 60 mg/dl
LDL CHOLESTROL	78.8 mg/dl		80 -130 mg/dl
VLDL CHOLESTROL	49.1 mg/dl		15 - 40 mg/dl
T.CH./HDL RATIO	3.9:1		Upto 5:1
LDL/HDL RATIO	1.8:1		2 - 4:1



Dr. Ankur Kumar
MBBS, MD
Consultant Pathologist
Reg. No 39540

ESTB BY:-

Dr. P. K. Tiwari
MD, M.Sc (Radio Imaging)
Ph.D (AIH Nuclear Medicine)
Consultant Imagerologist & Sonologist

Dr. S. Kumar
MD (Pat)
Consultant Pathologist

Dr. Abhishek Kumar
MBBS, MD
Consultant Neuropatho Physiologist

Dr. Anjali
MBBS, MD
Consultant (TMT, EEG Specialist)

Consultant Radiologist

Dr. Kumari Suman
MBBS, DGO, MD
Consultant (TVS & HSG Specialist)

PRINTING MISTAKE SHOULD BE REPORTED TO THE BACK IMMEDIATELY/ यहाँ जन्म से पहले भ्रूण का लिंग जाँच नहीं होता है ।



A.L.C. Advance Imaging Diagnostics

ISO 9001:2015 Certified center

(A Unit of P.K.Arogyam Health & Wellness Center)

E-95, P.C. Colony, Near Sai Netryalaya Transformer, Kankarbagh, Patna - 20

alcdiagnostics@gmail.com

www.pkarogyamhealthcheckup.com

7050037694, 8271206196

OPINION MUST BE CORRELATES WITH CLINICALLY & OTHER INVESTIGATION FOR FINAL DIAGNOSIS. NOT FOR MEDICO LEGAL PURPOSE

PATIENT NAME : Mr. SINGH AMRITESH KUMAR PATIENT ID: 4070
 COL DATE : 12/02/2022 REPORTING DATE: 12/03/2022 AGE SEX:- 41 YRS/M
 REF.BY : DR./ MEDIWHEEL

TEST NAME	RESULT	Unit	REF.RANGE
LFT:-			
SGPT	27.4	IU/L	5 - 48 IU/L
SGOT	43.3	IU/L	5 - 40 IU/L
ALKALINE PHOSPHATASE	100.2	IU/L	25 - 147 IU/L
TOTAL PROTIN	8.1	g/dl	6.0 - 8.7 g/dl
SERUM ALBUMIN	5.2	g/dl	3.5 - 5.4 g/dl
SERIUM GLUBLINE	2.9	g/dl	2.3 - 3.6 g/dl
AG RATIO	1.7 : 1		1.0 - 2.3 g/dl
BILIRUBIN			
	TOTAL	0.69 mg/dl	0.1 - 1.1 mg/dl
	IRECT	0.28 mg/dl	0.0 - 0.32 mg/dl
	INDIRECT	0.41 mg/dl	0.0 - 0.78 mg/dl
KFT/RFT			
URIC ACID	4.7	mg/dl	3.2 - 7.0 mg/dl
SERUM CREATNINE	0.8	mg/dl	0.6 - 1.5 mg/dl
BLOOD URIA	30.7	mg/dl	5 - 45 mg/dl
BLOOD URIA NITROZEN(BUN).	14.1	mg/dl	13 - 39 mg/dl



Dr. Ankur Kumar
 MBBS, MD
 Consultant Pathologist
 Reg. No 39540

Consultant Radiologist

Dr. S. Kumar

MD (Pat)
Consultant Pathologist

Dr. Abhishek Kumar
MBBS, MD
Consultant Neuropatho Physiologist

Dr. Anjali
MBBS, MD
Consultant(TMT,EEG Specialist)

Dr. Kumari Suman
MBBS, DGO, MD
Consultant (TVS & HSG Specialist)

NG MISTAKE SHOULD BE REPORTED BACK IMMEDIATELY



A.L.C. Advance Imaging Diagnostics

ISO 9001:2015 Certified Center

(A Unit of P.K. Arora Health & Wellness Center)

E-95, P.C. Colony, Near Sai Netryalaya Transformer, Kankarbagh, Patna - 20

alcdiagnostics@gmail.com

www.pharogayamhealthcheckup.com

7556551094, 9072061195

OPINION MUST BE CORRELATES WITH CLINICALLY & OTHER INVESTIGATION FOR FINAL DIAGNOSIS. NOT FOR MEDICO LEGAL PURPOSE

PATIENT NAME : Mr. SINGH AMARITESH KR

PATIENT ID: 4070

COL DATE : 12/03/2022 REPORTING DATE: 12/03/2022 AGE SEX: 41 YRS/M

REF BY : DR. / MEDIWHEEL

TEST NAME	RESULT	Unit	REF RANGE
ESR	10 mm/hr		<20 mm/hr
CBC			
Total W.B.C. Count	9400 /cumm		4000-11,000 /cumm
R B C COUNT	5.5 Million/ CUmm		4 - 7 Million/ CUmm
Platelets count	3.33 Lakh/ cumm		1.5-5.0 Lakh/ cumm
Differential Count of W.B.C.			
Neutrophils	65 %		40-70%
Lymphocytes	32 %		25-40%
Eosinophils	02 %		01-05%
Mnonocytes	01 %		00-02%
Basophiles	00 %		00-0%
HAEMOGLOBIN	15.6 gm/dl (105.4 %)		14.6 gm/dl = 100%
PCV	50.6 %		35-47 %
MCV	94.1 fl		76-96 fl
MCH	30.5 pg		29-35 pg
MCHC	36.4 %		30-38 %



Dr. Anjali Kumar
 MBBS MD
 Consultant Pathologist
 Reg No 39540
 Consultant Radiologist

ESTD BY:

Dr. P. K. Tiwari
 MD, M Sc (Radio Imaging)
 M. D (AI) Nuclear Medicine
 Consultant Imagingologist & Sonologist

Dr. S. Kumar
 MD (Pul)
 Consultant Pathologist

Dr. Abhishek Kumar
 MBBS, MD
 Consultant Neurophysiologist

Dr. Anjali
 MBBS, MD
 Consultant (TMT, EEG Specialist)

Dr. Kumari Suman
 MBBS, DGO, MD
 Consultant (TUS & HSG Specialist)

PRINTING MISTAKE SHOULD BE REPORTED BACK IMMEDIATELY/यहाँ जन्म से पहले बुग का रिग जीव नहीं होता है ।



A.L.C. Advance Imaging Diagnostics

ISO 9001:2015 Certified center

(A Unit of P.K. Arogyam Health & Wellness Center)

E-95, P.C. Colony, Near Sal Netryalaya Transformer, Kankarbagh, Patna - 20

alcdiagnostics@gmail.com

www.pkarogyamhealthcheckup.com

7050037694, 8271206196

OPINION MUST BE CORRELATES WITH CLINICALLY & OTHER INVESTIGATION FOR FINAL DIAGNOSIS. NOT FOR MEDICO LEGAL PURPOSE

PATIENT NAME : Mr. SINGH AMRITESH KUMAR PATIENT ID: 4070
COL DATE : 12/03/2022 REPORTING DATE: 13/03/2022 AGE SEX : 41 YRS/M
REF. BY : DR./ MEDIWHEEL.

GLYCOSYLATED HEMOGLOBIN

TEST NAME	RESULT	Unit	REF. RANGE
HbA1c	4.6 %		Below 5.7 % : Normal 5.7 - 6.4 % : Prediabetic > = 6.5 % : Diabetic
AVERAGE PLASMA GLUCOSE	99.0 mg/dl		90 - 120 mg/dl : Good Control 121 - 150 mg/dl : Fair Control 151 - 180 mg/dl : Unsatisfactory Control >180 mg/dl : Poor Control



Dr. Ankur Kumar
MBBS, MD
Consultant Pathologist
Reg. No. 39540

Consultant Radiologist

ESTD BY-

Dr. P. K. Tiwari
MD, M Sc (Radio Imaging)
Ph.D (All India Institute of Medical Sciences)
Consultant Imaging Radiologist & Sonologist

Dr. S. Kumar
MD (Pat)
Consultant Pathologist

Dr. Abhishek Kumar
MBBS, MD
Consultant Neuropatho Physiologist

Dr. Anjali
MBBS, MD
Consultant (TMT, EEG Specialist)

Dr. Kumari Suman
MBBS, DGO, MD
Consultant (TVS & USG Specialist)

PRINTING MISTAKE SHOULD BE REPORTED BACK IMMEDIATELY/यहाँ जन्म से पहले गुण का लिंग जाँच नहीं होता है ।



A.L.C. Advance Imaging Dignostics

ISO 9001:2015 Certified center

(A Unit of P.K.Arogyam Health & Wellness Center)

E-95, P.C. Colony, Near Sai Netryalaya Transformer, Kankarbagh, Patna - 20

alcdiagnostics@gmail.com

www.pkarogyamhealthcheckup.com

7050037694, 8271206196

OPINION MUST BE CORRELATES WITH CLINICALLY & OTHER INVESTIGATION FOR FINAL DIAGNOSIS. NOT FOR MEDICO LEGAL PURPOSE

PATIENT NAME : Mr. SINGH AMRITESH KUMAR PATIENT ID: 4070
COL DATE : 12/03/2022 REPORTING DATE: 12/03/2022 AGE SEX:- 41 YRS/M
REF.BY : DR. / MEDIWHEEL.

TEST NAME	RESULT	Unit	REF.RANGE
BLOOD GROUP	: 'B'		
Rh Typing	: POSITIVE		

Note: Do always cross – matching before blood transfusion



Dr. Ankur Kumar
MBBS, MD
Consultant Pathologist
Reg. No 39540

ESTB BY:-

Dr. P. K. Tiwari
MD, M.Sc (Radio Imaging)
Ph.D (AI Nuclear Medicine)
Consultant Imaginologist & Sonologist

Dr. S. Kumar
MD (Pat)
Consultant Pathologist

Dr. Abhishek Kumar
MBBS, MD
Consultant Neuropatho Physiologist

Dr. Anjali
MBBS, MD
Consultant (TMT, EEG Specialist)

Dr. Kumari Suman
MBBS, DGO, MD
Consultant (TVS & HSG Specialist)

Consultant Radiologist

PRINTING MISTAKE SHOULD BE REPORTED BACK IMMEDIATELY/ यहाँ जन्म से पहले भ्रुण का लिंग जाँच नहीं होता है ।



A.L.C. Advance Imaging Diagnostics

ISO 9001:2015 Certified center

(A Unit of P.K.Arogyam Health & Wellness Center)

E-95, P.C. Colony, Near Sai Netryalaya Transformer, Kankarbagh, Patna - 20

alcdiagnostics@gmail.com

www.pkarogyamhealthcheckup.com

7050037694, 8271206196

OPINION MUST BE CORRELATES WITH CLINICALLY & OTHER INVESTIGATION FOR FINAL DIAGNOSIS. NOT FOR MEDICO LEGAL PURPOSE

PATIENT NAME : Mr. SINGH AMRITESH KUMAR PATIENT ID: 4070

COL DATE : 12/03/2022 REPORTING DATE: 12/03/2022 AGE SEX : 41 YRS/M

REF.BY : DR. /MEDIWHEEL.

TEST NAME	RESULT	Unit	REF.RANGE
Total Triiodothyronin T3	1.01	ng/mL	0.80 -2.00 ng/mL
Total Thyroxin T4	6.90	µg/dL	5.10 -14.10 µg/dL
Serum TSH	1.11	µIU/mL	0.27 – 4.20 µIU/mL

THYROID DISORDER (>: Increase: < Decrease: n Normal

1. T3(n) T4(n) TSH(n) :EUTHYROID STATE:
2. T3(>) T4(>) TSH(<): HYPERTHYROIDISM:
3. T3(<)T4(<) TSH(>): HYPOTHYROIDISM:
4. T3(n)T4(n) TSH(>) : SUB-CLINICAL HYPO-THYROIDISM:
5. T3(n)T4(n) TSH(<): SUB-CLINICAL HYPER-THYROIDISM:
6. T3(>) T4(n) TSH(<): T3 THYROTOXICOSIS:

Total T3/T4 level is dependent on Level:

So determination of free T3/T4is a better MARKER of Thyroid Function.



Dr. Ankur Kumar
MBBS, MD
Consultant Pathologist
Reg. No 39540

Consultant Radiologist

Dr. Kumari Suman
MBBS, DCO, MD
Consultant (TVS & HSG Specialist)

ESTD BY-

Dr. P. K. Tiwari
MD, M.Sc (Radio Imaging)
Ph.D (M.A Nuclear Medicine)
Consultant Imaging & Sardiya

Dr. S. Kumar
MD (Pat)
Consultant Pathologist

Dr. Abhishek Kumar
MBBS, MD
Consultant Neuropaths Physiologist

Dr. Anjali
MBBS, MD
Consultant(TMT,EEG Specialist)

PRINTING MISTAKE SHOULD BE REPORTED BACK IMMEDIATELY

ID: 4070 CASE: 1
 AGE: 42Y 0M 08D MR AMRITESH KUMAR SINGH
 160Cms 69Kg MALE

12/03/2022 10:24:19
 ALC ADVANCE IMAGING DIAGNOSTICS
 E95 PC COLONY KANKARBAGH PATNA

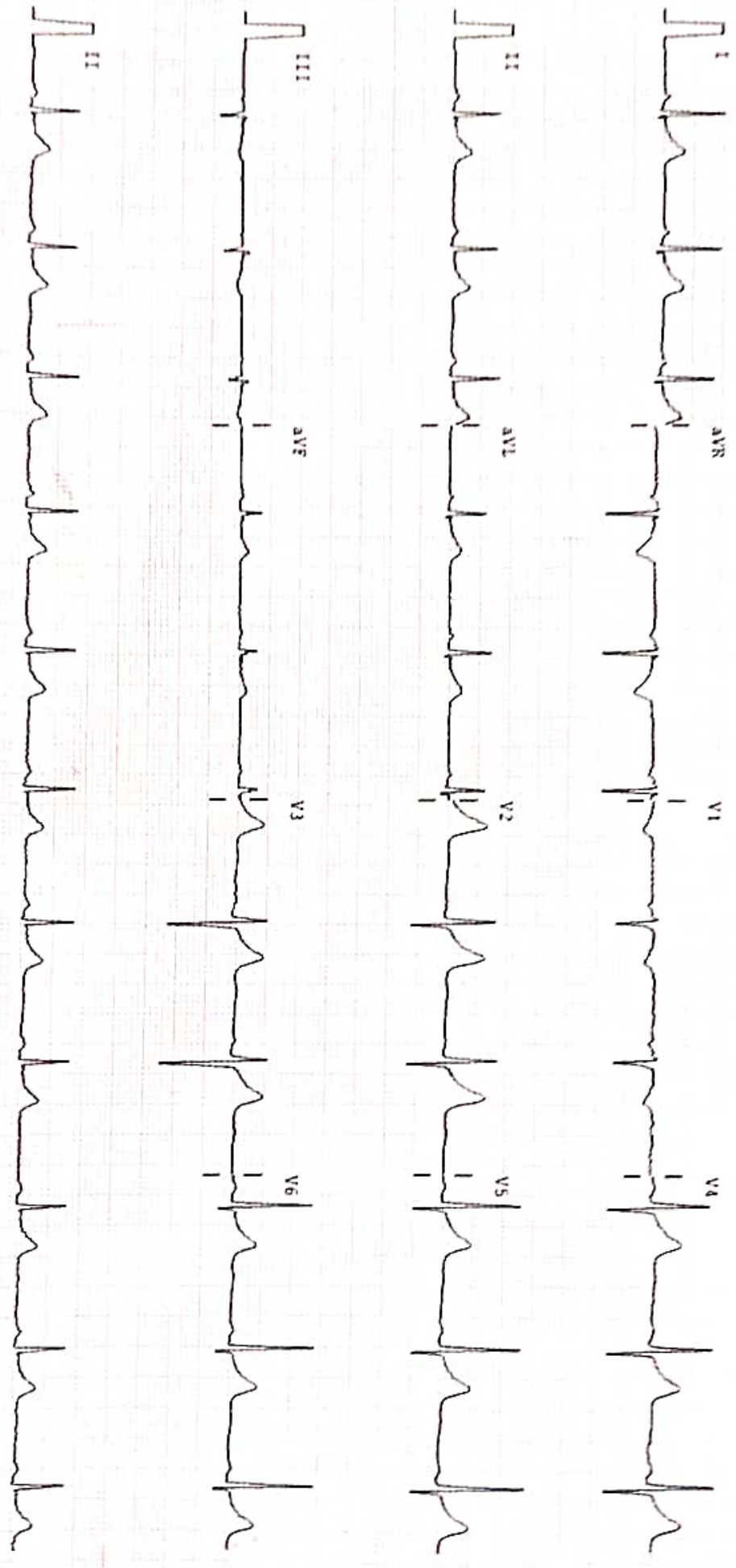
RATE: 64 bpm SINUS RHYTHM
 R-R: 931 ms POSSIBLE SEQUENCE ERROR: V2, V3 OMITTED
 P-R: 112 ms
 QRS: 78 ms
 QT: 384 ms
 QTc: 391 ms

..ANIS..
 P: 18°
 QRS: 20°
 T: 19°
 NORMAL ECG

12 SL. REPORT FORMAT: 3x4+1L, SO REF: DR BOB DR. DR. ABHISHEK KUMAR MBBS MD



Dr. Abhishek Kumar
MBBS, MD



25mm/sec 10mm/mV Notch: ON ECG: ON 0.05 - 35Hz ALLEGERS PISCES 10121VER... 1.81 CLINICALLY CORRELATE THE FINDINGS.