

CHIRAG IMAGING CENTRE

Opp. Dr. Manke Hospital, Lic Godhra-389001. Ph : 02672-252425



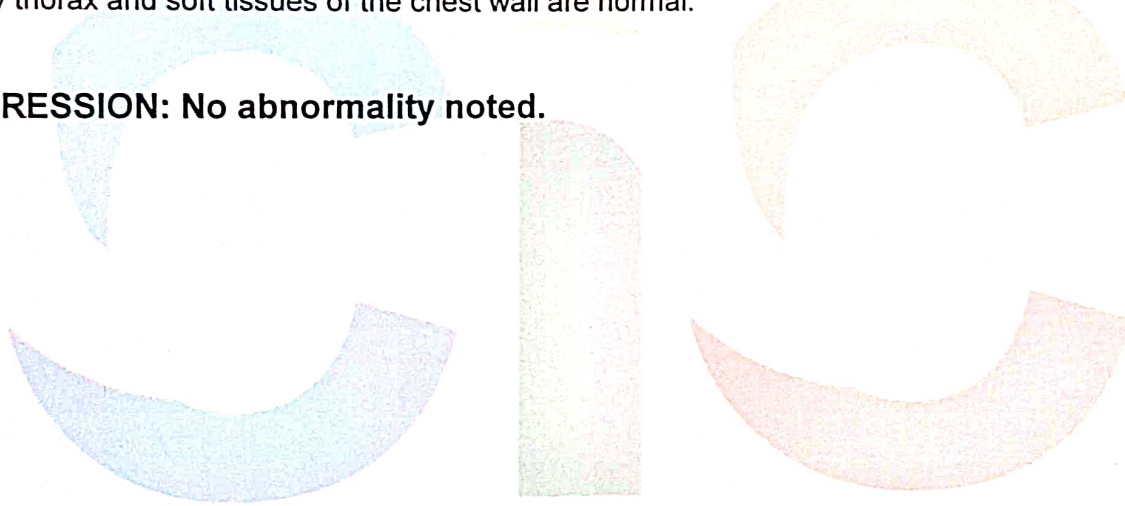
Date:26/02/2022

Name:KAMLESH KUMAR 34 Years / Male
Ref By:DR. DISHA LAB

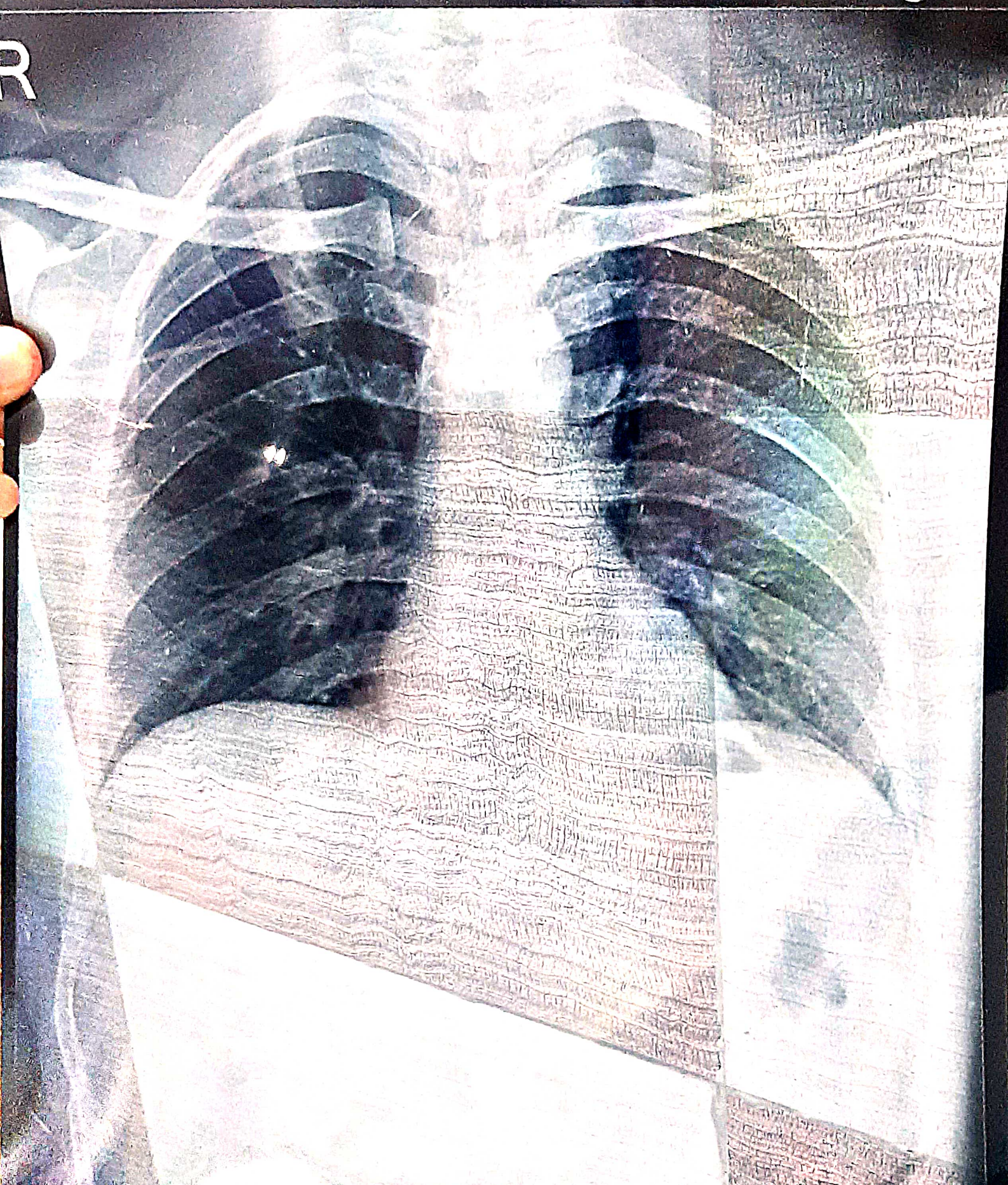
X-RAY CHEST (PA VIEW)

Both lung fields appear normal.
No evidence of koch's lesion or consolidation seen.
Both cardiophrenic, costophrenic angles and domes of the diaphragm are normal.
The cardiac size is within normal limit.
Trachea is central, no mediastinal shift is seen .
Mediastinal outlines do not show any abnormality.
Bony thorax and soft tissues of the chest wall are normal.

IMPRESSION: No abnormality noted.



Dr. Chirag J. Muniya
M.D., Radiology
Reg No. 18177



KAMLESH KUMAR 29 YRS 26022206 DISHA LAB M CHEST PA 26-02-2022 11:27 AM
CHIRAG IMAGING CENTRE GODHRA, PH NO-02672 252425
CHIRAG IMAGING CENTRE, GODHARA. PH: (02672) 252425

Date:26/02/2022

Name:KAMLESH KUMAR 34 Years / Male
Ref By:DR. DISHA LAB

ULTRASOUND WHOLE ABDOMEN

LIVER: 134mm in mid axillary line and appears normal in size and in echo pattern.
No focal intra-hepatic lesion detected. Intra-hepatic biliary radicals are not dilated.
Portal vein appears normal in course and caliber.

GALL BLADDER: Appears echo free with normal wall thickness.
Common Bile duct measures 5 mm. No evidence of calculus or mass lesion seen within CBD.

PANCREAS: Appears normal in size and echo pattern.
SPLEEN: 100mm along long axis and appears normal in size & echo pattern.

KIDNEYS:
Right kidney measures 88 X 37 mm and appears normal in position, size and in outline.
Corticomedullary differentiation maintained. No e/o focal mass lesion.
No evidence of calculus or hydronephrosis seen.

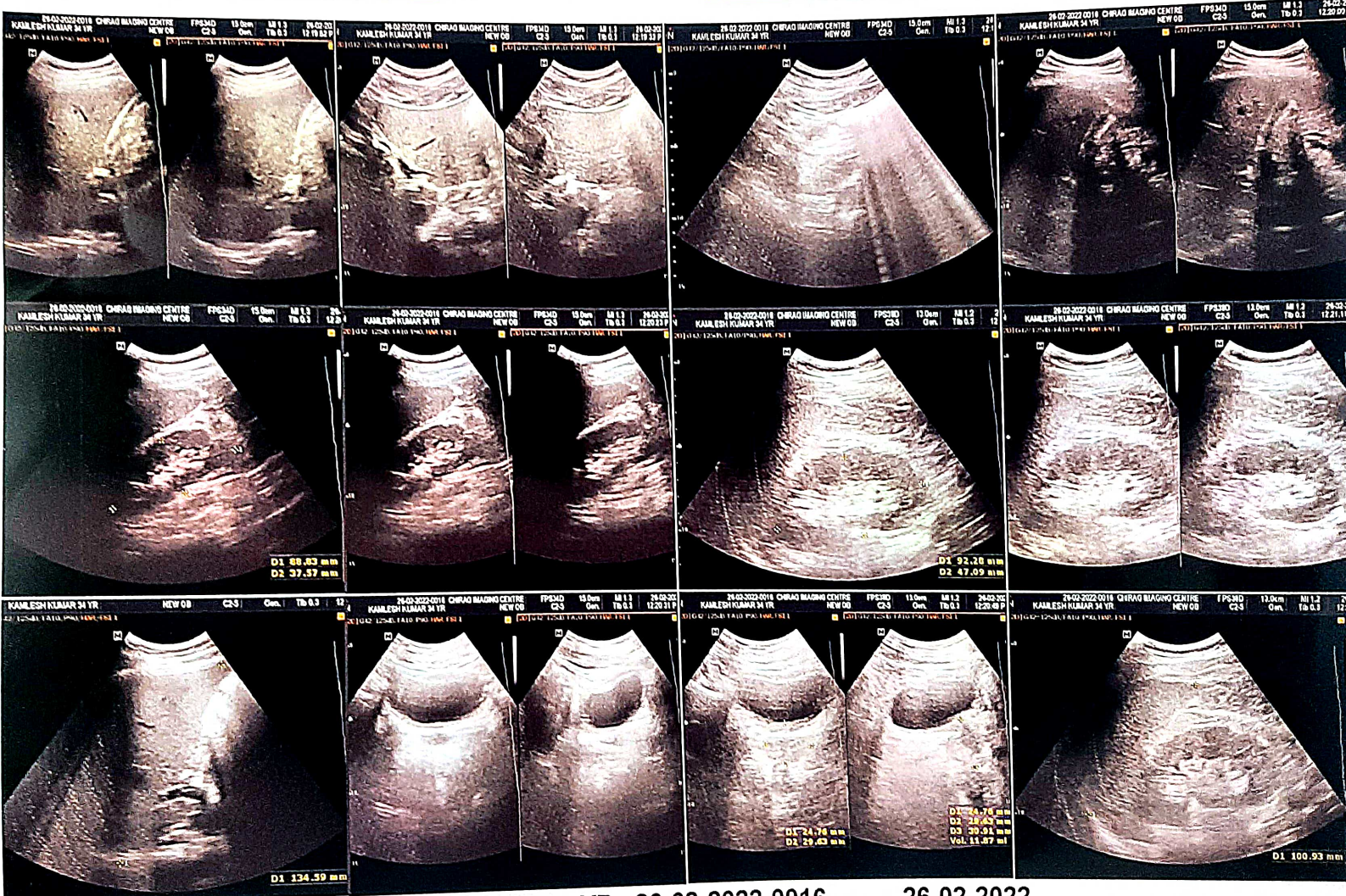
Left kidney measures 92 X 47 mm and appears normal in position, size and in outline.
Corticomedullary differentiation maintained. No e/o focal mass lesion.
No evidence of calculus or hydronephrosis seen.

URINARY BLADDER: Appears distended with clear contents and wall thickness WNL.
No evidence of calculus or mass lesion seen.

Prostate measures 24 X 29 X 30mm, volume around 11cc and appears normal in size shape and echopattern.

Visualized parts of retro peritoneum do not reveal any lymphadenopathy.
No evidence of free fluid seen in abdomen.
No evidence of abnormal dilatation or wall thickening of bowel loops seen.
No evidence of collection or mass lesion seen in RIF

IMPRESSION : No significant abnormality seen in this study.



KAMLESH KUMAR 34 YR 26-02-2022-0016

26-02-2022

CHIRAG IMAGING CENTRE