

DAKSH HOSPITAL

396 - 397, Gandhi Nagar, Scheme No. 8, ALWAR -301001

Ref. No.

Date.....

MEDICAL EXAMINATION REPORT
Mediwheel (BOB)

Name: Mrs. Priya

Age: 28 yrs

Sex: Female

Date: 23/09/2023

General Physical ExaminationHeight : 170 cm
Pulse : 74 /mt
Respiration : 18 /mtWeight : 69.6 kg
BP : 120/70 mm/hg
BMI : 24.1 kg/m²Systemic Exam:-

NAD. (Normal)

Dental Check up :-

NAD (Normal)

Eye check-up :-

NAD (Normal)

Skin Check up:-

Normal

ENT Check up:-

Normal

Gynae Check up:-2/35 of RMC - P10 max
on - NIL Paps smear laterImpression:-TSH - Mild increase 6.12
USG - both ovaries appear enlarged w/ multiple follicular cystsRecommendation:-

Ad. Anti TPO Antibody. /

Dr. Mukesh Kumar Gupta
 MBBS Gen Med & Surg
 Reg. No. 342316
 फिजिशियन एवं मधुमेह विशेषज्ञ
 दक्ष हॉस्पिटल, अलवर
 रजि० नं०-5423/16262

Results

Run Date 23/09/2023 10:49:00 AM

Operator DAKSH

Last Name

Sample ID 7

First Name MRS PRIYA GANDHI

Department

Gender Female Age

Physician DR. MUKESH GUPTA M.D

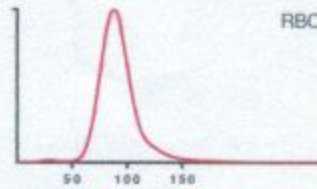
Patient ID AUTO_PID16198

Type Woman

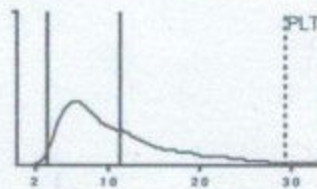
Date of birth

Sample comments

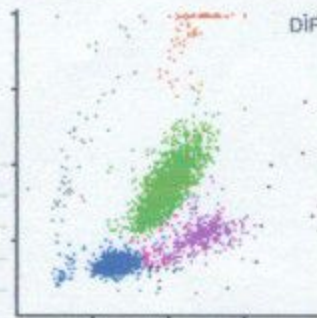
				Range
RBC	4.16	*	10 ⁶ /μL	3.80 - 5.50
HGB	12.9		g/dL	11.5 - 15.2
HCT	41.1	*	%	35.0 - 46.0
MCV	98.8	h*	μm ³	77.0 - 97.0
MCH	31.0		pg	26.0 - 34.0
MCHC	31.4	L	g/dL	32.0 - 35.0
RDW-CV	15.3		%	11.0 - 17.0
RDW-SD	56.2	H	μm ³	37.0 - 49.0



				Range
PLT	264		10 ³ /μL	150 - 450
PCT	0.28		%	0.15 - 0.40
MPV	10.4		μm ³	8.0 - 11.0
PDW	16.6		μm ³	11.0 - 22.0
P-LCC	93		10 ³ /μL	44 - 140
P-LCR	35.3		%	18.0 - 50.0



				Range
WBC	6.20		10 ³ /μL	3.50 - 10.00
	#			
NEU	3.34		1.60 - 7.00	54.1 40.0 - 75.0
LYM	2.39		1.00 - 3.00	38.8 20.0 - 45.0
MON	0.21		0.20 - 0.80	3.3 2.0 - 10.0
EOS	0.16		0.00 - 0.50	2.6 1.0 - 6.0
BAS	0.07		0.00 - 0.15	1.2 h 0.0 - 1.0
LIC	0.03		0.00 - 0.10	0.5 0.0 - 1.0



Dr. R.S. Gupta
Dr. R. S. GUPTA
 MD (Pathology) (MAHE)
 RMC No. 79778

Date :- 23/09/2023 Name :- MRS. PRIYA GANDHI
 Refd. :- Dr Mukesh Gupta M.D.

Age & Sex :- 28Yrs/Female

	TEST NAME	RESULT	REFERENCE RANGE
	ESR		12 00 -20 mm/hrs
	Blood Group & Rh Factor	O ⁺ POSITIVE	
	HbA1C	4.97	4 - 5.6%
	Blood Sugar (F)	83.1	< 70 - 100 mg/dl
	Blood Sugar (PP)	108.1	< 140 mg/dl
	Urine Sugar (F)	NIL	-
	Urine Sugar (PP)	NIL	-
LIVER	S.Bilirubin Total	0.90	0.30 - 1.20 mg/dl
	S.Bilirubin Direct	0.20	0.10 - 0.30 mg/dl
	S.Bilirubin Indirect	0.70	0.30 - 0.90 mg/dl
	S.G.O.T.	26	u/l
	S.G.P.T.	35	u/l
	S.Aik. Phosp.	185	u/l
	G.G.T.	19.1	5 -10 u/l
	Total Protein	6.9	6.5 - 8.5 gm/dl
	Albumin	3.8	3.8 - 5.4 gm/dl
	Globulin	3.1	2.3 - 3.5 gm/dl
	A/G Ratio	1.2	-
	AST/ALT Ratio	0.7	-
KIDNEY	Blood Urea	25.1	15 -45 mg/dl
	S.Creatinine	0.8	0.60 - 1.30 mg/dl
	BUN	20.1	6 -24 mg/dl
	S.Uric Acid	5.2	M 3.1 - 7.0, F 2.5 - 5.6 mg/dl
	BUN/Creatinine Ratio	25.1	-
LIPID PROFILE	Total Cholesterol	140.1	Up to 200 mg/dl
	S.HDL	42.1	30 - 70 mg/dl
	S.LDL	54.1	Up to 170 mg/dl
	S.VLDL	24.1	5.0 - 40 mg/dl
	S. Triglycerides	120.1	Up to 170 mg/dl
	LDL/HDL Ratio	1.2	-
	Total Cholesterol/ HDL Ratio	3.2	-
THYROID	T3	102.1	40 -181 ng/dl
	T4	6.9	4.6 - 10.5 µg/dl
	TSH	6.12	0.30 - 5.0 mIU/L

URINE EXAMINATION

Microscopic Examination :

General/Chemical Examination:	Colour	Pale Yellow	RBC	Absent
	Reaction	Acidic	WBC	1 - 2
	Specific Gravity	QNS	Epithelial Cells	0- 1
	Appearance	Clear	Cast	Absent
	Albumin	Nil	Crystal	Absent
	Sugar	Nil	Spermatozoa	Absent
			Amorphous Sediments	Absent
		Other	Absent	

X-RAY CHEST

NORMAL STUDY

STOOL EXAMINATION

Microscopic Examination :

General/ Chemical Examination:	Colour	-	RBC	-
	Consistency	-	WBC	-
	PH	-	Ova & Parasites	-
	Reducing Substances	-		

Doctor

R. S. GUPTA
 (Pathology) (MAHE)
 1174119773

TECHNOLOGIST

All investigation have their own limitations regarding the sensitivity & specificity of individual assay procedures, Isolated laboratory investigations never confirm the final diagnosis of the disease. They only help in arriving at a diagnosis in conjunction with clinical presentation and other related investigations. Report is not valid for medico-legal purpose subject to ALWAR jurisdiction only.

Date :- 23/09/2023

Name :- Mrs. Priya

Refd. :- Dr Mukesh Gupta MD

Age & Sex :- 28Yrs/ Female

CYTO-PATHOLOGY

PAP SMEAR

1. Specimen type	Received two conventional smears.
2. Specimen adequacy	Smears are satisfactory for evaluation.
3. Microscopic finding	Smears are moderately cellular comprises of predominantly intermediate with mature superficial squamous epithelial cells arranged in clusters & scattered singly.
4. Inflammation	Not seen
5. Bacilli	Not seen
6. Endocervical cells	Not seen
7. Koilocytic changes	Not seen
8. Trichomonas	Not seen
9. Dysplasia	Nil
10. Neoplasia	Nil
11. Endometrial cells	Nil

Impression:- Negative for intraepithelial lesion or malignancy


Dr. R.S. GUPTA
MD (Pathology) (MAHE)
RMC No. 7924/19778

Doctor


TECHNOLOGIST

All investigation have their own limitations regarding the sensitivity & specificity of individual assay procedures, isolated laboratory investigations never confirm the final diagnosis of the disease. They only help in arriving at a diagnosis in conjunction with clinical presentation and other related investigations. Report is not valid for medico-legal purpose subject to ALWAR jurisdiction only.



दक्ष हॉस्पिटल

396, गाँधी नगर स्कीम नं.8, अलवर (राज०) ☎ 0144-2703340

Sonography / 2D Echo Cardiography / Doppler Report

2D/ ECHO REPORT

Name: - Mrs Priya Gandhi

Age: - 28 Yrs

Date: - 23-Sep-23

Reg. No.: - Alw/2009/04
BOB health checkup

PROCEDURES:

M-MODE/2D/DOPPLER/COLOR/CONTRAST B.A.S. M²

MEASUREMENT:		DOPPLER:	
AOD	23	NORMAL	NORMAL (cm/sec.)
LA	22	(20- 37mm)	MV 0.54 (0.8- 1.3) MR No
AVO	16	(19- 40mm)	AV 1.3 (1.2- 1.8) AR No
RVDd.	12	(12- 25mm)	TV 0.6 (0.3- 0.8) TR No
		(03- 09mm)	PV 0.8 (0.7- 1.1) PR No
LVDd	46	(37- 56mm)	MITRAL VALVE-
LVDs	29	(22- 40mm)	AML Normal
IVS d	8	(06- 12mm)	PML Normal
IVS s	11		
PWd	4.5	(05- 10mm)	AORTIC VALVE Normal
LV FUNCTION		TV & PV are normal.	
M- E- S Separation	<0.9cm		
Minor	24.42%		
LV Ejection Fraction	66%	65 +/- 12%	

LV WALL MOTION: NO RWMA
ALL CARDIAC CHAMBERS ARE NORMAL
ALL VALVES ARE NORMAL
NO CLOT, VEGETATION, PERICARDIAL EFFUSION

FINAL DIAGNOSIS: NORMAL STUDY

Adv: - Follow up/ review at higher center for confirmation

Note:- Please Correlate clinically. Due to technical limitations as well as inaccuracies inherent in the laboratory and statistical analysis of biological process. Diagnostic accuracy of ECHO is up to 95% only.
Report is not valid for medico-legal purpose.


Dr. DHRUV KUMAR GUPTA
PHYSICIAN & SONOLOGIST
RM 5423/16262



"भ्रूण लिंग परीक्षण की शिकायत
104 टोल फ्री सेवा पर भी की
जा सकती है"

भ्रूण लिंग परीक्षण की शिकायत 104 टोल फ्री सेवा पर भी की जा सकती है।



दक्ष हॉस्पिटल

396, गाँधी नगर स्कीम नं.8, अलवर (राज०) ☎ 0144-2703340

Sonography / 2D Echo Cardiography / Doppler Report

NAME :- MRS PRIYA GANDHI/F/28 YRS

23-Sep-23

BOB HEALTH CHECKUP

U.S.G. OF ABDOMEN & PELVIS

LIVER

Liver is 12.3 cm at MCL with normal echo-texture. Intra hepatic biliary radicals Are not dilated. No evidence of focal or diffuse lesion.

GALL BLADDER

Gall bladder is normally contracted, visualized lumen appear normal.

PANCREAS

Pancreas is normal in size, shape & echo-texture. No evidence of focal or diffuse lesion. MPD not dilated.

SPLEEN

8.6 cm in size with normal shape & echo- texture. Spleen vein is normal. No evidence of focal or diffuse lesion

KIDNEY

Both kidneys are normal.

URINARY BLADDER

UB is normal.

UTERUS:

Uterus is normal in size (9.8x3.5x4.9cm) with homogenous echo-texture. Endometrial 14 mm in thickness & echo genicity

OVARIES:

Both ovaries appear mild enlarged & have multiple follicular cyst.

Advice- follow up/ hormonal study review at higher center for confirmation

Please correlate clinically. USG accuracy is 95 % due to technical limitations as well as inaccuracies inherent in the laboratory and statistical analysis biological process.
This report is not valid for medico-legal cases


DR. MUKESH GUPTA
Physician & Sonologist
RM 5423/16262



"भ्रूण लिंग परीक्षण की शिकायत
104 टोल फ्री सेवा पर भी की
जा सकती है"

भ्रूण लिंग परीक्षण की शिकायत 104 टोल फ्री सेवा पर भी की जा सकती है।

ID: 958

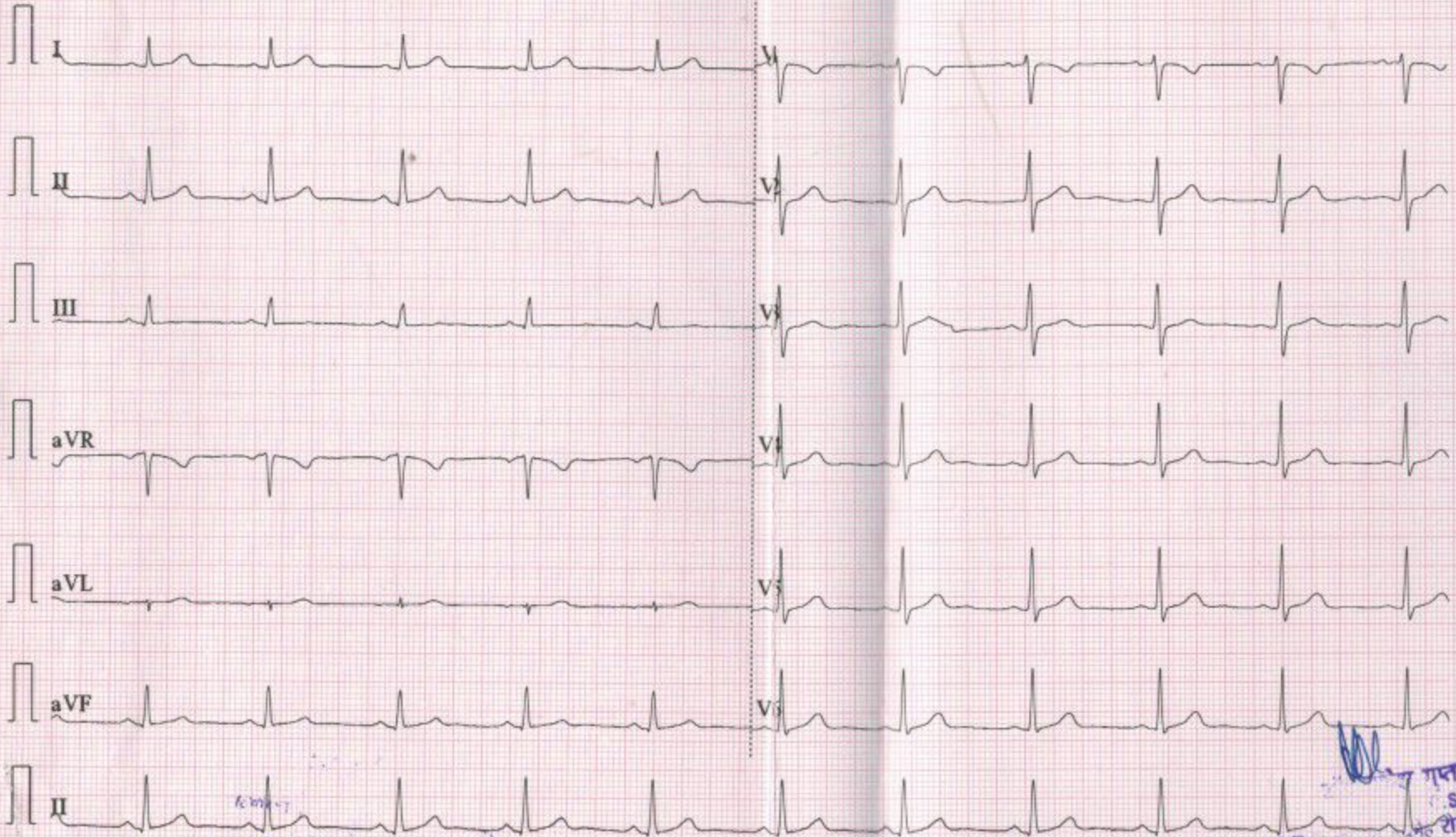DPL-02 23-09-2023 13:37:07

Female / Years
Req. No. :

HR : 66 bpm
 P : 104 ms
 PR : 134 ms
 QRS : 94 ms
 QT/QTcBz : 392/411 ms
 P/QRS/T : 66/55/39 °
 RV5/SV1 : 1.098/0.661 mV

Diagnosis Information:
 Sinus rhythm
 Normal ECG

Report Confirmed by:



(Handwritten signature)
 S. S. S. S.
 रजि. नं. 5423/16262
 अलवर
 अलवर

R

00

00

1000

