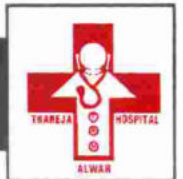



THAREJA NURSING HOME



DIGITAL X-RAY, OPG, COMPUTERISED ECG & EEG, DIAGNOSTIC LABORATORY EQUIPED WITH COMPUTERISED AUTO ANALYZER & CBC

1, Ram Kuteer, Company Bagh Road, ALWAR - 301001 (Raj.) Ph: 0144-2700184, 2331842

PROPOSAL NO. PKG10000227

Date 27/01/2023

Patient Name ABHINAV JAIN

Age 38 Yrs.

Ref. By Dr. M. N. THAREJA

Sex M

Details of packages		Patients report	Units	Normal value
HB		14.8	gm%	M-13.5-18, F-11.5-16.5
TRBC		5.06	million /cu mm	M-4.0-5.5, F-3.9-5.6
TWBC		9,900	cu mm	4000-11000
DLC	Polymorphs	60	%	42-75
	Lymphocytes	32	%	20-50
	Eosinophil	08	%	1-6
ESR		02	mm 1 st Hr.	M-0-9, F-0-20
Platelets		1,86,000	Lack / cu mm	1.5-4
PCV		42.1	%	37-54
MCV		83.2	Cubicmicrons	86-98
MCH		29.2	Picograms	26-34
MCHC		35.2	%	32-36
Blood Grouping & Rh Factor		"B"Rh+(POSITIVE)		
BUN		12.0	mg %	M-7-20
S. Creatinine		0.81	Mg/100ml	0.9-1.4 mg /100 ml
HBsAg		-		
HIV I & II		-	Elisa Method	
HbA1C		5.6	%	4-6%
VDRL		-		

Details of packages		Patients report	Units	Normal value	
LFT	GGTP	16.0	U/L	5-60	
	SGOT	18.0	Units / ml	Upto 40	
	SGPT	21.0	Units / ml	Upto 40	
	S. Bilirubin	Total Bilirubin	0.50	mg%	Upto 1.2
		Direct Bilirubin	0.30	mg%	0-0.25
		Indirec Bilirubin	0.20	mg%	
		T. Protein	7.64	Gm%	6.2-8.3
	S. Albumin	4.32	Gm%	3.2-5.3	
	Globulin	3.32	Gm%		
	Alkaline phosphate	102.0	IU/L	60 - 170	
S. Calcium	-	Gm%	8.5-10.5		
Uric Acid	3.78	Mg%	2.5-7 mg%		
Blood Sugar Fasting		77.0	Mg%	60-110 mg %	
Blood Sugar PP		117.0	Mg%	Upto 160	
Lipid Profile	S. Cholesterol	205.0	mg%	120-220	
	S. Triglycerides	130.0	mg/ml	Upto 170	
	HDL Cholesterol	54.0	IU/L		
	LDL cholesterol	125.0	IU/L	450 at 37° C	
	VLDL	26.0	mg %	Upto 35	

Routine Urine Analysis

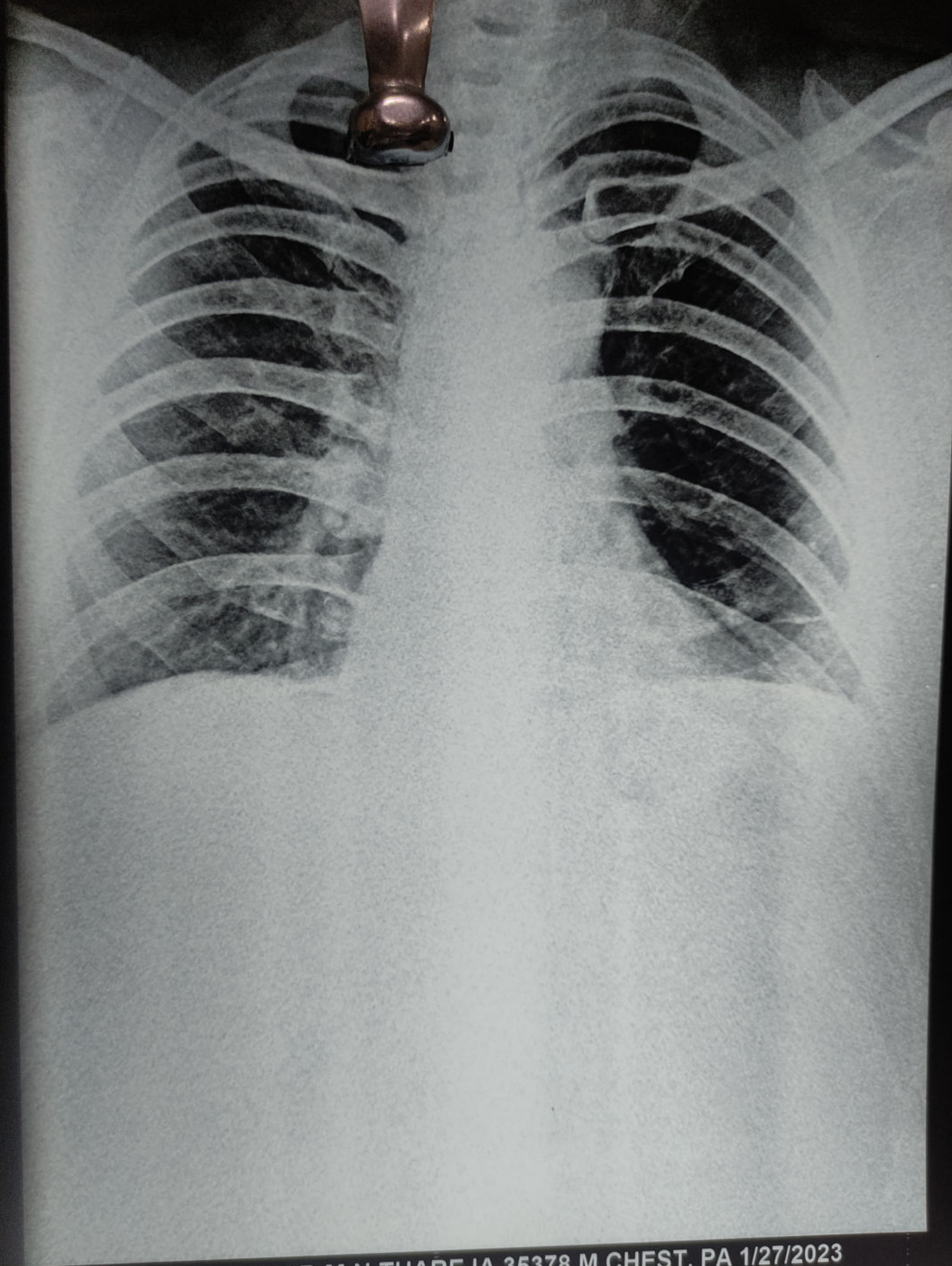
Physical/ Chemical		Microscopic:	
Appearance	Clear	RBCs	Nil
Specific Gravity	1010	WBCs	1-2/ HPF
Ph	ACIDIC	Epith. Cells	2-3/HPF
Albumin	Nil	Casts	Nil
Glucose F	NIL	Crystals	Nil
Ketones	----	Bacteria	Nil
Blood	Nil	Glucose P.P.	<u>NIL</u>

Signature of Technician

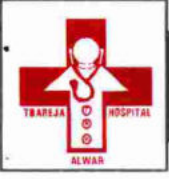Signature of Doctor

This Report is not Valid for Medical Legal Purpose

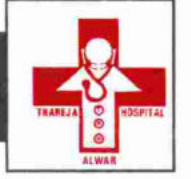RIGHT



ABHINAV JAIN 38 Y BY DR M.N.THAREJA 35378 M CHEST, PA 1/27/2023
THAREJA NURSING HOME. COMPANY BAGH ROAD, ALWAR



THAREJA NURSING HOME



DIGITAL X-RAY, OPG, COMPUTERISED ECG & EEG, DIAGNOSTIC
LABORATORY EQUIPED WITH COMPUTERISED AUTO ANALYZER & CBC

1, Ram Kuteer, Company Bagh Road, ALWAR - 301001 (Raj.) Ph: 0144-2700184, 2331842

PROPOSAL NO.

Date 27-01-2023

Patient Name ABHINAV JAIN

Age 38 Yrs.

Ref. By Dr. M. N. THAREJA

Sex M

PART - X-RAYED : X-RAY CHEST PA VIEW
REPORT : X-RAY CHEST P.A. VIEW
:- Chest is bilaterally symmetrical.
:- C.P. Angles are clear.

CONCLUSSION: NORMAL STUDY

V. Jey

Signature of Technician

Prinani

Signature of Doctor

Pat-Name:

Abhinav Jain

Age: 38 M / F

27/11/23

..... mmHg

..... cm /

..... kg

HR 73/min

Axis:

P 37°

QRS -9°

T 26°

Intervals:

RR 822 ms

P 116 ms

PR 134 ms

QR 88 ms

QT 364 ms

QTc 484 ms

P (II) 0.11 mV

S (V1) -1.11 mV

R (V5) 0.63 mV

50kOhm, 2.52 mV

5.70

SINUS RHYTHM

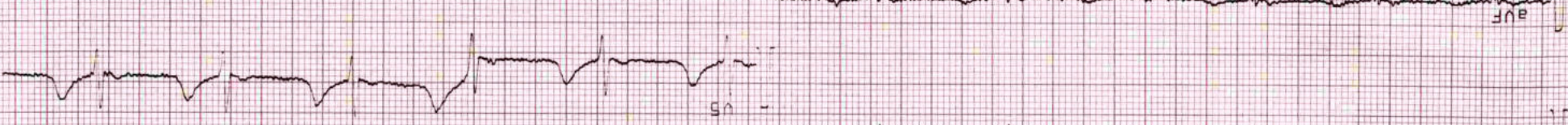
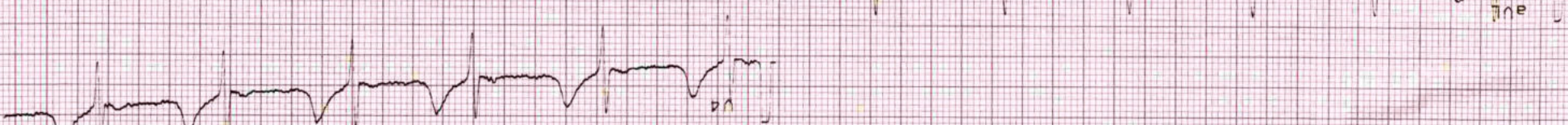
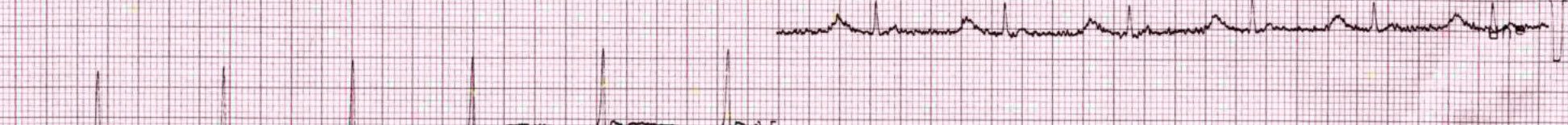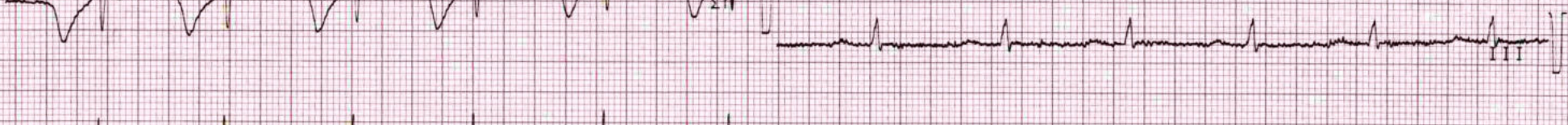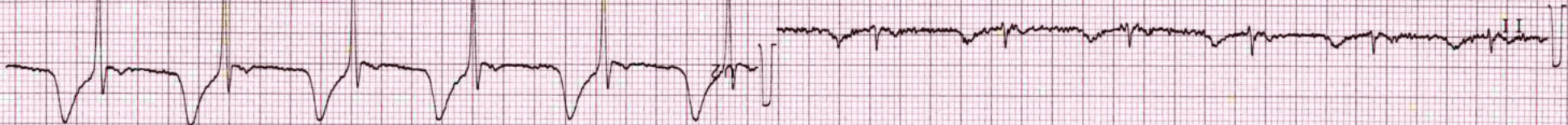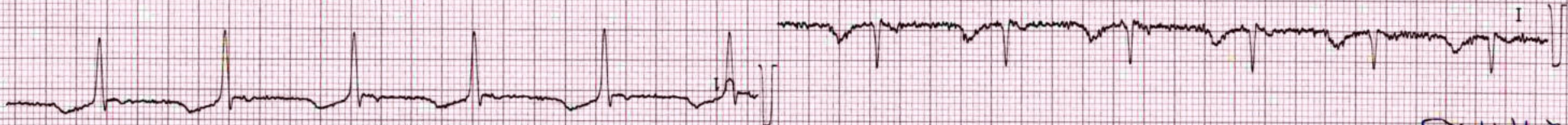
LEFTWARD AXIS

OTHERWISE NORMAL ECG

UNCONFIRMED REPORT

Signature

10 mm/mV



0.05-35 Hz F50 FN 27-JAN-23 12:00:59 AT-2 C 3.03



दक्ष हॉस्पिटल

396, गाँधी नगर स्कीम नं.8, अलवर (राज०) ☎ 0144-2703340

Sonography / 2D Echo Cardiography / Doppler Report

2D/ ECHO REPORT

Name: - Mr. Abhinav Jain

Age: - 38 Yrs

Date: - 27-Jan-23

Reg. No.: - Alw/2009/04

PROCEDURES:

M-MODE/2D/DOPPLER/COLOR/CONTRAST B.A.S. M²

MEASUREMENT:			DOPPLER:					
		NORMAL			NORMAL (cm/sec.)			
AOD	25	(20- 37mm)	MV	0.54	(0.8- 1.3)	MR	No	
LA	24	(19- 40mm)	AV	1.3	(1.2- 1.8)	AR	No	
AVO	18	(12- 25mm)	TV	0.6	(0.3- 0.8)	TR	No	
RVDD.	15.7	(03- 09mm)	PV	0.8	(0.7- 1.1)	PR	No	
LVDD	51	(37- 56mm)	MITRAL VALVE-					
LVDS	32	(22- 40mm)			AML		Normal	
IVS d	11.8	(06- 12mm)			PML		Normal	
IVS s	12.8							
PWd	9.8	(05- 10mm)	AORTIC VALVE					Normal
LV FUNCTION			TV & PV are normal.					
M- E- S Separation		<0.9cm						
Minor		24.42%						
LV Ejection Fraction	66%	65 +/- 12%						

Mitral E>A

LV WALL MOTION: NO RWMA

ALL CARDIAC CHAMBERS ARE NORMAL


ALL VALVES ARE NORMAL

NO CLOT, VEGETATION, PERICARDIAL EFFUSION

FINAL DIAGNOSIS: NORMAL STUDY

Adv: - Follow up/ review at higher center for confirmation

Note:- Please Correlate clinically. Due to technical limitations as well as inaccuracies inherent in the laboratory and statistical analysis of biological process. Diagnostic accuracy of ECHO is up to 95% only. Report is not valid for medico-legal purpose.


DR. MUKESH GUPTA Gupta
PHYSICIAN
Physician & Sonologist
RM 5423/16262



भ्रूण लिंग परीक्षण की शिकायत 104 टोल फ्री सेवा पर भी की जा सकती है।



THAREJA NURSING HOME

1, Ram Kuteer Company Bagh Road, ALWAR - 301001 (Raj.)
Mob. 9982111801, Ph. 0144-2700184, 2331842, Telefax: 0144-2342339
E-mail: drmnthareja@yahoo.com



Name Mr. Abhinav Jain Age 38 Yr OPD/UHID..... Date 27/1/23

Address Mobile No.....

VITALS	B.P.	Pulse	Temp.	Wt.	Ht.	Allergies
--------	------	-------	-------	-----	-----	-----------

Complaints

Routine eye check up

Findings

*VA - 6/6
6/6*

*- N6
N6*

*S/L
cornea clear B/E*

*Color vision - WNL
WNL*

Treatment

Adv

Both eyes within normal limit

DR. M.N. THAREJA
7233 (RMC)
Male Infertility Specialist

DR. SAVITA THAREJA
7600 (RMC)
Female Infertility Specialist

DR. JAYANT THAREJA
A-0824 (RSDC)
M.D.S.
Oral & Maxillo - Facial Surgery
Ex Resident Trauma Centre,
AIIMS, Delhi

DR. SHIVANI THAREJA
10807 / 31220 (RMC)
Ophthalmologist
Cornea Specialist

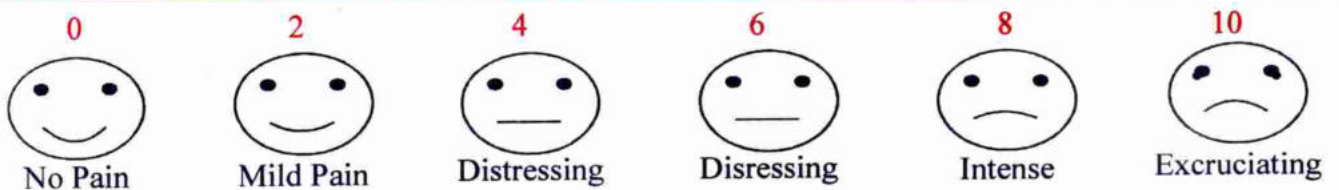
DR. PRERNA THAREJA
A-3574
MDS (Endodontics)
Root Canal Specialist
Ex Resident
AIIMS, Jodhpur


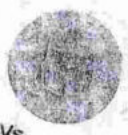

DR. H.R. GUPTA
1744 (RMC)
Senior Consultant
M.S. Gen Surgeon

DR. VARUN SAPRA
Reg. No. 70990 (DMC)
MBBS DNB ORTHO, D.ORTHO
Joint Replacement &
Arthroscopy Surgeon

Shivani
Dr. Shivani Thareja
M.S. (OPHTHAL)
Fellow (CORNEA)
L.V. Prasad Eye Institute
CORNEA CONSULTANT

Pain Scale



GOVT. OF RAJASTHAN  CENTRAL MOTOR VEHICLES RULES, 1989
FORM 7(See rule 16(2)) DUPLICATE Issue Date: 13/01/2006
DL No: **RJ02 20060141897**
Name: **ABHINAV JAIN**
S/o: **LALIT KUMAR JAIN**
DOB: 24/09/1984
Authorised to drive the following COVs
throughout India:-
NT:
TR:
Hazardous Validity
Hill Validity Upto:


Valid Upto
12/01/2026
(Licensing Authority, ALWAR)

Abhinav Jain

Shivani

Address:
416, SCHEME NO-8
ALWAR
RAJASTHAN
Pin Code : _____ Blood Group: _____
Badge Details
Authorization No.: _____ Date: _____
ID. Marks:
 Endorsement No.: RJ02 /DLD/0004136/2011
Endorsement Date.: 21/10/2011



MEHAR'S

SAHARA DIAGNOSTICS

Reg. No. NHM/434

Dr. R.D. Arora

M.D., D.M.R.E (Radio-dagnosis)

University Topper

R.M.C. Reg. No. 28052 & 009456

Mob.: 9829136035

The Healing Ashram, 12 Kailash Colony, Bhagat Singh Circle, Alwar

27 JAN 2023

NAME : abhinav jain

Clinician: Dr

FOR : ABDOMEN

c/o pain abdomen [indication/ reason for scan]

Patient information -Technically poor quality scans because of obesity and thick abd wall +hypersthenia

On real time B-mode sonography

Liver is enlarged in size and echo pattern enhanced, no SOL is seen. Hepatic and portal veins are normal. CBD is normal in caliber, no obstruction is seen.

Gall Bladder is normal in size and shape, no calculus or inflammation is seen.

Pancreas is normal in size and echopattern, no SOL is seen.

Spleen is normal in size and echopattern, no SOL is seen.

Kidneys, bilaterally are normal in size and shape, no calculus or dilated calyces are seen.

Right Iliac region appendix could not be traced at present

No evidence of ascites, free Pleural effusion or lymphadenopathy is seen.

Urinary Bladder is normal in size, wall is normal in thickness, no calculus or growth is seen.

Prostate normal

IMPRESSION:

Fatty liver gr 2

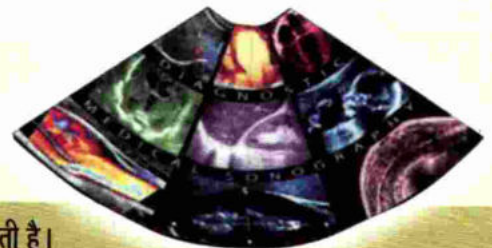
Further evaluation is suggested.

Patient information -Kindly note no luminal pathology can be detected in non distended urinary tract .

Dr Ram das arora

Ultrasound scan is an investigation and therefore has technical limitations as well as inaccuracies inherent in the laboratory and statistical analysis of biological process. It should always be viewed in this perspective. Further this is a routine general scan grossly containing information sought by ref consultant and report generated thus, is for his perusal only. Considering pace of advances in the field of sonography, more specified information can also be obtained by prior intimation.

- Consultant of Radiology works
- Working hours 10 a.m. to 4 p.m. On Call Basis



“ भ्रूण लिंग परीक्षण करवाना जघन्य अपराध है तथा इसकी शिकायत 104 टोल फ्री सेवा पर की जा सकती है।

“ • “बेटी बचाओं - बेटी पढ़ाओं “



THAREJA NURSING HOME



DIGITAL X-RAY, OPG, COMPUTERISED ECG & EEG, DIAGNOSTIC
LABORATORY EQUIPED WITH COMPUTERISED AUTO ANALYZER & CBC

1, Ram Kuteer, Company Bagh Road, ALWAR - 301001 (Raj.) Ph: 0144-2700184, 2331842

Name : **ABHINAV JAIN**

age **38**

Sex : **MALE**

Ref. By : **M.N. THAREJA**

Lab No. :

Date : **January 27, 2023**

HORMONES & MARKERS

Test	Value	Units	Biological Ref. Values
T3 (Total Triiodothyronine)	1.21	ng/dL	0.60-1.81 ng/dL Adults
T4 (Total Thyroxine)	4.80	µg/dL	3.2-12.60 µg/dL : Adults
TSH (Thyroid Stimulating Hormone)	5.49	µIU/mL	Adults : 0.35-5.50 µIU/mL

Interpretation of TSH :-

Children

0 Days : 1.0~39.0 uIU/mL
 5 days : 1.7~9.1 uIU/mL
 1 year : 0.4~8.6 uIU/mL
 2 years : 0.4~7.6 uIU/mL
 3 years : 0.3~6.7 uIU/mL
 4-19 years : 0.4~6.2 uIU/mL

Adults

20-54 years : 0.35-5.50 uIU/mL
 55-87 years : 0.5-8.9 uIU/mL

Pregnancy

1st Trimester : 0.30 - 4.50 µIU/mL
 2nd Trimester : 0.50 - 4.60 µIU/mL
 3rd Trimester : 0.80 - 5.20 µIU/mL

Interpretation of TSH :-

Children

3.20 - 34.6 µIU/mL 1- 2 Days
 0.70 - 15.4 µIU/mL 3 - 4 Days
 0.70 - 9.10 µIU/mL 15 Days - 5 Months
 0.70 - 6.40 µIU/mL 5 Months - 20 Years

Pregnancy

0.30 - 4.50 µIU/mL 1st Trimester
 0.50 - 4.60 µIU/mL 2nd Trimester
 0.80 - 5.20 µIU/mL 3rd Trimester

Method : **Fluorescence Immunoassay Technology**

Sample Type : **Fresh Blood Serum**

Remarks :

Primary malfunction of the Thyroid gland may result in excessive (hyper) or Low (hypo) release of T3 or T4. In addition, as TSH directly affect thyroid function, malfunction of the pituitary or the hypothalamus influences the thyroid gland activity.

Disease in any portion of the thyroid-pituitary-hypothalamus system may influence the level of T3 and T4 in the blood, in Primary Hypothyroidism,

TSH levels are significantly elevated, while in secondary and tertiary hypothyroidism, TSH levels may be low. In addition, in Euthyroid sick syndrome, multiple alterations in serum thyroid function test findings have been recognized.

Vijay
Signature of Technician

Sinani
Signature of Doctor

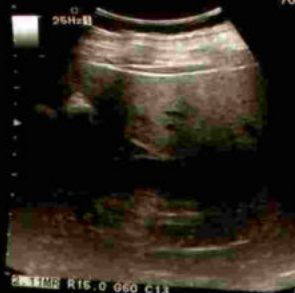ALOKA MEHARS SAHARA DIA
GNOSTICS ALWAR

:No 10

: Y

27-01-'23

12:56:56



70%

MI = 0.52 T15 < 0.4 70%

25Hz

R15.0 060 C13

Detailed description: This is a B-mode ultrasound image showing a fetal head in profile, similar to the one on the left. The skull and internal structures are visible. The image is labeled with 'MI = 0.52 T15 < 0.4 70%' at the top, '25Hz' in the top right corner, and 'R15.0 060 C13' at the bottom.