



DEPARTMENT OF PATHOLOGY

Patlent Name : Mrs. JYOTI YADAV
MR No : 657540
Age/Sex : 29 Years / Female
Type : OPD
TPA/Corporate : MEDIWHEEL PVT LTD

Bill Date : 02/08/2022
Reporting Date : 02/08/2022
Sample ID : 24915
Bill/Req. No. : 22936227
Ref Doctor : Dr.RMO

Test	Result	Bio. Ref. Interval	Units
BLOOD SUGAR 2 HR. PP			
BLOOD SUGAR P.P.	126	80 - 150	mg/dl

***** END OF THE REPORT *****



Sample no.

Dr.NALANDA BUKTARE
MD (Pathology)

Dr.PRADIP KUMAR
Consultant (Microbiology)

Dr.NISHA TIWARI
MBBS, MD (Microbiology)

USER NM NEERAJPA752

(This is only professional opinion and not the diagnosis, Please correlate clinically)

Q Block South City 11, Sohna Road, Main Sector-47, Gurgaon, Haryana
Ph.: 0124-4900000 (100 Lines) Fax : 0124-2218733 E-mail : parkmedicenters@gmail.com

PARK GROUP OF HOSPITALS : West Delhi • South Delhi • Gurgaon • Karnal • Panipat • Hodal • Ambala • Behror

the **health** care providers

the **health** care providers





DEPARTMENT OF PATHOLOGY

Patient Name : Mrs. JYOTI YADAV
MR No : 657540
Age/Sex : 29 Years / Female
Type : OPD
TPA/Corporate : MEDIWHEEL PVT LTD

Bill Date : 02/08/2022
Reporting Date : 02/08/2022
Sample ID : 24915
Bill/Req. No. : 22936227
Ref Doctor : Dr.RMO

Test	Result	Blo. Ref. Interval	Units
BLOOD SUGAR FASTING			
PLASMA GLUCOSE FASTING	92	60 - 100	mg/dl

***** END OF THE REPORT *****



Sample no.

Dr.NALANDA BUKTARE
MD (Pathology)

Dr.PRADIP KUMAR
Consultant (Microbiology)

Dr.BHAVANA CHAUHAN
MBBS, MD (Microbiology)
USER NM NEERAJPA752

(This is only professional opinion and not the diagnosis, Please correlate clinically)

Q Block South City 11, Sohna Road, Main Sector-47, Gurgaon, Haryana
Ph.: 0124-4900000 (100 Lines) Fax : 0124-2218733 E-mail : parkmedicenters@gmail.com

PARK GROUP OF HOSPITALS : West Delhi • South Delhi • Gurgaon • Karnal • Panipat • Hodal • Ambala • Behror

the **health** care providers

the **health** care providers





DEPARTMENT OF PATHOLOGY

Patient Name : Mrs. JYOTI YADAV
MR No : 657540
Age/Sex : 29 Years / Female
Type : OPD
TPA/Corporate : MEDIWHEEL PVT LTD

Bill Date : 02/08/2022
Reporting Date : 02/08/2022
Sample ID : 24915
Bill/Req. No. : 22936227
Ref Doctor : Dr.RMO

Test	Result	Bio. Ref. Interval	Units
BLOOD GROUPING AND RH FACTOR			
BLOOD GROUP	"O" RH POSITIVE		

***** END OF THE REPORT *****



Sample no.

Dr.NALANDA BUKTARE
MD (Pathology)

Dr.PRADIP KUMAR
Consultant (Microbiology)

Dr.NISHA TIWARI
MBBS, MD (Microbiology)

USER NM NEERAJPA752

(This is only professional opinion and not the diagnosis, Please correlate clinically)

Q Block South City 11, Sohna Road, Main Sector-47, Gurgaon, Haryana
Ph.: 0124-4900000 (100 Lines) Fax : 0124-2218733 E-mail : parkmedicenters@gmail.com

PARK GROUP OF HOSPITALS : West Delhi • South Delhi • Gurgaon • Karnal • Panipat • Hodal • Ambala • Behror

the **health** care providers

the **health** care providers





DEPARTMENT OF PATHOLOGY

Patient Name : Mrs. JYOTI YADAV
MR No : 657540
Age/Sex : 29 Years / Female
Type : OPD
TPA/Corporate : MEDIWHEEL PVT LTD

Bill Date : 02/08/2022
Reporting Date : 02/08/2022
Sample ID : 24915
Bill/Req. No. : 22936227
Ref Doctor : Dr.RMO

Test	Result	Bio. Ref. Interval	Units
CBC			
HAEMOGLOBIN	13.3	12 - 15	gms/dL
TOTAL LEUCOCYTE COUNT	9400	4000 - 10000	/ μ L
DIFFERENTIAL COUNT			
NEUTROPHILS	65	40.0 - 80.0	%
LYMPHOCYTES	30	20.0 - 40.0	%
MONOCYTES	03	2.0 - 10.0	%
EOSINOPHILS	02	0.0 - 5.0	%
BASOPHILS	00	0.0 - 2.0	%
RED BLOOD CELL COUNT	3.5	3.5 - 5.5	millions/ μ L
PACKED CELL VOLUME	33.0 L	35.0 - 50.0	%
MEAN CORPUSCULAR VOLUME	94.1	83 - 101	fL
MEAN CORPUSCULAR HAEMOGLOBIN	37.9 H	27 - 31	Picogrames
MEAN CORPUSCULAR HB CONC	40.3 H	33 - 37	g/dl
PLATELET COUNT	200	150 - 450	lakhs
RDW	12.3	11.6 - 13.7	%

***** END OF THE REPORT *****



Sample no.

Dr.NALANDA BUKTARE
MD (Pathology)

Dr.PRADIP KUMAR
Consultant (Microbiology)

Dr.BHAVANA CHAUHAN
MBBS, MD (Microbiology)

USER NM NEERAJPA752

(This is only professional opinion and not the diagnosis, Please correlate clinically)

Q Block South City 11, Sohna Road, Main Sector-47, Gurgaon, Haryana
Ph.: 0124-4900000 (100 Lines) Fax : 0124-2218733 E-mail : parkmedicenters@gmail.com

PARK GROUP OF HOSPITALS : West Delhi • South Delhi • Gurgaon • Karnal • Panipat • Hodal • Ambala • Behror

the **health** care providers

the **health** care providers





DEPARTMENT OF PATHOLOGY

Patient Name : Mrs. JYOTI YADAV
MR No : 657540
Age/Sex : 29 Years / Female
Type : OPD
TPA/Corporate : MEDIWHEEL PVT LTD

Bill Date : 02/08/2022
Reporting Date : 02/08/2022
Sample ID : 24915
Bill/Req. No. : 22936227
Ref Doctor : Dr.RMO

Test	Result	Bio. Ref. Interval	Units
ESR (WESTERGREN)			
E.S.R.	15	0 - 15	mm at the end of 1st hr

***** END OF THE REPORT *****



Sample no.

Dr.NALANDA BUKTARE
MD (Pathology)

Dr.PRADIP KUMAR
Consultant (Microbiology)

Dr.NISHA TIWARI
MBBS, MD (Microbiology)

USER NM NEERAJPA752

(This is only professional opinion and not the diagnosis, Please correlate clinically)

Q Block South City 11, Sohna Road, Main Sector-47, Gurgaon, Haryana
Ph.: 0124-4900000 (100 Lines) Fax : 0124-2218733 E-mail : parkmedicenters@gmail.com

PARK GROUP OF HOSPITALS : West Delhi • South Delhi • Gurgaon • Karnal • Panipat • Hodal • Ambala • Behror





DEPARTMENT OF PATHOLOGY

Patient Name : Mrs. JYOTI YADAV
MR No : 657540
Age/Sex : 29 Years / Female
Type : OPD
TPA/Corporate : MEDIWHEEL PVT LTD

Bill Date : 02/08/2022
Reporting Date : 02/08/2022
Sample ID : 24915
Bill/Req. No. : 22936227
Ref Doctor : Dr.RMO

Test	Result	Bio. Ref. Interval	Units
THYROID PROFILIE			
TRI-IODOTHYRONINE (T3)	1.27	0.60 - 1.81	ng/ml
THYROXINE (T4)	12.4	5.01 - 12.45	µg/dL
THYROID STIMULATING HORMONE (TSH)	0.68	0.5-5.50	µIU/ml

***** END OF THE REPORT *****



Sample no.

Dr.NALANDA BUKTARE
MD (Pathology)

Dr.PRADIP KUMAR
Consultant (Microbiology)

Dr.NISHA TIWARI
MBBS, MD (Microbiology)
USER NM DINESH

(This is only professional opinion and not the diagnosis, Please correlate clinically)

Q Block South City 11, Sohna Road, Main Sector-47, Gurgaon, Haryana
Ph.: 0124-4900000 (100 Lines) Fax : 0124-2218733 E-mail : parkmedicenters@gmail.com

PARK GROUP OF HOSPITALS : West Delhi • South Delhi • Gurgaon • Karnal • Panipat • Hodal • Ambala • Behror





DEPARTMENT OF PATHOLOGY

Patient Name : Mrs. JYOTI YADAV
 MR No : 657540
 Age/Sex : 29 Years / Female
 Type : OPD
 TPA/Corporate : MEDIWHEEL PVT LTD

Bill Date : 02/08/2022
 Reporting Date : 02/08/2022
 Sample ID : 24915
 Bill/Req. No. : 22936227
 Ref Doctor : Dr.RMO

Test	Result	Bio. Ref. Interval	Units
LFT (LIVER FUNCTION TEST)			
LFT			
TOTAL BILIRUBIN	0.6	0.1 - 1.2	mg/dL
DIRECT BILIRUBIN	0.4	0 - 0.4	mg/dL
INDIRECT BILIRUBIN	0.2	0.10 - 0.6	mg/dL
SGOT (AST)	12	0 - 45	U/L
SGPT (ALT)	13	0 - 45	U/L
ALKALINE PHOSPHATASE	117	30 - 170	IU/L
TOTAL PROTEINS	7.2	6.4 - 8.0	g/dL
ALBUMIN	3.8	3.3 - 5.5	g/dL
GLOBULIN	3.4	2.3 - 4.5	g/dL
A/G RATIO	1.1	1.1 - 2.2	

***** END OF THE REPORT *****



Sample no.

Dr.NALANDA BUKTARE
 MD (Pathology)

Dr.PRADIP KUMAR
 Consultant (Microbiology)

Dr.BHAVANA CHAUHAN
 MBBS, MD (Microbiology)

USER NM NEERAJPA752

(This is only professional opinion and not the diagnosis, Please correlate clinically)

Q Block South City 11, Sohna Road, Main Sector-47, Gurgaon, Haryana
 Ph.: 0124-4900000 (100 Lines) Fax : 0124-2218733 E-mail : parkmedicenters@gmail.com

PARK GROUP OF HOSPITALS : West Delhi • South Delhi • Gurgaon • Karnal • Panipat • Hodal • Ambala • Behror

the **health** care providers

the **health** care providers





DEPARTMENT OF PATHOLOGY

Patient Name : Mrs. JYOTI YADAV
MR No : 657540
Age/Sex : 29 Years / Female
Type : OPD
TPA/Corporate : MEDIWHEEL PVT LTD

Bill Date : 02/08/2022
Reporting Date : 02/08/2022
Sample ID : 24915
Bill/Req. No. : 22936227
Ref Doctor : Dr.RMO

Test	Result	Bio. Ref. Interval	Units
KFT (RENAL PROFILE)			
KFT			
SERUM UREA	16	10 - 45	mg/dL
SERUM CREATININE	0.7	0.4 - 1.4	mg/dL
SERUM URIC ACID	3.8	2.5 - 7.0	mg/dL
SERUM SODIUM	136	136 - 145	meq/l
SERUM POTASSIUM	4.7	3.5 - 5.5	meq/l
SERUM CALCIUM	9.7	8.5 - 10.5	mg/dL
SERUM PHOSPHORUS	2.8	2.5 - 4.5	mg/dL

***** END OF THE REPORT *****



Dr.NALANDA BUKTARE
MD (Pathology)

Dr.PRADIP KUMAR
Consultant (Microbiology)

Dr.BHAVANA CHAUHAN
MBBS, MD (Microbiology)

USER NM NEERAJPA752

(This is only professional opinion and not the diagnosis, Please correlate clinically)

Q Block South City 11, Sohna Road, Main Sector-47, Gurgaon, Haryana
Ph.: 0124-4900000 (100 Lines) Fax : 0124-2218733 E-mail : parkmedicenters@gmail.com

PARK GROUP OF HOSPITALS : West Delhi • South Delhi • Gurgaon • Karnal • Panipat • Hodal • Ambala • Behror





DEPARTMENT OF PATHOLOGY

Patient Name : Mrs. JYOTI YADAV
MR No : 657540
Age/Sex : 29 Years / Female
Type : OPD
TPA/Corporate : MEDIWHEEL PVT LTD

Bill Date : 02/08/2022
Reporting Date : 02/08/2022
Sample ID : 24915
Bill/Req. No. : 22936227
Ref Doctor : Dr.RMO

Test	Result	Bio. Ref. Interval	Units
LIPID PROFILE			
LIPID PROFILE		0 - 200	mg/dL
TOTAL CHOLESTEROL	166	60 - 165	mg/dl
SERUM TRIGLYCERIDES	164	30 - 70	mg/dl
HDL-CHOLESTEROL	42	6 - 32	mg/dL
VLDL CHOLESTEROL	32	50 - 135	mg/dL
LDL	92	1.0 - 3.0	mg/dl
LDL CHOLESTEROL/HDL RATIO	2.1	2.0 - 5.0	
TOTAL CHOLESTEROL/HDL RATIO	3.9		

***** END OF THE REPORT *****



Sample no.

Dr.NALANDA BUKTARE
MD (Pathology)

Dr.PRADIP KUMAR
Consultant (Microbiology)

Dr.BHAVANA CHAUHAN
MBBS, MD (Microbiology)
USER NM NEERAJPA752

(This is only professional opinion and not the diagnosis, Please correlate clinically)

Q Block South City 11, Sohna Road, Main Sector-47, Gurgaon, Haryana
Ph.: 0124-4900000 (100 Lines) Fax : 0124-2218733 E-mail : parkmedicenters@gmail.com

PARK GROUP OF HOSPITALS : West Delhi • South Delhi • Gurgaon • Karnal • Panipat • Hodal • Ambala • Behror

the **health** care providers the **health** care providers





DEPARTMENT OF RADIOLOGY

Patient Name	Mrs. JYOTI YADAV	Billed Date	02/08/2022	11 31 AM
Reg No	657540	Reported Date	02/08/2022	
Age/Sex	29 Years / Female	Req. No.	22936227	
Type	OPD	Consultant Doctor	Dr. RMO	

X-RAY CHEST AP/PA

X-RAY CHEST P.A. VIEW

Bilateral lungs appears normal.

No focal lung lesion seen.

No evidence of free fluid is seen.

Both hila are normal in size, have equal density and bear normal relationship.

The heart and trachea are central in position and no mediastinal abnormality is visible.

The cardiac size is normal for patient age and view.

The domes of the diaphragms are normal in position, and show smooth outline.

To be correlated clinically



Dr. Anshu K. Sharma
Dr. ANSHU K. SHARMA
MBBS, MD
CONSULTANT RADIOLOGIST

Dr. SAKET RUPRAMKA
MBBS, MD
CONSULTANT RADIOLOGIST

Dr. MANJEET SEHRAWAT
MBBS, MD, PDCC
CONSULTANT RADIOLOGIST

Dr. NEENA SIKKA
MBBS, DNB
CONSULTANT RADIOLOGIST

(This is only professional opinion and not the diagnosis, Please correlate clinically.)

Gurgaon : Q Block, South City-II, Sohna Road, Sector-47, Gurugram-122002, (Haryana)
Faridabad : J-Block, Sector - 10, Near Court, Faridabad - 121004, (Haryana)

• Helpline : 0124-4900000
• Helpline : 0129-4200000

the health care providers that





DEPARTMENT OF RADIOLOGY

Patient Name	Mrs. JYOTI YADAV	Billed Date	: 02/08/2022	11.31 AM
Reg No	657540	Reported Date	: 02/08/2022	
Age/Sex	29 Years / Female	Req. No.	: 22938227	
Type	OPD	Consultant Doctor	: Dr. RMO	

USG WHOLE ABDOMEN

The real time, B mode, gray scale sonography of the abdominal organs was performed.

LIVER : The liver is normal in size, 13.6cm shape and echotexture. No evidence of any focal lesion. IHBR is not dilated.

GALL BLADDER : The gall bladder is well distended . No evidence any calculus or mass seen.
GB wall thickness with in normal limits.No evidence of pericholecystic fluid is seen.

BILE DUCT :The common bile duct is normal in caliber. No evidence of calculus is noted in common bile duct.

SPLEEN :The spleen is normal in size 7.6cm and shape.Its echotexture is homogeneous.No evidence of focal lesion is noted.

PANCREAS :The pancreas is normal in size, shape, contours and echotexture.No evidence of solid or cystic mass lesion is noted.MPD is not dilated. No evidence of peripancreatic collection.

KIDNEYS : The bilateral kidneys are normal in size and echotexture. Cortico-medullary differentiation is maintained.There is no evidence of obvious calculus or hydronephrosis.

URINARY BLADDER :The urinary bladder is well distended.It shows uniformly thin walls and sharp mucosa.No evidence of calculus is seen. No evidence of mass or diverticulum is noted.

UTERUS: The uterus is retroflexed. It measures 7.1x6.4x3.2 cms. in the longitudinal, anteroposterior and transverse dimensions respectivelyThe uterine margins is smooth and does not reveal any contour abnormalities.
The uterine myometrium shows homogeneous echotexture.
No evidence of leiomyoma is noted. No solid or cystic mass lesion is noted.
The endometrial echo is in the midline and measures 7mm.
Left ovary is normal in size shape and echotexture.
A cystic lesion of size 22x16mm is seen abutting the right ovary....Likely exophytic cyst.
Minimal free fluid is seen in POD.
No evidence of obvious retroperitoneal or mesantric lymphadenopathy is seen.

IMPRESSION- Right ovarian exophytic cyst
Minimal free fluid is seen in POD

To be correlated clinically
Dr. ANSHU K. SHARMA
MBBS, MD
CONSULTANT RADIOLOGIST

Dr. SAKET RUPRAMKA
MBBS, MD
CONSULTANT RADIOLOGIST

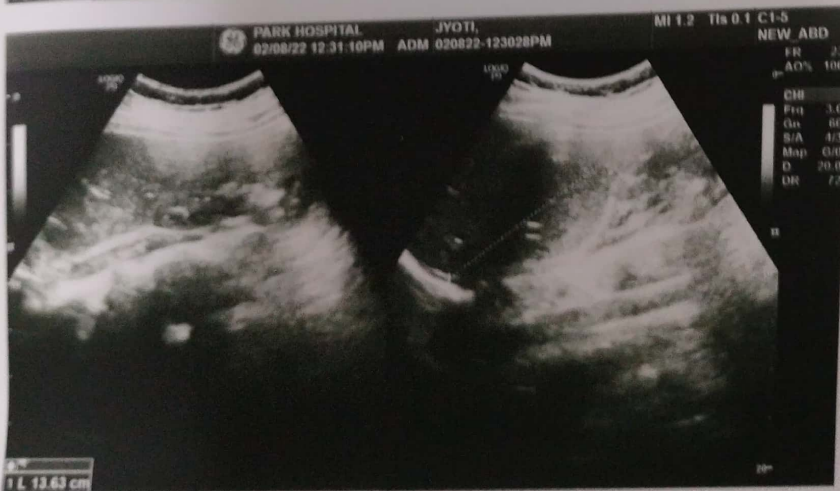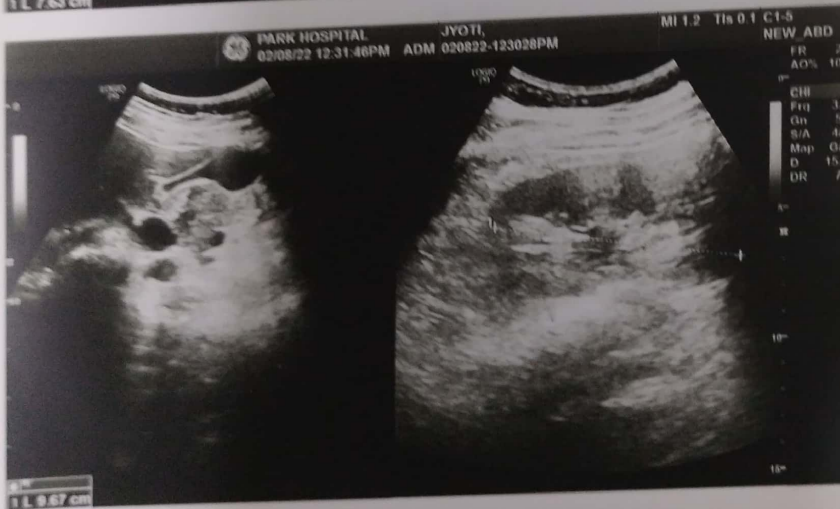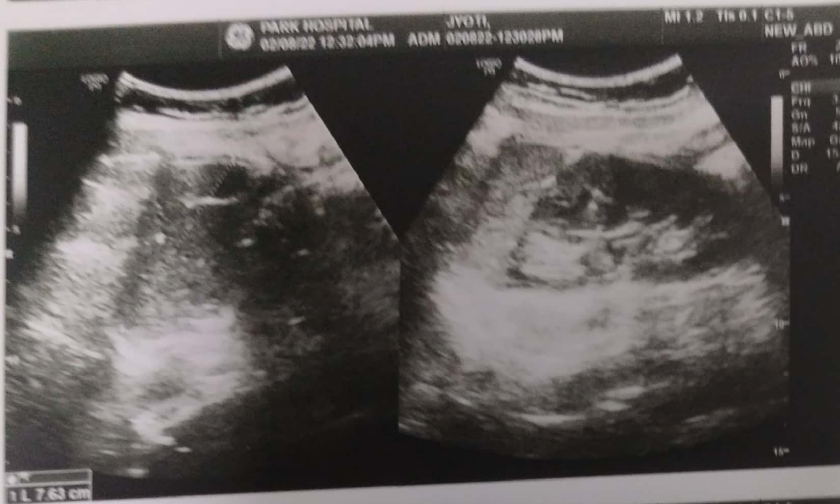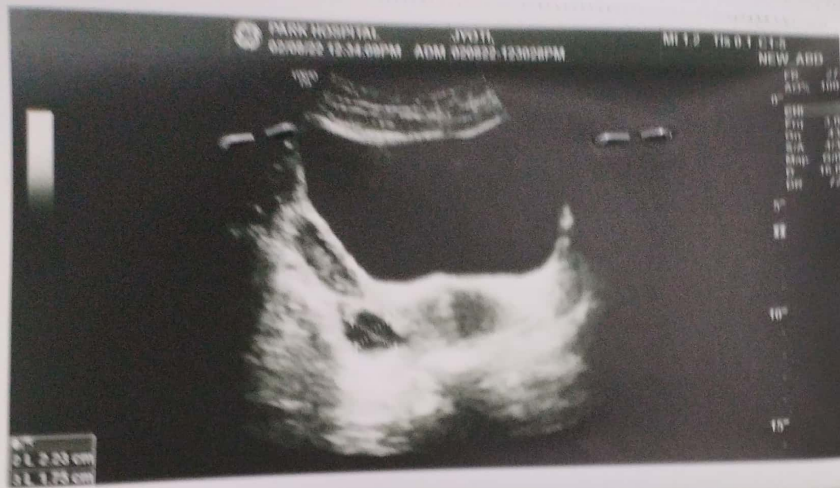Dr. MANJEET SEHRAWAT
MBBS, MD, PDCC
CONSULTANT RADIOLOGIST

Dr. NEENA SIKKA
MBBS, DNB
CONSULTANT RADIOLOGIST



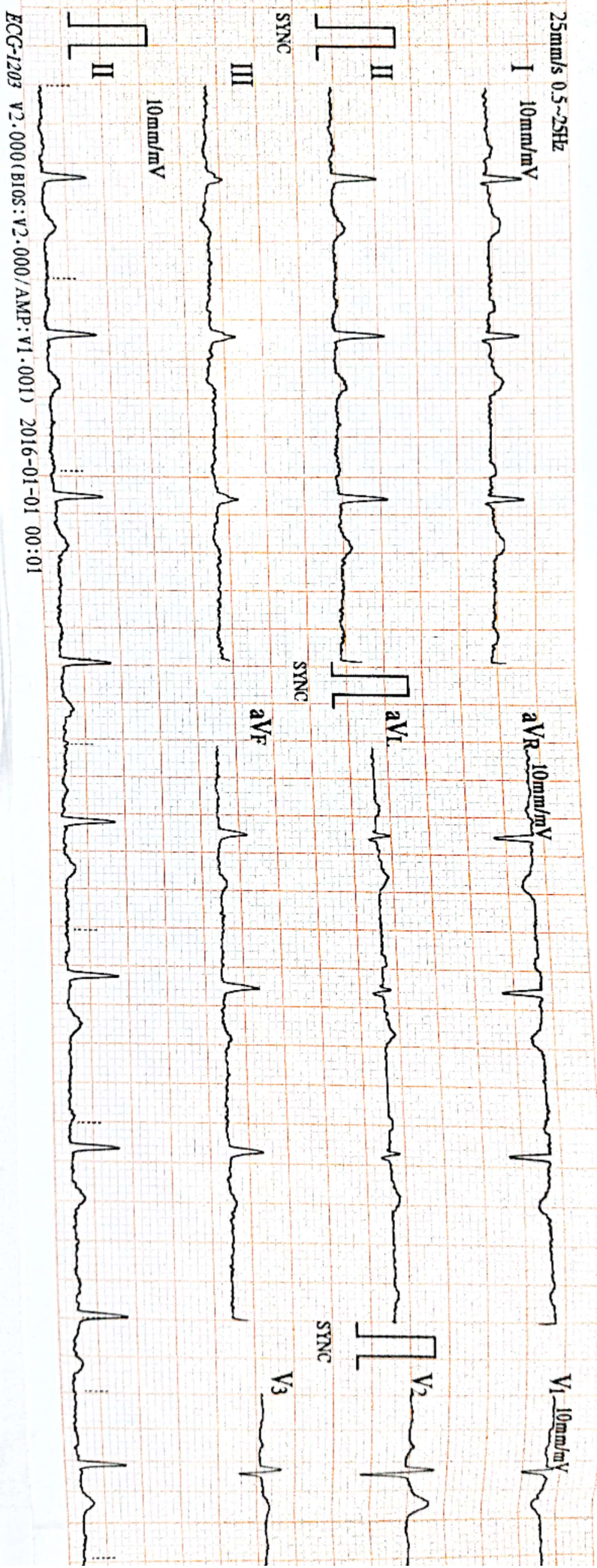
(This is only professional opinion and not the diagnosis, Please correlate clinically.)



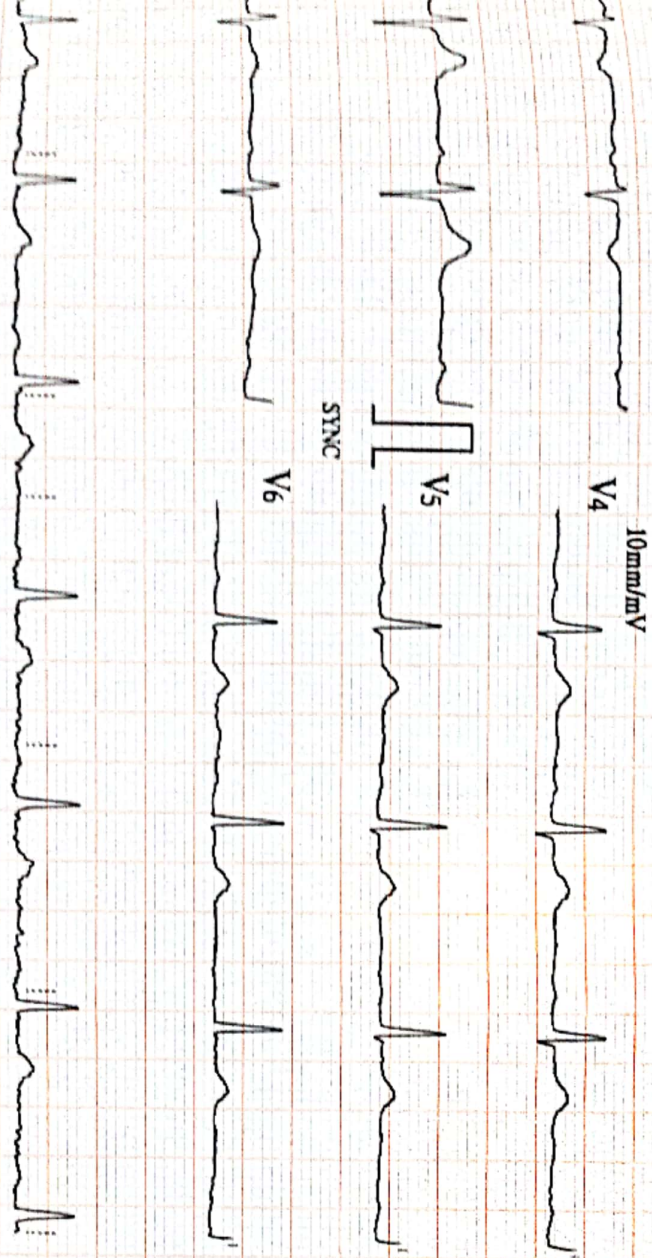


R

JYOTI YADAV 29Y REQ-22936227 220802120090538 F
PARK HOSPITAL SOUTH CITY II GURGAON HARYANA



ECG-1203 V2.000 (BIOS: V2.000 / AMP: V1.001) 2016-01-01 00:01



ID : 0008

HR : 70

bpm

R-R : 849

ms

P-R-T : 175

ms

QRS : 82

ms

QT/QTc : 362/392

ms

P/QRS/T : 13/63/40

°

PV5/SV1 : 0.690/0.330

mV

PV5+SV1 : 1.020

mV

Sex : female

Age : 29 (Y)

21/8/22

Sinus Rhythm
Borderline Normal ECG

12.10 PM

Unconfirmed report Verified by:



PRE EMPLOYMENT HEALTH CHECK UP REPORT

DATE-

PATIENT NAME- *Jyoti Yadav* AGE- *29* GENDER *F*

WEIGHT (kg) *66 kg*

PHYSICAL EXAMINATION

Pulse

BP *100/60 mmHg*

Blood Sugar(Random)

FINDINGS

Investigations: Investigation reports are attached

FITNESS CERTIFICATE

Candidate is fit, follow up USG w/A Report.

SIGNATURE

[Handwritten Signature]



(This is only professional opinion and not the diagnosis, Please correlate clinically)

Q Block South City 11, Sohna Road, Main Sector-47, Gurgaon, Haryana
Ph.: 0124-4900000 (100 Lines) Fax : 0124-2218733 E-mail : parkmedicenters@gmail.com

PARK GROUP OF HOSPITALS : West Delhi • South Delhi • Gurgaon • Karnal • Panipat • Hodal • Ambala • Behror

the **health** care providers the **health** care providers

