



Dr. Vandana G. Powar **M.B.B.S., D.C.P.**
Consultant Pathologist



PARTH
PATHOLOGY LABORATORY
(Computerised)

LAB - Shop No. 7, "Diwan Towers" Mangalwar Peth, Near Mirajkar Tikli, Opp. Nutan Marathi High School, Kolhapur. Mob. 9158529408, 9422047480, 9921285167

DATE – 31/03/2023

PATIENT NAME- Devendra Pujari

AGE – 36Y/MALE

HEIGHT – 177 cm

WEIGHT – 85 kg

BLOOD PRESSURE – 113 /72 mmHg

PULES – 83/ Min

FIT TO PERFORM ALL DUTIES

Dr. Vandana G. Powar

M.B.B.S., D.C.P.

Reg. No. 10183

PATHOLOGIST

Vandana Powar

DR. VANDANA POWAR
M.B.B.S., D.C.P.

All Biochemistry Tests Done By Computerised Auto Analyser

HAEMATOLOGY | CLINICAL PATHOLOGY | BIOCHEMISTRY | SEROLOGY | MICROBIOLOGY | HISTOPATHOLOGY

24 Hours Emergency Service

Home Service Available



भारत सरकार
GOVERNMENT OF INDIA



देवेन्द्र कल्लाप्पा पुजारी
Devendra Kallappa Pujari
जन्म तारीख/DOB: 01/06/1986
पुरुष / MALE
9853 7097 7565



आधार-सामान्य माणसाचा अधिकार

Diya



Dr. Vandana G. Powar
M.B.B.S., D.C.P
Reg. No. 68137

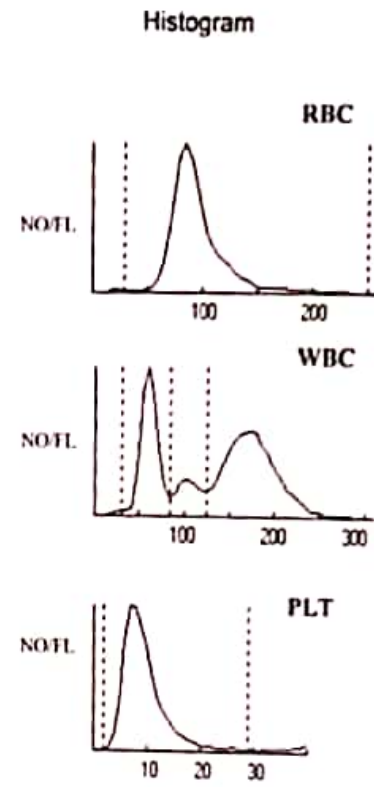


NAME : MR. DEVENDRA PUJARI
REF BY : Dr. MEDIWHEEL LIFE INS

DATE : 04/04/2023 PT.NO. : 203 04042
AGE : 36. Yrs. SEX : M

HAEMOGRAM WITH INDICES

Test	Result	Units	Normal Range
Haemoglobin	13.3	g/dl	14-18
RBC Count	4.44	millions / cu-mm	4.5 - 6.5
PCV	40.1	%	40 - 54
MCV	90.3	fL	80 - 96
MCH	30	Pg	27 - 33
MCHC	33.2	gm/dl	33 - 36
RDW CV	13.4	%	11.0 - 14.5
WBC Count	10300	/cumm	4000 - 11000
Neutrophils	63	%	40 - 75
Lymphocytes	32	%	20 - 40
Eosinophils	03	%	1 - 6
Monocytes	02	%	2-10
Basophils	00	%	0 - 1
Platelet Count	373000	/ul	150000 - 450000
MPV	8.7	fL	7.4 - 10.4
PDW	10.2	%	8-12
P-LCR	15.8	%	15-35
E.S.R. (By Wintrobe Method)	09	mm at 1hr	0-10
RBC Morphology	Normochromic, Normocytic.		
WBC Morphology	Within Normal Limits		
Platelets	Adequate		
* Blood group	- 'A' Rh Positive		



Dr. Vandana G. Powar
M.B.B.S., D.C.P.
Reg No. 62137



All Biochemistry Tests Done By Computerised Auto Analyser

HAEMATOLOGY | CLINICAL PATHOLOGY | BIOCHEMISTRY | SEROLOGY | MICROBIOLOGY | HISTOPATHOLOGY

24 Hours Emergency Service

Home Service Available



PT.NAME : MR. DEVENDRA PUJARI
REF. BY : DR. MEDIWHEEL LIFE INS

DATE : 04/04/2023
AGE : 36 Yrs. SEX : M
PT.NO. : 203 040423

BIOCHEMISTRY TEST REPORT

			<u>Normal Range</u>
Fasting Plasma Glucose	: 75.2	mg/dl	60-110 mg/dl
2 Hrs. Plasma Glucose	: 90.1	mg/dl	90-140 mg/dl
S. Creatinine	: 0.9	mg/dl	0.7 - 1.4 mg/dl
Blood Urea	: 22.7	mg/dl	12-42 mg/dl
Blood Urea Nitrogen	: 10.61	mg/dl	5 - 21 mg/dl
S. Uric acid	: 4.6	mg/dl	3.5 -7.2 mg/dl
CHOLESTEROL	: 158.9	mg/dl	0-250 mg/dl
HDL Cholesterol	: 33.6	mg/dl	30 - 70 mg/dl
S. Triglycerides	: 80.3	mg/dl	0-170 mg/dl
LDL Cholesterol	: 109.2	mg/dl	60 - 150 mg/dl
TC/HDLC Ratio	: 4.7		0 - 5
LDLC/HDLC Ratio	: 3.3		2.5 - 3.5

Dr. Vandana G. Powar
M.B.B.S., D.C.P.

Reg. No. 68137
* PAE
PATHOLOGIST

DR. VANDANA POWAR
M.B.B.S., D.C.P.

All Biochemistry Tests Done By Computerised Auto Analyser

HAEMATOLOGY | CLINICAL PATHOLOGY | BIOCHEMISTRY | SEROLOGY | MICROBIOLOGY | HISTOPATHOLOGY

24 Hours Emergency Service

Home Service Available

Dr. Vandana G. Powar M.B.B.S., D.C.P.
Consultant Pathologist



PARTH
PATHOLOGY LABORATORY
(Computerised)

LAB - Shop No. 7, "Diwan Towers" Mangalwar Peth, Near Mirajkar Tikti, Opp. Nutan Marathi High School, Kolhapur. Mob. 9158529408, 9422047480, 9921285167

PT.NAME : MR. DEVENDRA PUJARI
REF. BY : DR. MEDIWHEEL LIFE INS

DATE : 04/04/2023
AGE : 36 Yrs. SEX : M
PT.NO. : 203 040423

BIOCHEMISTRY TEST REPORT

			<u>Normal Range</u>
S. Bilirubin (Total)	: 0.28	mg/dl	0 - 1.0 mg/dl
S. Bilirubin (Direct)	: 0.17	mg/dl	0 - 0.25 mg/dl
S. Bilirubin (Indirect)	: 0.11	mg/dl	0 - 0.75 mg/dl
S.G.O.T	: 22.9	IU/L	5-40 IU/L
S.G.P.T	: 15.8	IU/L	5-40 IU/L
S. Alkaline Phosphatase	: 88.6	IU/L	37 - 147 IU/L
Total Proteins	: 7.9	g/dl	6.6 - 8.3 g/dl
S. Albumin	: 4.9	g/dl	3.5 - 5.0 g/dl
S. Globulin	: 3	g/dl	1.5 - 3 g/dl
A/G Ratio	: 1.6 : 1		0.90 - 2.00

Dr. Vandana G. Powar
M.B.B.S., D.C.P.



All Biochemistry Tests Done By Computerised Auto Analyser

HAEMATOLOGY | CLINICAL PATHOLOGY | BIOCHEMISTRY | SEROLOGY | MICROBIOLOGY | HISTOPATHOLOGY

24 Hours Emergency Service

Home Service Available

Dr. Vandana G. Powar M.B.B.S., D.C.P.
Consultant Pathologist



PARTH
PATHOLOGY LABORATORY
(Computerised)

LAB - Shop No. 7, "Diwan Towers" Mangalwar Peth, Near Mirajkar Tikli, Opp. Nutan Marathi
High School, Kolhapur. Mob. 9158529408, 9422047480, 9921285167

PT.NAME : MR. DEVENDRA PUJARI
REF. BY : DR. MEDIWHEEL LIFE INS

DATE : 04/04/2023
AGE : 36 Yrs. SEX : M
PT.NO. : 203 040423

REPORT ON % GLYCOHAEMOGLOBIN OF BLOOD

% Glycohaemoglobin of blood : 4.5 %

Estimated mean blood glucose : 82.5 mg/dl

(Reference For Guideline)

- < 6.0 - Normal
- 6.0 - 7.0 % - Good Control
- 7.0 - 8.0 % - Fair Control
- 8.0-10.0% - Unsatisfactory control
- >10.0% - Poor control

Dr. Vandana G. Powar
M.B.B.S., D.C.P.
Reg. No. 68137



All Biochemistry Tests Done By Computerised Auto Analyser

HAEMATOLOGY | CLINICAL PATHOLOGY | BIOCHEMISTRY | SEROLOGY | MICROBIOLOGY | HISTOPATHOLOGY

24 Hours Emergency Service

Home Service Available

Dr. Vandana G. Powar M.B.B.S., D.C.P.
Consultant Pathologist



PARTH
PATHOLOGY LABORATORY
(Computerised)

LAB - Shop No. 7, "Diwan Towers" Mangalwar Peth, Near Mirajkar Tikti, Opp. Nutan Marathi High School, Kolhapur. Mob. 9158529408, 9422047480, 9921285167

PT.NAME : MR. DEVENDRA PUJARI
REF. BY : DR. MEDIWHEEL LIFE INS

DATE : 04/04/2023
AGE : 36 Yrs. SEX : M
PT.NO. : 203 040423

EXAMINATION OF URINE

Normal Range

PHYSICAL EXAMINATION

Quantity	: 05 ml	
Colour	: Pale Yellow	
Appearance	: Clear	
Deposit	: Absent	
Reaction (pH)	: Acidic	
Specific Gravity	: 1.024	1.003 - 1.035

CHEMICAL EXAMINATION

Proteins	: Absent	
Glucose	: Absent	
Ketone Bodies	: --	
Bile Salts	: Absent	Absent
Bile Pigments	: Absent	Absent
Urobilinogen	: --	
Occult Blood	: Absent	

MICROSCOPIC EXAMINATION

Epithelial Cells	: 1 - 2	/hpf
Pus Cells	: 2 - 3	/hpf
Red Blood Cells	: Absent	/hpf
Casts	: Absent	
Crystals	: Absent	
Amorphous Deposits	: Absent	

OTHER FINDINGS

Yeast Cells	: Absent
Trichomonas vaginalis	: Absent
Bacteria	: Absent
Mucus Threads	: Absent
Spermatozoa	: Absent

Dr. Vandana G. Powar
M.B.B.S., D.C.P.
Reg. No. 68137
PATHOLOGIST
LABORATORY
DR. VANDANA POWAR
M.B.B.S., D.C.P.

All Biochemistry Tests Done By Computerised Auto Analyser

HAEMATOLOGY | CLINICAL PATHOLOGY | BIOCHEMISTRY | SEROLOGY | MICROBIOLOGY | HISTOPATHOLOGY

24 Hours Emergency Service

Home Service Available

Dr. Vandana G. Powar M.B.B.S., D.C.P.
Consultant Pathologist



PARTH
PATHOLOGY LABORATORY
(Computerised)

LAB - Shop No. 7, "Diwan Towers" Mangalwar Peth, Near Mirajkar Tikti, Opp. Nutan Marathi High School, Kolhapur. Mob. 9158529408, 9422047480, 9921285167

PATIENT NAME:- DEVENDRA PUJARI

AGE - 41 SEX/MALE

REFERANCE= MEDIWHEEL LIFE INS.

DATE - 04/04/2023

BIOCHEMISTRY

NORMAL VALUE

S. GAMMA.G.T : 30.2 mmol/L

10-50 mmol / L

Dr. Vandana G. Powar
M.B.B.S., D.C.P.
Reg. No. 68137

PATHOLOGIST

DR. VANDANA POWAR
M.B.B.S., D.C.P.

All Biochemistry Tests Done By Computerised Auto Analyser

HAEMATOLOGY | CLINICAL PATHOLOGY | BIOCHEMISTRY | SEROLOGY | MICROBIOLOGY | HISTOPATHOLOGY

24 Hours Emergency Service

Home Service Available

Dr. Vandana G. Powar M.B.B.S., D.C.P.
Consultant Pathologist



PARTH
PATHOLOGY LABORATORY
(Computerised)

LAB - Shop No. 7, "Diwan Towers" Mangalwar Peth, Near Mirajkar Tikti, Opp. Nutan Marathi
High School, Kolhapur. Mob. 9158529408, 9422047480, 9921285167

PATIENT NAME:- DEVENDRA PUJARI

AGE -36SEX-MALE

REFERANCE= MEDIWHEEL LIFE INS .

DATE - 04/04/2023

BIOCHEMISTRY

SERUM VLDL : 23.7

NORMAL VALUE

10-50 mmol / L

Dr. Vandana G. Powar
M.B.B.S., D.C.P.
Reg. No. 68137

PATHOLOGIST

DR. VANDANA POWAR
M.B.B.S., D.C.P.

All Biochemistry Tests Done By Computerised Auto Analyser

HAEMATOLOGY | CLINICAL PATHOLOGY | BIOCHEMISTRY | SEROLOGY | MICROBIOLOGY | HISTOPATHOLOGY

24 Hours Emergency Service

Home Service Available

Dr. Vandana G. Powar M.B.B.S., D.C.P.
Consultant Pathologist



PARTH
PATHOLOGY LABORATORY
(Computerised)

Lab - Shop No. 7, "Diwan Towers" Mangalwar Peth, Near Mirajkar Tikti, Opp. Nutan Marathi High School, Kolhapur. Mob. 9158529408, 9422047480, 9921285167

04/04/2023

**THE ECG OF CLIENT - DEVENDRA PUJARI
IS WITHIN NORMAL LIMIT**

NO ABNORMAL FINDINGS ARE DETECTED

Dr. Vandana G. Powar
M.B.B.S., D.C.
Reg. No. 68137



All Biochemistry Tests Done By Computerised Auto Analyser

HAEMATOLOGY | CLINICAL PATHOLOGY | BIOCHEMISTRY | SEROLOGY | MICROBIOLOGY | HISTOPATHOLOGY

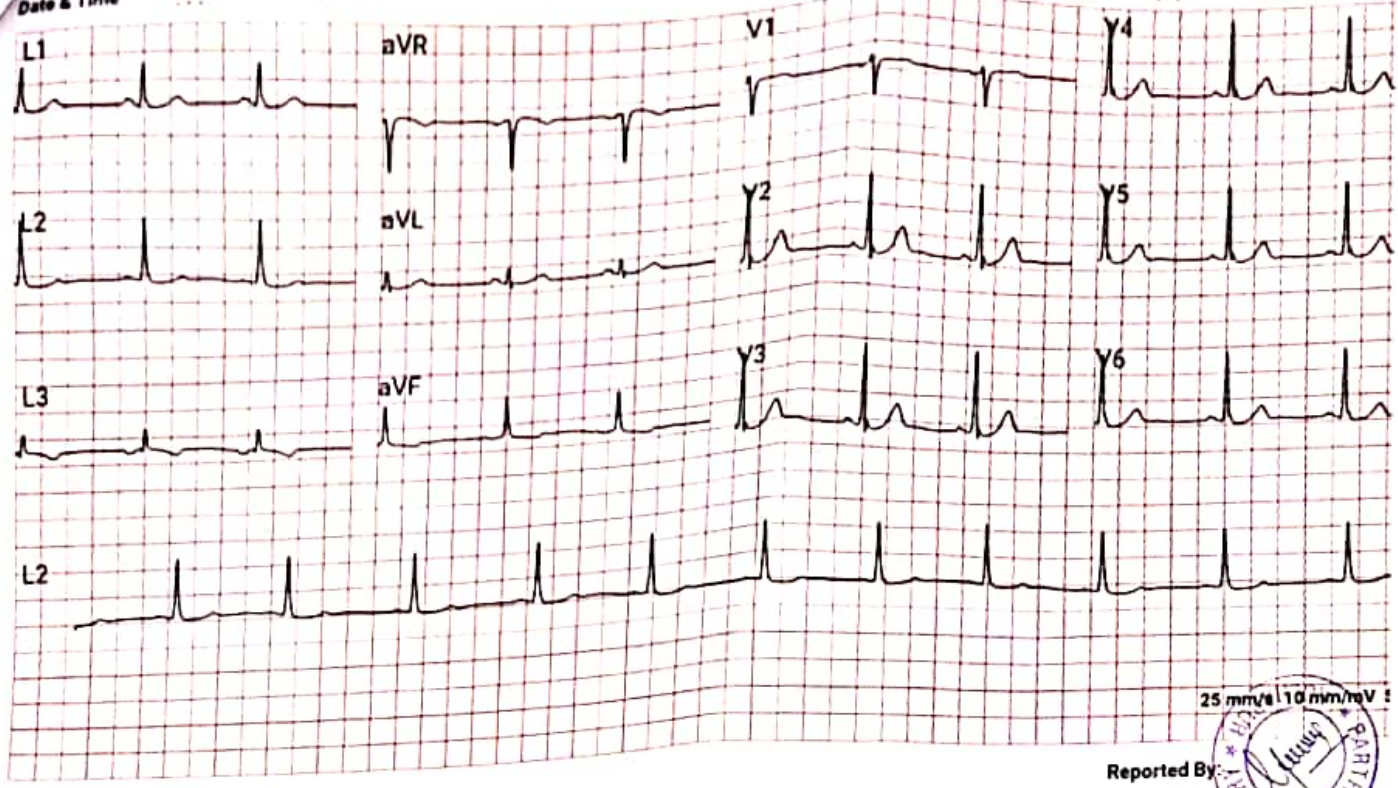
24 Hours Emergency Service

Home Service Available

12 lead simultaneous EC

Devendra Pujari
36 Male
04 APRIL 2023 09:10 AM

Heart Rate	68 bpm	QT	360.29 ms
QRS	151.71 ms	PR	142.0 ms
ST	80.67 ms	QTc	376.29 ms



Comments: Normal

25 mm/s 10 mm/mV

Reported By: *[Signature]*

Dr. Vandana G. Powar
M.B.S., D.C.R.
Reg. No. 64137



 GPS Map Camera

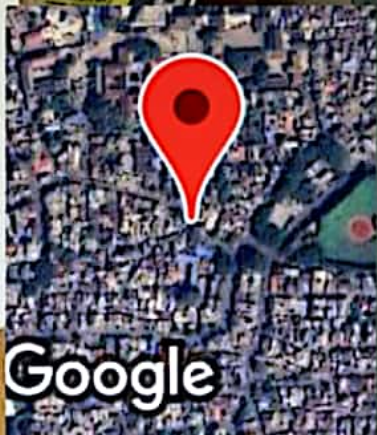Kolhapur, Maharashtra, India

Rajghat Rd, Mangalwar Peth, C Ward, Kolhapur,
Maharashtra 416002, India

Lat 16.692814°

Long 74.224317°

04/04/23 11:11 AM GMT +05:30



डॉ.बी.जी.जाधव-ढेकळे

एम. बी. बी. एस.
(जनरल फिजिशियन)

डॉ. नेहा घोरपडे

एम. बी. बी. एस., डी.एम.आर.ई
कन्सल्टिंग रेडीओलॉजिस्ट



अस्मिता क्लिनिक
आणि सोनोग्राफी सेंटर

१००४/३अ/२, फिंरंगाई देवळासमोर, शिवाजी पेठ, कोल्हापूर - ४१६०१२.

Ph. : (0231) 2621071 | E mail: asmitadiagno.neha@gmail.com

Patient Name : MR. DEVENDRA PUJARI

Date : 04 Apr 2023

Referred By : Dr. VANDANA POWAR

Age : 36 YEARS Sex : M

Clinically – For Health check up.

Abdomen Sonography

LIVER: is normal in size, shape, position and shows increased echogenicity. The contours are smooth. The parenchyma shows homogeneous echotexture. The intra – hepatic portal and venous system appears normal. The portal vein is normal and show hepatopetal flow. The intra-hepatic biliary radicals are not dilated. There is no focal mass lesion.

GALL BLADDER: is physiologically distended, normal in size and echotexture. There is no evidence of echoreflexive calculus in gall bladder. There is no abnormal biliary tree dilation noted. The portal vein & C.B.D appear normal. Wall thickness is normal. No e/o cholecystitis/calculus seen. PV measures -11 mm, CBD measures – 3 mm.

PANCREAS: is normal size, position & echotexture. The contours are smooth. There is no focal mass lesion seen. No pancreatitis or calcification.

SPLEEN: is normal in size, shape and echopattern. The contours are smooth. The splenic vein and portal vein are normal in calibre.

KIDNEYS: Both the kidneys are normal in size, shape and position and contours. There is no echoreflexive obstructing calculus seen on either sides nor hydronephrosis. Both visualized ureters appear to be normal. Parenchymal/cortical thickness is normal. Cortico -medullary differentiation is well maintained. Overlying bowel gases does not show further course of ureter. **Right kidney** measures- 105 X 49 mm, **Left kidney** measures – 108 X 52 mm.

Urinary bladder is physiologically distended, appears normal. No intraluminal abnormality.

PROSTATE: is normal size and uniform echotexture, measures 28 X 27 X 37 mm (weight- 15 gms). The gland bulges urinary bladder base.

Aorta and IVC are normal. No e/o free fluid in peritoneal cavity. No ascites. No significant lymphadenopathy. Bowel loops appear normal in size with good peristalsis.

Appendix is not appreciated in today's study. Terminal ileum is well seen.

No probe tenderness in right iliac fossa or anywhere in abdomen.

IMPRESSION : < FATTY LIVER- GRADE 1.

ADVICE - Clinical correlation and follow up if clinically needed.

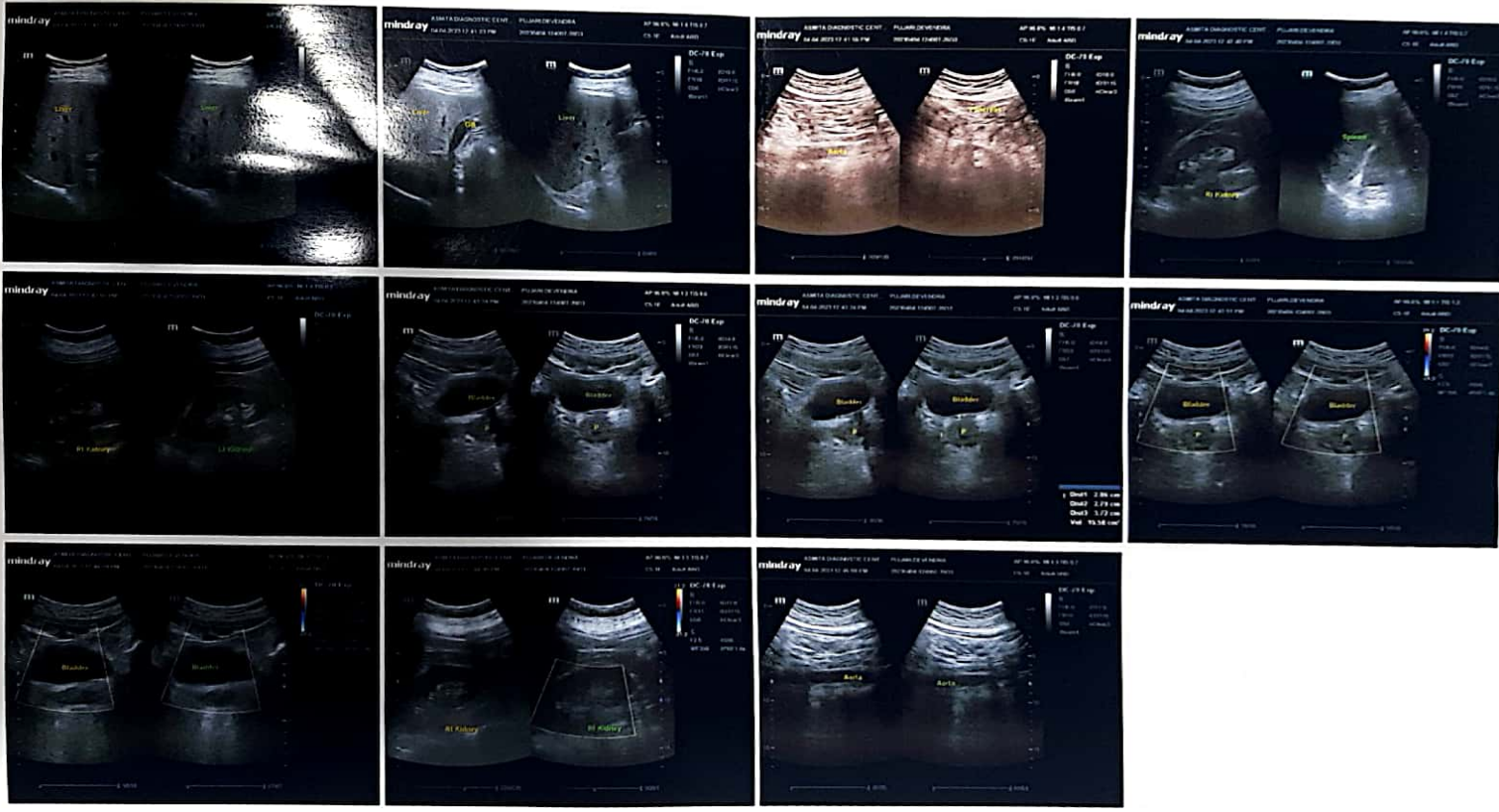
THANKS FOR REFERRAL. FEEDBACK IS WELCOME

DR. NEHA S. GHORPADE
MBBS DMRE Reg. No. 79916
Consulting Radiologist

डॉ. नेहा घोरपडे

एम. बी. बी. एस., डी.एम.आर.ई (रेडीओलॉजिस्ट)
रजि.नं.79916

परत येताना सर्व जुने रिपोर्ट्स, सोनोग्राफी रिपोर्ट्स अथवा एक्स-रे असल्यास बरोबर घेऊन येणे.





अस्मिता क्लिनिक
आणि सोनोग्राफी सेंटर

Name : MR. DEVENDRA PUJARI
Ref By : Dr. VANDANA POWAR

Age/Sex : 36 YEARS/M
Date : 04 Apr 2023

CHEST RADIOGRAPH

No radiological pulmonary parenchymal abnormality seen
The hilar structures are normal.
The heart size and outlines are normal.
The diaphragm contour and costophrenic angles are normal.
Bony rib cage and soft tissues of chest wall are normal.

IMPRESSION:

- Radiograph shows no significant abnormality.
- ADVICE - Clinical correlation and follow up if clinically needed.
- THANKS FOR REFERRAL.FEEDBACK IS WELCOME

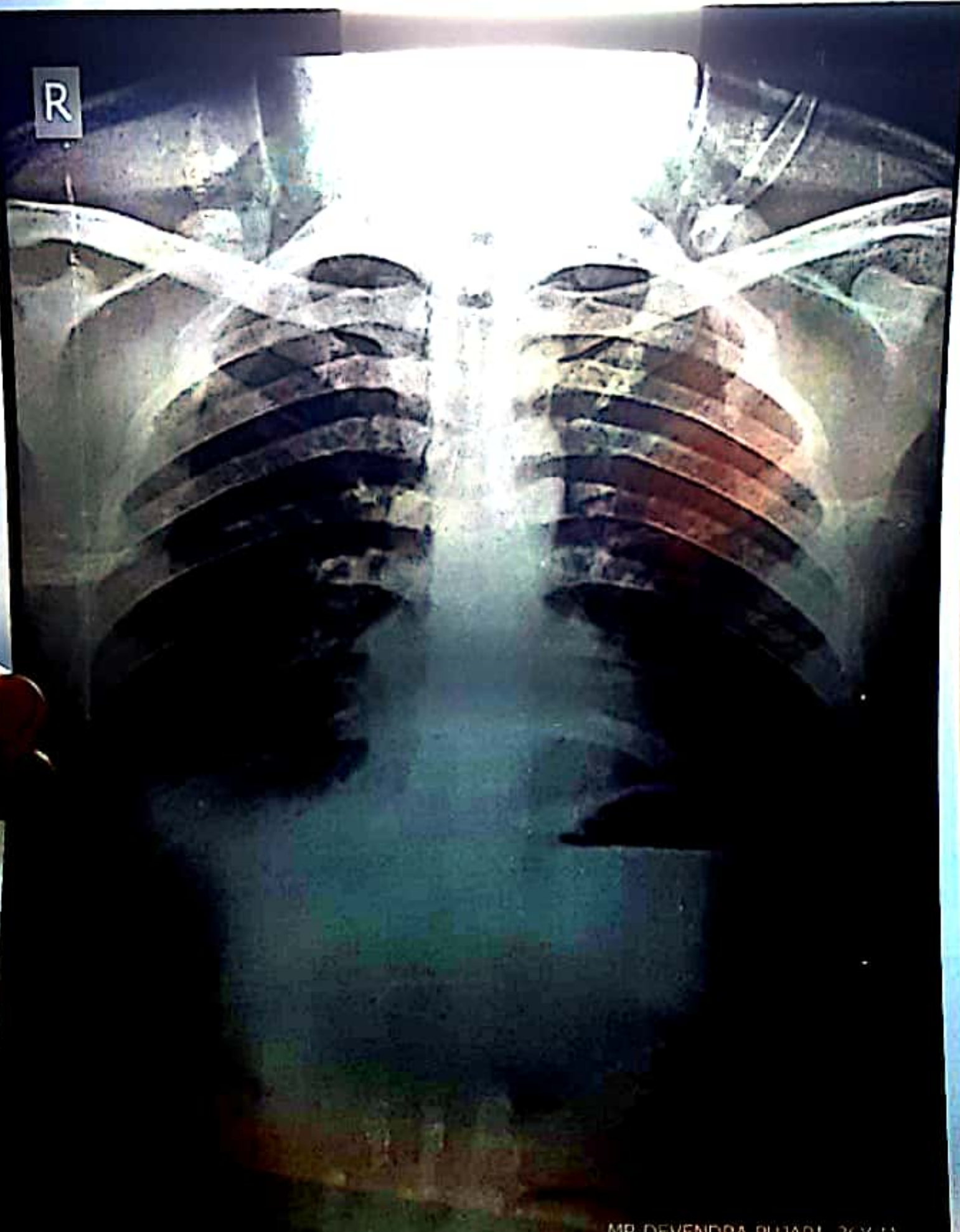
Neha

डॉ. नेहा घोरपडे

एम. बी. बी. एस., डी.एम.आर.ई (रेडिओलॉजिस्ट)
रजि.नं.79918

परत येताना सर्व जुने रिपोर्ट्स, सोनोग्राफी रिपोर्ट्स अथवा एक्स-रे असल्यास बरोबर घेऊन येणे.

R



DATE: 04/14/2025

MR DEVENDRA PUJARI 36Y/M
ASMITA CLINIC