


Name : Mrs. Saritha K S **Age:** 41 Y
Sex: F
Address : kml
Plan : ARCOFEMI MEDIWHEEL FEMALE AHC CREDIT PAN INDIA OP AGREEMENT

UHID: CKOR.0000248307

OP Number: CKOROPV389781
Bill No : CKOR-OCR-79251
Date : 30.11.2023 08:33

Sno	Service Type/ServiceName	Department
1	ARCOFEMI - MEDIWHEEL - FULL BODY ANNUAL PLUS CHECK ADVANCED - FEMALE - 2D ECHO - PAN INDIA - FY2324	
1	URINE GLUCOSE(FASTING)	
2	GAMMA GLUTAMYL TRANFERASE (GGT)	
3	SONO MAMOGRAPHY - SCREENING	
4	HbA1c GLYCATED HEMOGLOBIN	
5	2 D ECHO	
6	LIVER FUNCTION TEST (LFT)	
7	X-RAY CHEST PA	
8	GLUCOSE, FASTING	
9	HEMOGRAM + PERIPHERAL SMEAR	
10	ENT CONSULTATION <i>Dr. Nigama</i>	
11	FITNESS BY GENERAL PHYSICIAN	
12	GYNAECOLOGY CONSULTATION	
13	DIET CONSULTATION	
14	COMPLETE URINE EXAMINATION	
15	URINE GLUCOSE(POST PRANDIAL)	
16	PERIPHERAL SMEAR	
17	ECG	
18	BLOOD GROUP ABO AND RH FACTOR	
19	LIPID PROFILE	
20	BODY MASS INDEX (BMI)	
21	LBC PAP TEST- PAPSURE	
22	OPHTHAL BY GENERAL PHYSICIAN (50)	
23	RENAL PROFILE/RENAL FUNCTION TEST (RFT/KFT)	
24	ULTRASOUND - WHOLE ABDOMEN	
25	THYROID PROFILE (TOTAL T3, TOTAL T4, TSH)	
26	DENTAL CONSULTATION	
27	GLUCOSE, POST PRANDIAL (PP), 2 HOURS (POST MEAL)	

28. Physio
D3 - 199

Ht - 155 cm
 wt - 62.9 kg
 Bp - 123/69 mmHg
 pulse - 86 bts/min

NAME: MRS. SARITHA

AGE: 41Y

SEX: FEMALE

DATE: 30/11/2023

ECHOCARDIOGRAPHY REPORT

MEASUREMENT

AO -25(20 – 35)mm	LIVD d – 36(36-52)mm	IVS - 10 (06 - 11)mm
LA -28(19- 40)mm	LVID s - 25(23- 39)mm	PWD – 11(06- 11)mm
EF - 60% (>50%)	RVID-22	

VALVES

Mitral Valve : Normal
Aortic Valve : Normal
Tricuspid Valve : Normal
Pulmonary Valve : Normal

CHAMBERS

Left Atrium : Normal
Right Atrium : Normal
Left Ventricle : Normal
Right Ventricle : Normal

SEPTAE

IVS : Intact
IAS : Intact

GREAT ARTERIES

Aorta : Normal
Pulmonary Artery : Normal

DOPPLER DATA

Mitral : E > A
Aortic : Normal
Tricuspid : Normal
Pulmonary : Normal

WALL MOTION ABNORMALITIES : No RWMA

Pericardium : Normal

FINAL DIAGNOSIS

**NORMAL CHAMBERS AND VALVES
NORMAL BIVENTRICULAR FUNCTION
NO RWMA AT REST, LV EF -60%**



**DR. MOHAN MURALI
CONSULTANT
CARDIOLOGIST**

Patient Name : Mrs Saritha K S

Patient ID : 248307

Age : 41 Years

Sex : Female

Referring Doctor : H/C

Date : 30.11.23

SONOMAMMOGRAPHY

Both breast shows normal parenchymal echotexture. There is no evidence of distortion of parenchymal architecture.

There is no evidence of focal solid, cystic lesions or calcifications seen.

The nipple and areolar region show no abnormality.

The bilateral axillary region shows no abnormality and there is no evidence of enlarge lymph nodes.

IMPRESSION: NORMAL SONOMAMMOGRAPHY STUDY – BIRADS 1


DR VINOD JOSEPH DNB,DMRD
RADIOLOGIST

Patient Name	: Mrs. Saritha K S	Age	: 41 Y F
UHID	: CKOR.0000248307	OP Visit No	: CKOROPV389781
Reported on	: 30-11-2023 11:31	Printed on	: 30-11-2023 13:55
Adm/Consult Doctor	:	Ref Doctor	: SELF

DEPARTMENT OF RADIOLOGY

X-RAY CHEST PA

Both lungs fields appear normal.

Both hila are normal.

Both costophrenic and cardiophrenic angles are normal.

The cardiac and mediastinal shadows appear normal.

Bones and soft tissues appear normal.

IMPRESSION : NORMAL STUDY.

705

DR VINOD JOSEPH DNB,DMRD
RADIOLOGIST

Printed on:30-11-2023 11:31

---End of the Report---

Apollo Clinic

Consent Form

Patient Name: ① RAVIKUMAR Y.H. ⑤ SARITHA K.S. 41 y Age: 48

UHID Number: Company Name: Bank of Baroda

I Mr/Mrs/Miss: ① RAVIKUMAR Y.H. ② SARITHA K.S. Employee of Bank of Baroda

(Company) want to inform you that I am not getting the Consultation

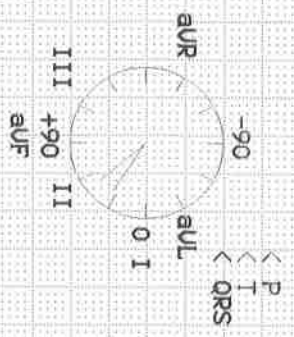
Test which is a part of health check package.

Reason If any: Coming on 09.12.2023

And I claim the above statement in my full consciousness.

Patient Signature: [Signature] Date: 30.11.2023

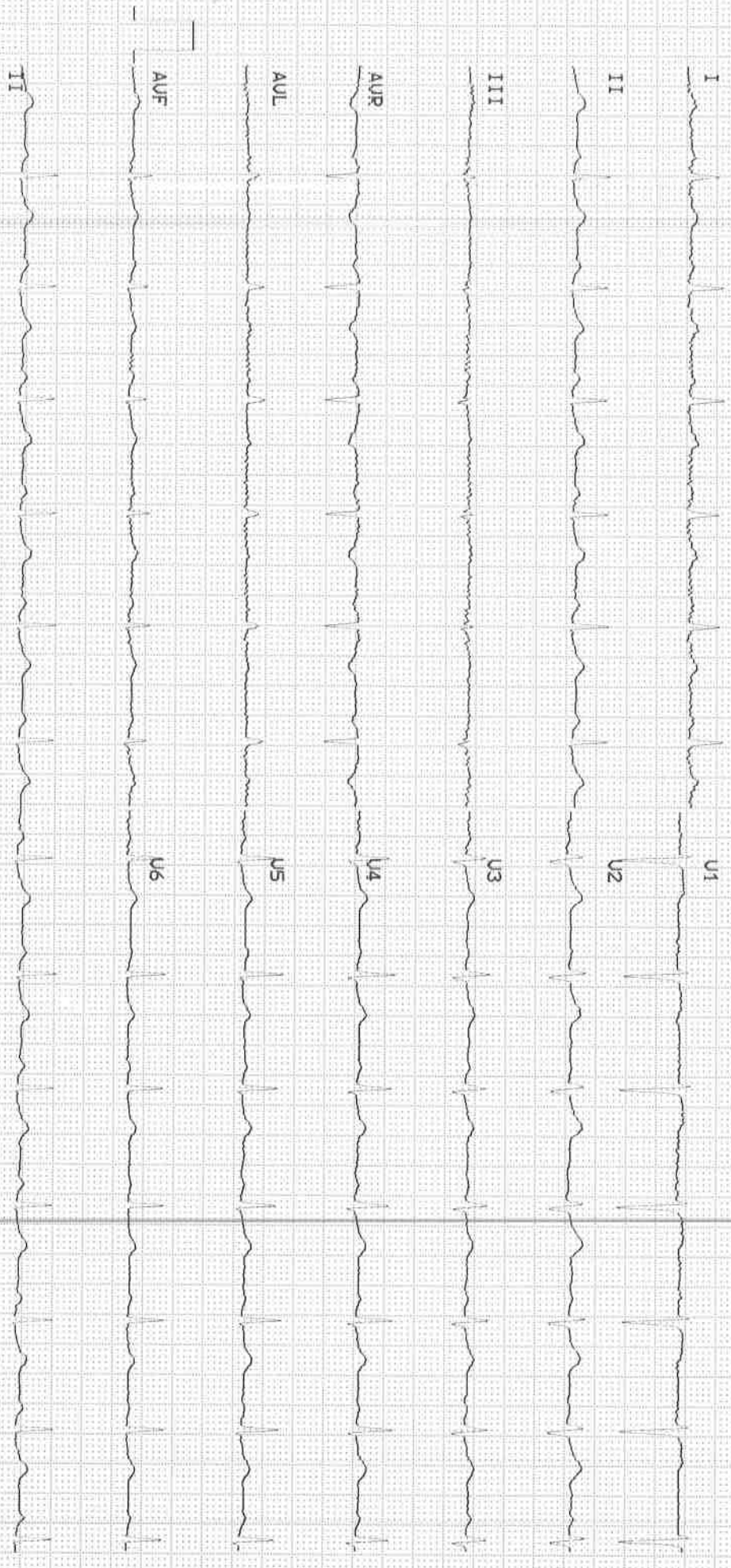
AGE: 41
 Measurement Results:
 QRS : 86 ms
 QT/QTcB : 408 / 467 ms
 PR : 150 ms
 P : 102 ms
 RR/PP : 764 / 735 ms
 P/QRS/T : 50 / 35 / 50 degrees
 QTd/QTcBd : 30 / 34 ms
 Sokolow : 1.5 mV
 NK : 11



Interpretation:

(2) S/P up

Unconfirmed report.



Patient Name	: Mrs. Saritha K S	Age	: 41 Y/F
UHID	: CKOR.0000248307	OP Visit No	: CKOROPV389781
Reported By:	: Dr. MOHAN MURALI	Conducted Date	: 30-11-2023 15:26
Referred By	: SELF		

ECG REPORT

Observation :-

1. Normal Sinus Rhythm.
2. Heart rate is 78beats per minutes.
3. No pathological Q wave or S-T,T changes seen.
4. Normal P,Q,R,S,T waves and axis.
5. No evidence of chamber, hypertrophy or enlargement seen

Impression:

NORMAL RESTING ECG.

Dr. MOHAN MURALI
CARDIOLOGIST

NOTE : KINDLY TAKE A PHOTOCOPY OF THE GRAPH
FOR FUTURE REFERENCE IF NEEDED.

----- END OF THE REPORT -----

Patient Name : Mrs Saritha K S

Patient ID : 248307

Age : 41ear(s)

Sex : Female

Referring Doctor : H/C

Date : 30.11 .2023

ULTRASOUND ABDOMEN AND PELVIS

Liver is normal in size and shows normal echo pattern. No biliary dilatation .No focal lesion
Portal vein is normal in size, course and caliber. CBD is not dilated.
Gall bladder is normal without evidence of calculi, wall thickening or pericholecystic fluid
Pancreas to the extent visualized, appears normal in size, contour and echogenicity
Spleen is normal in size, shape, contour and echopattern. No evidence of mass or focal lesion.
Right kidney is normal in size, position, shape and echopattern. Corticomedullary differentiation is maintained. No evidence of calculi or hydronephrosis.
Left kidney is normal in size, position, shape and echopattern.corticomedullary differentiation is maintained. No evidence of calculi or hydronephrosis.
Urinary Bladder is well distended. wall thickness is normal. No internal echoes.
Uterus: is normal in size. Endometrial echoes are normal
Endometrium: measures 2.0 mm.
Both ovaries are normal in size and echopattern.
Both adnexa: Normal, no mass seen.
There is no ascites.

IMPRESSION:

- **NO SIGNIFICANT ABNORMALITY DETECTED**

**DR VINOD JOSEPH DNB,DMRD
RADIOLOGIST**

DR VIJAYA LAKSHMI M
M.B.B.S, D.L.O, D.N.B(ENT)
Phone No.9972044580,080-25633823/24/23

HEALTH CHECK- ENT

30/11/23

NAME: *Sarika K.S.* **P** **AGE:** *4 1/2*

EAR: **RE:** **LE:**

EXTERNAL EAR
MIDDLE EAR
INNER EAR (FN) *Normal*

HEARING ASSESSMENT: **RE:** **LE:**

RHINNE
WEBER
ABC *Normal*

NOSE **THROAT**
AIRWAY
SEPTUM
TURBINATES *Normal* ORAL CAVITY
OTHERS *Normal* OROPHARYNX
LARYNX *Normal*

NECK
NECK NODES
OTHER *Normal*

AUDIOMETRY

IMPRESSION *Normal* **SIGNATURE:** *[Signature]*

Date : 30/11/23
MRNO :
Name : Mrs. Saranya
Age/Gender : 41 YRS

Department : OBSTETRICS & GYNAECOLOGY
Consultant : DR. JYOTHI RAJESH
KMC NO-42823
Qualification : DGO (DNB)
Consultation Timings : 9.30pm to 12.00pm
PHONE NO: 9972044580

Height :	Weight :	BMI :	Waist Circum :
Temp :	Pulse :	Resp :	B.P :

General Examination / Allergies
History

Clinical Diagnosis & Management Plan

No gynae complaints
Mm. mnc - regular since 20/11
OBN. P2L2 L0-1040 USC
3AT done
Past H. - NOS
Family H. - Paro - DM
Molta - 1/12
DE. P/A self

Plu - Cx 1 @ 10 Oct 2023
Plu - USG

Follow up date: 02 Dec 2023

Doctor Signature

DR. MAHABALESHWAR.M
MBBS.(MYS), MD(AIIMS DELHI)FICS
D.O (JIPMER)
REG.NO:KMC:9748

DATE: 30-11-23
OP NO:

THE APOLLO MEDICAL CENTER KORAMANGALA

NAME: *M. Ganika K.R.*
AGE : *61*
GENDER: *F*

OPHTHALMIC REPORT

RIGHT EYE

LEFT EYE

GENERAL APPEARANCE

VISION - DISTANCE

WITHOUT GLASS

6/6

6/6

WITH GLASS

GLASS POWER

NEAR

WITHOUT GLASS

NB

NB

WITH GLASS

GLASS POWER

COLOUR

- normal

ANTERIOR SEGMENT:

FUNDUS

unc

myoma

I.O.P: DIGITAL

DOCTOR SIGNATURE