

B बैंक ऑफ़ बड़ोदा
Bank of Baroda

नाम: MR. AJAY DAHIYA
Name:

कर्मचारी कूट क्र. 121350
E. C. No.



Ajay Dahiya

धारक के हस्ताक्षर
Signature of Holder

जारीकर्ता प्राधिकारी, यु. प्र. (सु.) अ.का. न.दि.
Issuing Authority CM (S), ZO, ND




Dr. NITIN AGARWAL
MBBS, MD,
Regn. No. DMC-R-1436

Ajay Dahiya

ONEPLUS ULTRASOUND LAB
47, Marsh Vihar, Pitam Pura,
Delhi-110034
Ph. 011-42480101, 9599913051
E-mail: oneplusul@gmail.com

पता पर पत्राचार को लीजिए
सुरक्षक महाप्रबन्धक (सुरक्षा)
बैंक ऑफ़ बड़ोदा कॉर्पोरेट सेंटर
बी-26, जी ब्लॉक, बन्दरा-कुर्ला कॉम्प्लेक्स
मुंबई 400 051, भारत
फोन : 91 22 6698 51 96 फ़ैक्स : 91 22 2652 5747
If found, please return to:
Asst. General Manager (Security)
Bank of Baroda, Baroda Corporate Center
C-26, G-Block, Bandra-Kurla Complex
Mumbai 400 051, India
Phone : 91 22 6698 5196, Fax : 91 22 2652 5747
रक्त समूह / Blood Group : B+
Burnt mark on left side of the
Identification Marks : forehead




Dr. NITIN AGARWAL
MBBS, MD
Regn. No. DMC-R-1436


Dr. Nitin

ONEPLUS ULTRASOUND LAB
47, Harsh Vihar, Pitam Pura,
Delhi-110034
Ph. 011-42480101, 9599913051
E-mail: oneplusul@gmail.com

ONEPLUS ULTRASOUND LAB

47, HARSH VIHAR, PITAMPURA, DELHI- 110034

Mr. AJAY DAHIYA

Age : 31/M

Ref. by : MEDIWHEEL

Indication1 :

Indication2 :

Indication3 :

COMMENTS : Likely incomplete RBBB. Sinus Rhythm.

ID : 2139

H/Wt : 170/70

Recorded : 13- 3-2023 10:16

Medication1 :

Medication2 :

Medication3 :

BPM : 78

BP : 122/78

P Axis : 87 deg

QRS Axis : 14 deg

T Axis : 58 deg

P duration : 86 msec

PR duration : 123 msec

QRS duration : 103 msec

QT interval : 296 msec

QTc interval : 327 msec

Raw E.C.G.(Seq)

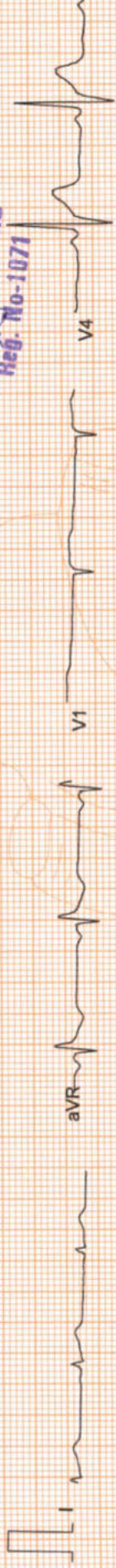Unconfirmed Report Reviewed By:

Cardiologist

~~Dr. A.K. GUPTA~~

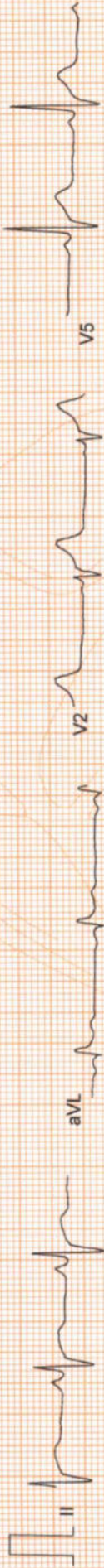~~Dr. S.B.S. MD~~

Reg. No-1071



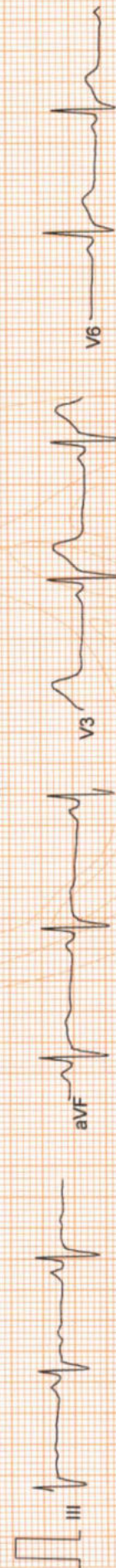V1

aVR



V2

aVL

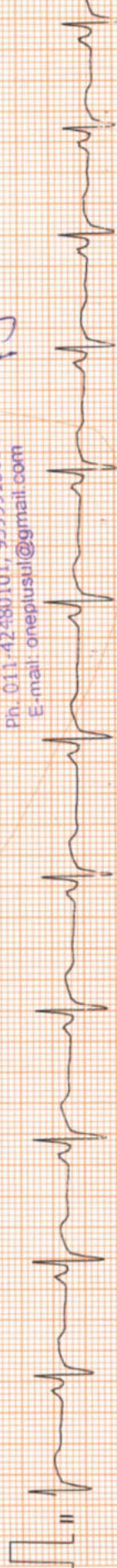

V3

aVF

Dr. S.B.S. MD

ONEPLUS ULTRASOUND LAB
47, Harsh Vihar, Pitam Pura,
Delhi-110034
Ph. 011-42480101, 9599913051
E-mail: oneplusul@gmail.com



V4



V5



V6

ONEPLUS ULTRASOUND LAB

47, HARSH VIHAR PITAMPURA DELHI 110034

Mr. AJAY DAHIYA

Age/Sex : 31/M

Ref. by : MED/WHEEL

Indication1 :

Indication2 :

Indication3 :

ID : 990

H/Wt : 170/70

Recorded : 13-3-2023 10:22

TREADMILL TEST SUMMARY REPORT

Protocol: BRUCE

History:

Medication1 :

Medication2 :

Medication3 :

PHASE	PHASE TIME	STAGE TIME	SPEED (Km./Hr.)	GRADE (%)	H.R. (BPM)	B.P. (mmHg)	RPP X100	II	ST LEVEL (mm) V2	V5	METS
STANDING SUPINE					81 82	122/78 122/78	98 100	1.0 1.0	2.2 2.2	1.4 1.4	
STAGE 1	2:59	2:59	2.70	10.00	84	132/80	110	0.9	1.7	1.5	4.80
STAGE 2	5:59	2:59	4.00	12.00	92	140/84	128	1.2	1.5	1.7	7.10
STAGE 3	8:59	2:59	5.40	14.00	119	152/86	180	1.4	1.3	2.4	10.00
STAGE 4	11:59	2:59	6.70	16.00	160	164/88	262	2.0	0.6	2.9	14.00
PEAK EXER	12:10	0:10			167	174/90	290	1.8	0.4	2.6	14.34
RECOVERY	2:59	2:59	0.00	0.00	84	130/80	109	0.6	1.0	1.1	

RESULTS

Exercise Duration : 12.10 Minutes
 Max Heart Rate : 167 bpm 88 % of target heart rate 189 bpm
 Max Blood Pressure : 174/90 mmHg
 Max Work Load : 14.34 METS

Reason of Termination :

IMPRESSIONS

Normal for age & sex

ONEPLUS ULTRASOUND LAB

47, Harsh Vihar, Pitam Pura,

Delhi-110034

Ph. 011-42480101, 9599913051

E-mail: oneplusul@gmail.com

Dr. Pooja Gupta
Dr. POOJA GUPTA
M.B.B.S, MD
Reg. Cardiologist

Dr. Pooja Gupta

ONEPLUS ULTRASOUND LAB

Mr. AJAY DAHIYA
I.D. : 990
AGE/SEX : 31/M

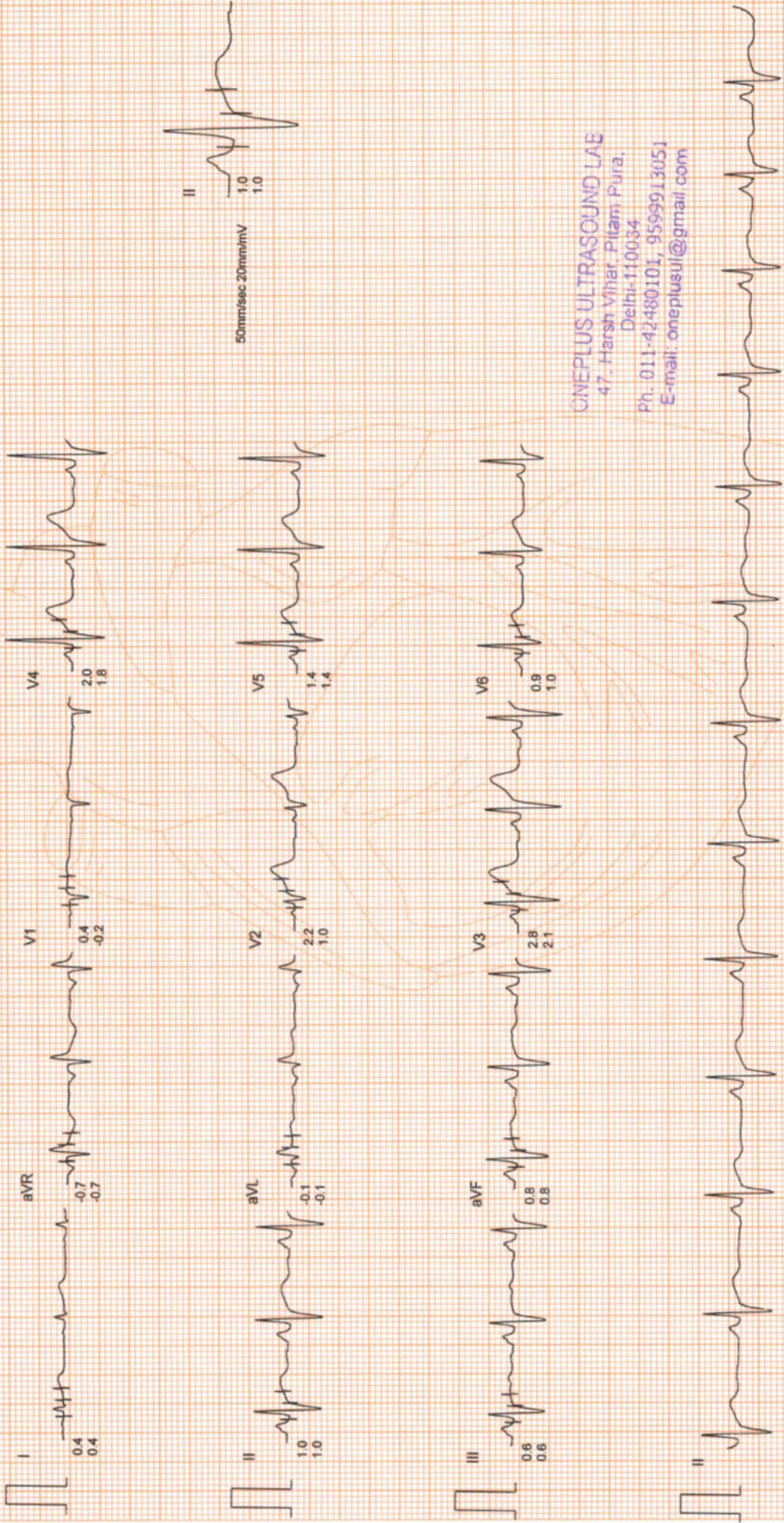
ST @ 10mm/mV
80ms PostJ

STANDING
PRETEST

RATE : 81 BPM
B.P. : 122/78 mmHg

RECORDED : 13-3-2023 10:22

LINKED MEDIAN



ONEPLUS ULTRASOUND LAB
47, Harsh Vihar Pitam Pura,
Delhi-110034
Ph. 011-42480101, 9599913051
E-mail: oneplusul@gmail.com

ONEPLUS ULTRASOUND LAB

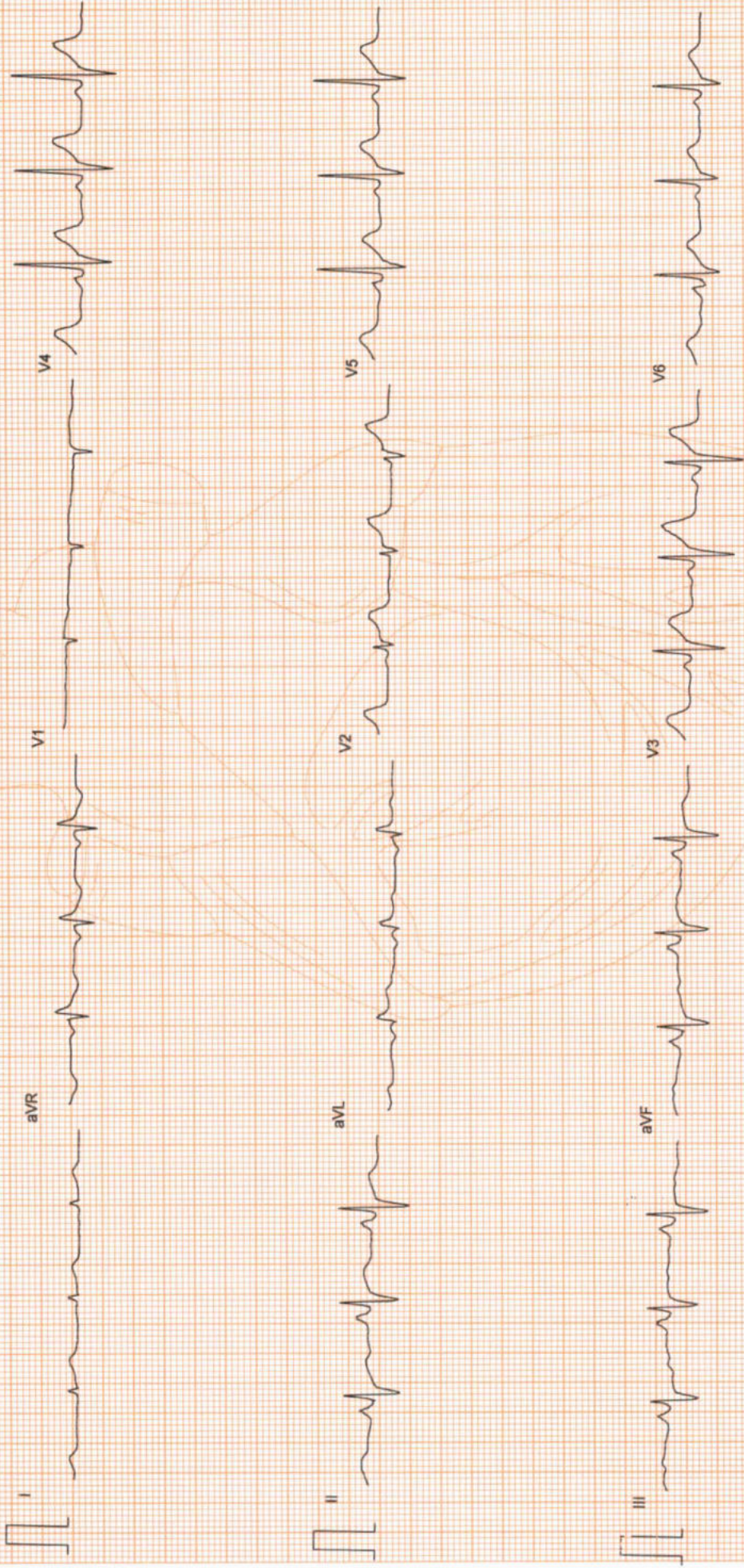
Mr. AJAY DAHIYA
I.D. : 990
AGE/SEX : 31/M
RECORDED : 13-3-2023 10:22

SUPINE
PRETEST

RATE : 82 BPM
B.P. : 122/78 mmHg

ST @ 10mm/mV
80ms PostJ

RAW E.C.G.



ONEPLUS ULTRASOUND Lab
47, Harsh Vihar, Pitam Pura,
Delhi-110034
Ph: 011-42480101, 9599913053
E-mail: oneplusul@gmail.com

ONEPLUS ULTRASOUND LAB

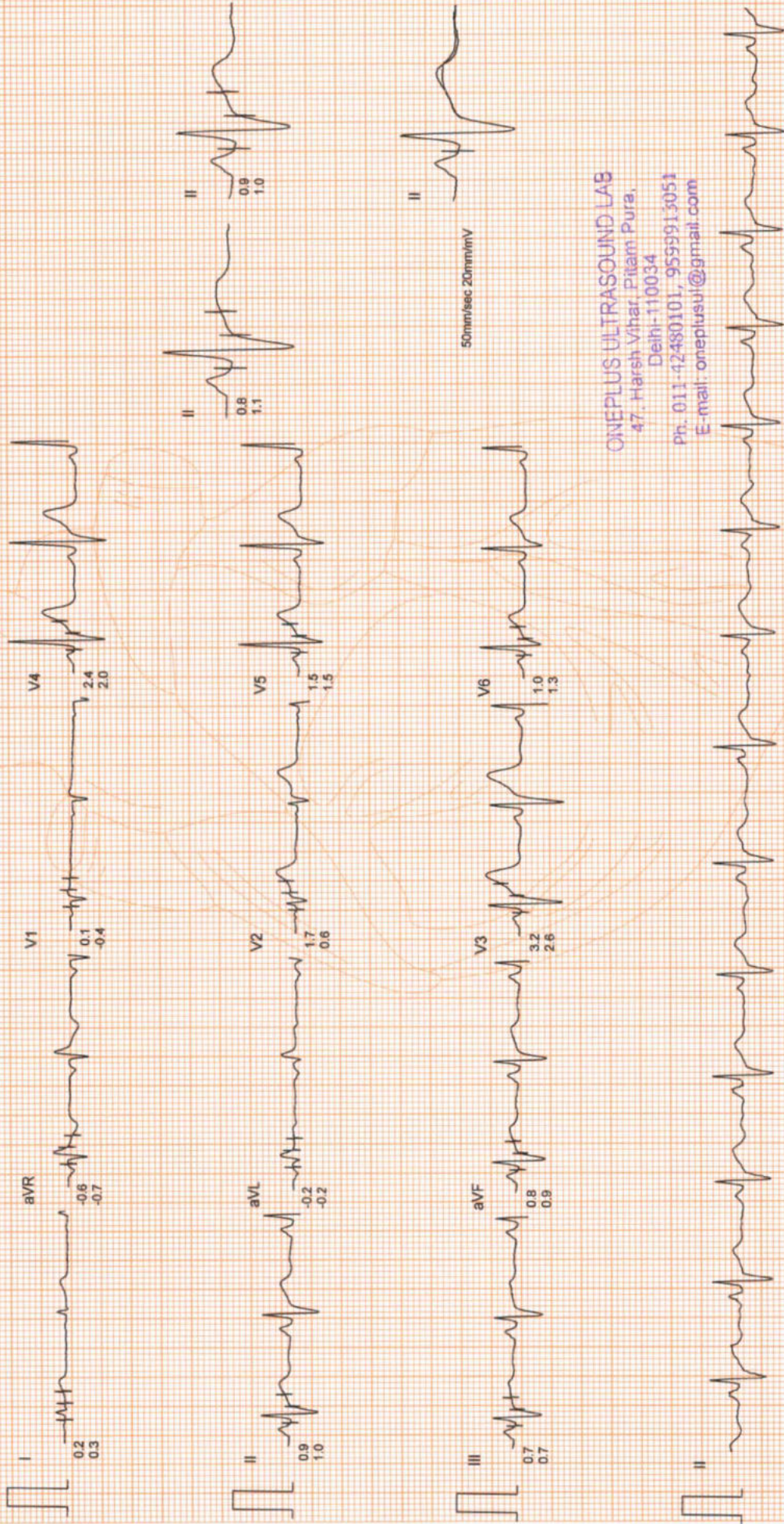
Mr. AJAY DAHIYA
I.D. : 990
AGE/SEX : 31/M
RECORDED : 13-3-2023 10:22

RATE : 84 BPM
B.P. : 132/80 mmHg

BRUCE
EXERCISE 1
PHASE TIME : 2:59
STAGE TIME : 2:59

ST @ 10mm/mV
80ms PostJ
SPEED : 2.7 Km./Hr.
GRADE : 10.0 %

LINKED MEDIAN



ONEPLUS ULTRASOUND LAB
47, Harsh Vihar, Pitam Pura,
Delhi-110034
Ph. 011-42480101, 9559913051
E-mail: oneplusul@gmail.com

ONEPLUS ULTRASOUND LAB

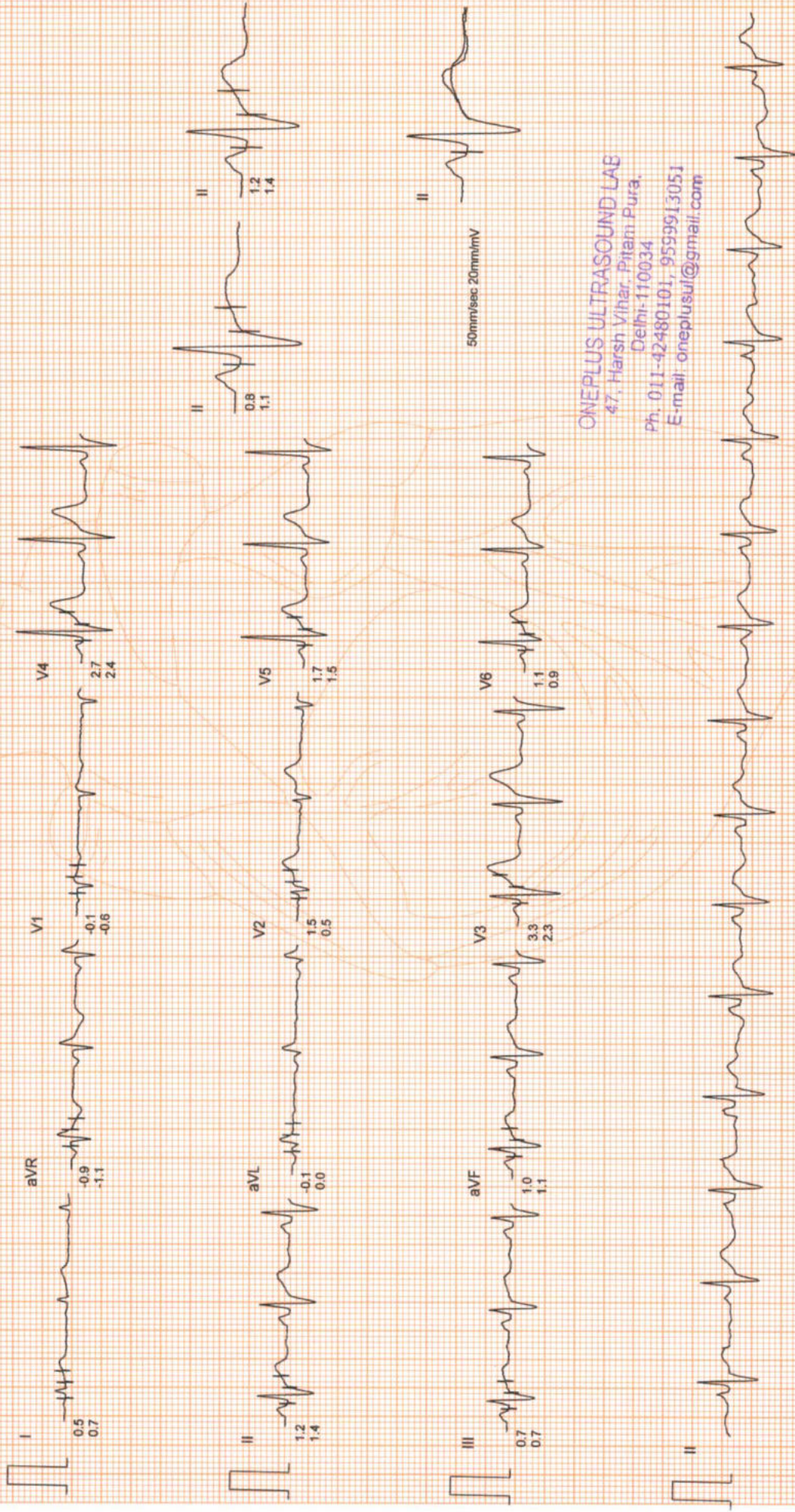
Mr. AJAY DAHIYA
I.D. : 990
AGE/SEX : 31/M
RECORDED : 13-3-2023 10:22

BRUCE
EXERCISE 2
PHASE TIME : 5:59
STAGE TIME : 2:59

RATE : 92 BPM
B.P. : 140/84 mmHg

ST @ 10mm/mV
80ms PostJ
SPEED : 4.0 Km/Hr.
GRADE : 12.0 %

LINKED MEDIAN



50mm/sec 20mm/mV

ONEPLUS ULTRASOUND LAB
47, Harsh Vihar, Pitam Pura,
Delhi-110034
Ph. 011-42480101, 9599913051
E-mail: onepplusul@gmail.com

ONEPLUS ULTRASOUND LAB

Mr. AJAY DAHIYA

I.D. : 990

AGE/SEX : 31/M

RECORDED : 13-3-2023 10:22

RATE : 119 BPM

B.P. : 152/86 mmHg

BRUCE

EXERCISE 3

PHASE TIME : 8:59

STAGE TIME : 2:59

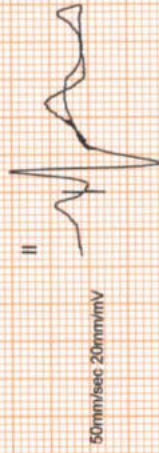
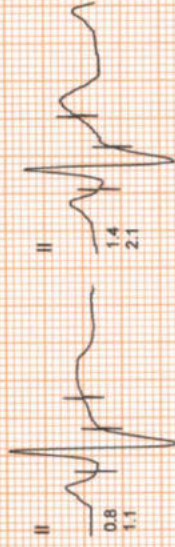
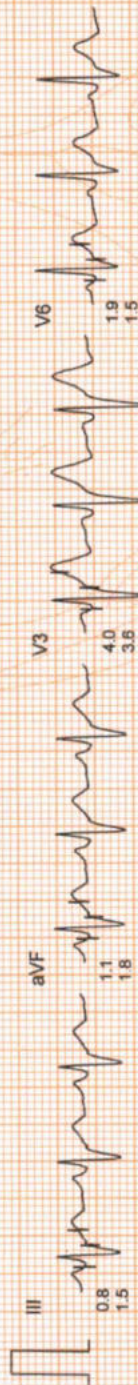
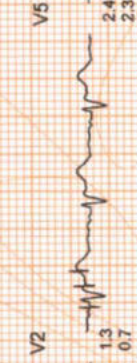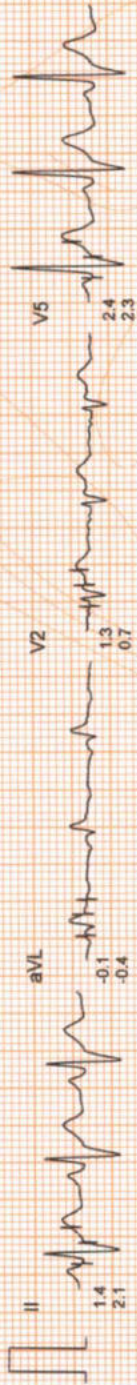
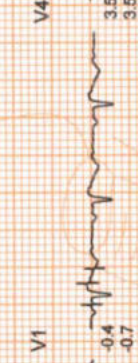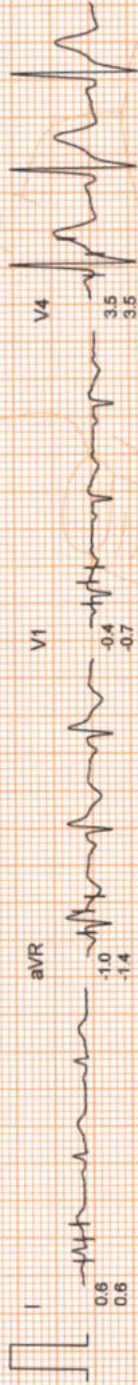
ST @ 10mm/mV

80ms PostJ

SPEED : 5.4 Km./Hr.

GRADE : 14.0 %

LINKED MEDIAN



50mm/sec 20mm/mV

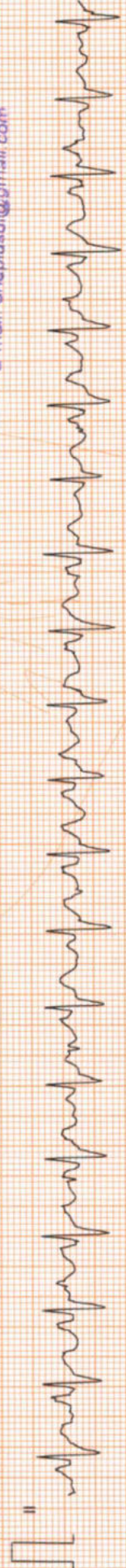
ONEPLUS ULTRASOUND LAB

47, Harsh Vihar, Pitam Pura,

Delhi-110034

Ph: 011-42480101, 9599913051

E-mail: oneplusul@gmail.com



ONEPLUS ULTRASOUND LAB

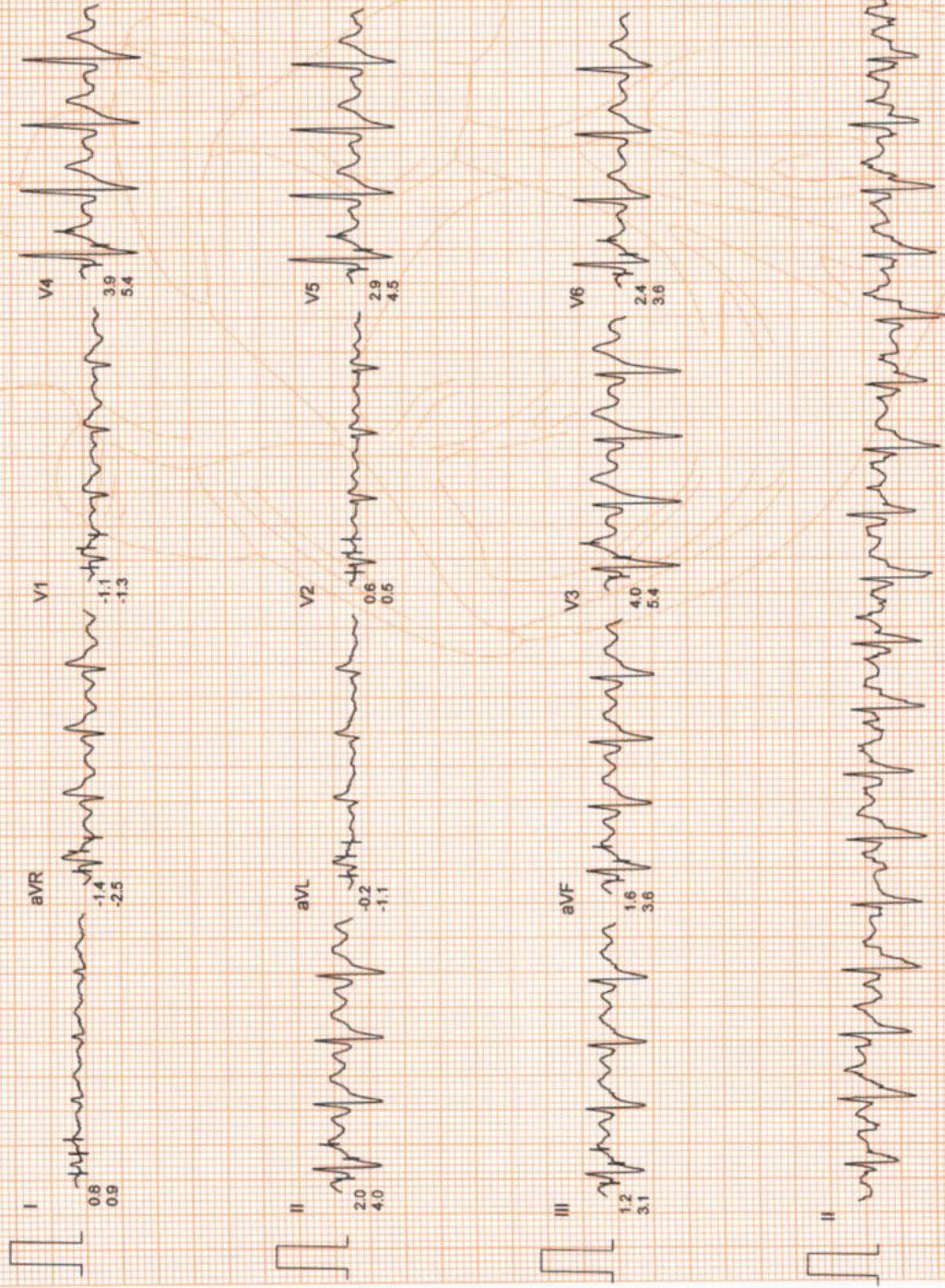Mr. AJAY DAHIYA
I.D. : 990
AGE/SEX : 31/M
RECORDED : 13-3-2023 10:22

RATE : 160 BPM
B.P. : 164/88 mmHg

BRUCE
EXERCISE 4
PHASE TIME : 11:59
STAGE TIME : 2:59

ST @ 10mm/mV
80ms PostJ
SPEED : 6.7 Km./Hr.
GRADE : 16.0 %

LINKED MEDIAN



ONEPLUS ULTRASOUND LAB
47, Harsh Vihar, Pitam Pura,
Delhi-110034
Ph. 011-42480101, 9599913051
E-mail: oneplusul@gmail.com

ONEPLUS ULTRASOUND LAB

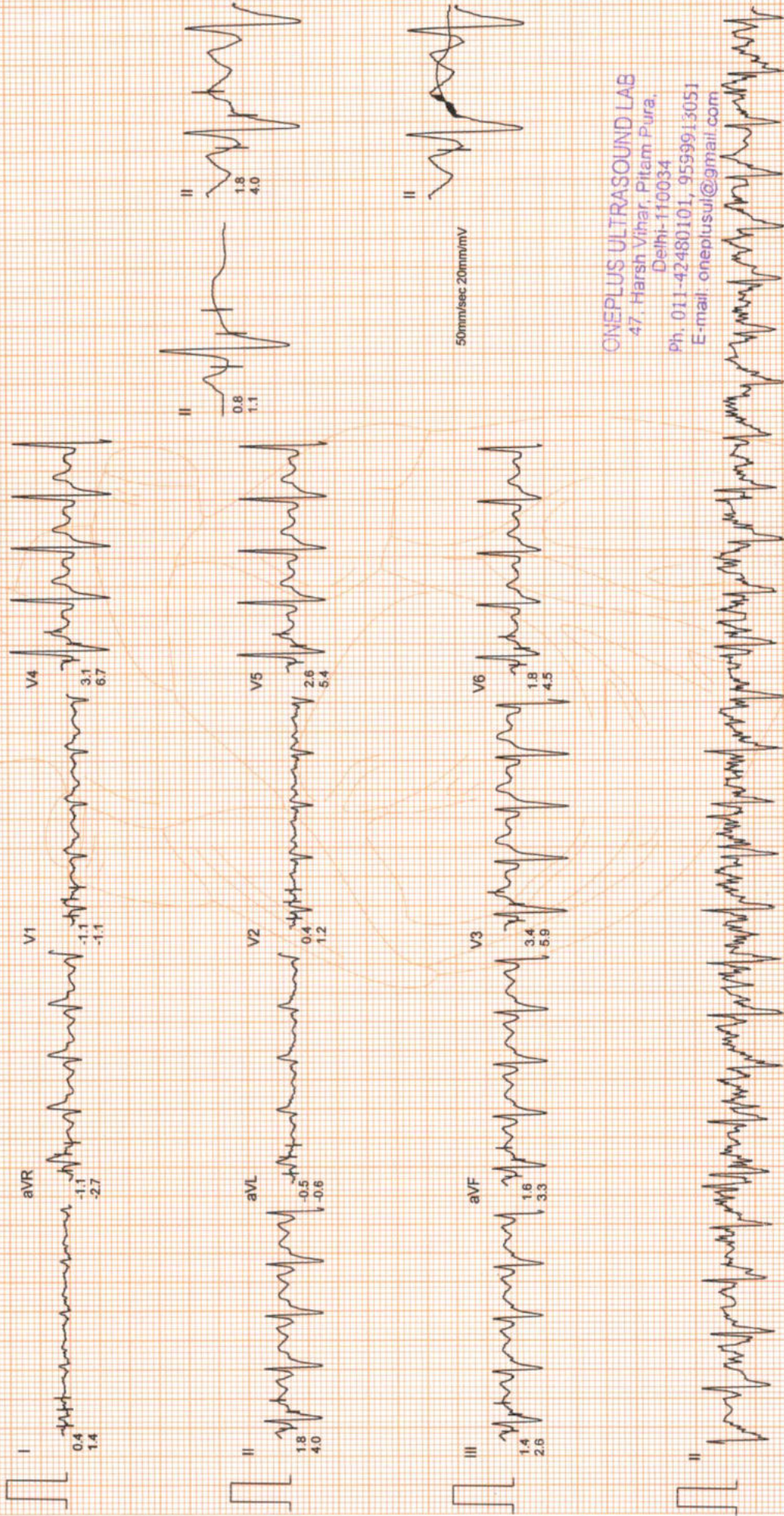Mr. AJAY DAHIYA
I.D. : 990
AGE/SEX : 31/M
RECORDED : 13-3-2023 10:22

RATE : 167 BPM
B.P. : 174/90 mmHg

BRUCE
PEAK EXER
PHASE TIME : 12:10
STAGE TIME : 0:10

ST @ 10mm/mV
80ms PostJ
SPEED : 8.0 Km./Hr.
GRADE : 18.0 %

LINKED MEDIAN



ONEPLUS ULTRASOUND LAB
47, Harsh Vihar, Pitam Pura,
Delhi-110034
Ph. 011-42480101, 9599913051
E-mail: oneplusul@gmail.com

Filtered

Computer Corrected Baseline

25mm/sec 10mm/mV

CardiCom, INDIA Ph..091-731-2620740, TeleFax:091-731-2431214

GREEN INDIA

ONEPLUS ULTRASOUND LAB

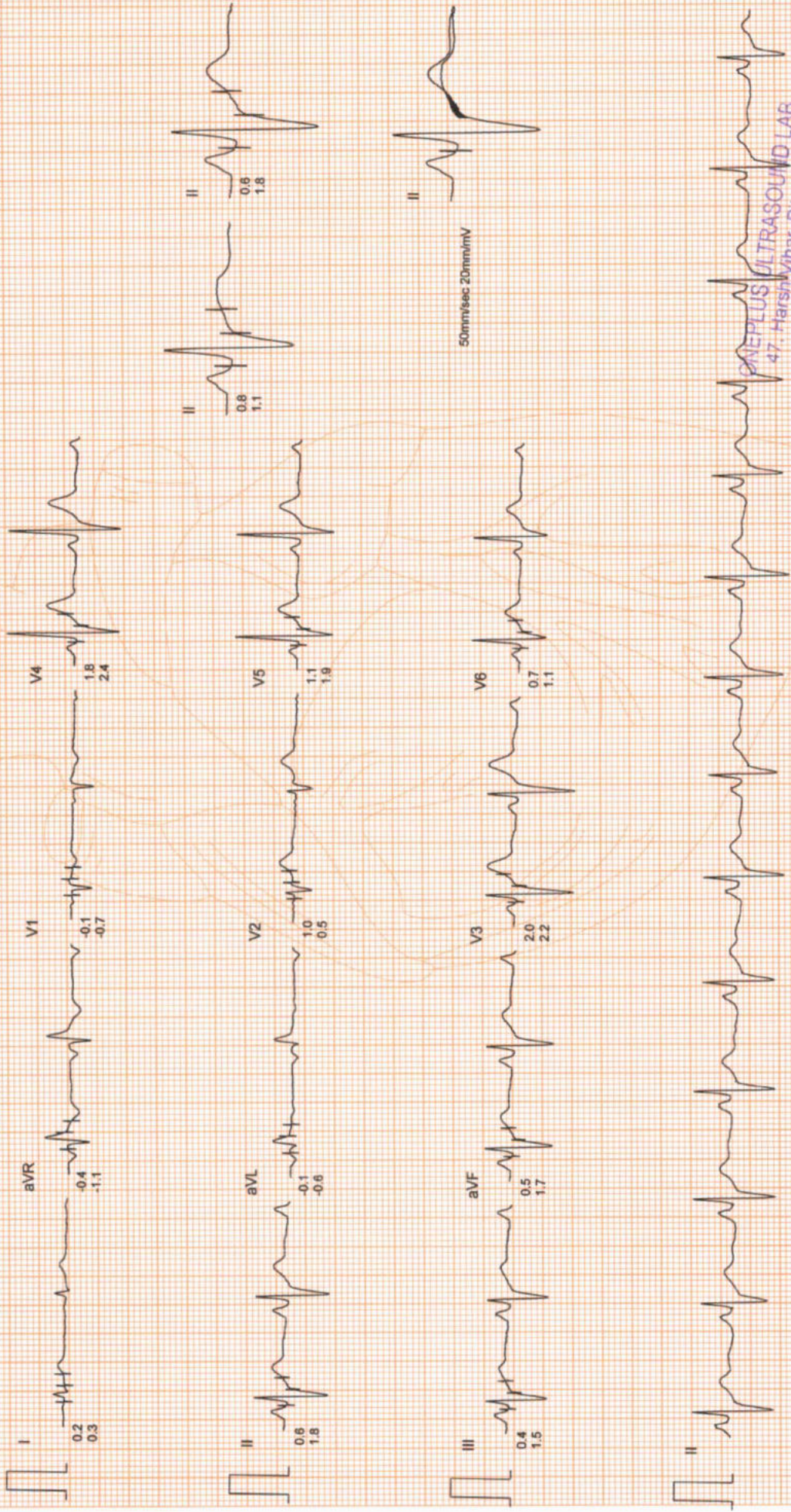
Mr. AJAY DAHIYA
I.D. : 990
AGE/SEX : 31/M
RECORDED : 13-3-2023 10:22

BRUCE
RECOVERY
PHASE TIME : 2:59

RATE : 84 BPM
B.P. : 130/80 mmHg

ST @ 10mm/mV
80ms PostJ
SPEED : 0.0 Km./Hr.
GRADE : 0.0 %

LINKED MEDIAN



Filtered

Computer Corrected Baseline

25mm/sec 10mm/mV

CardiCom, INDIA Ph.:091-731-2620740, TeleFax:091-731-2431214

ONEPLUS ULTRASOUND LAB
47, Harsh Vihar, Pitam Pura,
Delhi-110034
Ph. 011-42480101, 9599913051
E-mail: oneplusul@gmail.com

ONEPLUS ULTRASOUND LAB

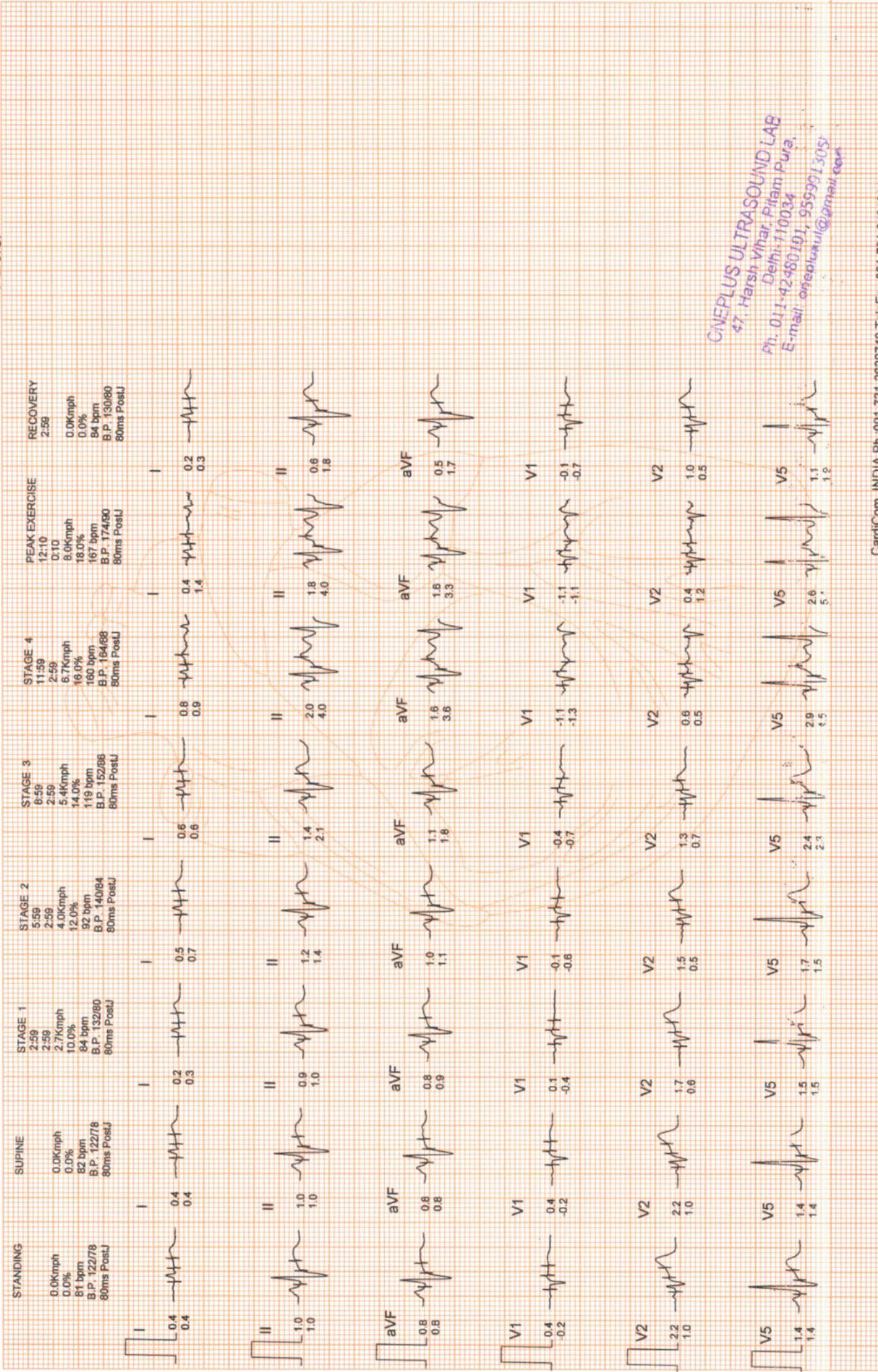
Mr. AJAY DAHIYA

I.D. : 990

AGE/SEX : 31/M

RECORDED : 13-3-2023 10:22

AVG E.C.G.



ONEPLUS ULTRASOUND LAB
47, Harsh Vihar, Pitam Pura,
Delhi-110034
E-mail: oneplusul@gnail.com

ONEPLUS ULTRASOUND LAB

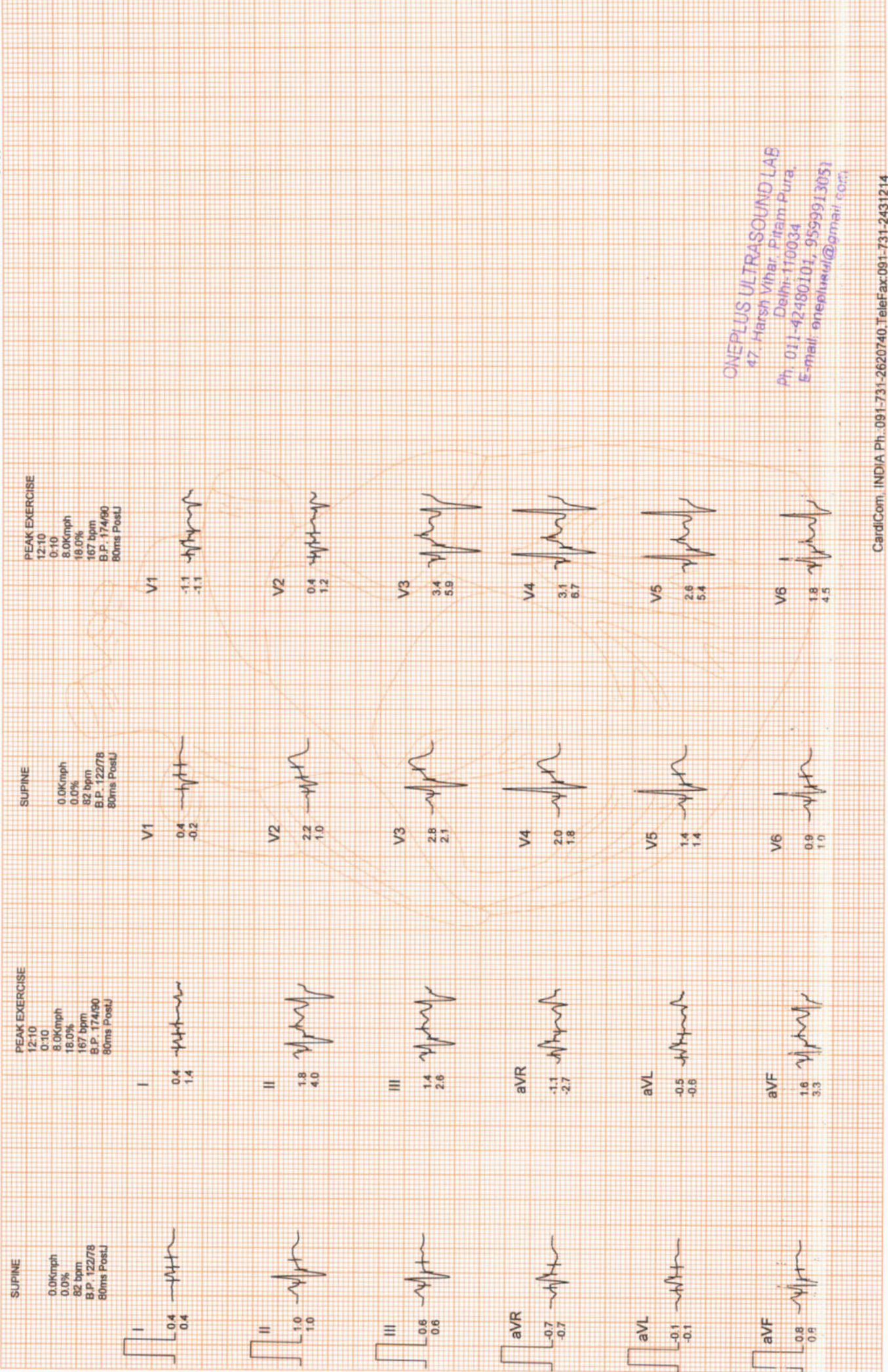
AGE/SEX : 31/M

Mr. AJAY DAHIYA

I.D. : 990

RECORDED : 13-3-2023 10:22

COMPARISON REPORT



ONEPLUS ULTRASOUND LAB
47, Harsh Vihar, Pitam Pura,
Delhi-110034
Ph. 011-42480101, 9599913051
E-mail: oneplusul@gmail.com



OnePLUS
Ultrasound Lab
— QUALITY FIRST... ALWAYS! —

Dr. Nitin Agarwal

Pathologist & Director
Ex. Sr. Res. MAMC
& Lok Nayak Hospital
Ex. Chief of Lab Dr. Lal Path Labs.

Dr. Pooja (Garg) Agarwal

Radiologist & Director
MAMC & Lok Nayak Hospital

Name	: Mr. AJAY DAHIYA	Age/Sex	: 31 YRS/Male
Ref. By	: Dr. MEDIWHEEL	Lab No	: 012303130005
Date	: 13-Mar-2023	Patient ID	: LSHHI110588

ULTRASOUND EXAMINATION----WHOLE ABDOMEN

Liver is normal in size (13.4 cm) and outline with normal echopattern. No abscess or mass lesion seen. Hepatic veins, portal vein, IVC and aorta are normal. Intrahepatic biliary radicles are not dilated. CBD is normal in caliber (5.2 mm).

Gall bladder is well distended with anechoic lumen. Wall thickness is normal.

Right kidney is ectopic and malrotated, lying in right renal fossa and facing antero-medially. **Right renal pelvis is prominent.** It is normal in outline and echopattern. Corticomedullary differentiation is maintained

Left kidney is normal in size, shape, position, outline and echopattern. Corticomedullary differentiation is maintained. No pelvicalyceal dilation or calculus or mass lesion is seen.

Spleen is normal in size and echotexture. No mass lesion seen.

Pancreas is normal in size, outline and echotexture.

Urinary bladder is normal in shape and position. No evidence of intravesical stone or mass seen.

Prostate is normal in size, shape and echopattern.

Prostate measures 3.6 x 2.9 x 2.5 cm. **Weight of prostate is 15.3 grams.**

No abnormal bowel wall thickening seen in right iliac fossa.

No free fluid seen anywhere in abdomen.

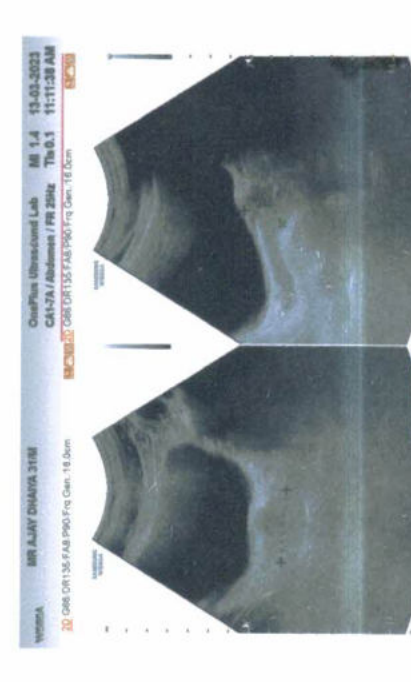
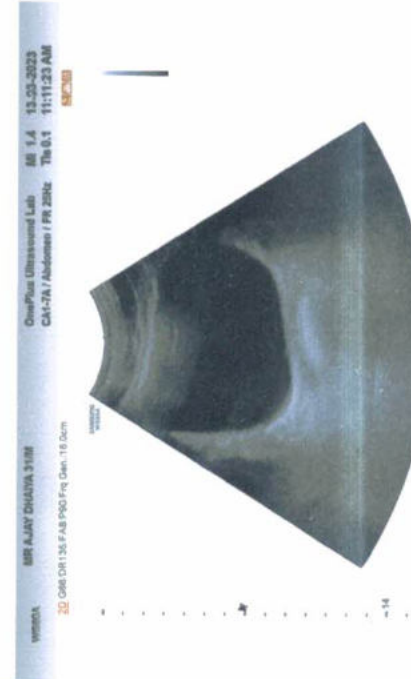
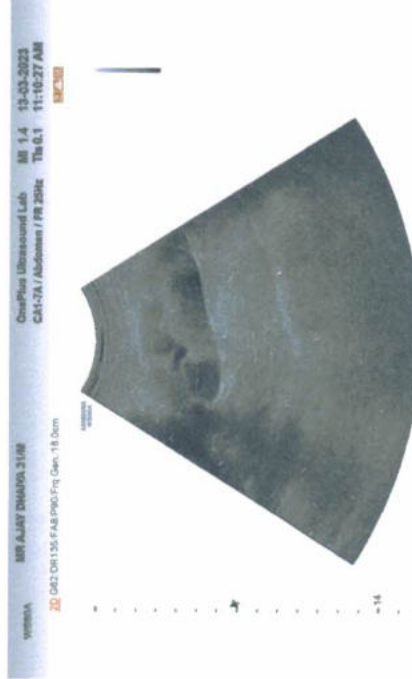

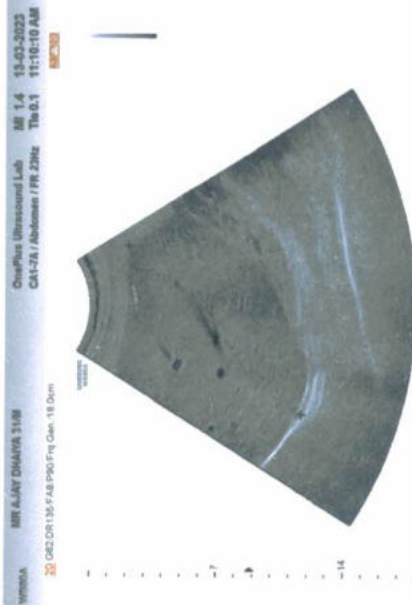
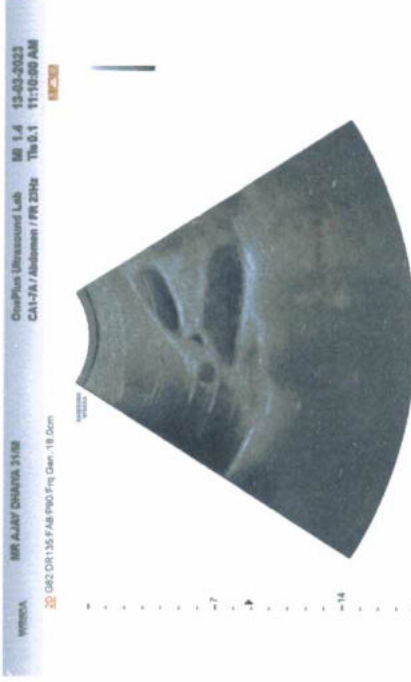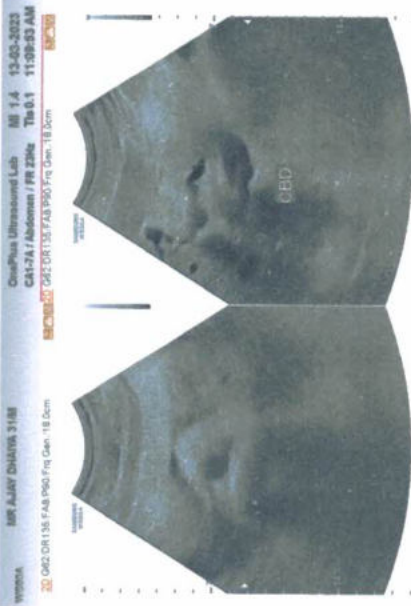
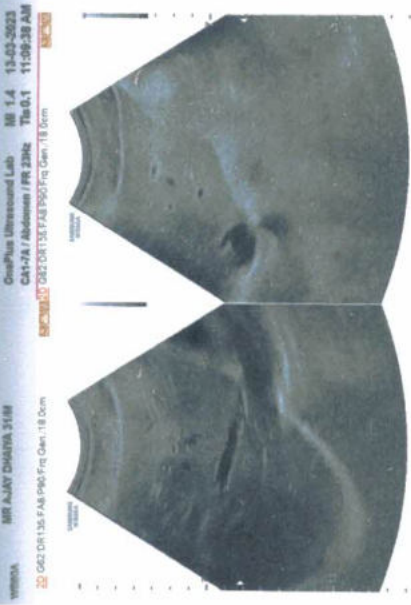Please correlate clinically

Dr. POOJA GARG
M.B.B.S., D.M.R.D.
Reg No. DMC/REG/NO. DMC/R/03398
Radiologist

Type By : darshita

47, Harsh Vihar, Pitampura, New Delhi-110034 | Ph.: 011-42480101, 9599913051


E-mail: oneplusul@gmail.com | Web.: www.oneplusul.in



D1 3.38 cm
D2 2.89 cm
D3 3.43 cm
D4 1.57 cm

D1 0.82 cm

D1 3.40 cm





OnePLUS

Ultrasound Lab

— QUALITY FIRST... ALWAYS! —

Dr. Nitin Agarwal

Pathologist & Director
Ex. Sr. Res. MAMC
& Lok Nayak Hospital
Ex. Chief of Lab Dr. Lal Path Labs.

Dr. Pooja (Garg) Agarwal

Radiologist & Director
MAMC & Lok Nayak Hospital



NAME	:Mr. AJAY DAHIYA	Barcode No	:10139840
AGE/GENDER	:31 YRS/Male	SPECIMEN DATE	:13/Mar/2023 09:13AM
PATIENT ID	:110588	SPECIMEN RECEIVED	:13/Mar/2023 09:25AM
REFERRED BY	:Dr. MEDIWHEEL	REPORT DATE	:13/Mar/2023 04:39PM
CENTRE NAME	:ONEPLUS ULTRASOUND LAB	LAB NO.	:012303130005

Test Name	Result	Unit	Ref. Range
-----------	--------	------	------------

HAEMATOLOGY

Medi Wheel Health checkup < 40 Male

<u>Glycosylated Hemoglobin (HbA1c)</u>	5.0	%	Non Diabetic adults <5.7 Prediabetic (at risk) 5.7-6.4 Diabetes >6.4
--	-----	---	--

Estimated average blood glucose (eag) 97


Reference range (mg/dl):

90 - 120:Excellent control, 121 - 150:Good Control, 151 - 180:Average Control, 181 - 210:Action Suggested

>211:Panic value

Checked By.

Dr NITIN AGARWAL
M B B S , MD (Path)
DMC/R/01436


DR. NITIN AGARWAL
MBBS,MD(PATHOLOGIST)

47, Harsh Vihar, Pitampura, New Delhi-110034 | Ph.: 011-42480101, 9599913051

E-mail: oneplusul@gmail.com | Web.: www.oneplusul.in

Page 1 of 7

Clinical correlation is essential for final diagnosis. • If test results are unsatisfactory please contact personally or on phone. • This report is for perusal of doctors only.
• All disputes Subject to Delhi Jurisdiction only. • Not for medicolegal purposes. • All congenital anomalies in a foetus may not be diagnosed in routine obstetric ultrasound.



OnePLUS Ultrasound Lab

— QUALITY FIRST... ALWAYS! —

Dr. Nitin Agarwal

Pathologist & Director

Ex. Sr. Res. MAMC

& Lok Nayak Hospital

Ex. Chief of Lab Dr. Lal Path Labs.

Dr. Pooja (Garg) Agarwal

Radiologist & Director

MAMC & Lok Nayak Hospital



NAME	:Mr. AJAY DAHIYA	Barcode No	:10139840
AGE/GENDER	:31 YRS/Male	SPECIMEN DATE	:13/Mar/2023 09:13AM
PATIENT ID	:110588	SPECIMEN RECEIVED	:13/Mar/2023 09:25AM
REFERRED BY	:Dr. MEDIWHEEL	REPORT DATE	:13/Mar/2023 11:34AM
CENTRE NAME	:ONEPLUS ULTRASOUND LAB	LAB NO.	:012303130005

Test Name	Result	Unit	Ref. Range
-----------	--------	------	------------

HAEMATOLOGY

BLOOD GROUP (ABO)

B

Rh typing

POSITIVE

NOTE :

- * Apart from major A,B,H antigens which are used for ABO grouping and Rh typing, many minor blood group antigens exist. Agglutination may also vary according to titre of antigen and antibody.
- * So before transfusion, reconfirmation of blood group as well as cross-matching is needed.
- * Presence of maternal antibodies in newborns, may interfere with blood grouping.
- * Auto agglutination (due to cold antibody, falciparum malaria, sepsis, internal malignancy etc.) may also cause erroneous result.

CBC

Haemoglobin	15.2	g/dl	13.0-17.0
Total Leucocyte Count	7100	/cumm	4000-10000
Differential leucocyte count			
Neutrophils	72.6	%	40-80
Lymphocyte	19.90	%	20-40
Monocytes	5.50	%	2-10
Eosinophils	1.5	%	1-6
Basophils	0.5	%	0-2
RBC Count	6.30	million/cumm	4.5 - 5.5
PCV(Hematocrit)	49.5	%	40-50
MCV	79.0	fL	83-101
MCH	24.3	Pg	27-32
MCHC	30.8	G/dL	32-35
Platelet count	227000	/cumm	150000-450000
RDW-CV	14.4	%	11.4-14.0
ESR(WESTEGRENs METHOD)	08	mm in 1st hr	0-20

Checked By.

Dr. NITIN AGARWAL
M B B S , MD (Path)
DMC/R/01436
DR. NITIN AGARWAL
MBBS,MD(PATHOLOGIST)

47, Harsh Vihar, Pitampura, New Delhi-110034 | Ph.: 011-42480101, 9599913051

E-mail: oneplusul@gmail.com | Web.: www.oneplusul.in

Page 2 of 7

Clinical correlation is essential for final diagnosis. • If test results are unsatisfactory please contact personally or on phone. • This report is for perusal of doctors only.
• All disputes Subject to Delhi Jurisdiction only. • Not for medicolegal purposes. • All congenital anomalies in a foetus may not be diagnosed in routine obstetric ultrasound.



OnePLUS Ultrasound Lab

— QUALITY FIRST... ALWAYS! —

Dr. Nitin Agarwal

Pathologist & Director
Ex. Sr. Res. MAMC
& Lok Nayak Hospital
Ex. Chief of Lab Dr. Lal Path Labs.

Dr. Pooja (Garg) Agarwal

Radiologist & Director
MAMC & Lok Nayak Hospital



NAME	:Mr. AJAY DAHIYA	Barcode No	:10139840
AGE/GENDER	:31 YRS/Male	SPECIMEN DATE	:13/Mar/2023 09:13AM
PATIENT ID	:110588	SPECIMEN RECEIVED	:13/Mar/2023 09:25AM
REFERRED BY	:Dr. MEDIWHEEL	REPORT DATE	:13/Mar/2023 04:39PM
CENTRE NAME	:ONEPLUS ULTRASOUND LAB	LAB NO.	:012303130005

Test Name	Result	Unit	Ref. Range
-----------	--------	------	------------

BIOCHEMISTRY

<u>Blood sugar fasting</u>	92	mg/dL	70-110
<u>Blood sugar pp</u>	115	mg/dL	70.0-140.0
<u>Bun (blood urea nitrogen)</u>	12.00	mg/dl	8.9-21.6
<u>Uric acid, serum</u>	4.2	mg/dl	3.5-7.2
<u>Creatinine, serum</u>	0.70	mg/dl	0.60-1.2

LFT(LIVER FUNCTION TEST)

Bilirubin Total	0.64	mg/dl	0.1-1.2
Bilirubin Conjugated	0.24	mg/dl	0-0.4
Bilirubin Unconjugated	0.4	mg/dl	up to 0.7
SGOT (AST)	24	U/L	0-46
SGPT (ALT)	22	U/L	0-49
Alkaline phosphatase	98	U/L	40-129
Gamma glutamyl transpeptidase	32	U/L	10-45
Total Protein	7.4	gm/dl	6.60 - 8.70
Albumin serum	4.2	g/dL	3.0-5.2
Globulin	3.20	gm/dl	1.8-3.4
Albumin/Globulin Ratio	1.31		1.10 - 2.50

LIPID PROFILE

Cholesterol	178	mg/dl	50-200
Triglycerides	104	mg/dL	25-150
HDL Cholesterol	44	mg/dL	40 - 60
LDL cholesterol	113	mg/dL	<130
VLDL cholesterol	20.8	mg/dL	5-40
Cholesterol/HDL Ratio	4.0		Low Risk 3.3-4.97 Average Risk 4.4-7.1 Moderate Risk 7.1-11.0 High Risk >11.0

Checked By.

Dr. NITIN AGARWAL
M B B S , M D
DMC/R/01430
DR. NITIN AGARWAL
MBBS, MD(PATHOLOGIST)

47, Harsh Vihar, Pitampura, New Delhi-110034 | Ph.: 011-42480101, 9599913051

E-mail: oneplusul@gmail.com | Web.: www.oneplusul.in

Page 3 of 7



OnePLUS Ultrasound Lab

— QUALITY FIRST... ALWAYS! —

Dr. Nitin Agarwal
Pathologist & Director
Ex. Sr. Res. MAMC
& Lok Nayak Hospital
Ex. Chief of Lab Dr. Lal Path Labs.

Dr. Pooja (Garg) Agarwal
Radiologist & Director
MAMC & Lok Nayak Hospital



NAME	:Mr. AJAY DAHIYA	Barcode No	:10139840
AGE/GENDER	:31 YRS/Male	SPECIMEN DATE	:13/Mar/2023 09:13AM
PATIENT ID	:110588	SPECIMEN RECEIVED	:13/Mar/2023 09:25AM
REFERRED BY	:Dr. MEDIWHEEL	REPORT DATE	:13/Mar/2023 04:39PM
CENTRE NAME	:ONEPLUS ULTRASOUND LAB	LAB NO.	:012303130005

Test Name	Result	Unit	Ref. Range
LDL/HDL Ratio	2.6		0 - 3.55
According to ATP III and NCEP guidelines			

Parameter	Normal	Desirable	Borderline	High
Total cholesterol	<200		200-239	240
Triglycerides	<150	150-199	200-499	500
LDL	Optimal <100 Near Optimal 100-129	130-159	160-180	190
HDL	<40 : LOW 60 : HIGH			

BUN/Creatinine ratio

Bun (blood urea nitrogen)	12.00	mg/dl	8.9-21.6
CREATININE	0.70	mg/dl	0.30-1.10
BUN/Creatinine ratio	17.14		10.0 - 20.0

ENDOCRINOLOGY

THYROID PROFILE(T3,T4,TSH)

Triiodothyronine total [t3]	0.84	ng/dl	0.52-1.9
Thyroxine total [t4]	7.40	µg/dl	4.4 - 10.8
TSH (Thyroid Stimulating Hormone)	2.28	µIU/ml	0.25-5.0

AGE WISE VARIATION IN TSH

AGE	TSH(µIU/ml)	AGE	TSH(µIU/ml)
1-4 weeks	1.00 - 19.0	16-20 yrs	0.25 - 5.0
1-12 mths	1.70 - 9.1	21 - 80 yrs	0.25 - 5.0
1-5 yrs	0.80 - 8.2	I st trimester	0.25 - 5.0
6-10 yrs	0.25 - 5.0	II nd trimester	0.50 - 5.0
11-15 yrs	0.25 - 5.0	III rd trimester	0.4 - 6.0

Checked By.

Dr. NITIN AGARWAL
MBBS, MD (Path)
DMC/R/01156
DR. NITIN AGARWAL
MBBS, MD (PATHOLOGIST)

47, Harsh Vihar, Pitampura, New Delhi-110034 | Ph.: 011-42480101, 9599913051

E-mail: oneplusul@gmail.com | Web.: www.oneplusul.in

Page 4 of 7



OnePLUS Ultrasound Lab

— QUALITY FIRST... ALWAYS! —

Dr. Nitin Agarwal

Pathologist & Director
Ex. Sr. Res. MAMC
& Lok Nayak Hospital
Ex. Chief of Lab Dr. Lal Path Labs.

Dr. Pooja (Garg) Agarwal

Radiologist & Director
MAMC & Lok Nayak Hospital



NAME	:Mr. AJAY DAHIYA	Barcode No	:10139840
AGE/GENDER	:31 YRS/Male	SPECIMEN DATE	:13/Mar/2023 09:13AM
PATIENT ID	:110588	SPECIMEN RECEIVED	:13/Mar/2023 09:25AM
REFERRED BY	:Dr. MEDIWHEEL	REPORT DATE	:13/Mar/2023 04:39PM
CENTRE NAME	:ONEPLUS ULTRASOUND LAB	LAB NO.	:012303130005

Test Name	Result	Unit	Ref. Range
-----------	--------	------	------------

Reference ranges - Interpretation of Diagnostic tests - (Jacques Wallach)

1. Primary hypothyroidism is accompanied by depressed serum T3 and T4 values and elevated serum TSH level.
2. Primary hyperthyroidism is accompanied by elevated serum T3 and T4 levels along with depressed TSH values.
3. Slightly elevated T3 levels may be found in pregnancy and estrogen therapy, while depressed levels may be encountered in severe illness, renal failure and during therapy with drugs like propranolol and propyl thiouracil.
4. Although elevated TSH levels are nearly always indicative of primary hypothyroidism, and may be seen in secondary thyrotoxicosis

Checked By.

Dr. NITIN AGARWAL
M B B S , MD (Path)
DMC/R/01436
DR. NITIN AGARWAL
MBBS,MD(PATHOLOGIST)

47, Harsh Vihar, Pitampura, New Delhi-110034 | Ph.: 011-42480101, 9599913051

E-mail: oneplusul@gmail.com | Web.: www.oneplusul.in

Page 5 of 7



OnePLUS Ultrasound Lab

— QUALITY FIRST... ALWAYS! —

Dr. Nitin Agarwal
Pathologist & Director
Ex. Sr. Res. MAMC
& Lok Nayak Hospital
Ex. Chief of Lab Dr. Lal Path Labs.

Dr. Pooja (Garg) Agarwal
Radiologist & Director
MAMC & Lok Nayak Hospital



NAME	:Mr. AJAY DAHIYA	Barcode No	:10139840
AGE/GENDER	:31 YRS/Male	SPECIMEN DATE	:13/Mar/2023 09:13AM
PATIENT ID	:110588	SPECIMEN RECEIVED	:13/Mar/2023 09:25AM
REFERRED BY	:Dr. MEDIWHEEL	REPORT DATE	:13/Mar/2023 03:06PM
CENTRE NAME	:ONEPLUS ULTRASOUND LAB	LAB NO.	:012303130005

Test Name	Result	Unit	Ref. Range
-----------	--------	------	------------

CLINICAL PATHOLOGY

URINE ROUTINE

Physical examination

Quantity	10		ML
Colour	PALE YELLOW		
Transparency	SLIGHTLY TURBID		CLEAR
Sp.gravity	1.020		1.010-1.030
pH	6.50		
Reaction	ACIDIC		ACIDIC

Chemical examination


Urine protein	NIL		NIL
Urine sugar	NIL		NIL
Bilirubin, urine	NEGATIVE		NEGATIVE
Urobilinogen	NORMAL		NORMAL
Ketones	NEGATIVE		NEGATIVE

Microscopic examination

Pus cells.	3-5	/HPF	0-2
Epithelial cells	1-2	/HPF	NIL
R.B.C.	NIL	/HPF	NIL
Casts	NIL	/HPF	NIL
Crystals	NIL	/HPF	NIL
Bacteria	NIL	/HPF	NIL
Others.	NIL	NIL	NIL

Checked By.

Dr NITIN AGARWAL
M B B S , MD (Psth)
DMC/R/01436


DR. NITIN AGARWAL
MBBS,MD(PATHOLOGIST)

47, Harsh Vihar, Pitampura, New Delhi-110034 | Ph.: 011-42480101, 9599913051

E-mail: oneplusul@gmail.com | Web.: www.oneplusul.in

Page 6 of 7



OnePLUS Ultrasound Lab

— QUALITY FIRST... ALWAYS! —

Dr. Nitin Agarwal

Pathologist & Director
Ex. Sr. Res. MAMC
& Lok Nayak Hospital
Ex. Chief of Lab Dr. Lal Path Labs.

Dr. Pooja (Garg) Agarwal

Radiologist & Director
MAMC & Lok Nayak Hospital



NAME	:Mr. AJAY DAHIYA	Barcode No	:10139840
AGE/GENDER	:31 YRS/Male	SPECIMEN DATE	:13/Mar/2023 09:13AM
PATIENT ID	:110588	SPECIMEN RECEIVED	:13/Mar/2023 03:20PM
REFERRED BY	:Dr. MEDIWHEEL	REPORT DATE	:13/Mar/2023 04:50PM
CENTRE NAME	:ONEPLUS ULTRASOUND LAB	LAB NO.	:012303130005

Test Name	Result	Unit	Ref. Range
-----------	--------	------	------------

CLINICAL PATHOLOGY

STOOL ROUTINE

Physical examination

Colour	BROWNISH		
Consistency	SEMI LOOSE		Semi Formed
Blood	ABSENT		Absent
Mucus	ABSENT		Absent

Chemical examination, stool

pH 6.00

Microscopic examination

Pus cells	0-1	/HPF	
R.B.C.	NIL	/HPF	NIL
Ova	NIL		NIL
Cysts	NIL		NIL
Bacteria	NIL	/HPF	NIL
Others	NIL		

*** End Of Report ***

Checked By.

Dr. NITIN AGARWAL
MBBS, MD (Path)
DMC/R/01438
DR. NITIN AGARWAL
MBBS, MD (PATHOLOGIST)

47, Harsh Vihar, Pitampura, New Delhi-110034 | Ph.: 011-42480101, 9599913051

E-mail: oneplusul@gmail.com | Web.: www.oneplusul.in

Page 7 of 7

Clinical correlation is essential for final diagnosis. • If test results are unsatisfactory please contact personally or on phone. • This report is for perusal of doctors only. • All disputes Subject to Delhi Jurisdiction only. • Not for medicolegal purposes. • All congenital anomalies in a foetus may not be diagnosed in routine obstetric ultrasound.

Name	: Mr. AJAY DAHIYA	Age/Sex	: 31 YRS/Male
Ref. By	: Dr. MEDIWHEEL	Lab No	: 012303130005
Date	: 13-Mar-2023	Patient ID	: LSHHI110588

X-ray-Chest PA view

Bony cage and soft tissues are normal.
Cardiothoracic ratio is normal.
Mediastinum is normal.
Both hila are normal.
Both costophrenic angles are clear.
Both domes of diaphragm are normal.
Lung fields are clear. No parenchymal lesion seen.

IMPRESSION: Normal Study.

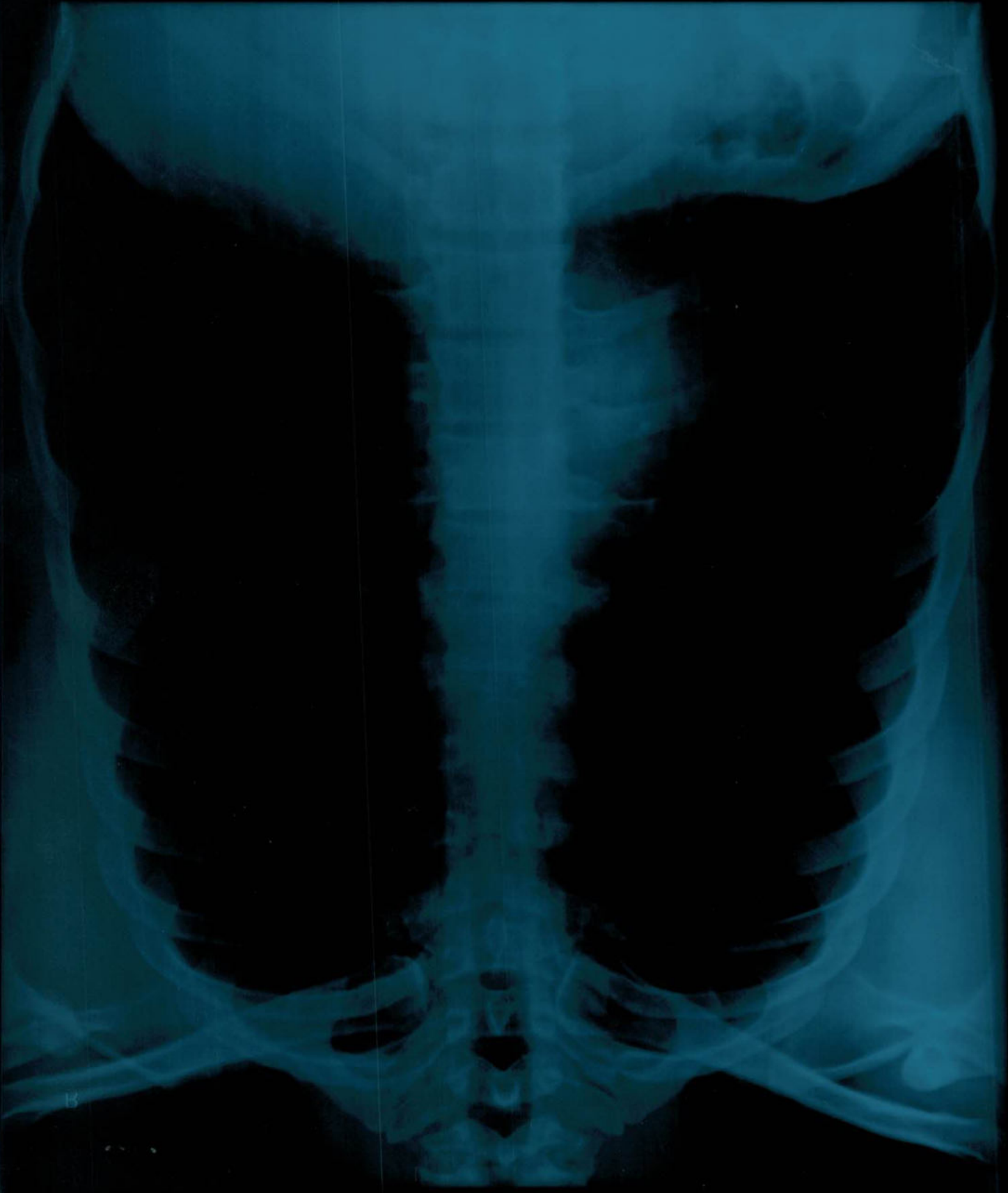Dr. POOJA GARG
M.B.B.S., D.M.F.
Reg No. DMC/R/03398
Radiologist



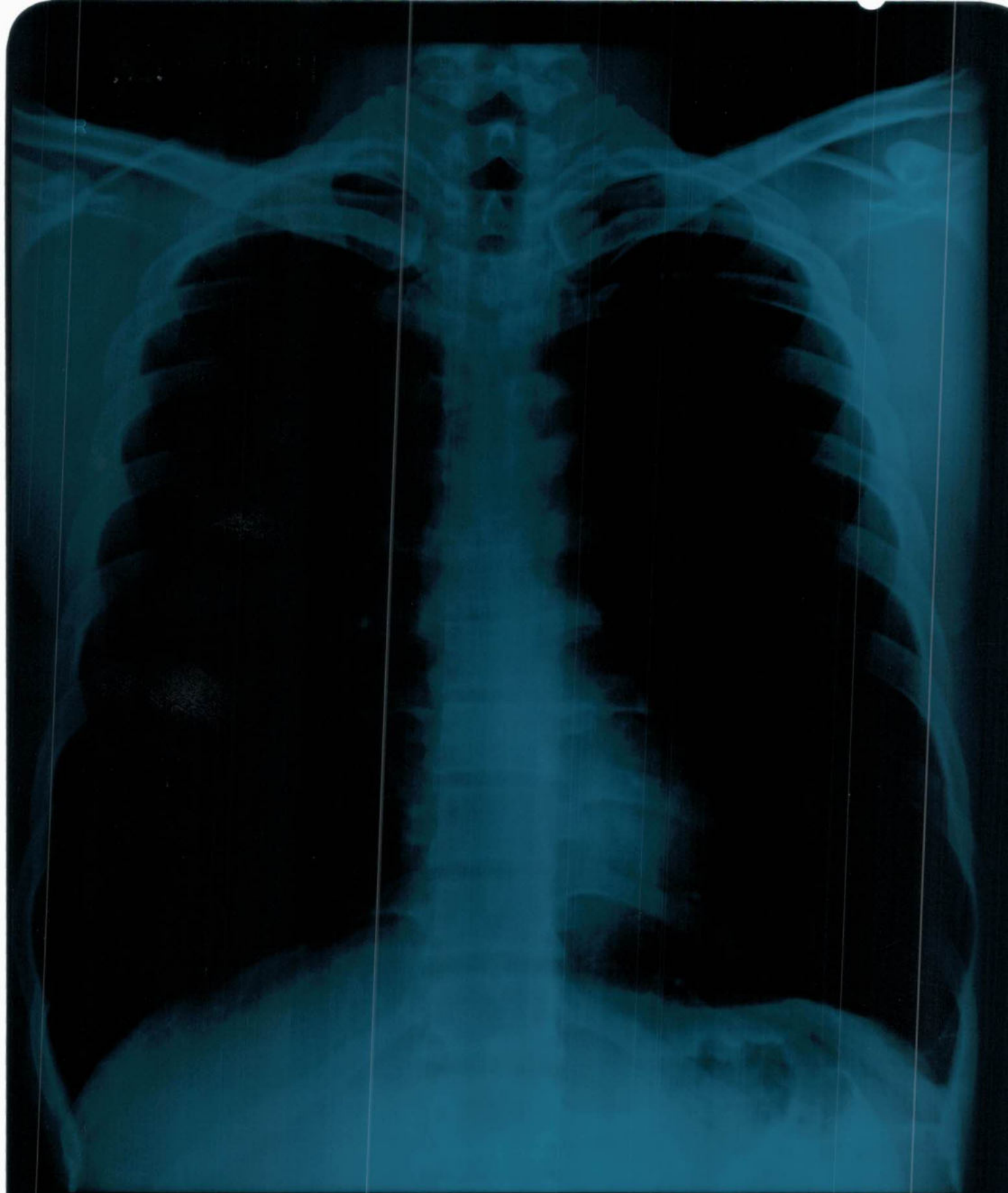
Type By : pooja

47, Harsh Vihar, Pitampura, New Delhi-110034 | Ph.: 011-42480101, 9599913051
E-mail: oneplusul@gmail.com | Web.: www.oneplusul.in

ОИЕБГУС ПГТРАСОИИД ГАВ.АТ-НАРСН ВИНАВ.ЫТАМЬУРА
МР. АЛАУ ДАНИА 31 УРС 13131033 M CHEST PA VIEW



13



MR. AJAY DAHIYA 31 YRS 13/3/2023 M CHEST PA VIEW
ONEPLUS ULTRASOUND LAB. 47-HARSH VIHAR, PITAMPURA