

# DHILLON NURSING HOME



#12-A, SHARDA NAGAR, NEAR SAI MANDIR, JALBERA ROAD, AMBALA CITY

Ph. : 0171-2535201, Mobile : 9728700272, 9992015279

E-mail: dhillonhosp11@gmail.com

**Dr. P. S. Dhillon**

M.B.B.S., M.S.  
Regd. No. HMC 13832

**Dr. (Mrs.) H. K. Dhillon**

M.B.B.S., M.D., PGD Sonography  
Regd. No. HMC 13869

Pt Name - Shubham Sharma 27 yo Male  
21/7/21

BP - 120/70 mmHg

PR - 80/min

SpO<sub>2</sub> - 98%

Cherub - NAD.

CVS - S<sub>1</sub>, S<sub>2</sub> ~~normal~~  
Newly

P/A - No any abnormality

USG/ECA/CXR - WNL

Eye Exam - O.K.

- Near vision normal  
- No color vision problem.

ENT - No Abnormalities detected

*(Signature)*  
Dr. P. S. Dhillon  
M.B.B.S., M.D. (Surgery)  
Regd. No. HMC 013832  
21/7/21

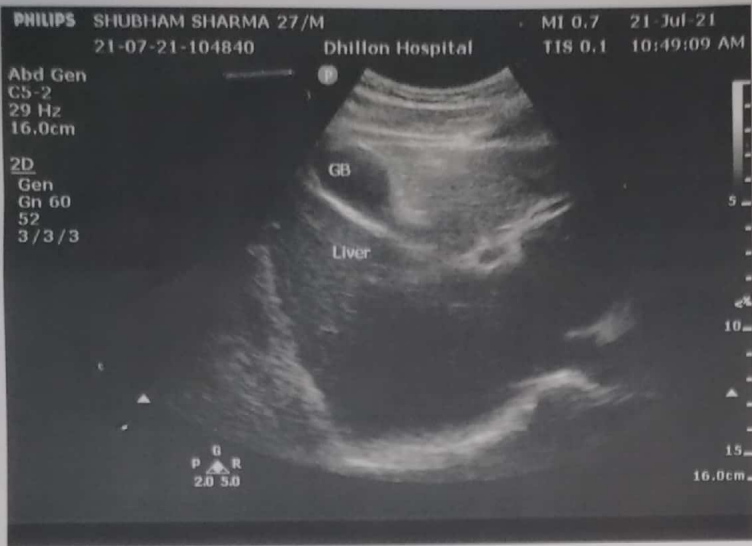#### OPD TIMINGS :

MORNING : 9:00 a.m. TO 1:30 p.m. EVENING : 5:30 p.m. TO 8:00 p.m.  
Sunday Evening by Appointment only

Facilities : Surgery (open and laproscopic), Delivery (Normal/Operative), Indoor Admission, Computerised Laboratory, ECG, X-ray, Ultrasound & Color Doppler

24 Hrs. Emergency Service Available

NOT VALID FOR MEDICO LEGAL PURPOSE



# SING HOME

NDIR, JALBERA ROAD, AMBALA CITY

728700272, 9992015279

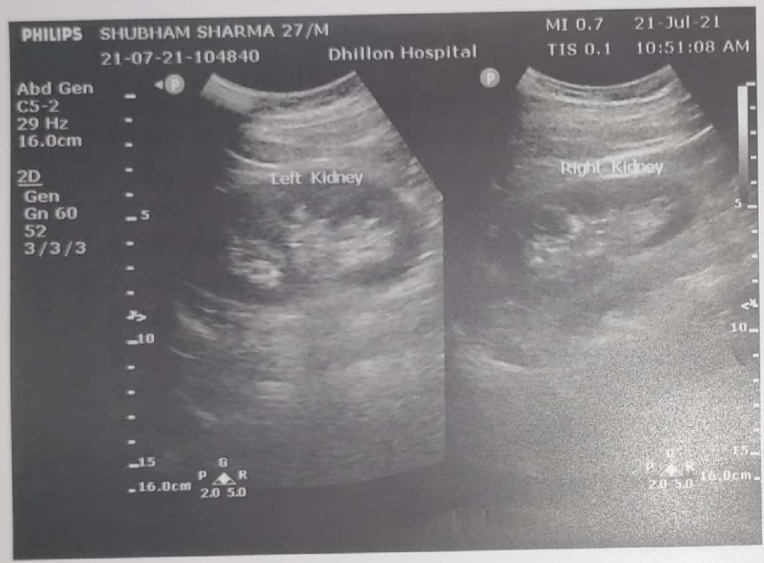1@gmail.com

*Dr. (Mrs.) H. K. Dhillon*

M.B.B.S., M.D., PGD Sonography  
Regd. No. HMC 13869

Age/Sex:27/M

Date:21.07.21



## FINDINGS

### ABDOMEN

...sion is seen. Intrahepatic biliary radicles are normal.

...ows seen. Gall bladder wall is normal in thickness. No

...al echogenic mass with distal acoustic shadowing seen.

...o focal lesion seen.

...en.

...n. Cortico medullary distinction is normal and well

...ystem is normal and shows no hydro nephrosis.

... Cortico medullary distinction is normal and well

...al and shows no hydronephrosis

...echogenic with distal acoustic shadowing is seen. Wall

...ape and echo texture.

S/O  
Right Renal Concretions

Adv. To correlate clinically.

*Dr. (Mrs.) H. K. Dhillon*  
M.B.B.S., M.D. (S&K), PGD Sonography  
**DR HARVINDER KAUR**  
MD, PGD (Sonography)

This report is not meant for Medico legal purpose and above mentioned findings are only Sonological findings and not the complete pathology. Please do correlate with Clinical Findings and other investigation report is for final diagnosis and management as any finding may be missed or over diagnosed due to Technical limitations of ultrasound examination.

### OPD TIMINGS :

MORNING : 9:00 a.m. TO 1:30 p.m. EVENING : 5:30 p.m. TO 8:00 p.m.  
Sunday Evening by Appointment only



# DHILLON NURSING HOME



316.21

#12-A, SHARDA NAGAR, NEAR SAI MANDIR, JALBERA ROAD, AMBALA CITY

Ph. : 0171-2535201, Mobile : 9728700272, 9992015279

E-mail: dhillonhosp11@gmail.com

**Dr. P. S. Dhillon**

M.B.B.S., M.S.  
Regd. No. HMC 13832

**Dr. (Mrs.) H. K. Dhillon**

M.B.B.S., M.D., PGD Sonography  
Regd. No. HMC 13869

Patient Name: Shubum Sharma

Age/Sex: 27/M

Date: 21.07.21

## SONOLOGICAL FINDINGS

### USG WHOLE ABDOMEN

**LIVER** : Liver is normal in size and echotecture. No focal lesion is seen. Intrahepatic biliary radicles are normal. Portal vein and hepatic veins are normal.

**GALL BLADDER** : is normally distended. No echogenic shadows seen. Gall bladder wall is normal in thickness. No pericholecystic collection seen.

**COMMON BILE DUCT**: Normal in diameter. No intraluminal echogenic mass with distal acoustic shadowing seen.

**PANCREAS**: Normal in size and has normal echo pattern. No focal lesion seen.

**SPLEEN**: Normal in size and echo pattern. No focal lesion seen.

**RIGHT KIDNEY**: Normal in size, site, outline and echo pattern. Cortico medullary distinction is normal and well maintained. **Contains few small concretions.** Pelvicalyceal system is normal and shows no hydro nephrosis.

**LEFT KIDNEY**: Normal in size, site, outline and echo pattern. Cortico medullary distinction is normal and well maintained. No calculus seen. Pelvicalyceal system is normal and shows no hydronephrosis

**URINARY BLADDER**: Normal in distension. No intraluminal echogenic with distal acoustic shadowing is seen. Wall thickness is normal.


**PROSTATE AND SEMINAL VESICLES**: Normal in size and shape and echo texture.

### IMPRESSION:

s/o

Right Renal Concretions

Adv. To correlate clinically.

  
DR. (Mrs.) H. K. Dhillon  
M.B.B.S., M.D., PGD Sonography  
Regd. No. HMC 13869  
**DR HARVINDER KAUR**  
MD, PGD (Sonography)

This report is not meant for Medico legal purpose and above mentioned findings are only Sonological findings and not the complete pathology. Please do correlate with Clinical Findings and other investigation report is for final diagnosis and management as any finding may be missed or over diagnosed due to Technical limitations of ultrasound examination.

### OPD TIMINGS :

MORNING : 9:00 a.m. TO 1:30 p.m.      EVENING : 5:30 p.m. TO 8:00 p.m.  
Sunday Evening by Appointment only

Facilities : Surgery (open and laproscopic), Delivery (Normal/Operative), Indoor Admission, Computerised Laboratory, ECG, X-ray, Ultrasound & Color Doppler

24 Hrs. Emergency Service Available

NOT VALID FOR MEDICO LEGAL PURPOSE

# DHILLON NURSING HOME



#12-A, Sharda Nagar, Near Sai Mandir, Jalbera Road, Ambala City. (Haryana)

Ph.: 0171-2535201, Mobile : 9728700272

E-mail : dhillonhosp11@gmail.com | dhillonhospital21@gmail.com

Patient Name: Mr. shubham sharma      Age / Sex: 27 YRS / M  
Referred By: Mediwheel      Date: 21/07/2021  
Reg. no. 110001  
Collected on: 21/07/2021      Reported on: 21/07/2021 02:45 PM



## HAEMATOTOLOGY

TEST	VALUE	UNIT	REFERENCE
Hemoglobin	13.8	g/dl	13 - 17
Total Leukocyte Count	8,400	cumm	4,000 - 11,000
Differential Leucocyte Count			
Neutrophils	61	%	40 - 80
Lymphocyte	33	%	20 - 40
Eosinophils	03	%	1 - 6
Monocytes	03	%	2 - 10
Basophils	00	%	< 2
Erythrocyte Sedimentation Rate (Wintrobe)	09	mm for 1st hour	0 - 9
Blood Group & Rh.			
ABO	O		
Rh (ANTI -D)	POSITIVE		

## BIOCHEMISTRY

### LIVER FUNCTION TEST (LFT)

TEST	VALUE	UNIT	REFERENCE
Serum Bilirubin (Total)	0.51	mg/dl	0.2 - 1.2
Serum Bilirubin (Direct)	0.23	mg/dl	0 - 0.3
Serum Bilirubin (Indirect)	0.28	mg/dl	0.2 - 1
SGPT (ALT)	30.06	U/l	13 - 40
SGOT (AST)	23.96	U/l	0 - 37
Serum Alkaline Phosphatase	87.83	U/l	
Serum Protein	7.28	g/dl	6.4 - 8.3
Serum Albumin	4.51	g/dl	3.5 - 5.2
Globulin	2.77	g/dl	1.8 - 3.6
A/G Ratio	1.63		1.1 - 2.1

Mr. Kulwinder Singh  
DMLT, Lab Incharge

Dr. H. K. Dhillon  
MBBS, MD Pathologist




# DHILLON NURSING HOME

#12-A, Sharda Nagar, Near Sai Mandir, Jalbera Road, Ambala City. (Haryana)



Ph.: 0171-2535201, Mobile : 9728700272

E-mail : dhillonhosp11@gmail.com | dhillonhospital21@gmail.com

Patient Name:	Mr. shubham sharma	Age / Sex:	27 YRS / M	 110001
Referred By:	Mediwheel	Date:	21/07/2021	
Reg. no.	110001	Reported on:	21/07/2021 02:45 PM	
Collected on:	21/07/2021			

## KIDNEY FUNCTION TEST (KFT)

TEST	VALUE	UNIT	REFERENCE
BUN	10.17	mg/dl	7.9 - 20
Serum Urea	21.78	mg/dl	19 - 45
Serum Creatinine	0.95	mg/dl	0.6 - 1.1
Serum Uric Acid	4.85	mg/dl	3.5 - 7.2
Urea / Creatinine Ratio	22.93		
BUN / Creatinine Ratio	10.71		

TEST	VALUE	UNIT	REFERENCE
Fasting Blood Sugar	94.08	mg/dl	70 - 110
Blood Sugar PP	121.86	mg/dl	70 - 140
HbA1c	5.5	%	
HbA1c	111.15	mg/dL	
Estimated average glucose			

Below 6.0% - Normal Value  
 6.0% - 7.0% - Good Control  
 7.0% - 8.0% - Fair Control  
 8.0% - 10% - Unsatisfactory Control  
 Above 10% - Poor Control

Gamma Glutamyl Transferase, GGT

24.71

IU/L

9 - 52

GGT is an enzyme present in liver, kidney, and pancreas. It is induced by alcohol intake and is a sensitive indicator of liver disease, particularly alcoholic liver disease.

### Clinical utility -

Follow-up of alcoholics undergoing treatment since the test is sensitive to modest alcohol intake - confirmation of hepatic origin of elevated serum alkaline phosphatase.  
 Increased in liver disease, acute viral or toxic hepatitis, chronic or subacute hepatitis, alcoholic hepatitis, cirrhosis, biliary tract obstruction (Intrahepatic or Extrahepatic), primary or metastatic liver neoplasm, and mononucleosis - Drugs (by enzymeinduction): phenytoin, carbamazepine, Barbiturates, alcohol.

## CLINICAL PATHOLOGY

Mr. Kulwinder Singh  
DMLT, Lab Incharge

Dr. H. K. Dhillon  
MBBS, MD Pathologist  
PGD Sonography  
Reg. No. 013859

# DHILLON NURSING HOME




#12-A, Sharda Nagar, Near Sai Mandir, Jalbera Road, Ambala City. (Haryana)

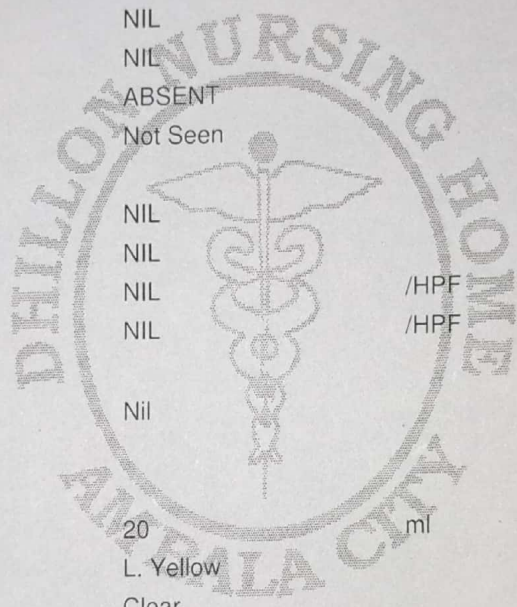
Ph.: 0171-2535201, Mobile : 9728700272


E-mail : dhillonhosp11@gmail.com | dhillonhospital21@gmail.com


Patient Name:	Mr. shubham sharma	Age / Sex:	27 YRS / M
Referred By:	Mediwheel	Date:	21/07/2021
Reg. no.	110001	Reported on:	21/07/2021 02:45 PM
Collected on:	21/07/2021		



TEST	VALUE	UNIT	REFERENCE
Urine Sugar Fasting	Nil		
Stool Routine Examination			
Macroscopic			
Colour	Yellow		
Consistency			
Mucus	NIL		
Blood	NIL		
Occult Blood	ABSENT		
Parasites	Not Seen		
Microscopic			
OVA	NIL		
Cysts	NIL		
Pus Cells	NIL	/HPF	
Red Blood Cells	NIL	/HPF	
Macrophages			
Urine Sugar PP	Nil		
Urine Routine Examination			
Physical Examination			
Quantity	20	ml	
Colour	L. Yellow		Pale Yellow
Transparency	Clear		Clear
Specific Gravity			1.005 - 1.03
pH	6.0		5 - 7
Chemical Examination			
Protein / Albumin	Absent		Absent
Sugar / Glucose	Absent		Absent
Microscopic Examination			
R.B.C.	Absent	/HPF	Absent
Pus Cells	0-1	/HPF	Absent
Epithelial Cells	Absent	/HPF	Absent
Casts	Absent		Absent
Crystals	Absent		
Bacteria	Absent		Absent



  
 Mr. Kulwinder Singh  
 DMLT, Lab Incharge

  
 Dr. H. K. Dhillon  
 MBBS, MD Pathologist  
 Dr. (Mrs.) H. K. Dhillon  
 MBBS, MD (Path), PGD, Sonography  
 Regd. No. HMC 013869



# DHILLON NURSING HOME



#12-A, Sharda Nagar, Near Sai Mandir, Jalbera Road, Ambala City. (Haryana)

Ph.: 0171-2535201, Mobile : 9728700272

E-mail : dhillonhosp11@gmail.com | dhillonhospital21@gmail.com

Patient Name: Mr. shubham sharma      Age / Sex: 27 YRS / M  
Referred By: Mediwheel      Date: 21/07/2021  
Reg. no. 110001  
Collected on: 21/07/2021      Reported on: 21/07/2021 02:45 PM




110001

## ENDOCRINOLOGY

TEST	VALUE	UNIT	REFERENCE
Serum Triiodothyronine, T3	H 118	ng/mL	0.69 - 2.15
Serum thyroxine, T4	L 10.8	ng/mL	52 - 127
Thyroid-Stimulating Hormone, TSH	2.27	μIU/mL	0.3 - 4.5

--- End of report ---



Mr. Kulwinder Singh  
DMLT, Lab Incharge

Dr. H.K. Dhillon  
MBBS, MD Pathologist  
Regd. No. HMC/...

R  
PA

L

MR.SHUBHAM SHARMA/27YRS 00223 M CHEST PA 21/07/2021 23:07:32  
DHILLON NURSING HOME, JALBERA ROAD, AMBALA CITY

.....





DHILLON MULTI HOSP

JALSERA ROAD,  
ANBAI CITY  
01712535201

Name : SUBHAM SHARMA  
Age : 27 Years  
Gender : MALE  
BP :  
(mm/Hg)  
Weight : Kgs  
Date : 21/07/21  
Note :  
VESTA 3016  
(Ver 3.8.12)  
www.zmsindia.com

