

DAKSH HOSPITAL

396 - 397, Gandhi Nagar, Scheme No. 8, ALWAR -301001

Ref. No.

Date.....

MEDICAL EXAMINATION REPORT

Mediwheel (BOB)

Name: Mr Manish Kumar

Age: 40 yrs Sex: Male

Date: 08/04/2023

General Physical Examination

Height	: 169 cm	Weight	73 kg
Pulse	: 90/min	BP	120/86
Temp.	: AF	Respiration	14/min
BMI	: 25.6		

Systemic Exam:-

(NAD) NORMAL

Dental Check up :-

NORMAL

Eye check-up :-

NORMAL

Skin Check up:-

NORMAL

ENT Check up:-

NORMAL, ↓ HEARING LOCAL

Gynae Check up:-

N/A

Impression:-Lr Ear Reduced Hearing
Back pain.Recommendation:-

- ENT Surgery
- Orthopaedic Opine
- XRAY R spine & AP
Lr ear

Dr. Mukesh Kumar Gupta

MD Gen. Medicine

Reg. No 5423/16262

डॉ० मुकेश गुप्ता

M.D. F.C.C.S.

फिजिशियन एवं मधुमेह रोग विशेषज्ञ

दक्ष हॉस्पिटल, अलवर

रजि. नं. 5423/16262

Results

Run Date 08/04/2023 11:01:59 AM

Operator DAKSH

Last Name

Sample ID 2

First Name MR KUMAR MANISH

Department

Gender Male

Age

Physician DR. MUKESH GUPTA M.D

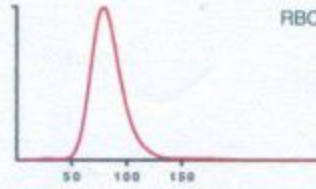
Patient ID AUTO_PID12895

Type Man

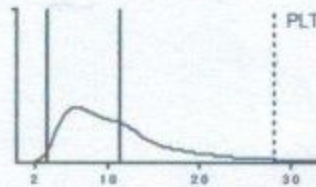
Date of birth

Sample comments

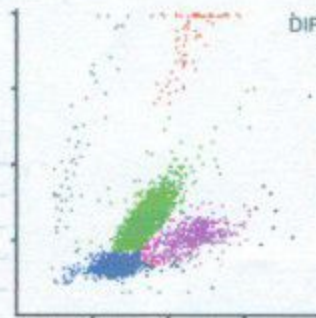
				Range
RBC	5.39	*	10 ⁹ /μL	3.80 - 5.50
HGB	14.7		g/dL	13.0 - 17.0
HCT	47.6	*	%	39.0 - 52.0
MCV	88.4	*	μm ³	76.0 - 100.0
MCH	27.3		pg	26.0 - 34.0
MCHC	30.8	L	g/dL	32.0 - 35.0
RDW-CV	16.6	h	%	11.0 - 16.0
RDW-SD	54.2	h	μm ³	37.0 - 49.0



				Range
PLT	251		10 ³ /μL	150 - 450
PCT	0.26		%	0.15 - 0.40
MPV	10.5		μm ³	8.0 - 11.0
PDW	18.0		μm ³	11.0 - 22.0
P-LCC	91		10 ³ /μL	44 - 140
P-LCR	36.3		%	18.0 - 50.0



				Range
WBC	6.84		10 ³ /μL	3.50 - 10.00
	#		Range	%
NEU	3.71		1.60 - 7.00	54.7
LYM	2.58		1.00 - 3.00	37.9
MON	0.24		0.20 - 0.80	3.5
EOS	0.16		0.00 - 0.50	2.3
BAS	0.11		0.00 - 0.15	1.6 h
LIC	0.04		0.00 - 0.10	0.5



डॉ० मुकेश गुप्ता

M.D. F.C.C.S.

फिजिशियन एवं मधुमेह रोग विशेषज्ञ

दक्ष हॉस्पिटल अलवर

08/04/2023 11:01:59 AM

Doctor

Printed by : DAKSH

S/N107Y0XH04 **TECHNOLOGIST**

All investigation have their own limitations regarding the sensitivity & specificity of individual assay procedures, Isolated laboratory investigations never confirm the final diagnosis of the disease. They only help in arriving at a diagnosis in conjunction with clinical presentation and other related investigations. Report is not valid for medico-legal purpose subject to ALWAR jurisdiction only.



दक्ष हॉस्पिटल

396, गाँधी नगर स्कीम नं.8, अलवर (राज०) ☎ 0144-2703340

Sonography / 2D Echo Cardiography / Doppler Report

Name: MR. MANISH KUMAR /M/40 YRS
Refd. By- DR.MUKESH GUPTA MD

Date: 8-Apr-23

U.S.G. OF ABDOMEN & PELVIS

LIVER

Liver is normal in size shape with normal echo-texture. Intra hepatic biliary radicals are not dilated.
No evidence of focal or diffuse lesion.

GALL BLADDER

Gall bladder is normal dilated. Lumen clear. Wall thickness normal. CBD normal

PANCREAS

Pancreas is normal in size, shape & echo-texture.

SPLEEN

Normal in size with normal shape & echo- texture.

BOTH KIDNEY

Right kidney has 4 mm upper pole stone without hydronephrosis.
Left kidney is normal.

PROSTATE & URINARY BLADDER is normal shape, size & echo texture..

Advice- X Ray KUB / URINE EXAM

Please correlate clinically. USG accuracy is 95 % due to technical limitations as well as inaccuracies inherent in the laboratory and statistical analysis biological process.

This report is not valid for medico-legal cases.

DR. MUKESH GUPTA
SONOLOGIST

Dr. Mukesh Kumar Gupta
Physician & Sonologist
RM 5423/16262



"भ्रूण लिंग परीक्षण की शिकायत
104 टोल फ्री सेवा पर भी की
जा सकती है"

भ्रूण लिंग परीक्षण की शिकायत 104 टोल फ्री सेवा पर भी की जा सकती है।



दक्ष हॉस्पिटल

396, गाँधी नगर स्कीम नं.8, अलवर (राज०) ☎ 0144-2703340

Sonography / 2D Echo Cardiography / Doppler Report

2D/ ECHO REPORT

Name: - Mr. Manish

Age: - 40 Yrs

Date: - 8-Apr-23

Reg. No.: - Alw/2009/04
BOB health checkup

PROCEDURES:

M-MODE/2D/DOPPLER/COLOR/CONTRAST B.A.S. M²

MEASUREMENT:		DOPPLER:	
AOD	21	NORMAL	NORMAL (cm/sec.)
LA	20	(20- 37mm)	MV 0.54 (0.8- 1.3) MR No
AVO	15	(19- 40mm)	AV 1.3 (1.2- 1.8) AR No
RVDd.	11	(12- 25mm)	TV 0.6 (0.3- 0.8) TR No
		(03- 09mm)	PV 0.8 (0.7- 1.1) PR No
LV Dd	48	(37- 56mm)	MITRAL VALVE-
LV Ds	23	(22- 40mm)	AML Normal
IVS d	11	(06- 12mm)	PML Normal
IVS s	9		
PWd	6	(05- 10mm)	AORTIC VALVE Normal
LV FUNCTION		TV & PV are normal.	
M- E- S Separation	<0.9cm		
Minor	24.42%		
LV Ejection Fraction	70%	65 +/- 12%	

LV WALL MOTION: NO RWMA
ALL CARDIAC CHAMBERS ARE NORMAL
ALL VALVES ARE NORMAL
NO CLOT, VEGETATION, PERICARDIAL EFFUSION

FINAL DIAGNOSIS: NORMAL STUDY

Adv: - Follow up/ review at higher center for confirmation

Note:- Please Correlate clinically. Due to technical limitations as well as inaccuracies inherent in the laboratory and statistical analysis of biological process. Diagnostic accuracy of ECHO is up to 95% only.
Report is not valid for medico-legal purpose.


Dr. Mukesh Kumar Gupta
Physician & Sonologist
RM 5423/16262



"भ्रूण लिंग परीक्षण की शिकायत
104 टोल फ्री सेवा पर भी की
जा सकती है।"

जा सकती है।

ID: 583

08-04-2023 13:07:01

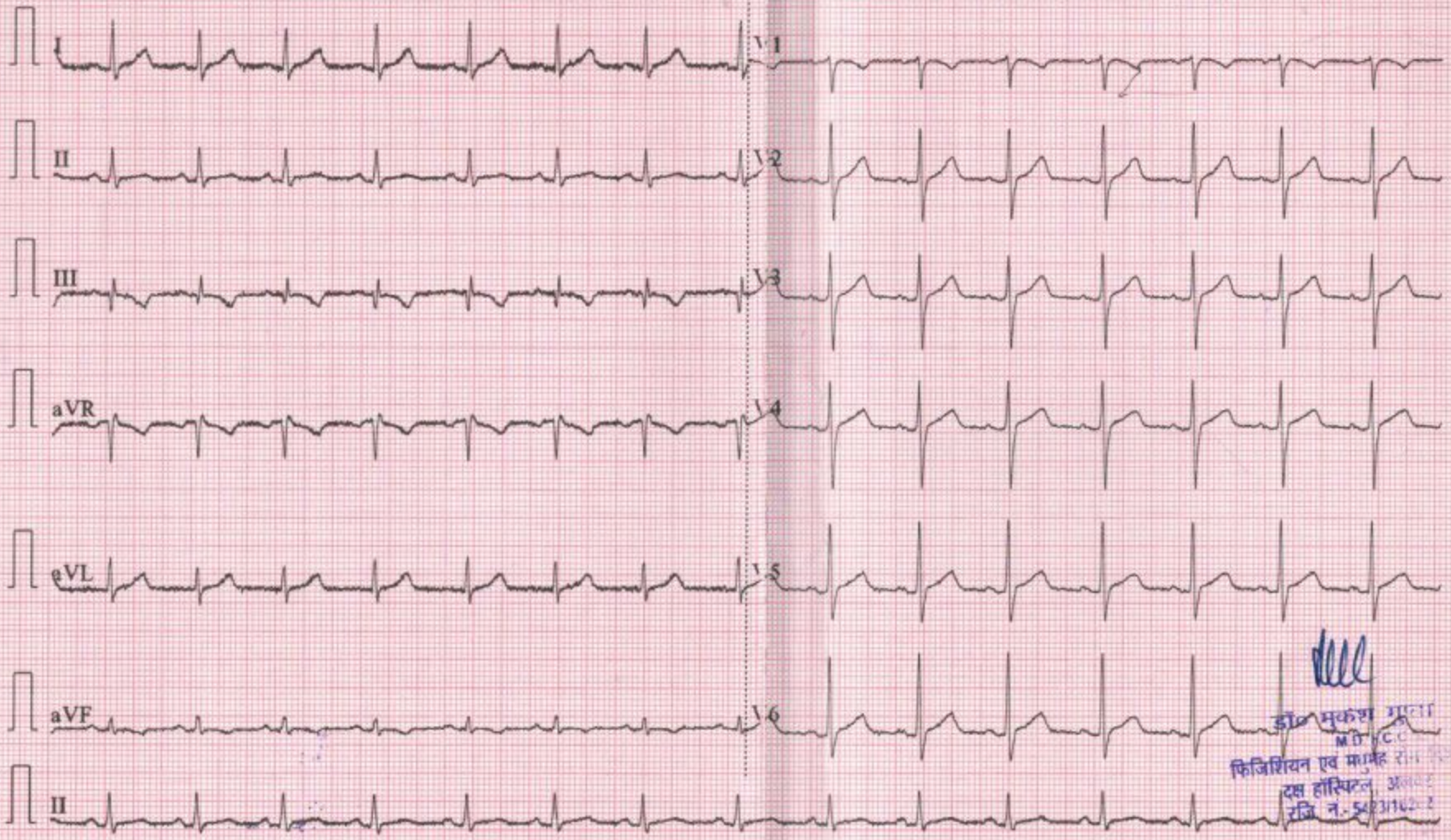
male Years
Req. No. :

HR : 92 bpm
P : 100 ms
PR : 146 ms
QRS : 86 ms
QT/QTcBz : 348/431 ms
P/QRS/T : 53/25/-9 °
RV5/SV1 : 1.244/0.518 mV

Diagnosis Information:

Sinus rhythm
Lateral ST elevation - possible early repolarization
Inferior T wave abnormality is borderline for age and gender
Borderline ECG

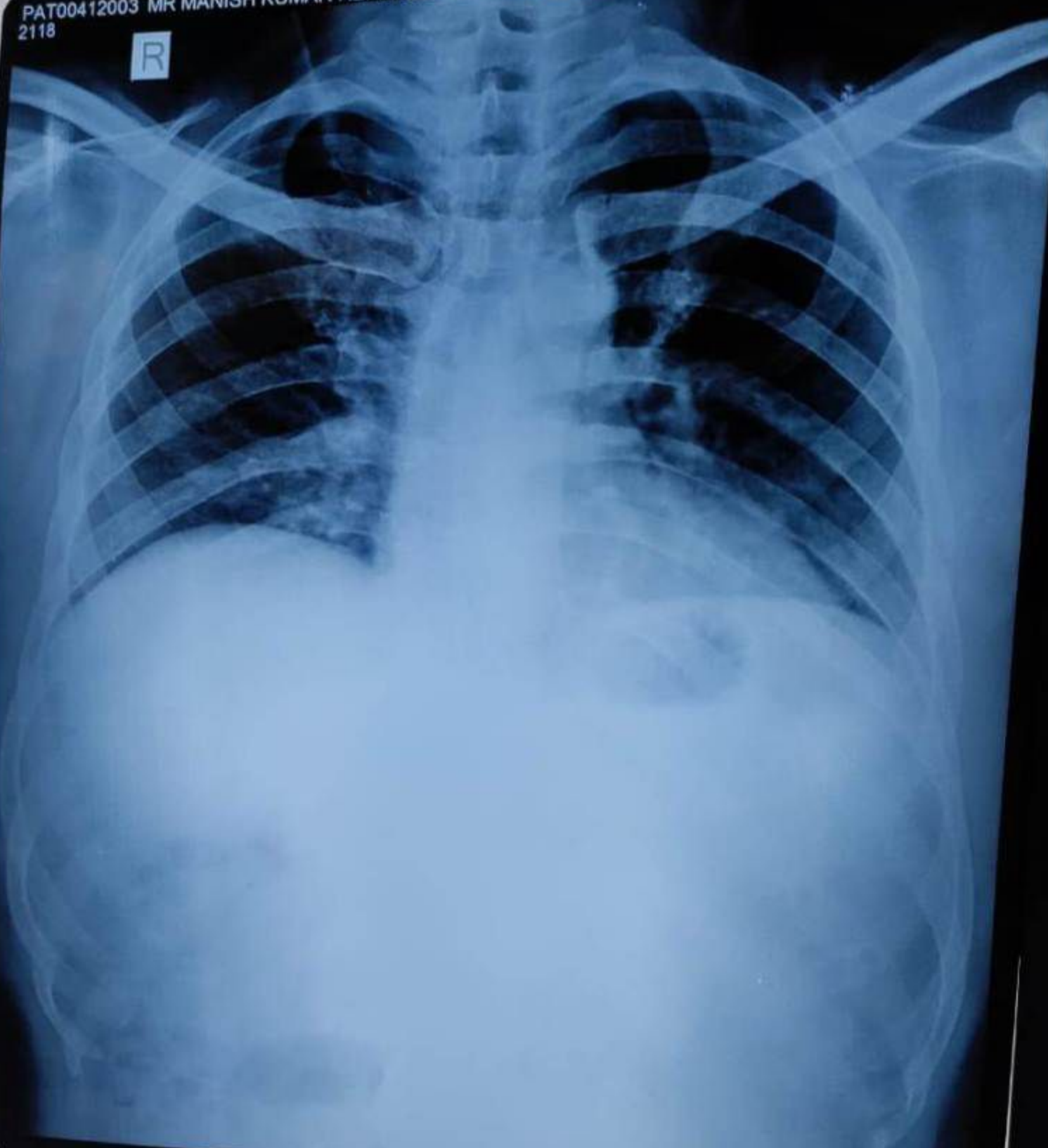
Report Confirmed by:



[Signature]
डॉ. मुकेश गुप्ता
MD, FCC
फिजिशियन एवं माइनेर रोग विशेषज्ञ
दस हॉस्पिटल, अलवर
रजि. नं. 5423102-2

PAT00412003 MR MANISH KUMAR REFD BY DR MUKESH GUPTA MD CHEST 08.04.2023
2118

R



VIJAY DIAGNOSTIC CENTRE 1/16 KALA KUAN, ALWAR

2118