



भारतीय विशिष्ट पहचान प्राधिकरण

Unique Identification Authority of India



पता:

आत्मजा: ओम प्रकाश गुप्ता, साहिद संजय मार्ग बिहीया,  
बेहेया, भोजपुर,  
बिहार - 802152


Address:

D/O: Om Prakash Gupta, sahid sanjay marg  
bihiya, Behea, Bhojpur,  
Bihar - 802152



6366 8571 8869

VID : 9139 4980 6484 9794



1947



help@uidai.gov.in



www.uidai.gov.in



भारत सरकार

Government of India



सरिता कुमारी गुप्ता

Sarita Kumari Gupta

जन्म तिथि/DOB: 19/11/1998

महिला/ FEMALE

6366 8571 8869

VID : 9139 4980 6484 9794

मेरा **आधार**, मेरी पहचान

**Facilities:**

All clinical Biomedical & Hematology Investigations  
including Bone Marrow Examination  
VPT, Podiascan & Complete Foot Care (First Time in Purvanchal)  
All Hormonal Investigation by Chemiluminescent Method  
Visceral Fat by (AB-140) Ambulatory BP Monitoring  
CGMS & Insulin Pump Available  
PFT, 2D-ECHO (Color Doppler), Holter, TMT, Cardiac-3 available  
VIA, VILI, Colposcopy available  
Special Endocrinological Investigation Protocols.

ISO 9001:2008 Certified  
Mobile: 9389994334, 9554572190, 9453837595



# Panacea Pathology

## Clinical Reference Lab

Persistence, Preparedness and Precision  
EQAS (CMC Vellore Attached) & IQAS System  
पूर्वांचल की सर्वोत्तम गुणवत्ता वाली पैथोलॉजी

PATIENT NAME : SARITA

AGE/GENDER : 24YRS/FEMALE

REFD BY DR. : ARCO FEMI HEALTHCARE LTD.

RECEIVED DATE : 25-02-2023(09:30AM)

SAMPLE : BLOOD & URINE

REPORT DATE : 25-02-2023(07:00PM)

## PATHOLOGY REPORT

### COMPLETE BLOOD COUNT (CBC)

TEST	LAB TEST VALUES	NORMAL RANGE
<b>HEMOGRAM</b>		
HEMOGLOBIN (FLOW CYTOMETRY)	12.1	13 – 16 gm/dl
TOTAL LEUCOCYTE COUNT (TLC)	7,400	4000 – 11000
RBC COUNT	4.39	3.5 – 5.5
PCV (HCT)	39.1	37 – 47
MCV	89.2	80 – 95
MCH	27.5	28 – 34
MCHC	30.3	30 – 36
PLATELET COUNT	1,49,000	1,50,000 – 4,00,000
E.S.R. (WINTROBE FIRST HOURS)	12.0	20 mm/1 <sup>st</sup> hr
<b>DIFFERENTIAL LEUCOCYTE</b>		
NEUTROPHILS	53	40 – 75%
LYMPHOCYTES	41	20 – 45%
EOSINOPHILS	03	1 – 6%
MONOCYTES	03	2 – 8%
BASOPHILS	00	< 2 %

### RENAL & KIDNEY PROFILE, SERUM

TEST	LAB TEST VALUES	NORMAL RANGE
<b>RENAL FUNCTION TESTS</b>		
BLOOD UREA NITROGEN (BUN)	10.2	10 – 50 mg/dl
SERUM CREATININE	0.75	0.60 – 1.60 mg/dl
URIC ACID	3.92	3.60 – 7.70 mg/dl
ALKALINE PHOSPHATASE (ALP)	71.6	142 – 353 mg/dl
TOTAL PROTIENS	7.25	0 – 39 mg/dl
ALBUMIN	4.13	3.8 – 5.4 mg/dl
SERUM GLOBULIN	3.12	2.1 – 3.5 mg/dl
CALCIUM	9.0	8.80 – 10.20
PHOSPHORUS	3.04	2.50 – 5.00
SERUM SODIUM NA+	1.005	135.00 – 155.00 mEq/Ltr
SERUM POTASIUUM K+	4.12	3.60 – 5.50 mEq/Ltr
ICALCIUM	1.22	1.10 – 1.35 mmol/L
SERUM CHLORIDE CL+	101.3	98.00 – 110.00 mEq/Ltr

PAGE 1

Lab Technician

PANACEA HOSPITAL  
(A UNIT OF ARCO FEMI HEALTH CARE PVT. LTD.)  
REG. NO.: AL-1500  
B.36/44 B-4 KABIR NAGAR  
DURGAKUND, VARANASI  
M.D. Pathology

Timing : 8.00 a.m. to 9.00 p.m. (Sunday 8.00 a.m. to 3.00 p.m.)

This Report is not valid for medico legal purpose

**Note:** These tests have technical limitations. Clinico-pathological interpretation is necessary. In case of any disparity test may be repeated immediately.

Address : 36/44 FK Kabir Nagar, Durgakund, Varanasi – 221005

Email: [dramishra@gmail.com](mailto:dramishra@gmail.com), [drpallaviojha@gmail.com](mailto:drpallaviojha@gmail.com) Website: [panaceahospital.org](http://panaceahospital.org)

**Facilities:**

All clinical Biomedical & Hematology Investigations including Bone Marrow Examination  
VPT, Podiascan & Complete Foot Care (First Time in Purvanchal)  
All Hormonal Investigation by Chemiluminescent Method  
Visceral Fat by (AB-140) Ambulatory BP Monitoring  
CGMS & Insulin Pump Available  
PFT, 2D-ECHO (Color Doppler), Holter, TMT, Cardiac-3 available  
VIA, VILI, Colposcopy available  
Special Endocrinological Investigation Protocols.

ISO 9001:2008 Certified  
Mobile: 9389994334, 9554572190, 9453837595



# Panacea Pathology

## Clinical Reference Lab

Persistence, Preparedness and Precision  
EQAS (CMC Vellore Attached) & IQAS System  
पूर्वाचल की सर्वोत्तम गुणवत्ता वाली पैथोलॉजी

PATIENT NAME : SARITA

AGE/GENDER : 24YRS/FEMALE

REFD BY DR. : ARCO FEMI HEALTHCARE LTD.

RECEIVED DATE : 25-02-2023(09:30AM)

SAMPLE : BLOOD & URINE

REPORT DATE : 25-02-2023(07:00PM)

### PATHOLOGY REPORT

#### LIPID PROFILE, SERUM

TEST	LAB TEST VALUES	NORMAL RANGE
<b>BLOOD CHEMISTRY</b>		
TOTAL CHOLESTEROL (SERUM)	141.0	Desirable:- &lt; 200 mg/dl Borderline:- 200 – 239 mg/dl High:- & gt; 240 mg/dl
TRIGLYCERIDES (SERUM)	138.0	35 – 170 mg/dl
HDL CHOLESTEROL (SERUM)	34.0	35.30 – 79.50 mg/dl
LDL CHOLESTEROL (SERUM)	79.4	& lt; 130 mg/dl
VLDL	27.6	& lt; 40 mg/dl
CHOLESTROL/HDL RATIO	4.14	& lt; 3.0 Low Risk Ratio 3.0 – 5.0 Avg Risk & lt; 5.0 High Risk
LDL/HDL RATIO	0.43	& lt; 3 Ratio

#### BLOOD GROUP

TEST	LAB TEST VALUES
<b>BLOOD GROUP ABO &amp; RH FACTOR</b>	
BLOOD GROUP	"A"
RH FACTOR	POSITIVE

#### GLYCOSYLATED HEMOGLOBIN (HBA1C)

TEST	LAB TEST VALUES	NORMAL RANGE
HBA1C	5.1	Normal : <5.97 % Good Control : 5.97 – 6.81% Fair Control : 6.81 – 7.65% Poor Control : >7.65%

#### THYROID PROFILE (T3, T4, TSH)

TEST	LAB TEST VALUES	NORMAL RANGE
<b>THYROID FUNCTION TEST</b>		
T3	1.02	0.60 – 1.81 ng/ml
T4	8.10	4.50 – 10.90 ug/dl
TSH	3.11	0.39 – 6.10 uIU/mL

PAGE 2

Lab Technician

PANACEA HOSPITAL  
(A UNIT OF AAROH HEALTHCARE PVT. LTD.)  
REGD. NO. AL-1500  
B.36/44 B4, KABIR NAGAR  
DURGAKUND, VARANASI  
M.D. Pathology

Timing : 8.00 a.m. to 9.00 p.m. (Sunday 8.00 a.m. to 3.00 p.m.)

This Report is not valid for medico legal purpose

**Note:** These tests have technical limitations. Clinico-pathological interpretation is necessary. In case of any disparity test may be repeated immediately.

Address : 36/44 FK Kabir Nagar, Durgakund, Varanasi – 221005

Email: [dramishra@gmail.com](mailto:dramishra@gmail.com), [drpallaviojha@gmail.com](mailto:drpallaviojha@gmail.com) Website: [panaceahospital.org](http://panaceahospital.org)

**Facilities:**  
 All clinical Biomedical & Hematology Investigations  
 including Bone Marrow Examination  
 VPT, Podiascan & Complete Foot Care (First Time in Purvanchal)  
 All Hormonal Investigation by Chemiluminescent Method  
 Visceral Fat by (AB-140) Ambulatory BP Monitoring  
 CGMS & Insulin Pump Available  
 PFT, 2D-ECHO (Color Doppler), Holter, TMT, Cardiac-3 available  
 VIA, VILI, Colposcopy available  
 Special Endocrinological Investigation Protocols.

ISO 9001:2008 Certified  
 Mobile: 9389994334, 9554572190, 9453837595



## Panacea Pathology

### Clinical Reference Lab

Persistence, Preparedness and Precision  
 EQAS (CMC Vellore Attached) & IQAS System  
 पूर्वांचल की सर्वोत्तम गुणवत्ता वाली पैथोलॉजी

PATIENT NAME : SARITA

AGE/GENDER : 24YRS/FEMALE

REFD BY DR. : ARCO FEMI HEALTHCARE LTD.

RECEIVED DATE : 25-02-2023(09:30AM)

SAMPLE : BLOOD & URINE

REPORT DATE : 25-02-2023(07:00PM)

## PATHOLOGY REPORT

### LIVER PROFILE TEST, SERUM

TEST	LAB TEST VALUES	NORMAL RANGE
<b>BIO CHEMISTRY</b>		
TOTAL BILIRUBIN	0.70	0.0 – 1.1 mg/dl
DIRECT BILIRUBIN	0.25	0.0 – 0.2 mg/dl
INDIRECT BILIRUBIN	0.45	< 0.90 mg/dl
SGOT (AST)	26.0	0 – 52 mg/dl
SGPT (ALT)	21.0	0 – 39 mg/dl
GGT (GYT)	17.6	< 55 U/L

### URINE ROUTINE EXAMINATION

TEST	LAB TEST VALUES	NORMAL RANGE
<b>PHYSICAL EXAMINATION</b>		
QUANTITY	30	ML
COLOUR	STRAW	PALE YELLOW
APPEARANCE	CLEAR	CLEAR
SPECIFIC GRAVITY	1.005	1.01 – 1.03
PH	6.5	4.7 – 7.5
<b>CHEMICAL EXAMINATION</b>		
GLUCOSE	Not Detected	Not Detected
PROTEIN	NIL	Not Detected
<b>MICROSCOPIC EXAMINATION</b>		
PUS CELLS	1-2	0-5
RBC	Not Detected	Not Detected
EPITHELIAL CELLS	2-3	0-5
CASTS	Not Detected	Not Detected
CRYSTALS	Not Detected	Not Detected
BACTERIA	Not Detected	Not Detected

### RANDOM/FASTING BLOOD SUGAR

TEST	LAB TEST VALUES	NORMAL RANGE
<b>RBS/FBS</b>		
RANDOM BLOOD SUGAR	120.0	125-140 mg/dl
FASTING BLOOD SUGAR	71.7	70-110 mg/dl

----- End of Report -----

Lab Technician

PANACEA HOSPITAL  
 (A UNIT OF AARON HEALTH CARE PVT. LTD.)  
 REG. NO. AL-1500  
 B-36/44 FK KABIR NAGAR  
 M.D. Pathology  
 DURGAKUND, VARANASI

Timing : 8.00 a.m. to 9.00 p.m. (Sunday 8.00 a.m. to 3.00 p.m.)

This Report is not valid for medico legal purpose

**Note:** These tests have technical limitations. Clinico-pathological interpretation is necessary. In case of any disparity test may be repeated immediately.

**Address :** 36/44 FK Kabir Nagar, Durgakund, Varanasi – 221005

**Email:** [dramishra@gmail.com](mailto:dramishra@gmail.com), [drpallaviojha@gmail.com](mailto:drpallaviojha@gmail.com) **Website:** [panaceahospital.org](http://panaceahospital.org)



# PANACEA HOSPITAL

B 36/44 F.K KABIR NAGAR, DURGAKUND  
TOLLFREE NO-18001233070.  
Whatsapp No - 8795832852  
www.piire.org



## OP Slip

Print Date : 25-Feb-2023 09:12AM




<b>UHID No</b> :- UD-22230003765	<b>OP No</b> :- OP-22230013946	<b>OP Date</b> :- 25 Feb 2023 9:12AM
<b>Patient Name</b> :- Mrs SARITA	<b>Age/Sex</b> :- 24 Y/Female	<b>Mobile No</b> :- 9624800754
<b>Husband</b> :- PRATIK KUMAR	<b>Department</b> :- OBST. & GYNAECOLOGY	
<b>Pay Type</b> :- Cash	<b>Consultant</b> :- Dr VANDANA SINGH (MBBS,MS)	
<b>Token No</b> :- NOR. - 1	<b>Paid/Bal</b> :- 0.00 /30.00	
<b>Patient Type</b> :- Normal		
<b>Address</b> :- SASARAM, varanasi		

BP :-  
height :- 160  
Weight (kg) :- 64  
BMI :-

SpO2 98  
PR 93

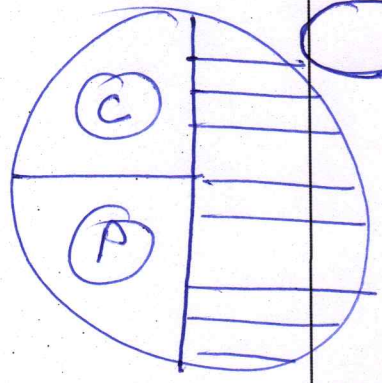
Rx



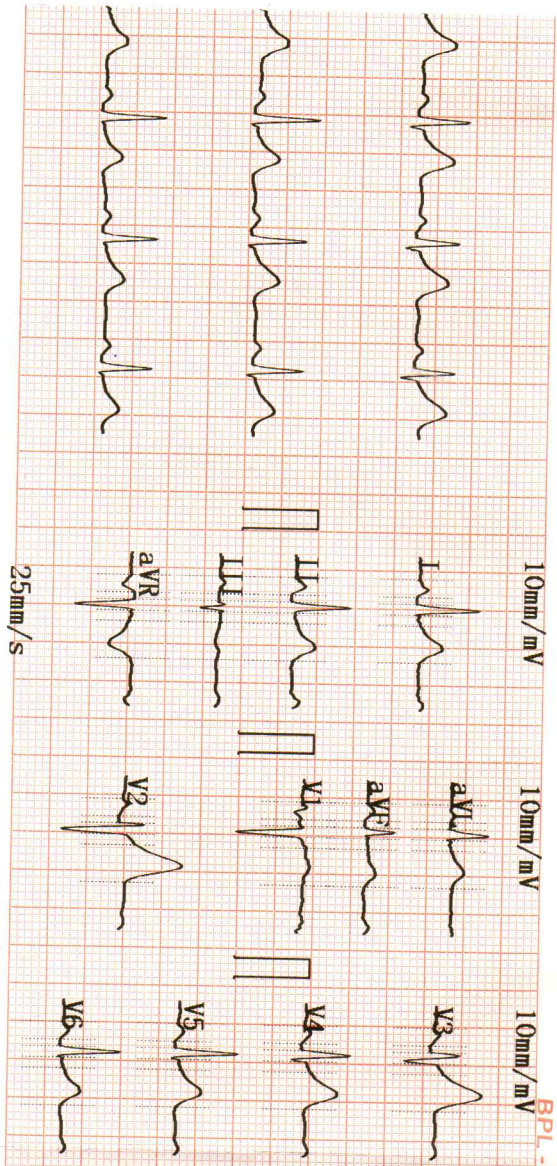
PPD

Rx.

Del. 14w Kent (d. (C.D).  
Exure gown (d.



Printed By : Mr NITIN YADAV  
Created By : Mr NITIN YADAV



2023-02-25 13:52

ID	:	:
Name	:	:
Sex	:	:
Height	:	:
SYS	:	:
DIA	:	:
HR	:	93 bpm
PR Interval	:	133 ms
P Duration	:	94 ms
QRS Duration	:	61 ms
T Duration	:	199 ms
QT/QTc	:	319/398 ms
P/QRS/T Axis	:	47.6/25.4/28.3 deg
R(V5)/S(V1)	:	0.82/0.84 mV
R(V5)+S(V1)	:	1.66 mV

<< Conclusions >>

Normal Sinus Rhythm;  
 Longitudinal left axis deviation.  
 \*\*Report need physician confirm\*\*

*Pallavi*  
 DR. PALLAVI MISHRA  
 MD (GENERAL MEDICINE)  
 MCI Reg. No. 52013

Physician

CARDIAC

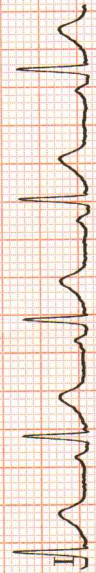
BPL - 02

AUTO 10mm/mV

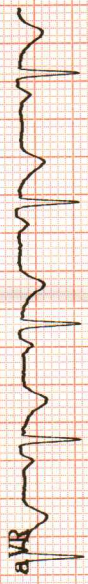10mm/mV

10mm/mV


10mm/mV



I



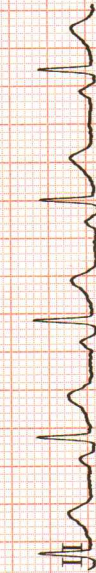aVR



V1

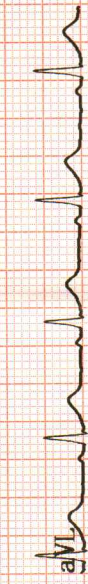


V4



II

aVL



V2




V5



III

aVF



V3



V6

25mm/s AC50Hz+EMC35Hz+DFT

CARDIART





# PANACEA HOSPITAL

*A shelter for many hearts A Home for many lives*

(An ISO 9001:2008 Certified Organisation)

Lab Attached with CMC Vellore Under EQAS Scheme

Name	MRS.SARITA	Sex /Age	24/F	Date	25/02/2023
Ref. by	Dr.Pallavi Mishra(MD)	BSA - m <sup>2</sup>		Echo window	fair

## Echo - Cardiography


MITRAL VALVE Doppler	AML - normal morphology MV Flow - E - 0.8 A-0.7 E/A=1.15	PML - normal morphology MVA - 3.0 cm <sup>2</sup> Mitral Regurgitation - <b>No</b>
TRICUSPID VALVE Doppler	Normal TV Flow -No	Tricuspid Regurgitation - <b>No</b>
PULMONARY VALVE Doppler	Normal PV Flow -No	Pulmonary Regurgitation - No
AORTIC VALVE Doppler	Trileaflet-No AV Flow - no	Aortic Regurgitation - no
MEASUREMENT	Aorta - 30.3 (20-38) mm IVS ed - 18.3 (6-12) mm LVID ed - 32.0 (35-55) mm LVPW ed - 9.7 (6-12) mm OA - 7 (> 5) mm	LA - 32.0 (24-32) mm IVS es -13.6 (6-12) mm LVID es - 36.3 (24-40) mm LVPW es - 10.3 (6-12) mm EPSS - 8 (< 9) mm

**CONCLUSION**

All cardiac chamber dimensions are WNL  
 No valvular abnormalities  
 Good LV systolic function present Modified Simpson's method (4C, 2C) (LVEF-77%)  
 No diastolic dysfunction present (E/A = 1.15) by tissue Doppler (E/e'=6.2)  
 No RWMA  
 No pericardial effusion  
 Intact IAS / IV  
 No PAH  
 No intra cardiac mass /thrombus /vegetation

**IMPRESSION** **Normal Echocardiogram**

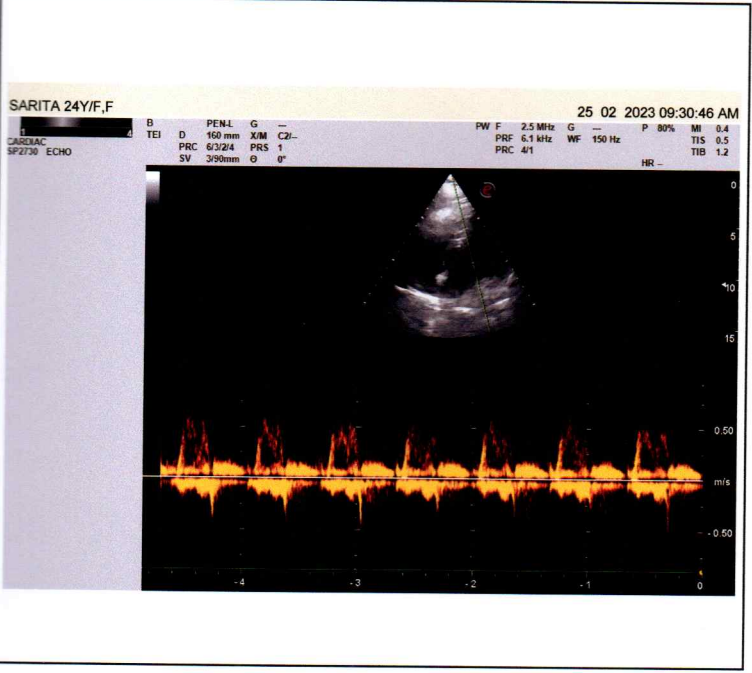
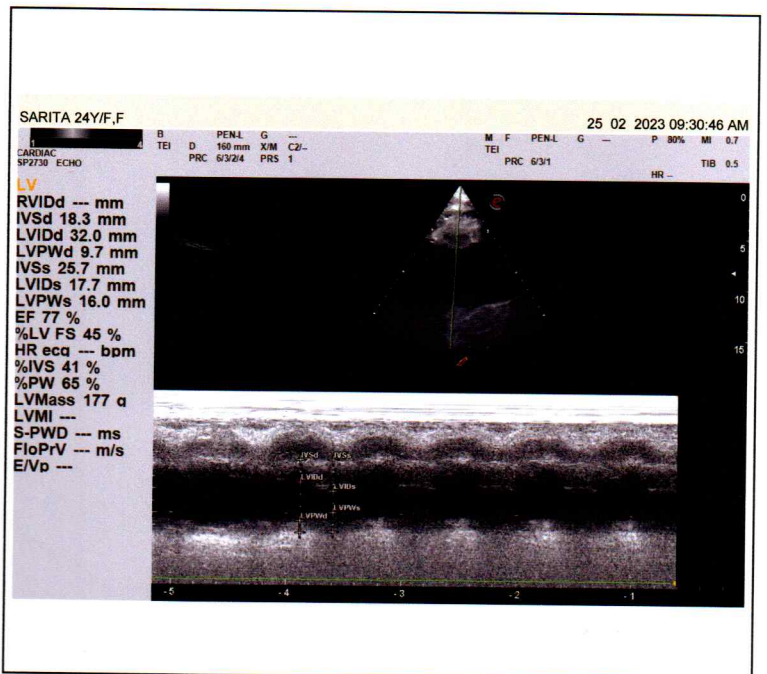
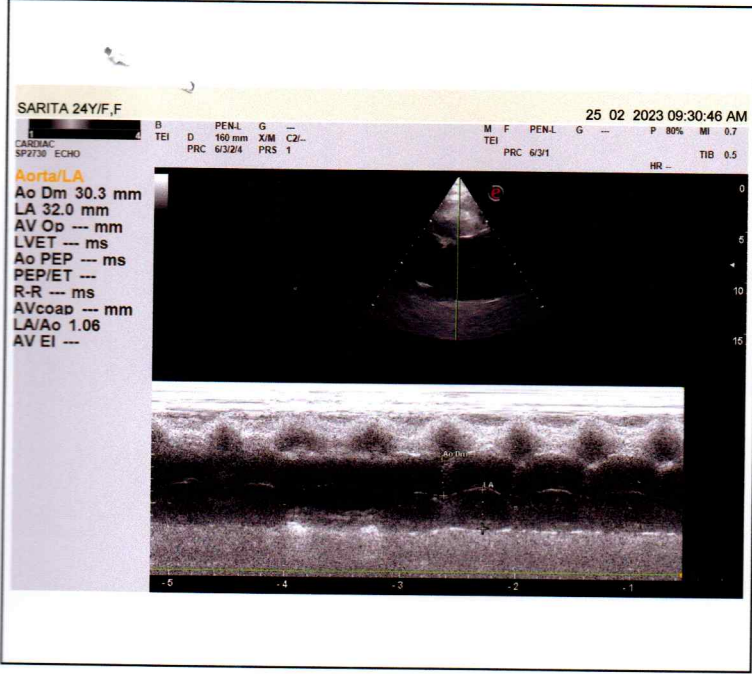
  
 Niraj Mishra  
 Physician Assistant  
 (PIRE)

  
 Dr. Pallavi Mishra  
 MBBS, MD, (MED), Lucknow  
 Echocardiography Specialist, MIAE  
 Non-invasive cardiologist  
 Women Cardiologist  
 Diabetocardiologist

Address : Kabir Nagar (Near Sanjay Shiksha Niketan), Durgakund, Varanasi

Mobile : 9554572190 / 9453837595 / Recpn. 9389994334

E-mail : dramishra@gmail.com, drpallaviojha@gmail.com, Website: www.paire.org





**GPS Map Camera**

**Varanasi, Uttar Pradesh, India**

**44-B3, Durgakund, Bhelupur, Varanasi, Uttar Pradesh 221001, India**

**Lat 25.289246°**

**Long 82.993301°**

**25/02/23 09:22 AM GMT +05:30**

रचना या डॉक्टर एवं स्टाफ के साथ  
अभद्र व्यवहार अबवा मारपीट  
करना गैर जमानती अपराध है।  
कानून  
U.P. Medical Protection Act - 2013  
1. शोषण, उत्पीड़न, बर्बरता (जिसमें अत्याचार है)  
2. 3 साल की अवधि में 50000/- तक मुआवजा।  
3. चरमस्थित व्यक्ति कागु के मुआवजा की श्रेणी में आता है।  
डी.जी. उ.प. अधिकृत एवं जमानती के साथ।  
आपको हरिद्वार-जीएचए रोड एमिडिएशन। आई.एच.ए. चारवली।

A Suffer For Many Heart  
Home For Many Lives

# Diabetes Care Organisation

ओ. पी. डी. पंजीकरण  
O.P.D. REGISTRATION

IPD BILLING

 **GPS Map Camera**

**Varanasi, Uttar Pradesh, India**  
**44-B3, Durgakund, Bhelupur, Varanasi, Uttar Pradesh 221001, India**  
**Lat 25.289246°**  
**Long 82.993301°**  
**25/02/23 09:05 AM GMT +05:30**



Call Now - 1800-123-3070

# PANACEA HOSPITAL

*A shelter for many hearts A Home for many lives*

(An ISO 9001:2008 Certified Organisation)

Lab Attached with CMC Vellore Under EQAS Scheme

**NAME:** MRS.SARITA

**AGE/SEX:** 25 YRS / FEMALE

**REF BY:** DR. ASHUTOSH MISHRA (MD)

**DATE:** 25/02/2023

## ULTRA SOUND FOR ABDOMEN REPORT

**Liver:** Normal in shape and size(11.9cm) and shows smooth and regular margin.

**Gall bladder** GB not visualized (post cholecystectomy).

**CBD** Visualized part normal in course & caliber.

**Pancreas:** Normal in size, shape & echogenicity. Margins are smooth & regular. No diffuse/ focal lesion seen. Pancreatic tail obscured.

**Spleen:** Normal in size shape & echogenicity. Margins are smooth & regular. No diffuse / focal lesion seen. Splenic vessels at hilum is normal.

**Kidney:** Right kidney: 8.9 X 4.0cm Left kidney: 11.5 X 4.1 cm Normal cortical echogenicity with well maintained Cortical-medullary differentiation., Pelvicalyceal system normal. No calculus/mass lesion seen. No hydronephrosis/ hydroureter seen.

**Urinary bladder:** Normally distended, wall thickness is normal. No echogenic foci lumen or diverticula seen. Both VUJ appears normal. No E.R. calculus / mass lesion seen

**Uterus:** Uterus normal in size shape & echogenicity. Margins are smooth & regular. Endometrial thickness within normal limits.

**Ovary:** Right ovary normal in size and shows normal morphology.  
Left ovary normal in size and shows normal morphology.

**Others:** No free fluid in peritoneal cavity.  
No free fluid in bilateral pleural cavity.

### **Impression:**

❖ **NO SIGNIFICANT SONOLOGICAL ABNORMALITY DETECTED.**

REPORTED BY

**DR. R. K. TIWARI**

**MD RADIODIAGNOSIS (GOLD MEDALIST)**

**KGMU,LUCKNOW**

**Reg.No. 57557**

Please correlate clinically and further investigations.

Note: (1) This report is not valid for medico-legal purposes.

(2) In case of any discrepancy due typing error, please get it Rectified immediately.

**Address :** Kabir Nagar (Near Sanjay Shiksha Niketan), Durgakund, Varanasi

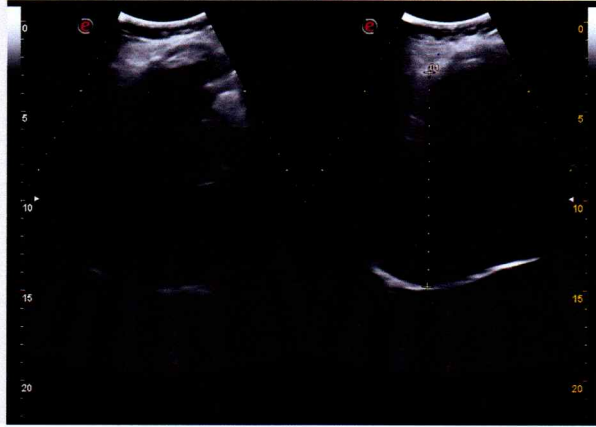
**Mobile :** 9554572190 / 9453837595 / Recpn. 9389994334

**E-mail :** dramishra@gmail.com, drpallaviojha@gmail.com, Website: www.piire.org

SARITA 24Y/F,F 25 02 2023 09:32:08 AM

ABDOMINAL AC2541 ABD B TEI D GEN.M G 197 mm X/M C2/- P 60% MI 0.8 PRC 19/2/3/5 PRS 4

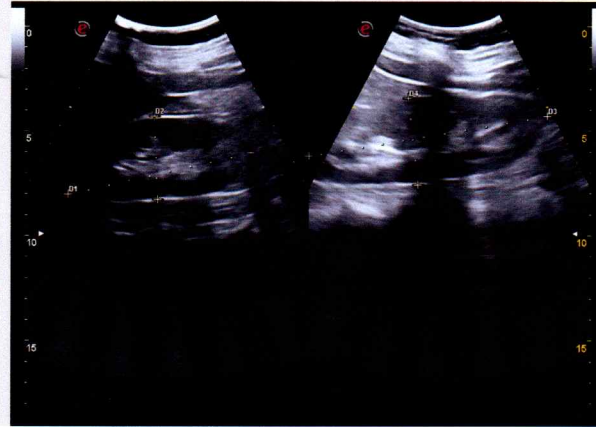
D1 119.4 mm



SARITA 24Y/F,F 25 02 2023 09:32:08 AM

ABDOMINAL AC2541 ABD B TEI D GEN.M G 169 mm X/M C2/- P 60% MI 0.8 PRC 19/2/3/5 PRS 4

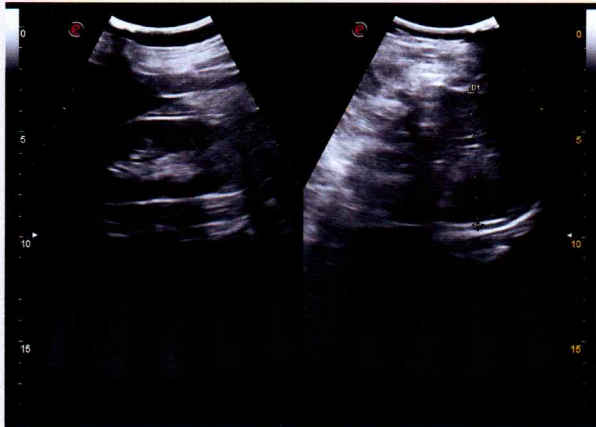D-Ratio  
D1 89.7 mm  
D2 40.0 mm  
D/D 224 %  
D-Ratio  
D3 115.4 mm  
D4 41.8 mm  
D/D 276 %



SARITA 24Y/F,F 25 02 2023 09:32:08 AM

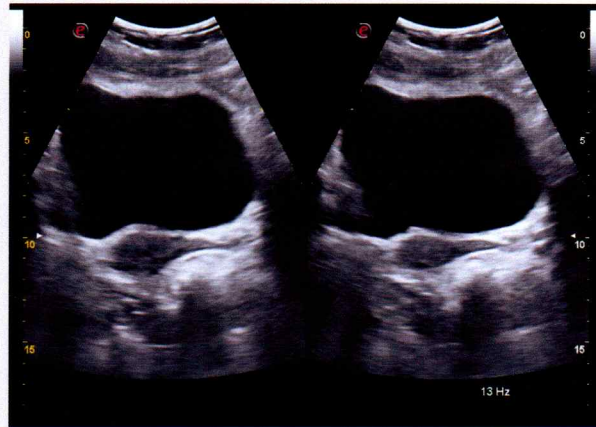
ABDOMINAL AC2541 ABD B TEI D GEN.M G 169 mm X/M C2/- P 60% MI 0.8 PRC 19/2/3/5 PRS 4

D1 63.1 mm



SARITA 24Y/F,F 25 02 2023 09:32:08 AM

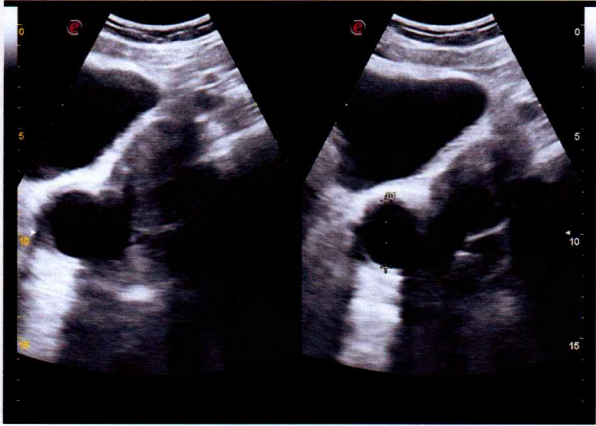
ABDOMINAL AC2541 ABD B TEI D GEN.M G 169 mm X/M C2/- P 60% MI 0.8 PRC 19/2/3/5 PRS 4



SARITA 24Y/F,F 25 02 2023 09:32:08 AM

ABDOMINAL AC2541 ABD B TEI D GEN.M G 169 mm X/M C2/- P 60% MI 0.8 PRC 19/2/3/5 PRS 4

D1 31.7 mm





# PANACEA HOSPITAL

*A shelter for many hearts A Home for many lives*

(An ISO 9001:2008 Certified Organisation)

Lab Attached with CMC Vellore Under EQAS Scheme

**NAME:**MRS.SARITA

**AGE/SEX:** 25 YRS / FEMALE

**REFBY:**DR.ASHUTOSH MISHRA(MD)

**DATE:**25/02/2023

## X-RAY CHEST PA

### BOTH LUNG FIELDS AND PLEURAE:

Both lungs show normal bronchovascular pattern.

Right & left hila are normal

No focal mass or calcification is seen

There is no evidence of any fluid in the both the pleural cavities.

Both domes of diaphragms are normal in position.

### MEDIASTINUM:

Trachea is central in position.

Cardiac silhouette is of normal size and configuration.

No evidence of pericardial effusion.

No significant lymphadenopathy is seen.

Visualized skeleton is normal.

-----  
NO SIGNIFICANT RADIOGRAPHIC ABNORMALITY.

*h*  
**REPORTED BY**

**DR. Rahul Kumar Tiwari**

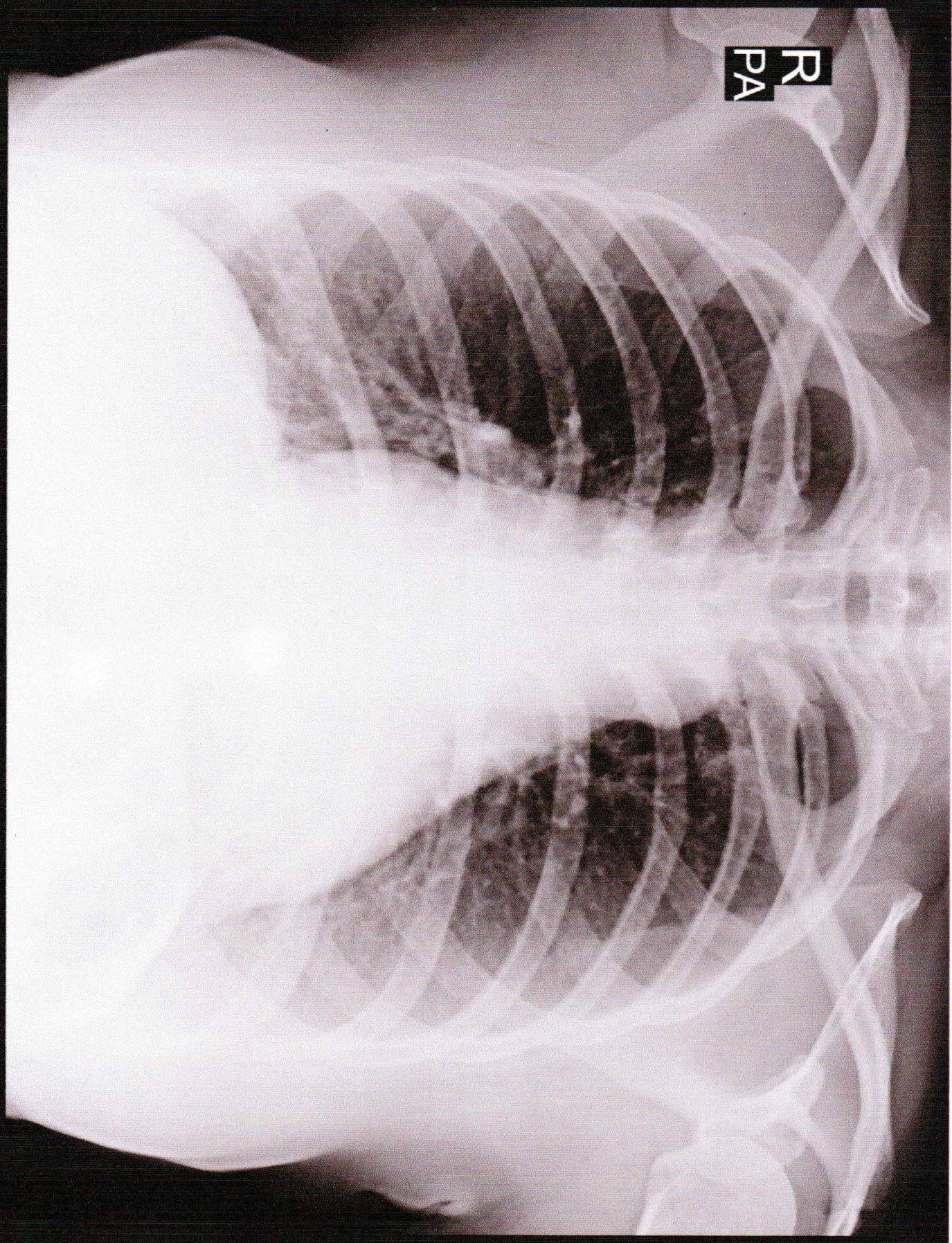
MBBS, MD (Radio Diagnosis)

Reg.No. 57557

**Address :** Kabir Nagar (Near Sanjay Shiksha Niketan), Durgakund, Varanasi

**Mobile :** 9554572190 / 9453837595 / Recpn. 9389994334

**E-mail :** dramishra@gmail.com, drpallaviojha@gmail.com, Website: www.piire.org



R  
PA

SARITA 24Y/F 3765 O CHEST P.A. 25-Feb-23 10:09 AM

PANACEA HOSPITAL, KABIR NAGAR, DURGAKUND, VARANASI