

ID: 9 *denudo*

Male : 88 Years

Req. No. : R.P-130180

Age - 502-58 P-87

HR : 88 bpm

P : 95 ms

PR : 157 ms

QRS : 79 ms

QT/QTcBz : 343/416 ms

P/QRS/T : 44/38/-13 °

RV5/SV1 : 1.383/0.682 mV

Diagnosis Information:

Sinus Rhythm

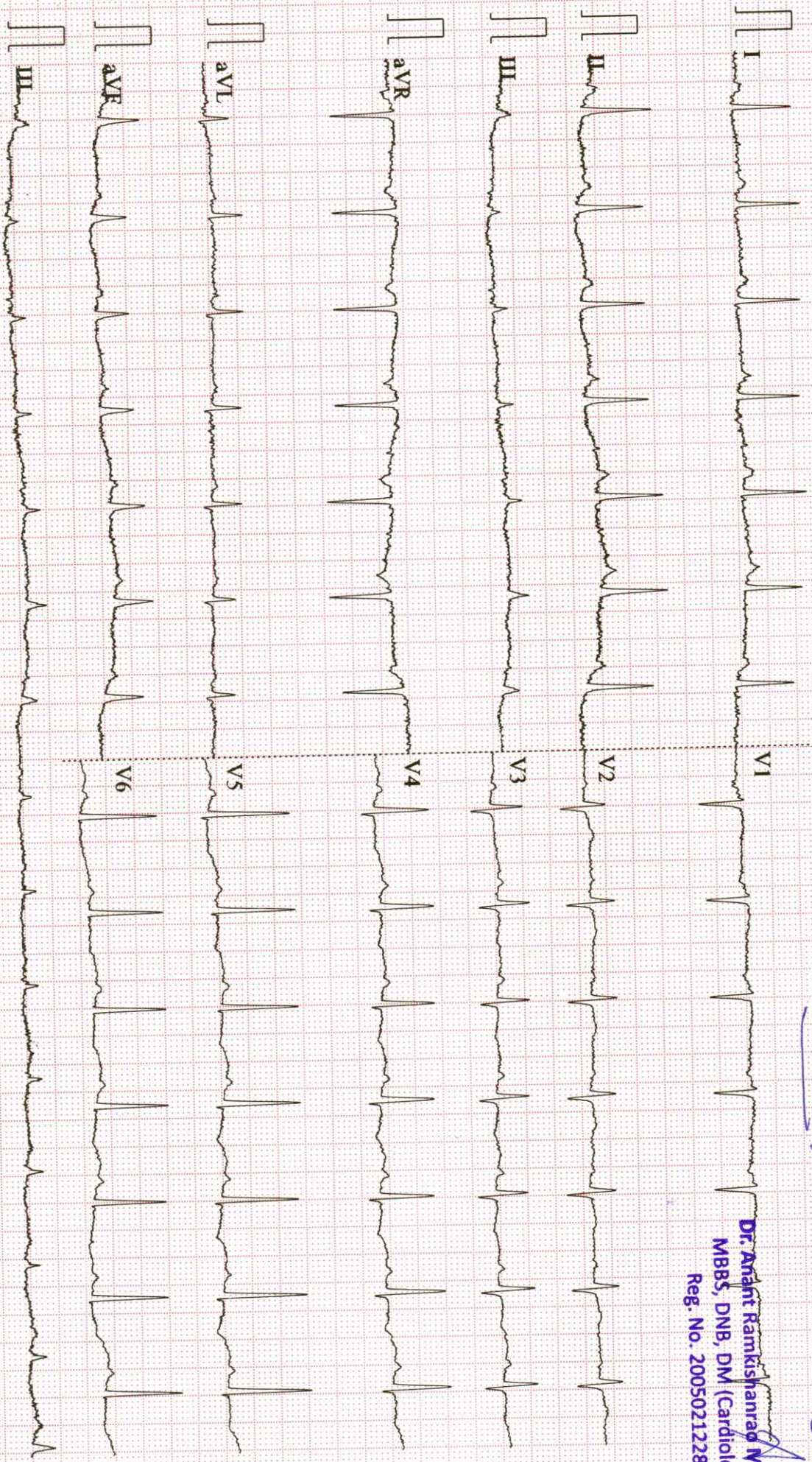
T Wave Abnormality(I,II,III,aVL,aVF,V3,V4,V5,V6)

*NSR  
PLV3-V6*

Report Confirmed by:

*Adv :- 20-ECAD*

Dr. Anant Ramkishanrao Munde  
MBBS, DNB, DM (Cardiology)  
Reg. No. 2005021228



0.15-45Hz AC50 25mm/s 10mm/mV 2\*5.0s+1r V2.21 SEMIP V1.92 Siddhivinayak Hospital



7/1/2023

Mrs. *Penpa Chante*.  
S/F.

Height - 155 cm  
Weight - 64 kg  
BMI - 26.6 kg/m<sup>2</sup>  
overweight

Menopausal ~~age~~ women.  
P<sub>3</sub>L<sub>3</sub> - FTD,

S.p - 130/80

do (L) sided knee pain.

Dental carries,

Ech (L & R, M,  
AVL, AVF  
V3 to V6).

ECG Echo - normal.

USG Abd - normal.

Low Hb & HbA1c is on  
borderline consult physician.

Adv

- Blood investigations
- CXR
- X-ray (L) knee  
A/P view.

Vision Test

R eye    L eye

D → 6/6      6/6

N → N12      N12

Color Normal  
Vision

Pt fit. can remove her  
weight duties.



**HELPLINE**

022 - 2588 3531

S-1, Vedant Complex,  
Vartak Nagar, Thane (W) 400 606

[www.siddhivinayakhospitals.org](http://www.siddhivinayakhospitals.org)





Name - Mrs. Renuka Ghante	Age - 51 Y/F
Ref by Dr.- Siddhivinayak Hospital	Date - 07/10/2023

### USG ABDOMEN & PELVIS

#### Clinical details:- Routine

The Liver is normal in size and shows normal echogenicity. There is no obvious abnormal focal lesion seen. There is no IHBR dilatation seen in both the lobes of the liver.

The CBD and the Portal vein appear normal.

The Gall bladder is well distended & appears normal. No calculi or filling defects are seen. No evidence of Pericholecystic collection. The wall thickness is normal.

Right Kidney measures 8.0 x 3.7 cm & appears normal in shape and position. There is no evidence of hydronephrosis or any calculi seen. Cortico-medullary differentiation is maintained.

Left Kidney measures 9.3 x 4.7 cm & appears normal in shape and position. There is no evidence of hydronephrosis or any calculi seen. Cortico-medullary differentiation is maintained.

The Pancreas is normal in size & shows homogenous echopattern. It shows no focal lesion. The Spleen is normal in size (9.3 cm) with homogenous echotexture.

The urinary bladder is adequately distended and appears normal. There is no evidence of any obvious calculi or any mass lesion seen. Both Uretero-vesical junctions appear clear. No abnormal intraluminal lesion noted.

The Uterus is menopausal.

Bilateral adnexae appear normal. No focal lesion noted.

No free fluid or obvious lymphadenopathy is seen in abdomen and pelvis.

#### IMPRESSION:

- No significant abnormality seen.

Adv.: Clinical and lab correlation.

**DR. MOHAMMAD SOHAIB**  
MBBS; DMRE  
CONSULTANT RADIOLOGIST

Note: The above report represents interpretation of various radiographic / sonographic shadows, and hence has its own limitations. This report has to be co-related clinic-pathologically by the referring / physician and it does NOT represent the sole diagnosis. Second opinion is always advisable.





Name - Mrs. Renuka Ghante	Age - 51 Y/F
Ref by Dr.- Siddhivinayak Hospital	Date - 07/10/2023

**USG -BOTH BREAST**

**Real time sonography of both breast was performed with high frequency probe.**

Both breast show normal, medium level, homogeneous echotexture. No evidence of any solid or cystic focal mass lesion.

No evidence of calcification noted.


The pectorallis major muscles appear normal.

No evidence of axillary lymphadenopathy seen.

**IMPRESSION:**

- **No significant abnormality is noted.**

*Thanks for the referral.....*

  
**DR. MOHAMMAD SOHAIB**  
**MBBS; DMRE**  
**CONSULTANT RADIOLOGIST**

**Note: The above report represents interpretation of various radiographic / sonographic shadows, and hence has its own limitations. This report has to be co-related clinic-pathologically by the referring / physician and it does NOT represent the sole diagnosis.**







### ECHOCARDIOGRAM

NAME	MRS. RENUKA GHANTE
AGE/SEX	51 YRS/F
REFERRED BY	SIDDHIVINAYAK HOSPITAL
DOCTOR	DR. ANANT MUNDE, DNB, DM (CARDIOLOGY)
DATE OF EXAMINATION	07/10/2023

### 2D/M-MODE ECHOCARDIOGRAPHY

<b>VALVES:</b> <b>MITRAL VALVE:</b> <ul style="list-style-type: none"> <li>• AML: Normal</li> <li>• PML: Normal</li> <li>• Sub-valvular deformity: Absent</li> </ul> <b>AORTIC VALVE:</b> Normal <ul style="list-style-type: none"> <li>• No. of cusps: 3</li> </ul> <b>PULMONARY VALVE:</b> Normal <b>TRICUSPID VALVE:</b> Normal	<b>CHAMBERS:</b> <b>LEFT ATRIUM:</b> Normal <b>LEFT VENTRICLE:</b> Normal <ul style="list-style-type: none"> <li>• RWMA: No</li> <li>• Contraction: Normal</li> </ul> <b>RIGHT ATRIUM:</b> Normal <b>RIGHT VENTRICLE:</b> Normal <ul style="list-style-type: none"> <li>• RWMA: No</li> <li>• Contraction: Normal</li> </ul>
<b>GREAT VESSELS:</b> <ul style="list-style-type: none"> <li>• AORTA: Normal</li> <li>• PULMONARY ARTERY: Normal</li> </ul>	<b>SEPTAE:</b> <ul style="list-style-type: none"> <li>• IAS: Intact</li> <li>• IVS: Intact</li> </ul>
<b>CORONARIES:</b> Proximal coronaries normal <b>CORONARY SINUS:</b> Normal <b>PULMONARY VEINS:</b> Normal	<b>VENACAVAE:</b> <ul style="list-style-type: none"> <li>• SVC: Normal</li> <li>• IVC: Normal and collapsing &gt;20% with respiration</li> </ul> <b>PERICARDIUM:</b> Normal

### MEASUREMENTS:

AORTA		LEFT VENTRICLE STUDY		RIGHT VENTRICLE STUDY	
PARAMETER	OBSERVED VALUE	PARAMETER	OBSERVED VALUE	PARAMETER	OBSERVED VALUE
Aortic annulus	20 mm	Left atrium	32 mm	Right atrium	mm
Aortic sinus	mm	LVIDd	42.2 mm	RVd (Base)	mm
Sino-tubular junction	mm	LVIDs	25.7 mm	RVEF	%
Ascending aorta	mm	IVSd	7.6 mm	TAPSE	mm
Arch of aorta	mm	LVPWd	7.6 mm	MPA	mm
Desc. thoracic aorta	mm	LVEF	69 %	RVOT	mm
Abdominal aorta	mm	LVOT	mm	IVC	12.5 mm





Name – Mrs. Renuka Ghanate	Age - 51 Y/F
Ref by Dr.- Siddhivinayak Hospital	Date - 07/10/2023

**X- Ray chest (PA VIEW)**

No obvious active parenchymal lesion seen in both lungs.

Cardiac and aortic shadows appear normal

No evidence of pleural of effusion is seen.

Both domes of diaphragm appear normal.

No obvious bony lesion is seen.

**IMPRESSION:**

- No significant abnormality seen.

Adv.: Clinical and lab correlation.

**DR. MOHAMMAD SOHAIB**  
**MBBS; DMRE**  
**CONSULTANT RADIOLOGIST**

Note: The above report represents interpretation of various radiographic / sonographic shadows, and hence has its own limitations. This report has to be co-related clinic-pathologically by the referring / physician and it does NOT represent the sole diagnosis.



### COLOR - FLOW & DOPPLER ECHOCARDIOGRAPHY

NAME	MR. RENUKA GHANTE
AGE/SEX	51 YRS/F
REFERRED BY	SIDDHIVINAYAK HOSPITAL
DOCTOR	DR. ANANT MUNDE, DNB, DM (CARDIOLOGY)
DATE OF EXAMINATION	0710/2023

	MITRAL	TRICUSPID	AORTIC	PULMONARY
FLOW VELOCITY (m/s)			1.15	0.91
PPG (mmHg)				
MPG (mmHg)				
VALVE AREA (cm <sup>2</sup> )				
DVI (ms)				
PR END DIASTOLIC VELOCITY (m/s)				
ACCELERATION/ DECELERATION TIME (ms)				
PHT (ms)				
VENA CONTRACTA (mm)				
REGURGITATION		TRJV= m/s PASP= mmHg		
E/A	E<A			
E/E'				

**FINAL IMPRESSION: NORMAL STUDY.**

- No RWMA
- Normal LV systolic function (LVEF: 69 %)
- Good RV systolic function
- Grade I diastolic dysfunction
- All cardiac valves are normal
- All cardiac chambers are normal
- IAS/IVS intact
- No pericardial effusion/ clot/vegetations

**ADVICE:** Nil

**ECHOCARDIOGRAPHER:**

Dr. ANANT MUNDE

INTERVENTIONAL CARDIOLOGIST

Name	: Mrs. RENUKA GHANATE	Collected On	: 7/10/2023 11:06 am
Lab ID.	: 170043	Received On	: 7/10/2023 11:16 am
Age/Sex	: 51 Years / Female	Reported On	: 7/10/2023 8:16 pm
Ref By	: SIDDHIVINAYAK HOSPITAL CGHS /ESIS	Report Status	: INTERIM



**\*LIPID PROFILE**


TEST NAME	RESULTS	UNIT	REFERENCE RANGE
<b>TOTAL CHOLESTEROL (CHOLESTEROL OXIDASE, ESTERASE, PEROXIDASE)</b>	184.0	mg/dL	Desirable blood cholesterol: - <200 mg/dl. Borderline high blood cholesterol: - 200 - 239 mg/dl. High blood cholesterol: - >239 mg/dl.
<b>S.HDL CHOLESTEROL (DIRECT MEASURE - PEG)</b>	45.0	mg/dL	Major risk factor for heart : <30 mg/dl. Negative risk factor for heart disease : >=80 mg/dl.
<b>S. TRIGLYCERIDE (ENZYMATIC, END POINT)</b>	90.8	mg/dL	Desirable level : <161 mg/dl. High : >= 161 - 199 mg/dl. Borderline High : 200 - 499 mg/dl. Very high : >499mg/dl.
<b>VLDL CHOLESTEROL (CALCULATED VALUE)</b>	18	mg/dL	UPTO 40
<b>S.LDL CHOLESTEROL (CALCULATED VALUE)</b>	121	mg/dL	Optimal: <100 mg/dl. Near Optimal: 100 - 129 mg/dl. Borderline High: 130 - 159 mg/dl. High : 160 - 189mg/dl. Very high : >= 190 mg/dl.
<b>LDL CHOL/HDL RATIO (CALCULATED VALUE)</b>	2.69		UPTO 3.5
<b>CHOL/HDL CHOL RATIO (CALCULATED VALUE)</b>	4.09		<5.0

Above reference ranges are as per ADULT TREATMENT PANEL III recommendation by NCEP (May 2015).

Result relates to sample tested, Kindly correlate with clinical findings.

----- END OF REPORT -----

Checked By  
SHAISTA Q



**DR. SMITA RANVEER.**  
**M.B.B.S.M.D. Pathology(Mum)**  
**Consultant Histocytopathologist**





Name	: Mrs. RENUKA GHANATE	Collected On	: 7/10/2023 11:06 am
Lab ID.	: 170043	Received On	: 7/10/2023 11:16 am
Age/Sex	: 51 Years / Female	Reported On	: 7/10/2023 8:16 pm
Ref By	: SIDDHIVINAYAK HOSPITAL CGHS /ESIS	Report Status	: INTERIM



**COMPLETE BLOOD COUNT**


TEST NAME	RESULTS	UNIT	REFERENCE RANGE
<b>HEMOGLOBIN</b>	<b>10.4</b>	gm/dl	12.0 - 15.0
HEMATOCRIT (PCV)	<b>31.2</b>	%	36 - 46
RBC COUNT	<b>4.48</b>	x10 <sup>6</sup> /uL	4.5 - 5.5
MCV	<b>70</b>	fl	80 - 96
MCH	<b>23.2</b>	pg	27 - 33
MCHC	33	g/dl	33 - 36
RDW-CV	14.3	%	11.5 - 14.5
<b>TOTAL LEUCOCYTE COUNT</b>	4270	/cumm	4000 - 11000
<b><u>DIFFERENTIAL COUNT</u></b>			
NEUTROPHILS	70	%	40 - 80
LYMPHOCYTES	22	%	20 - 40
EOSINOPHILS	02	%	0 - 6
MONOCYTES	06	%	2 - 10
BASOPHILS	00	%	0 - 1
<b>PLATELET COUNT</b>	282000	/cumm	150000 - 450000
MPV	10.6	fl	6.5 - 11.5
PDW	16.4	%	9.0 - 17.0
PCT	0.300	%	0.200 - 0.500
RBC MORPHOLOGY	Normocytic Normochromic		
WBC MORPHOLOGY	Normal		
PLATELETS ON SMEAR	Adequate		

Method : EDTA Whole Blood- Tests done on Automated Six Part Cell Counter.RBC and Platelet count by Electric Impedance ,WBC by SF Cube method and Differential by flow cytometry . Hemoglobin by Cyanide free reagent for hemoglobin test (Colorimetric Method).Rest are calculated parameters.

**Result relates to sample tested, Kindly correlate with clinical findings.**

----- END OF REPORT -----

Checked By  
SHAISTA Q



**DR. SMITA RANVEER.**  
**M.B.B.S.M.D. Pathology(Mum)**  
**Consultant Histocytopathologist**



Name : Mrs. RENUKA GHANATE  
Lab ID. : 170043  
Age/Sex : 51 Years / Female  
Ref By : SIDDHIVINAYAK HOSPITAL CGHS /ESIS

Collected On : 7/10/2023 11:06 am  
Received On : 7/10/2023 11:16 am  
Reported On : 7/10/2023 8:16 pm  
Report Status : INTERIM



**HEMATOLOGY**

TEST NAME	RESULTS	UNIT	REFERENCE RANGE
<b>ESR</b>			
<b>ESR</b>	<b>50</b>	mm/1hr.	0 - 20

METHOD - WESTERGREN

Result relates to sample tested, Kindly correlate with clinical findings.

----- END OF REPORT -----

Checked By  
SHAISTA Q

**DR. SMITA RANVEER.**  
**M.B.B.S.M.D. Pathology(Mum)**  
**Consultant Histocytopathologist**






Name	: Mrs. RENUKA GHANATE	Collected On	: 7/10/2023 11:06 am
Lab ID.	: 170043	Received On	: 7/10/2023 11:16 am
Age/Sex	: 51 Years / Female	Reported On	: 7/10/2023 8:16 pm
Ref By	: SIDDHIVINAYAK HOSPITAL CGHS /ESIS	Report Status	: INTERIM



**URINE ROUTINE EXAMINATION**

TEST NAME	RESULTS	UNIT	REFERENCE RANGE
<b><u>URINE ROUTINE EXAMINATION</u></b>			
<b><u>PHYSICAL EXAMINATION</u></b>			
VOLUME	30 ml		
COLOUR	Pale yellow	Text	Pale Yellow
APPEARANCE	Clear		Clear
<b><u>CHEMICAL EXAMINATION</u></b>			
REACTION (methyl red and Bromothymol blue indicator)	Acidic		Acidic
SP. GRAVITY (Bromothymol blue indicator)	1.010		1.005 - 1.022
PROTEIN (Protein error of PH indicator)	Absent		Absent
BLOOD (Peroxidase Method)	Absent		Absent
SUGAR (GOD/POD)	Absent		Absent
KETONES (Acetoacetic acid)	Absent		Absent
BILE SALT & PIGMENT (Diazonium Salt)	Absent		Absent
UROBILINOGEN (Red azodye)	Absent		Normal
LEUKOCYTES (pyrrole amino acid ester diazonium salt)	Absent	Text	Absent
NITRITE (Diazonium compound With tetrahydrobenzo quinolin 3-phenol)	Absent		Negative
<b><u>MICROSCOPIC EXAMINATION</u></b>			
RED BLOOD CELLS	Absent	Text	Absent
PUS CELLS	1-2	/ HPF	0 - 5
EPITHELIAL	0-2	/ HPF	0 - 5
CASTS	Absent		

Checked By  
SHAISTA Q



**DR. SMITA RANVEER.**  
**M.B.B.S.M.D. Pathology(Mum)**  
**Consultant Histocytopathologist**



Name : Mrs. RENUKA GHANATE  
Lab ID. : 170043  
Age/Sex : 51 Years / Female  
Ref By : SIDDHIVINAYAK HOSPITAL CGHS /ESIS

Collected On : 7/10/2023 11:06 am  
Received On : 7/10/2023 11:16 am  
Reported On : 7/10/2023 8:16 pm  
Report Status : INTERIM



**URINE ROUTINE EXAMINATION**

TEST NAME	RESULTS	UNIT	REFERENCE RANGE
CRYSTALS	Absent		
BACTERIA	Absent		Absent
YEAST CELLS	Absent		Absent
ANY OTHER FINDINGS	Absent		Absent
REMARK	Result relates to sample tested. Kindly correlate with clinical findings.		
	<b>Result relates to sample tested, Kindly correlate with clinical findings.</b>		
	----- END OF REPORT -----		

Checked By  
SHAISTA Q

**DR. SMITA RANVEER.**  
**M.B.B.S.M.D. Pathology(Mum)**  
**Consultant Histocytopathologist**





<b>Name</b>	: Mrs. RENUKA GHANATE	<b>Collected On</b>	: 7/10/2023 11:06 am
<b>Lab ID.</b>	: 170043	<b>Received On</b>	: 7/10/2023 11:16 am
<b>Age/Sex</b>	: 51 Years / Female	<b>Reported On</b>	: 7/10/2023 8:16 pm
<b>Ref By</b>	: SIDDHIVINAYAK HOSPITAL CGHS /ESIS	<b>Report Status</b>	: INTERIM



**IMMUNO ASSAY**

TEST NAME	RESULTS	UNIT	REFERENCE RANGE
<b><u>TFT (THYROID FUNCTION TEST )</u></b>			
SPACE		Space	-
SPECIMEN	Serum		
T3	135.9	ng/dl	84.63 - 201.8
T4	9.79	µg/dl	5.13 - 14.06
TSH	2.40	µIU/ml	0.270 - 4.20
T3 (Triiodo Thyronine hormone)	T4 (Thyroxine)	TSH(Thyroid stimulating hormone)	
AGE	RANGE	AGE	RANGES
1-30 days	100-740	1-14 Days	11.8-22.6
1-11 months	105-245	1-2 weeks	9.9-16.6
1-5 yrs	105-269	1-4 months	7.2-14.4
6-10 yrs	94-241	4 -12 months	7.8-16.5
11-15 yrs	82-213	1-5 yrs	7.3-15.0
0.1-2.5			
15-20 yrs	80-210	5-10 yrs	6.4-13.3
0.20-3.0			
		11-15 yrs	5.6-11.7
0.30-3.0			


**INTERPRETATION :**

TSH stimulates the production and secretion of the metabolically active thyroid hormones, thyroxine (T4) and triiodothyronine (T3), by interacting with a specific receptor on the thyroid cell surface. The synthesis and secretion of TSH is stimulated by Thyrotropin releasing hormone (TRH), in response to low levels of circulating thyroid hormones. Elevated levels of T3 and T4 suppress the production of TSH via a classic negative feedback mechanism. Failure at any level of regulation of the hypothalamic-pituitary-thyroid axis will result in either underproduction (hypothyroidism) or overproduction (hyperthyroidism) of T4 and/or T3.

**Result relates to sample tested, Kindly correlate with clinical findings.**

----- END OF REPORT -----

**Checked By**  
SHAISTA Q



**DR. SMITA RANVEER.**  
**M.B.B.S.M.D. Pathology(Mum)**  
**Consultant Histocytopathologist**



Name : Mrs. RENUKA GHANATE Collected On : 7/10/2023 11:06 am  
Lab ID. : 170043 Received On : 7/10/2023 11:16 am  
Age/Sex : 51 Years / Female Reported On : 7/10/2023 8:16 pm  
Ref By : SIDDHIVINAYAK HOSPITAL CGHS /ESIS Report Status : INTERIM



**HAEMATOLOGY**

TEST NAME	RESULTS	UNIT	REFERENCE RANGE
<b><u>BLOOD GROUP</u></b>			
SPECIMEN	WHOLE BLOOD EDTA & SERUM		
* ABO GROUP	'B'		
RH FACTOR	POSITIVE		
Method: Slide Agglutination and Tube Method (Forward grouping & Reverse grouping)			
<b>Result relates to sample tested, Kindly correlate with clinical findings.</b>			
----- END OF REPORT -----			

Checked By  
SHAISTA Q

**DR. SMITA RANVEER.**  
**M.B.B.S.M.D. Pathology(Mum)**  
**Consultant Histocytopathologist**





Name	: Mrs. RENUKA GHANATE	Collected On	: 7/10/2023 11:06 am
Lab ID.	: 170043	Received On	: 7/10/2023 11:16 am
Age/Sex	: 51 Years / Female	Reported On	: 7/10/2023 8:16 pm
Ref By	: SIDDHIVINAYAK HOSPITAL CGHS /ESIS	Report Status	: INTERIM



**\*BIOCHEMISTRY**


TEST NAME	RESULTS	UNIT	REFERENCE RANGE
<b>BLOOD UREA</b> (Urease UV GLDH Kinetic)	21.6	mg/dL	21 - 43
<b>BLOOD UREA NITROGEN</b> (Calculated)	10.09	mg/dL	5 - 20
<b>S. CREATININE</b> (Enzymatic)	0.70	mg/dL	0.6 - 1.4
<b>S. URIC ACID</b> (Uricase)	5.0	mg/dL	2.6 - 6.0
<b>S. SODIUM</b> (ISE Direct Method)	144.4	mEq/L	137 - 145
<b>S. POTASSIUM</b> (ISE Direct Method)	3.54	mEq/L	3.5 - 5.1
<b>S. CHLORIDE</b> (ISE Direct Method)	105.3	mEq/L	98 - 110
<b>S. PHOSPHORUS</b> (Ammonium Molybdate)	3.59	mg/dL	2.5 - 4.5
<b>S. CALCIUM</b> (Arsenazo III)	9.60	mg/dL	8.6 - 10.2
<b>PROTEIN</b> (Biuret)	6.52	g/dl	6.4 - 8.3
<b>S. ALBUMIN</b> (BGC)	3.94	g/dl	3.2 - 4.6
<b>S.GLOBULIN</b> (Calculated)	2.58	g/dl	1.9 - 3.5
<b>A/G RATIO</b> calculated	1.53		0 - 2

NOTE BIOCHEMISTRY TEST DONE ON FULLY AUTOMATED ( EM 200) ANALYZER.

**Result relates to sample tested, Kindly correlate with clinical findings.**

----- END OF REPORT -----

Checked By  
SHAISTA Q



**DR. SMITA RANVEER.**  
**M.B.B.S.M.D. Pathology(Mum)**  
**Consultant Histocytopathologist**



Name : Mrs. RENUKA GHANATE  
Lab ID. : 170043  
Age/Sex : 51 Years / Female  
Ref By : SIDDHIVINAYAK HOSPITAL CGHS /ESIS

Collected On : 7/10/2023 11:06 am  
Received On : 7/10/2023 11:16 am  
Reported On : 7/10/2023 8:16 pm  
Report Status : INTERIM



\* 1 7 0 0 4 3 \*

### Peripheral smear examination

TEST NAME	RESULTS
SPECIMEN RECEIVED	Whole Blood EDTA
RBC	Normocytic Normochromic
WBC	Total leucocyte count is normal on smear.
	Neutrophils:70 % Lymphocytes:24 % Monocytes:04 % Eosinophils:02 % Basophils:00 %
PLATELET	Adequate on smear.
HEMOPARASITE	No parasite seen.

**Result relates to sample tested, Kindly correlate with clinical findings.**

----- END OF REPORT -----

Checked By  
SHAISTA Q

**DR. SMITA RANVEER.**  
M.B.B.S.M.D. Pathology(Mum)  
Consultant Histocytopathologist





<b>Name</b>	: Mrs. RENUKA GHANATE	<b>Collected On</b>	: 7/10/2023 11:06 am
<b>Lab ID.</b>	: 170043	<b>Received On</b>	: 7/10/2023 11:16 am
<b>Age/Sex</b>	: 51 Years / Female	<b>Reported On</b>	: 7/10/2023 8:16 pm
<b>Ref By</b>	: SIDDHIVINAYAK HOSPITAL CGHS /ESIS	<b>Report Status</b>	: INTERIM




**LIVER FUNCTION TEST**

TEST NAME	RESULTS	UNIT	REFERENCE RANGE
<b>TOTAL BILLIRUBIN</b> (Method-Diazo)	0.28	mg/dL	0.0 - 2.0
<b>DIRECT BILLIRUBIN</b> (Method-Diazo)	0.15	mg/dL	0.0 - 0.4
<b>INDIRECT BILLIRUBIN</b> Calculated	0.13	mg/dL	0 - 0.8
<b>SGOT(AST)</b> (UV without PSP)	18.3	U/L	0 - 37
<b>SGPT(ALT)</b> UV Kinetic Without PLP (P-L-P)	16.8	U/L	UP to 40
<b>ALKALINE PHOSPHATASE</b> (Method-ALP-AMP)	78.0	U/L	42 - 98
<b>S. PROTIEN</b> (Method-Biuret)	6.52	g/dl	6.4 - 8.3
<b>S. ALBUMIN</b> (Method-BCG)	3.94	g/dl	3.5 - 5.2
<b>S. GLOBULIN</b> Calculated	2.58	g/dl	1.90 - 3.50
<b>A/G RATIO</b> Calculated	1.53		0 - 2

Result relates to sample tested, Kindly correlate with clinical findings.

----- END OF REPORT -----

Checked By  
SHAISTA Q



**DR. SMITA RANVEER.**  
**M.B.B.S.M.D. Pathology(Mum)**  
**Consultant Histocytopathologist**



Name	: Mrs. RENUKA GHANATE	Collected On	: 7/10/2023 11:06 am
Lab ID.	: 170043	Received On	: 7/10/2023 11:16 am
Age/Sex	: 51 Years / Female	Reported On	: 7/10/2023 8:16 pm
Ref By	: SIDDHIVINAYAK HOSPITAL CGHS /ESIS	Report Status	: INTERIM



**BIOCHEMISTRY**

TEST NAME	RESULTS	UNIT	REFERENCE RANGE
GAMMA GT	40.0	U/L	5 - 55
<b><u>BLOOD GLUCOSE FASTING &amp; PP</u></b>			
BLOOD GLUCOSE FASTING	109.1	mg/dL	70 - 110
BLOOD GLUCOSE PP	112.1	mg/dL	70 - 140

Method (GOD-POD). DONE ON FULLY AUTOMATED ANALYSER (EM200).

1. Fasting is required (Except for water ) for 8-10 hours before collection for fasting specimen. Last dinner should consist of bland diet.
2. Don't take insulin or oral hypoglycemic agent until after fasting blood sample has been drawn

**INTERPRETATION**

- Normal glucose tolerance : 70-110 mg/dl
- Impaired Fasting glucose (IFG) : 110-125 mg/dl
- Diabetes mellitus :  $\geq 126$  mg/dl

**POSTPRANDIAL/POST GLUCOSE (75 grams)**

- Normal glucose tolerance : 70-139 mg/dl
- Impaired glucose tolerance : 140-199 mg/dl
- Diabetes mellitus :  $\geq 200$  mg/dl

**CRITERIA FOR DIAGNOSIS OF DIABETES MELLITUS**


- Fasting plasma glucose  $\geq 126$  mg/dl
- Classical symptoms +Random plasma glucose  $\geq 200$  mg/dl
- Plasma glucose  $\geq 200$  mg/dl (2 hrs after 75 grams of glucose)
- Glycosylated haemoglobin  $> 6.5\%$

\*\*\*Any positive criteria should be tested on subsequent day with same or other criteria.

**GLYCOCELATED HEMOGLOBIN (HBA1C)**

HBA1C (GLYCOSALATED HAEMOGLOBIN)	<b>6.6</b>	%	Hb A1c > 8 Action suggested < 7 Goal < 6 Non - diabetic level
AVERAGE BLOOD GLUCOSE (A. B. G. )	<b>142.7</b>	mg/dL	65.1 - 136.3
METHOD	Particle Enhanced Immunoturbidimetry		

Checked By  
SHAISTA Q



**DR. SMITA RANVEER.**  
**M.B.B.S.M.D. Pathology(Mum)**  
**Consultant Histocytopathologist**



Name : Mrs. RENUKA GHANATE Collected On : 7/10/2023 11:06 am  
Lab ID. : 170043 Received On : 7/10/2023 11:16 am  
Age/Sex : 51 Years / Female Reported On : 7/10/2023 8:16 pm  
Ref By : SIDDHIVINAYAK HOSPITAL CGHS /ESIS Report Status : INTERIM



**BIOCHEMISTRY**

TEST NAME	RESULTS	UNIT	REFERENCE RANGE
-----------	---------	------	-----------------

HbA1c : Glycosylated hemoglobin concentration is dependent on the average blood glucose concentration which is formed progressively and irreversibly over a period of time and is stable till the life of the RBC/erythrocytes. Average Blood Glucose (A.B.G) is calculated value from HbA1c : Glycosylated hemoglobin concentration in whole Blood. It indicates average blood sugar level over past three months.

**Result relates to sample tested, Kindly correlate with clinical findings.**

----- END OF REPORT -----

Checked By  
SHAISTA Q

**DR. SMITA RANVEER.**  
**M.B.B.S.M.D. Pathology(Mum)**  
**Consultant Histocytopathologist**

