

DATE :- 15/04/2023
HEIGHT - 152 cm.
WEIGHT :- 50.3 kg



Medi wheel Health,
Check up

S/B DR. JAYDEEP BHAMBARE

PATIENT NAME :- Suchita R. Jha

AGE /SEX :- 52/F

SPO2 :- 93%
Pulse :- 88/min
BP :- 135/86 mm/hg
PR :- 25/min

Clinically better
No any present complain

Plan

BP tablet x 30d.

b/c
BP - 150/90 mm of Hg

P - 90/min

SPO2 - 98% on RA

15-4-2023

Tudgana 500

USG - Cholelithiasis without cholecystitis Au - Au x 30d

CBC - 11.4 | 6600 | 150

HbA1C - 4.6

diel ✓

F/PP - 90 | 110

Creat - 0.96

Uric acid - 3.3

Lipids - 181 | 141 | 96

SGPT - 30

Bili - 0.7

Protein - 6.7

ASTH - 2.44g

NAME: MRS. SUCHITA JHA	DATE: 15/04/2023
AGE/ SEX: 52 YEARS/ FEMALE	REFERRED BY: HEALTH CHECKUP

ULTRASOUND ABDOMEN & PELVIS

Clinical profile- Health checkup

Liver: Normal in size (13.8 cm), shape and shows normal echotexture. No evidence of any space occupying lesion seen. Intrahepatic biliary radicals are not dilated. Portal vein is normal in caliber.

Gallbladder: GB is distended and shows two calculi within measuring 16 and 15 mm. No wall thickening/pericholecystic fluid collection seen. CBD is normal in caliber.

Pancreas: Head & part of the body is visualized, appears normal in bulk & echotexture. Rest of the pancreas is obscured by bowel gases.

Spleen: Appears normal in size, shape and echotexture. No calcification or mass is seen.

Kidneys: Right kidney – 10.6 x 3 cm. Left kidney – 9 x 3.7 cm.

Both kidneys are normal in size, shape, positions and echotexture. Bilateral corticomedullary differentiation appears normal. No hydronephrosis seen. No evidence of any calculus or mass lesion seen.

Urinary Bladder: is well distended. No evidence of calculus/ wall thickening noted.

Uterus is atrophied and measures 5.9 x 3.8 x 2.6 cm appears normal in size, shape and echotexture.

Endometrium appears normal measuring 2 mm. No evidence of adnexal abnormality.

Free fluid: No evidence of any free fluid in peritoneal cavity.

IMPRESSION:

- Cholelithiasis without cholecystitis.

Clinical correlation is suggested.


DR TRIPTI PAREEK
(DNB RADIOLOGIST)

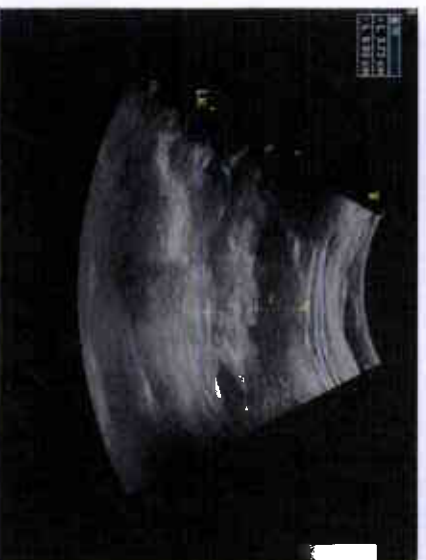
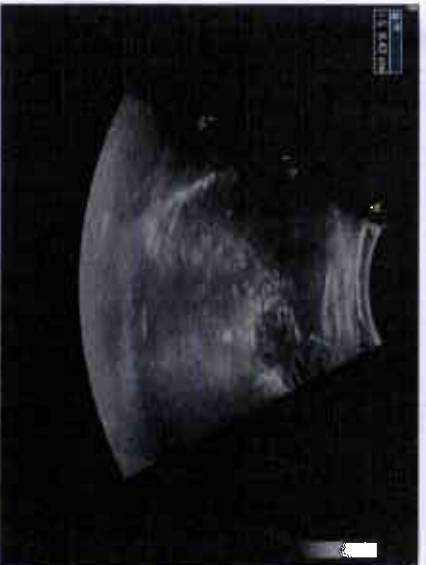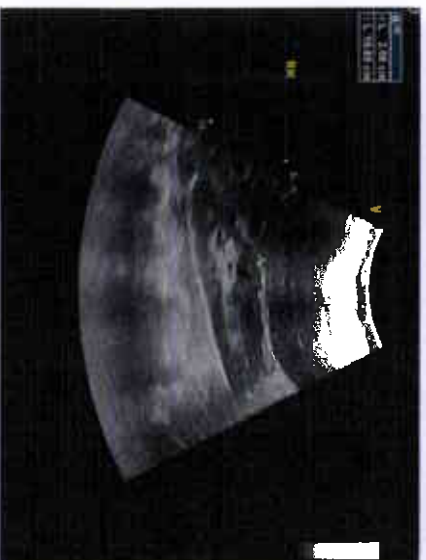
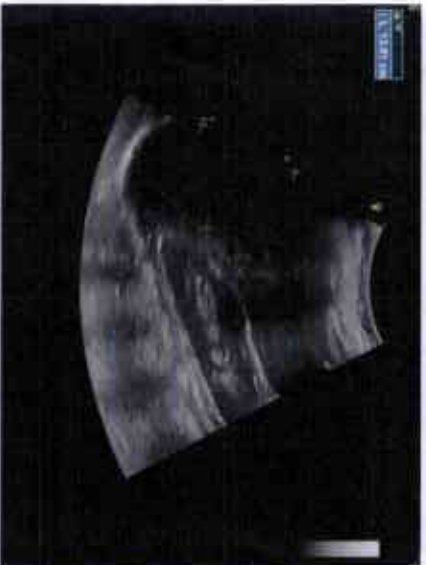
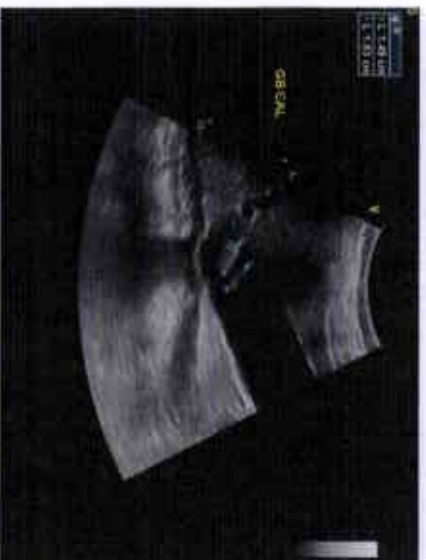
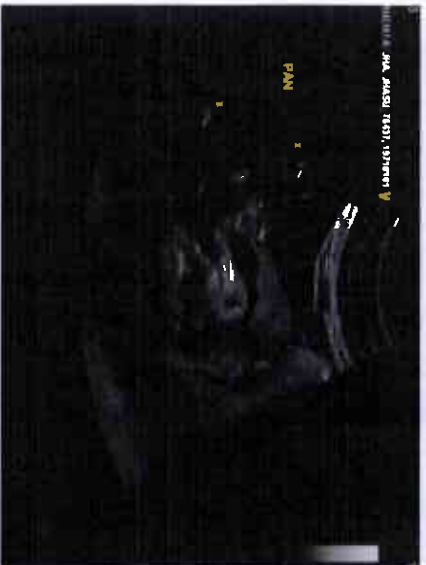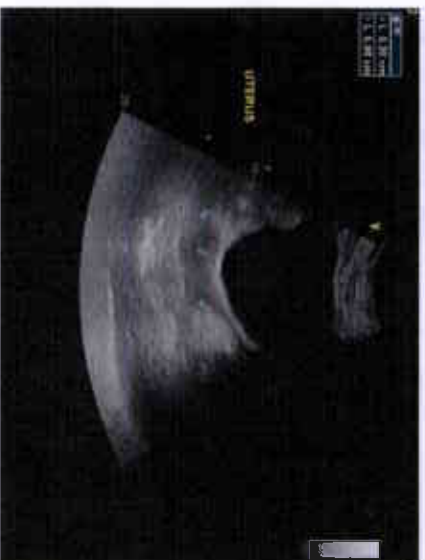
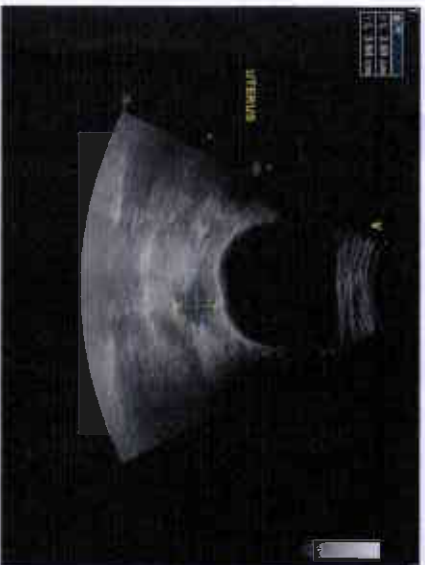
MAGNUM MULTISPECIALITY HOSPITAL
NASIK ROAD, NASHIK

Name JHA, SUCHITA

Sex Female

Age 52

Date 15/04/2023



NAME: MRS. SUCHITA JHA	DATE: 15/04/2023
AGE/ SEX: 52 YEARS / FEMALE	REFERRED BY: HEALTH CHECKUP

XRAY CHEST PA (VIEW)

Both the lungs are clear and do not show any obvious focal lesion.

Bilateral costo-phrenic and cardio-phrenic angles appear clear.

There is no evidence of pleural effusion or pneumothorax on either side.

Both the hilum appear normal.

Domes of diaphragm have normal contours and positions.

Visualised bones and soft tissues reveal no abnormality.

CONCLUSION:

No significant abnormality is seen.

Advise clinical correlation.


DR TRIPTI PAREEK
(DNB RADIOLOGIST)

ID: 0
SUCHITA JHA
Female 52Years
135/86 mmHg
Department: ER

15-04-2023 09:30:19 AM
HR : 79 bpm
P : 110 ms
PR : 146 ms
QRS : 88 ms
QT/QTc : 364/418 ms
P/QRS/T : 68/48/34 °
RV5/SV1 : 1.476/0.578 mV

Diagnosis Information:
Sinus rhythm
Normal ECG

Report Confirmed by: DR. JAYDEEP BHAMBARE

