

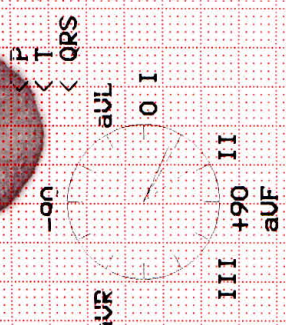
Ms. Vardai Shah  
 4x815  
 RR-3-23

UP 75 bpm

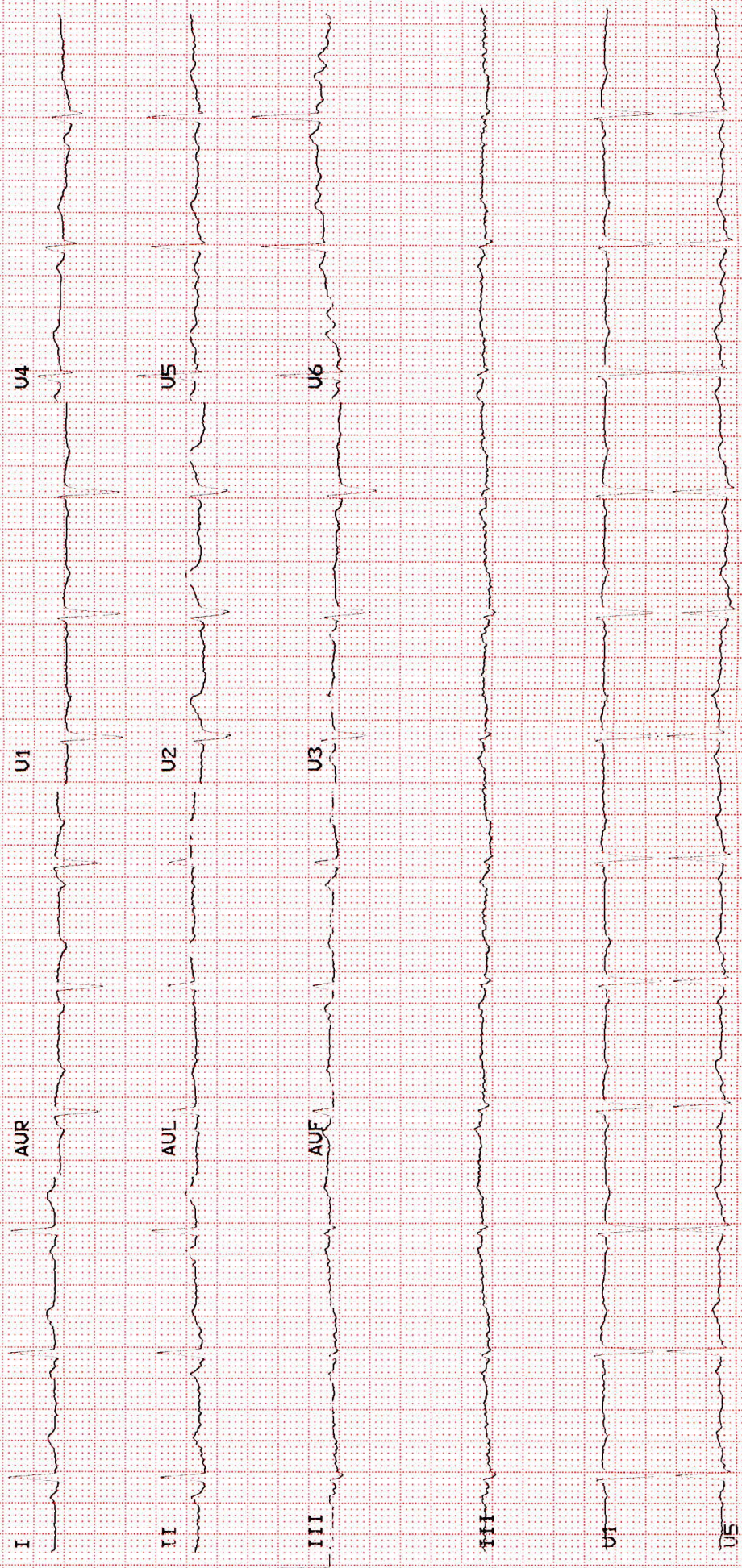
Interpretation:

normal ECG

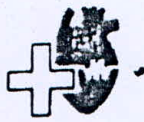Measurement Results:  
 QRS : 94 ms  
 QT/QTcB : 382 / 428 ms  
 PR : 142 ms  
 P : 110 ms  
 RR/PP : 796 / 790 ms  
 P/QRS/T : 55/ 25/ 30 degrees  
 QTd/QTcBD : 70 / 78 ms  
 Sokolow : 1.9 mV  
 NK : 10



Unconfirmed report







we treat...HE CURES

# Metro Hospital & Heart Institute

(A unit of Sunhill Hospital Private Limited)

OPD CONSULTATION

Patient Name Mrs. Vardai Shah Age/Sex 42 Card No.           

Doctor's Name Dr. Sushil Kumar

Date 22-3-23 Time           

## OPHTHALMIC EXAMINATION

### VISION

#### DISTANCE VISION-

Rt 6/6  
Lt 6/6 0 class.

#### NEAR VISION-

Rt N/6  
Lt N/6 0 class.

#### COLOUR VISION


Normal

### EYE EXAMINATION

Cornea  
Ant Chamber  
Pupil  
Fundus Examination

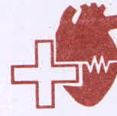Normal

ADVICE-





*Medicined  
(B/A)*



**METRO**  
HOSPITAL & HEART INSTITUTE  
(A unit of Sunhill Hospitals Private Limited)  
(NABH & ISO 9001: 2008 Certified)

## Radiology Investigation Report

Name : Mrs. VARDAI SHAH  
Ref. By : Dr. ANIL SINGH  
IP/OP : OP/202230239  
Date : 22/03/2023

Age/Sex : 42 Y/F  
UHID NO : 2023004849  
Request No : 70223376

### USG WHOLE ABDOMEN

The diaphragm is normal in contour & respiratory excursion. There is no ascitis or lymph node mass.

Liver is normal in shape, outline & echotexture. No focal lesion of abnormal ecogenecity is seen. Intrahepat biliary radicles are not dilated. Portal vein & portal venous radicles are normal.

Gall bladder is well distended, its outlines are smooth & its wall are not thick. No calculus /mass lesion is see in its lumen. Common bile duct is normal in course & caliber. No calculus is seen in its lumen.


Spleen & pancreas appears normal in shape, size, outline & echotexture.

Both the kidneys are normal in shape, size, outline & echotexture. Renal parenchymal thickness is norma Corticomedullary junction is defined & is normal. There is no hydronephrosis. **There are multiple B/L renal calculus largest measuring approx 5.3 mm seen in right kidney and 6 mm seen in left kidney.**

Urinary bladder is normal in contour & capacity. Bladder wall is not thick. No pathological filling defect / vesic calculus is seen in bladder. Ureterovesical junctions appear normal.

**Retroverted uterus** .Uterus is normal in size shape, outline & echotexture. Myometrial & endometrial echoe are normal. No uterine mass is seen. Both the ovaries appear normal. There is no free fluid seen in cul de sac.

**IMPRESSION** : multiple B/L renal calculus.  
Retroverted uterus .

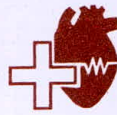

DR. PRAKASH CHANDRA PANDEY  
MBBS, DMRD  
CONSULTANT RADIOLOGIST

**Note:**

- (1) Not Valid for medical-legal purposes.
- (2) This is a professional opinion based on imaging finding and not the diagnosis.
- (3) In case of any discrepancy due to machine error or typing error, please get it rectified immediately.



**METRO****HOSPITAL & HEART INSTITUTE**

(A unit of Sunhill Hospitals Private Limited)

(NABH &amp; ISO 9001:2008 Certified)

**Radiology Investigation Report**

**Name** : Mrs. VARDAI SHAH  
**Ref. By** : Dr. ANIL SINGH  
**IP/OP** : OP/202230239  
**Date** : 22/03/2023

**Age/Sex** : 42 Y/F  
**UHID NO** : 2023004849  
**Request No** : 70223376

**X-RAY CHEST PA View**

*Trachea is central.*

*Bilateral hila are normal in size & density.*

*Cardiac silhouette is normal.*


*Bilateral lung fields are clear.*

*Bilateral Costophrenic angles are normal.*

*Bilateral domes of diaphragm are normal in position & contour.*

*Bones and soft tissues are normal.*

**IMPRESSION : Normal skiagram**



**DR. PRAKASH CHANDRA PANDEY**  
**MBBS, DMRD**  
**CONSULTANT RADIOLOGIST**

**Note:**

- (1) Not Valid for medical-legal purposes.
- (2) This is a professional opinion based on imaging finding and not the diagnosis.
- (3) In case of any discrepancy due to machine error or typing error, please get it rectified immediately.

Plot No. F-1, Sector-6A, SIDCUL, Haridwar - 249 403

Emergency : +91 8191902600, Phone : 01334 - 239040 / 42 / 43, Fax : 01334 - 239043

E-mail : metroharidwar@metrohospitals.com, Website: www.metrohospitals.com

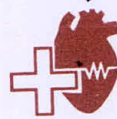Regd. Office : 21, Community Center, Preet Vihar, New Delhi-110092

CIN No.: U33201DL2006PTC156918

MHHI/CL/0115/Rev. No. 01

23-Mar-23 11:26 AM





## 2D ECHOCARDIOGRAPHY

Name:	Mrs. Vardai Shah	UHID No:	2023004846
Age/Sex:	42Y/F	Ward:	OPD
Referred by:	Dr. Anil Singh	Date:	22.03.2023

ACOUSTIC WINDOW: Normal

### MEASUREMENTS AND CALCULATIONS

Measurements	Observed Value	Reference Value
IVS (ED)	1.3	(0.6 – 1.1 cm)
LVPW (ED)	1.2	(0.6 – 1.1 cm)
LVID (ED)	3.9	Male (3.7 – 5.5 cm) Female (3.7 – 5.2 cm)
Aortic root diameter	2.4	(2.0 – 3.7 cm)
LA dimension	2.5	Male (1.9 – 4.0 cm) Female (1.7 – 3.8 cm)
LV EF	55%	(55 – 75%)

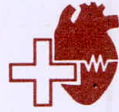### MORPHOLOGICAL DATA

Mitral valve	Normal	Right Atrium	Normal
Aortic valve	Normal	Right Ventricle	Normal
Tricuspid valve	Normal	PA	Normal
Pulmonary valve	Normal	IVS	Intact
		IAS	Intact

### DOPPLER STUDY

Valve	Regurges	Velocities (cm/s)	Gradients (mmHg)
Mitral	Trace	E – 78, A – 89, E/A < 1	
Aortic	Nil	Vel – 134	
Tricuspid	Mild	Vel – 261	PASP – 32
Pulmonary	Nil	Vel – 103	





# METRO

HOSPITAL & HEART INSTITUTE

(A unit of Sunhill Hospitals Private Limited)

(NABH & ISO 9001: 2008 Certified)

## FINAL IMPRESSION

- Normal Acoustic Window
- Normal Chambers Dimensions
- Mild concentric LVH
- No RWMA
- LVEF~55%
- Grade I LVDD
- Trace MR, Mild TR, PASP 32 mmHg
- No pericardial effusion
- No Intracardiac clot



### Dr. Krishna CK

MD, DNB (Medicine), DNB (Cardiology)  
Consultant Interventional Cardiology  
UKMC Reg. No: 12883

### Dr. Ajit Kumar

MBBS, PGDCC  
Associate Consultant, Cardiology  
UKMC Reg. No: 7569

*(Note: This document is not for medico-legal purpose)*

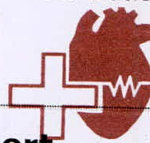Plot No. F-1, Sector-6A, SIDCUL, Haridwar - 249 403  
Emergency : +91 8191902600, Phone : 01334 - 239040 / 42 / 43, Fax : 01334 - 239043  
E-mail : metroharidwar@metrohospitals.com, Website: www.metrohospitals.com

Regd. Office : 21, Community Center, Preet Vihar, New Delhi-110092

CIN No.: U33201DL2006PTC156918

MHHI/CL/0115/Rev. No. 01





# METRO PATH LABS

(A unit of Sunhill Hospitals Private Limited)

## Pathology Report


Name : Mrs. VARDAI SHAH  
Ref. By : Dr. ANIL SINGH  
IP/OP : OP/202230239  
Sample Date : 22/03/2023  
Reporting Date: 22/03/2023

Age/Sex : 42 Y/F (ISO & NABH Certified)  
UHD : 2023004849  
Request No. : 10344272  
Sample Time : 09:57  
Reporting Time: 20:36

Test	Result	Unit	Bio. Ref. Inter. Test Method
<b>Biochemistry</b>			
HB1AC	5.7	%	4.5-6.3
BLOOD SUGAR -FASTING	78.0	mg/dl	70.0-110.0
<b>LIPID PROFILE</b>			
TOTAL CHOLESTEROL	156.0	mg/dl	00-250.0
HDL-CHOLESTEROL	46.0	mg/dl	00-50.0
LDL	93.0	mg/dl	00-150.0
TRIGLYCERIDES	83.0	md/dl	30-150
VLDL	17.0	mg/dl	0-50
CHOL/HDL Ratio	3.3		<4.5
<b>LFT (LIVER FUNCTION TEST)</b>			
BILIRUBIN INDIRECT	0.47	mg/dl	0.2-0.8
SGOT	24.0	U/L	10-42
SGPT	16.0	U/L	10-42
BIILIRUBIN TOTAL	0.97	mg/dl	0.2-1.0
ALKALINE PHOSPHATASE	67.0	IU/L	28-111
BILIRUBIN DIRECT	<b>0.50</b>	mg/dl	0.1-0.4
TOTAL PROTEIN	7.4	gm/dl	6.4-8.2
ALBUMIN	3.7	g/dl	3.5-5.0
GLOBULIN	3.7	gm/dl	2.0-4.0
AG RATIO	1.0		-
<b>KFT (KIDNEY FUNCTION TEST)</b>			
UREA	18.0	mg/dl	15-45
SODIUM	137.0	mmol/L	135-155
CREATININE	0.64	mg/dl	0.6-1.3
URIC ACID	4.1	mg/dl	3.0-7.6
BUN	8.0	mg/dl	05-20
POTTASSIUM	4.2	mmol/L	3.5-5.5
CALCIUM	9.4	mg/dl	8.5-10.5

\*\*\* End of Reports \*\*\*

Dr. Vishal Arora  
MBBS, DCP  
(Consultant Pathologist)



**Note:**

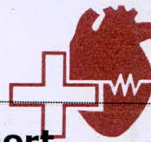
1. These reports are mere estimation of values at that particular time and are liable to vary/change in different conditions in different laboratories.
2. The values are to be collaborated with clinical findings by qualified doctor and any alarming and unexpected results should be reported to Lab urgently for recheck and manual typing errors.
3. These reports are not valid for medicolegal purposes and all doctor unsigned reports should be considered provisional only.
4. All card based tests are screening test therefore need confirmation by other alternative test like (PCR, ELISA)

Plot No. F-1, Sector-6A, SIDCUL, Haridwar - 249 403

Emergency : +91 8191902600, Phone : 01334 - 239040 / 42 / 43, Fax : 01334 - 239043

E-mail : metroharidwar@metrohospitals.com, Website: www.metrohospitals.com





# METRO PATH LABS

(A unit of Sunhill Hospitals Private Limited)

(ISO &amp; NABH Certified)

Name : Mrs. VARDAI SHAH  
Ref. By : Dr. ANIL SINGH  
IP/OP : OP/202230239  
Sample Date : 22/03/2023  
Reporting Date: 22/03/2023

Age/Sex : 42 Y / F  
UHID : 2023004849  
Request No. : 10344272  
Sample Time : 09:57  
Reporting Time: 20:36

Test	Result	Unit	Bio. Ref. Inter.	Test Method
------	--------	------	------------------	-------------

### Hematology

#### BLOOD GROUP

ABO	A	-		
Rh	POSITIVE	-		
ESR	20	mm/hr	20	

### Serology & Immunology

#### THYROID PROFILE

T3	2.79	nmol/L	1.70-3.10
T4	12.9	µg/dl	5.95-15.4
TSH	1.13	µIU/L	0.46-4.68

\*\*\* End of Reports \*\*\*

Dr. Vishal Arora  
MBBS, DCP  
(Consultant Pathologist)



#### Note:

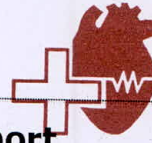
1. These reports are mere estimation of values at that particular time and are liable to vary/change in different conditions in different laboratories.
2. The values are to be collaborated with clinical findings by qualified doctor and any alarming and unexpected results should be reported to Lab urgently for recheck and manual typing errors.
3. These reports are not valid for medicolegal purposes and all doctor unsigned reports should be considered provisional only.
4. All card based tests are screening test therefore need confirmation by other alternative test like (PCR, ELISA).

Plot No. F-1, Sector-6A, SIDCUL, Haridwar - 249 403

Emergency : +91 8191902600, Phone : 01334 - 239040 / 42 / 43, Fax : 01334 - 239043

E-mail : metroharidwar@metrohospitals.com, Website: www.metrohospitals.com





# METRO PATH LABS

## Pathology Report

(A unit of Sunhill Hospitals Private Limited)

Name : Mrs. VARDAI SHAH  
 Ref. By : Dr. ANIL SINGH  
 IP/OP : OP/202230239  
 Sample Date : 22/03/2023  
 Reporting Date: 22/03/2023

Age/Sex : 42 Y/F (ISO & NABH Certified)  
 UHID : 2023004849  
 Request No. : 10344272  
 Sample Time : 09:57  
 Reporting Time: 20:36


Test	Result	Unit	Bio. Ref. Inter.	Test Method
------	--------	------	------------------	-------------

### Urine Examination

URINE SUGAR	NIL			
URINE ROUTINE ANALYSIS				
PHYSICAL EXAMINATION				
COLOUR	PALE			
TRANSPARENCY	YELLOW			
S. GRAVITY	CLEAR			
	1.025			
CHEMICAL EXAMINATION				
ALBUMIN	NIL			
SUGAR	NIL			
pH	6.0			
BLOOD	NIL			
KETONE	NIL			
MICROSCOPIC EXAMINATION				
PUS CELLS	2-3			
EPITHELIAL CELLS	3-4			
RBC	NIL			
CRYSTALS	NIL			
CAST	NIL			
BACTERIA	NIL			
AMORPHOUS PHOSPHATE	NIL			
AMORPHOUS URATES	NIL			

\*\*\* End of Reports \*\*\*

Dr. Vishal Arora  
 MBBS, DCP  
 (Consultant Pathologist)



**Note:**

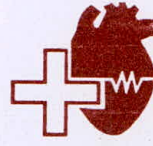
- These reports are mere estimation of values at that particular time and are liable to vary/change in different conditions in different laboratories.
- The values are to be collaborated with clinical findings by qualified doctor and any alarming and unexpected results should be reported to Lab urgently for recheck and manual typing errors.
- These reports are not valid for medicolegal purposes and all doctor unsigned reports should be considered provisional only.
- All card based tests are screening test therefore need confirmation by other alternative test like (PCR, ELISA).

Plot No. F-1, Sector-6A, SIDCUL, Haridwar - 249 403

Emergency : +91 8191902600, Phone : 01334 - 239040 / 42 / 43, Fax : 01334 - 239043

E-mail : metroharidwar@metrohospitals.com, Website: www.metrohospitals.com





# METRO PATH LABS

(A unit of Sunhill Hospitals Private Limited)

(ISO & NABH Certified)

CIN No.: U33201DL2006PTC156918

Patient Name : **Mr.VARDAI SHAH**  
DOB/Age/Gender : 42 Year's /male  
Pateint ID : M-12  
Referred By : **Dr.**

Sample Collected Date : Mar,22/2023  
Report Date : Mar,22/2023  
Report Time : 08:50 PM

Test Description	Value(S)	Unit(S)	Refrence Range
<b>Complete Blood Count &amp;:{C.B.C.} HAEMATOLOGY</b>			
Hemoglobin:-	9.4	mg/dl	12.5---16.5
T L C:-	5.070	Cells/cumm	4.000—11.000
D L C:-			
Neutrophils:-	58.7	%	45 - 75
Lymphocytes:-	32.5	%	25 - 45
Eosinophils:-	6.5	%	1 - 6
Monocytes:-	2.30	%	2 - 8
Basophils:-	0.00	%	—<2
RED BLOOD CELLS Count:R.B.C:	3.91	Million/cu/mm	3.5 - 5.5
PACKED CELL VOLUME (HCT) P.C.V	32.5	%	36 - 52
MEAN CELLS VOLUME:(M.C.V):	82.4	fl	80 - 100
MEAN CELLS HEMOGLOBIN:M.C.H	23.5	pg	27 - 32
MEAN CELLS HEMGRAM CONCENTRATION:-M.C.H.C; 31.4		gm/dl	31 - 37
PLATELETS COUNT:-	2.77	Lakh/cu mm	1.50 - 4.50
RDW:-	16.6	%	11.5 - 15.0

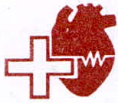
\*\*\*End Of Report\*\*\*

Plot No. F-1, Sector-6A, SIDCUL, Haridwar - 249 403

Emergency : +91 8191902600, Phone : 01334 - 239040 / 42 / 43, Fax : 01334 - 239043

E-mail : metroharidwar@metrohospitals.com, Website: www.metrohospitals.com





# METRO HOSPITAL & HEART INSTITUTE

(A unit of Sunhill Hospitals Private Limited)

CIN No.: U33201DL2006PTC156918

## OPD INITIAL ASSESSMENT



Dr. Name Dr. Sameer Raw  
 OPD TIMINGS \_\_\_\_\_  
 Regn. No. \_\_\_\_\_  
 Tel. No. +91-81919 02600

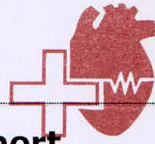NAME OF PATIENT Ms. Vandana Shel AGE/SEX 42y  
 ID NO. \_\_\_\_\_ DATE / IN TIME 24/3/23

PRESENT COMPLAINT :	INVESTIGATION / TREATMENT / PREVENTIVE CARE / NUTRITION ADVISED
<p><u>Booked for routine health checkup</u></p> <p><u>Pare, (CVD)</u></p> <p><u>Inc @; no gynae issue</u></p>	<p><u>WP: 19/3/23.</u></p>
<p>PAST HISTORY: <u>Tap smear done</u></p>	
<p>FAMILY HISTORY: <u>Uncle with MS &amp; 1<sup>st</sup> D</u></p>	<p><u>Acute leucocytometry</u></p>
<p>EXAMINATION: <u>bc breast @</u></p>	<p><u>No gynecological issue,</u>  <u>patient apparently fit for</u>  <u>gynae part of need</u></p>
<p>DIAGNOSIS :</p> <p>DRUG ALLERGY :</p>	<p>(DOCTOR SIGNATURE) <u>[Signature]</u></p> <p>OUT TIME</p>
<p>FOR OPD APPOINTMENT : +91-1334-6666 60, 2390 40, 42, 43</p>	<p>Next Followup:</p>

**NUTRITIONAL SCREENING:**  Wt. Loss  Loss Of Appetite  Muscle Wasting  Delay Wound Healing  Lethargy  Decrease Mobility

**Pain scale** 0. NO PAIN 02 Mild Pain 04 Annoying Pain 06 Moderate Pain 08 Severe Pain 10 Worst Pain





# METRO PATH LABS

(A unit of Sunhill Hospitals Private Limited)

## Pathology Report

Name : Mrs. VARDAI SHAH  
Ref. By : Dr. ANIL SINGH  
IP/OP : OP/220033768  
Sample Date : 24/03/2023  
Reporting Date: 28/03/2023

Age/Sex : 42 Y/F (ISO & NABH Certified)  
UHIP : 2023004849  
Request No. : 10344563  
Sample Time : 13:52  
Reporting Time: 15:39

Test	Result	Unit	Bio. Ref. Inter.	Test Method
------	--------	------	------------------	-------------

### Cytology


#### PAP SMEAR


Microscopy:- Smear are cellular and predominantly shows superficial and intermediate squamous epithelial cells. Few endocervical cell cluster seen.

Background shows RBCs and few polymorphonuclear inflammatory cells. No fungus, parasite granuloma or atypical cell seen.

Imp:-PAP smear are negative for intraepithelial cell lesion as malignancy.

\*\*\* End of Reports \*\*\*

  
Dr. Vishal Arora  
MBBS, DCP  
(Consultant Pathologist)



#### Note:

1. These reports are mere estimation of values at that particular time and are liable to vary/change in different conditions in different laboratories.
2. The values are to be collaborated with clinical findings by qualified doctor and any alarming and unexpected results should be reported to Lab urgently for recheck and manual typing errors.
3. These reports are not valid for medicolegal purposes and all doctor unsigned reports should be considered provisional only.
4. All card based tests are screening test therefore need confirmation by other alternative test like (PCR, ELISA).

Plot No. F-1, Sector-6A, SIDCUL, Haridwar - 249 403

Emergency : +91 8191902600, Phone : 01334 - 239040 / 42 / 43, Fax : 01334 - 239043

E-mail : metroharidwar@metrohospitals.com, Website: www.metrohospitals.com