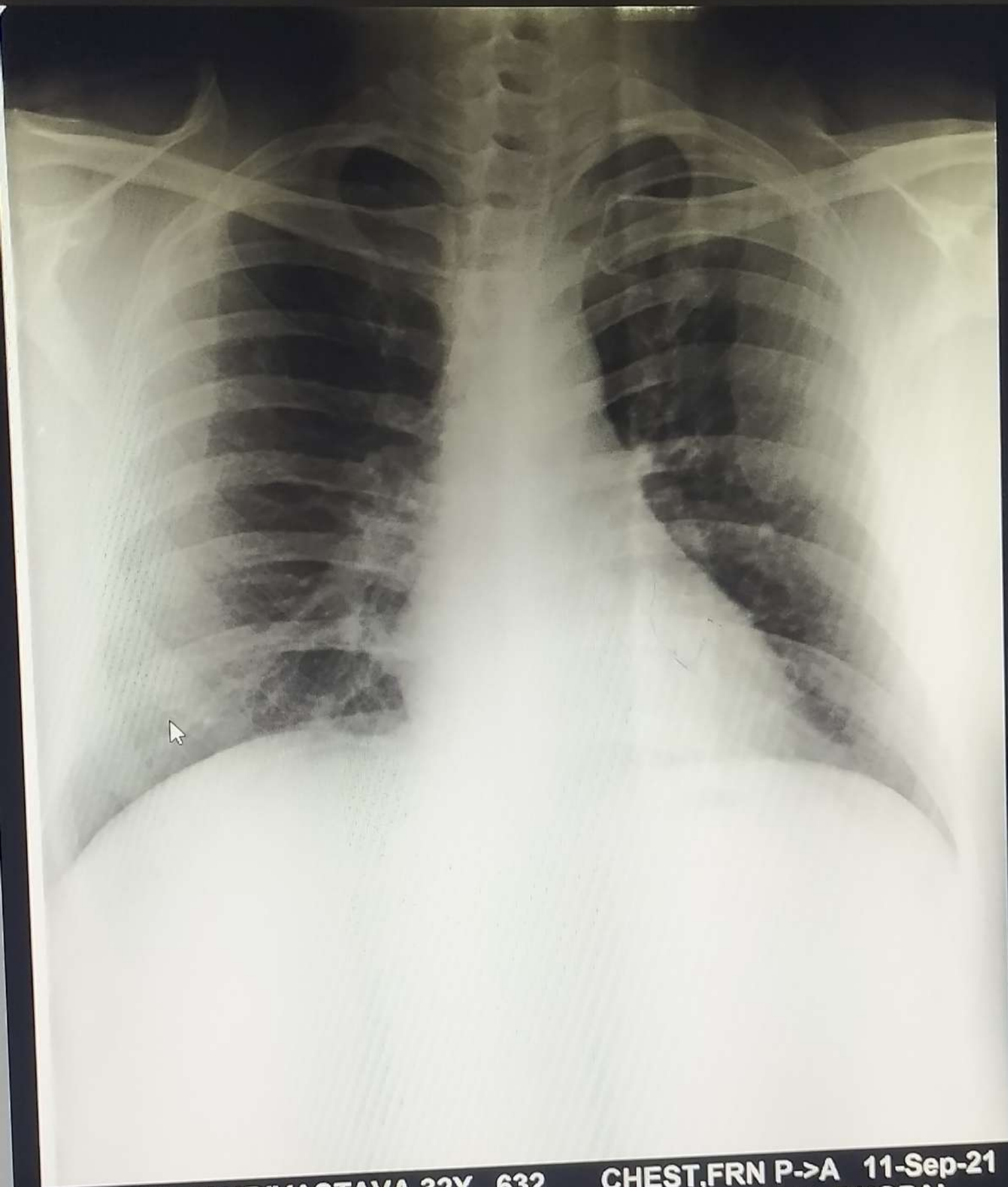

MR ANKIT SHRIVASTAVA 32Y 632 CHEST,FRN P->A 11-Sep-21
DIWAKAR DIAGNOSTIC CENTRE , ARERA COLONY ,BHOPAL

डिवाकर डायग्नोस्टिक सेंटर



E-7/636, पंजाब नेशनल बैंक के पास, मॉन रोड, अरुण कॉलोनी थोपाल (म.प्र.)

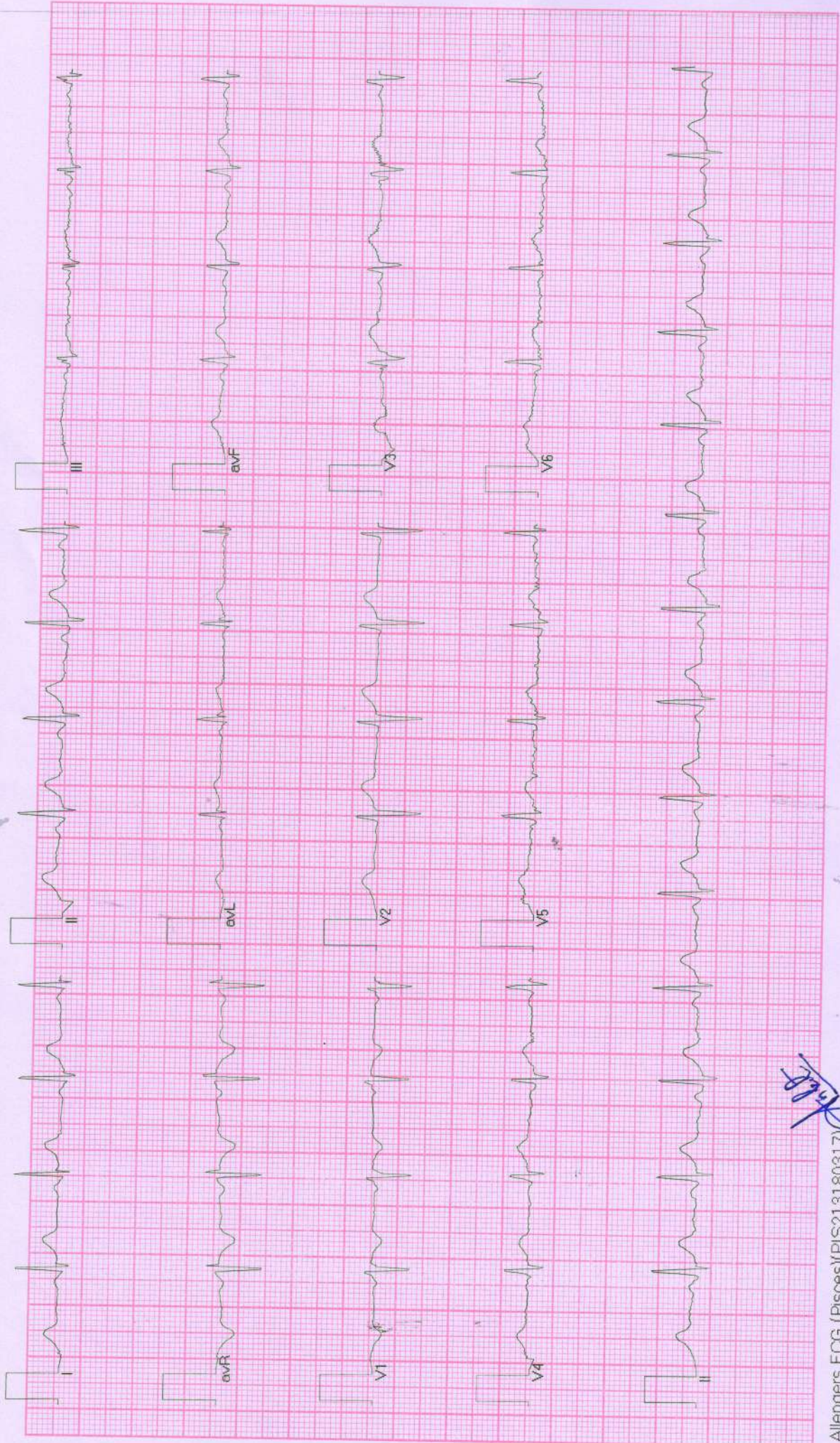
फोन: 0755-2464288, मो: 9826340190

Dr. B. M. Agarwal
MBBS, DCP
Consultant Pathologist



Allengers Global Healthcare Pvt Ltd.,
74 / MR. ANKIT SHRIVASTAVA / 32 Yrs / M / 172Cms. / 89Kgs.
Heart Rate : 84 bpm / Tested On : 11-Sep-21 15:29:00 / HF 0.05 Hz - LF 100 Hz / Notch 50 Hz / Sn 1.00 Cm/mV / Sw 25 mm/s
/ Refd By : BOB

ECG



BPL-DYNATRAC

[Handwritten signature]

डिवाकर डायग्नोस्टिक सेंटर



E-7/636, पंजाब नेशनल बैंक के पास, धन रोड, अंता कॉलोनी थापाल (म.प्र.)

फोन: 0755-2464288, मो: 9826340190

Pt Name :- Mr. Ankit Shrivastava
 Age :- 32/M
 Lab. No. :- 106
 Date :- 11/09/2021

EXAMINATION OF BLOOD

TEST	RESULT	NORMAL VALUE
Haemoglobin	14.8gms%	Female 12-16gms%, Male 14-18gms%
Red Cell count	4.8	4.5-5.6 million/cumm
Platelet Count	2.30	1.5-5.6 Lac/cumm
Leucocytes per.cumm	6200/cumm	5000-11000/cumm
Neutrophils	60%	50-70%
Lymphocytes	35%	20-40%
Eosinophils	03%	0-7%
Monocytes	02%	2-8%
PCV	44.0	37-47
MCV	87.0	76-96
MCH	29.0	27-32
MCHC	32.7	31-35
ESR	08	Male 0-9, Female 0-20mm/HR
Blood Group	"O" Positive	By slide method
Total Serum Cholesterol	170.0	100-250 mg%
Serum Triglyceride	130.0	Up to 150 mg%
Serum Cholesterol HDL	47.0	Up to 65 mg%
Serum Cholesterol LDL	97.0	Up to 125 mg%
VLDL	26.0	Up to 30 mg%
HDL/LDL Ratio	3.62	Below 5
S.Bilirubin(Total)	0.9	0.2-1.0mg/dl
Direct	0.5	0.0-0.25mg/dl
Indirect	0.4	
S6OT	27.0	5-35U/L
S6PT	30.0	8-40U/L
Alk Phosphatase	8.7	3-13 KA units
S. Protein(Total)	7.0	6.0-8.0mg%
Albumin	4.9	3.7-5.3mg%
Globulin	2.4	1.5 to 3.5 mg%
Blood Urea	21.0	Up to 40 mg%
S.Creatine	0.91	0.5-1.4mg/dl
S. Uric Acid	5.4	3.5-7.5mg%
G6TP	22.0	5-35 UL/dl
Fasting Blood Sugar	84.0	Up to 110 mg%
PP Blood Sugar	110.0	Up to 125 mg%
Glycosylated Hemoglobin	5.5	Below - 6.0 % -Non Diabetic control 6-7 % -Excellent control Above- 8 % -Poor control
Thyrod Stimulating Hormone(TSH)	3.7	0.27-4.2

Dr. B. M. Agarwal
 MBBS, DCP
 Consultant Pathologist





Pt Name :	Mr. Ankit Shrivatava
Age :	32/M
Lab. No. :	106
Date :	11/09/2021

EXAMINATION OF BLOOD

TEST	RESULT	NORMAL VALUE
PSA	4.11 ng/ml.	0.21-6.77 ng/ml.

Dr. B. M. Agarwal
 Pathologist
 MBBS, DCR



All test have technical limitation. Collaborative clinic pathological interpretation is mandatory. In case of disparity test may be repeated immediately. Typographic mistakes should be get correct instantly. This report is not valid for medico legal purpose

डिवाकर डायग्नोस्टिक सेंटर



E-7/636, पंजाब रेगनल बँक के पास, धन रोड, अरुण कॉलोनी भापाल (म.प्र.)

फोन: 0755-2464288, मो: 9826340190

Pt Name :- Mr. Ankit Shrivastava
Age :- 32/M
Lab. No. :- 106
Date :- 11/09/2021

URINE ANALYSIS

A. PHYSICALEXAMINATION	
1. Colour	Pale Yellow
2. Appearance	Clear
3. Specific Gravity	Q.N.S.
B. CHEMICAL EXAMINATION	
1. Reaction	Acidic
2. Albumin	Nil
3. Sugar	Nil
4. Bile Salts	Absent
C. MICROSCOPIEXAMINATION	
Pus Cells	2-3/HPF
R.B.C.	Nil
Epithelial Cell	2-3/HPF
Cast	Nil
Crystals(Cal.Oxa)	Nil
Bacteria	Nil
Amorphous	Nil
T. Vaginatis	Nil



Dr. B. M. Asarwal
Pathologist
Consultant Pathologist



Pt Name :	Mr. Ankit Shrivastava
Age :	32/M
Ref.By :	BOB
Lab.No. :	106
Date :	11/09/2021
Skigram	X Ray Chest PA View
Radiologist	Dr. B.M.Agarwal MD (Radiology)

REPORT

Tricia Central

Thoracic cage normal

Both Lungs Field Clear.

Both hilers normal

Cardiac border normal

Both cp angles clear

Both domes and diaphragm normal

IMPRESSION

-NO CARDIO PULMONARY PATHOLOGY
-COORRELATE WITH CLINICAL FINDINGS.



Dr. B. M. Agarwal
MD Radiology
Consultant Radiologist

PTO

Right kidney is normal in size, shape and position. Corticomedullary differentiation (CMD) is well maintained. Normal cortical thickness is noted. No E/O hydronephrosis or calculus is noted.

No evidence of free fluid is noted.

No evidence of lymphadenopathy is noted.

IVC and aorta appear to be normal.

Spleen is normal in size and echo texture.

Pancreas appear normal in size, shape and echo texture with smooth contour. No peripancreatic pathology seen. (Not seen due to gases)

Gall Bladder is physiologically well distended. No. E/O echogenic foci in GB lumen. GB wall is normal / thickened. No E/O pericholecystic collection. Common duct reveals normal course and caliber.

Liver appears normal in size and shape with normal outline. Normal/ increased parenchymal echogenicity is noted. No E/O focal lesion/ IHBV dilatation is seen. Hepatic veins and portal veins appear normal. *RL 14 cm*

No E/O subdiaphragmatic collection.

WHOLE ABDOMEN ULTRASOUND REPORT

Indication:

Name: Mrs. Ankit Shirasdekar
R/B: Health Checkup
Date: 11/9/21
Age: 32 YRS./F

34, पंतल, मॉडर्न अदिति आर्कड, शाहपुरा मस्जिद के पास
भरत नगर रोड, ई-7/194, अररा कॉलोनी, भोपाल - 462038
Mob.: 8989649694, 9516333619
Clinic Registration : CL/5392/Jun/2017
PNDT Registration : MPPCPNDT/BPL/2017/206



Advised clinical Correlation.

Impression: ~~Normal study~~ Mild hepatomegaly with fatty liver grade II & left renal cyst 2.3 cm. Rest normal.

Left Kidney is normal is size, shape and position. CMD is well maintained. Normal cortical thickness is noted. No E/O hydronephrosis or calculus is noted. Left simple cyst of 2.3 cm near upper pole.

Urinary Bladder is well distended (physiological), its contents are echo free. No E/O bladder wall thickening is noted. Post-void residue is insignificant.

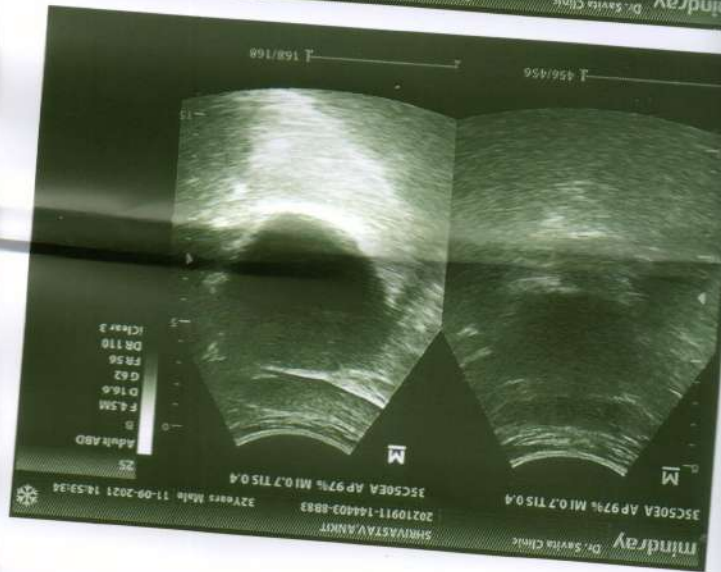
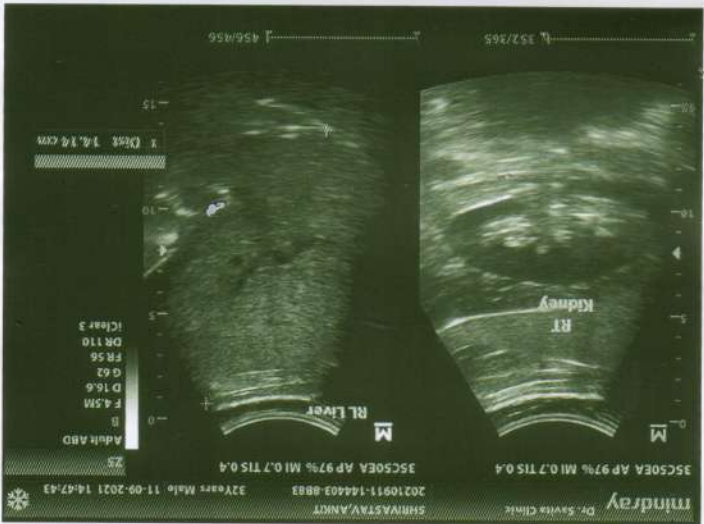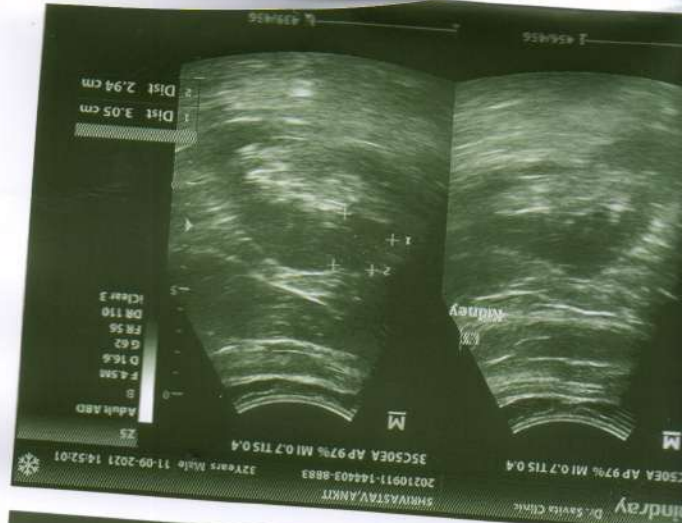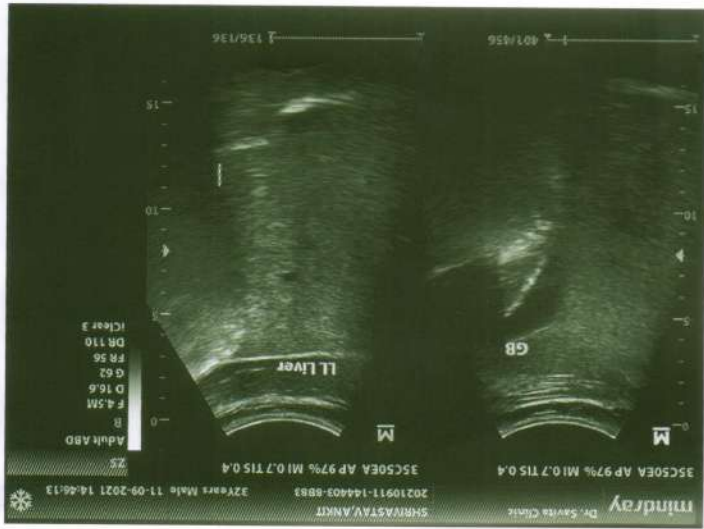
Prostate is normal in size. Shape and echo texture with smooth outline. No E/O focal lesion is noted.

Uterus is ante/ retro verted and normal in size/shape and echo texture with smooth outline. No E/O focal lesion is noted. Endometrial echo appear normal. Cervical and vaginal shadows appear normal.

Right Ovary appears enlarged / Normal in size, shape and echo texture.

Left Ovary appears enlarged / Normal in size, shape and echo texture.





Diwakar Diagnostic Centre
E-7/636, Arera Colony, Bhopal

360 / MR. ANKIT SHRIVASTAVA / 32 Yrs / M / 172 Cms / 89 Kg Date: 11-Sep-2021 Refd By : BOB

Report

(GEM213180307)(R)Allengers

ACCPDL

Report :

TEST OBJECTIVE	: ROUTINE CHECK UP
RISK FACTOR	: MALE
ACTIVITY	: MODERATE ACTIVE
OTHER INVESTIGATION	: ROUTINE BLOOD INVESTIGATION, X RAY
REASON FOR TERMINATION	: FATIGUE, HEART RATE ACHIEVED
EXERCISE TOLERANCE	: FAIR
EXERCISE INDUCED ARRHYTHMIAS	: NO
HAEMODYNAMIC RESPONSE	: NORMAL
CHRONOTROPIC RESPONSE	: NORMAL
FINAL IMPRESSION	: STRESS TEST IS NEGATIVE FOR EXERCISE INDUCED ISCHAEMIC HEART DISEASE

Ankit



Doctor : Cardiologist

360 / MR. ANKIT SHRIVASTAVA / 32 Yrs / M / 172 Cms / 89 Kg Date: 11-Sep-2021 Refd By : BOB

(GEM213180307)(R)Allengers

Stage	Time	Duration	Belt Speed (mph)	Elevation	METs	Rate	% THR Achieved	BP	RPP	PVC	Comments
Supine	00:13	0:01	00.0	00.0	01.0	93	49 %	120/80	111	00	
Standing	00:27	0:01	00.0	00.0	01.0	113	60 %	120/80	135	00	
HV	00:39	0:01	00.0	00.0	01.0	085	45 %	120/80	102	00	
Warm Up	00:52	0:04	01.7	10.0	01.1	103	55 %	120/80	123	00	
ExStart	00:54	0:06	01.7	10.0	01.1	103	55 %	120/80	123	00	
BRUCE Stage 1	03:54	3:00	01.7	10.0	04.7	153	81 %	130/90	198	00	
PeakEx	05:19	1:25	02.5	12.0	05.8	172	91 %	130/90	223	00	
Recovery	06:18	1:00	00.0	00.0	01.0	129	69 %	130/90	167	00	
Recovery	07:18	2:00	00.0	00.0	01.0	117	62 %	120/80	140	00	
Recovery	07:45	2:26	00.0	00.0	01.0	109	58 %	120/80	130	00	

Findings :

Exercise Time : 04:26
 Max HR Attained : 172 bpm 91% of Target 188
 Max BP Attained : (Sys) 130/90
 Max WorkLoad Attained : 5.8 Fair response to induced stress
 Test End Reasons : Fatigue, Heart Rate Achieved

Doctor : Cardiologist

Diwakar Diagnostic Centre

360 / MR ANKIT SHRIVASTAVA / 32 Yrs / M / 172 Cms / 89 Kg / HR : 98

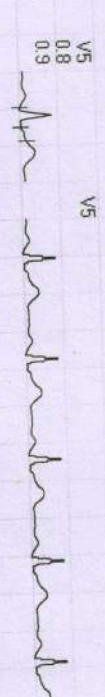
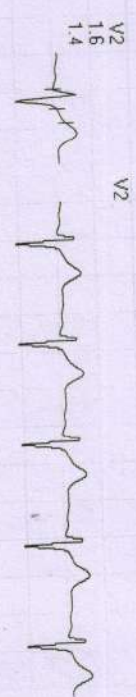
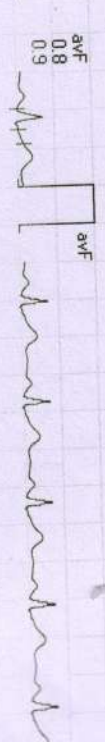

Date: 11-Sep-2021 03:29:52 PM METS: 1.0/ 93 bpm 49% of THR BP: 120/80 mmHg Raw ECG/ BIC On/ Notch On/ HF 0.05 Hz/LF 20 Hz

EXTime: 00:12 0.0 mph, 0.0%
25 mm/Sec 1.0 Cm/mV

SUPINE

AGIPDL

4X 80 mS Post J




REMARKS:
II aVR aVF V2 V4 V6

360 / MR. ANKIT SHRIVASTAVA / 32 Yrs / M / 172 Cms / 89 Kg / HR : 113

Date: 11-Sep-2021 03:29:52 PM METS: 1.0/113 bpm 60% of THR BP: 120/80 mmHg Raw ECG/ BLC On/ Notch On/ HF 0.05 Hz/LF 20 Hz

4X 80 ms Post J

EXTime: 00:26 0.0 mph, 0.0%
25 mm/Sec 1.0 Cm/mV



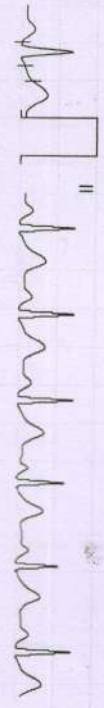
I
STL 1.0
STS 1.0




V1
-0.1
-0.6



II
1.5
1.3



V2
1.2
1.1



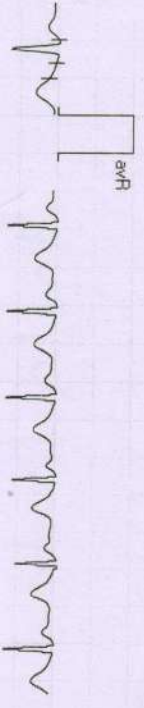
III
0.4
0.3



V3
1.4
1.1




aVR
-1.2
-1.1



V4
1.2
1.2



aVL
0.3
0.3



V5
0.8
0.8



aVF
1.0
0.8



V6
0.7
0.7



REMARKS:
II aVR aVF V2 V4 V6



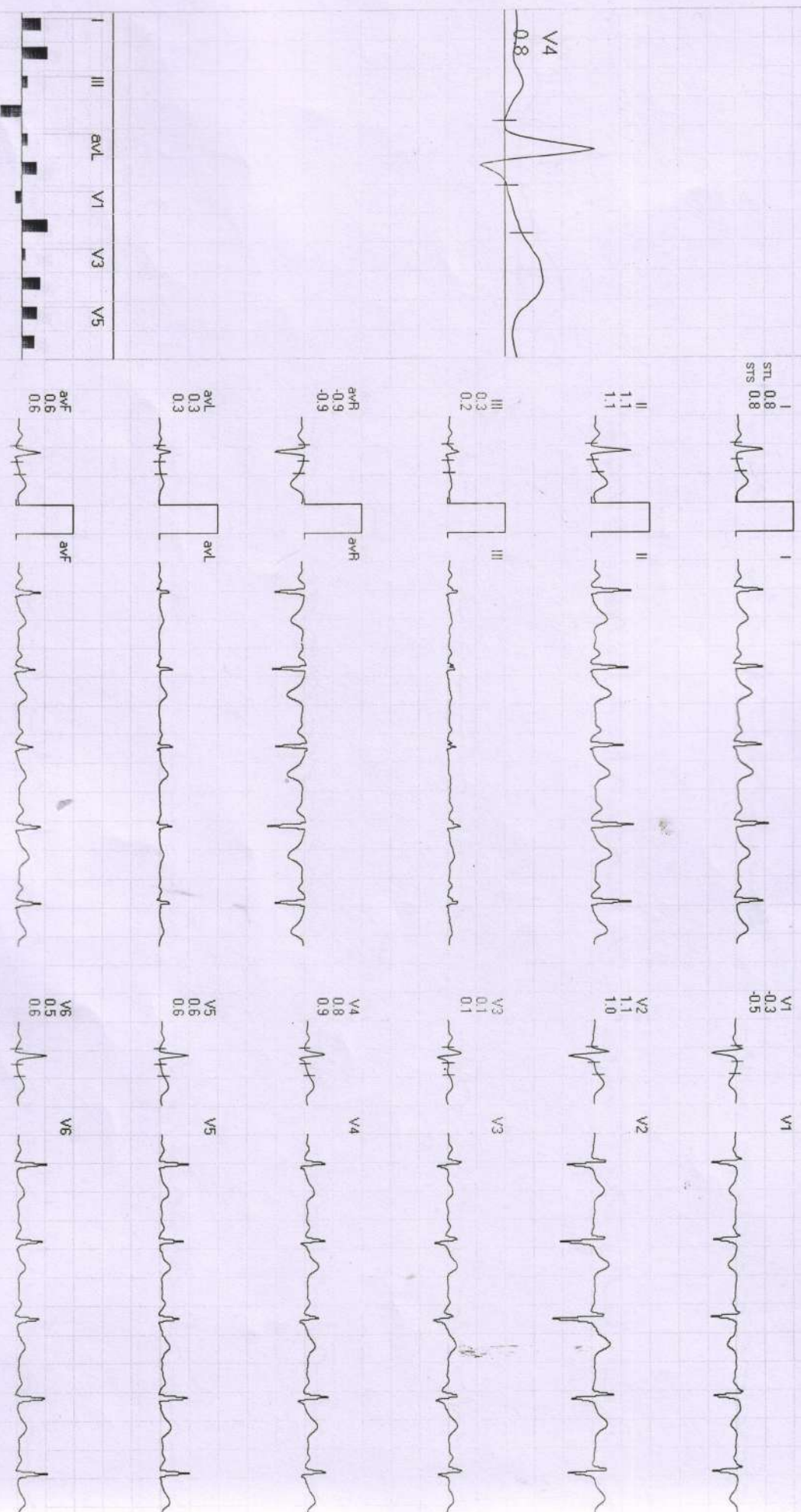
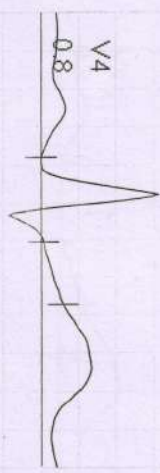
360 / MR. ANKIT SHRIVASTAVA / 32 Yrs / M / 172 Cms / 89 Kg / HR : 85

Date: 11-Sep-2021 09:29:52 PM METS: 1.0/85 bpm 45% of THR BP: 120/80 mmHg Raw ECG/BLC On/ Notch On/ HF 0.05 Hz/LF 20 Hz

ExTime: 00:38 0.0 mph 0.0%

4X 80 mS Post J

25 mm/Sec. 1.0 Cm/mV



REMARKS:
I III aVL V1 V3 V5
II aVR aVF V2 V4 V6



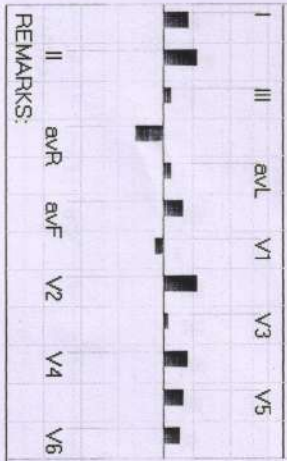
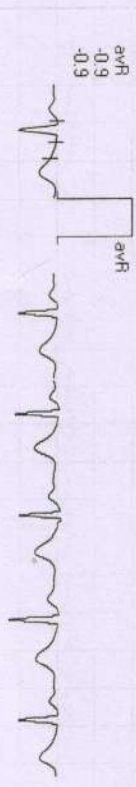
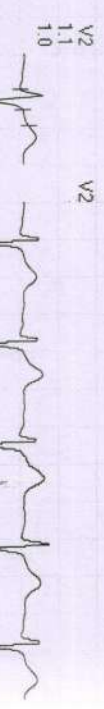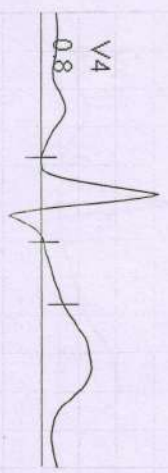
360 / MR. ANKIT SHRIVASTAVA / 32 Yrs / M / 172 Cms / 89 Kg / HR : 85

Date: 11-Sep-2021 09:29:52 PM METS: 1.0/85 bpm 45% of THR BP: 120/80 mmHg Raw ECG/BLC On/ Natch On/ HF 0.05 Hz/LF 20 Hz

ExTime: 00:38 0.0 mph 0.0%

4X 80 mS Post J

25 mm/Sec. 1.0 Cm/mV



REMARKS:

360 / MR. ANKIT SHRIVASTAVA / 32 Yrs / M / 172 Cms / 89 Kg / HR : 108

Date: 11-Sep-2021 03:29:52 PM

METS: 1.0 / 103 bpm 54% of THR

BP: 120/80 mmHg

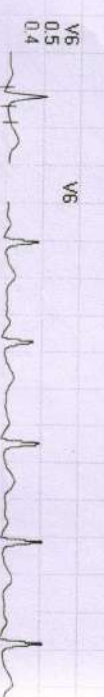
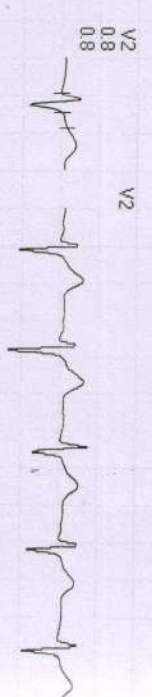
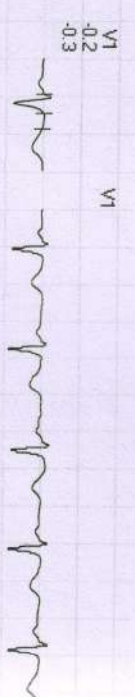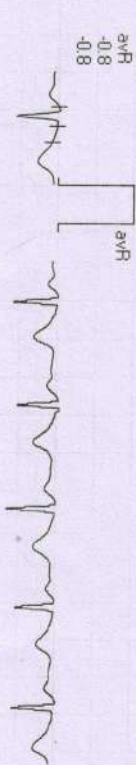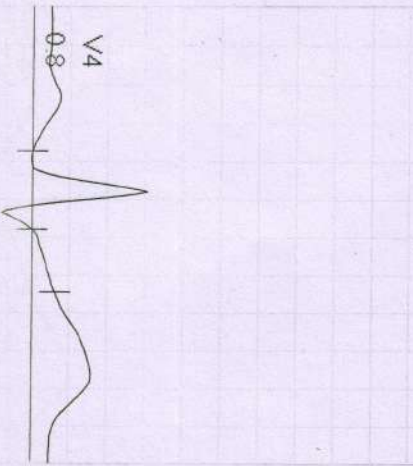
Raw ECG/BLC On/ Naich On/ HF 0.05 Hz/LF 20 Hz

ExTime: 00:51 1.0 mph, 0.0%

4X

80 mS Post J

25 mm/Sec 1.0 Cm/mV



I	III	aVL	V1	V3	V5
II	aVR	aVF	V2	V4	V6

STL 0.6	I	aVR	aVL
STS 0.6	II	-0.8	0.1
	III	0.4	0.1
	IV	0.3	
	V		
	VI		
	VII		
	VIII		
	IX		
	X		
	XI		
	XII		

V1	-0.2	V5	0.7
V2	-0.3	V6	0.7
V3	0.8		
V4	0.8		
V5	0.8		
V6	0.8		

REMARKS:


360 / MR. ANKIT SHRIVASTAVA / 32 Yrs / M / 172 Cms / 89 Kg / HR : 108

Date: 11-Sep-2021 03:29:52 PM METS: 1.0/ 103 bpm 54% of THR BP: 120/80 mmHg Raw ECG/BLC On/ Notch On/ HF 0.05 Hz/LF 20 Hz

ExTime: 00:00 0.0 mph, 0.0%

4X 80 ms Post J

25 mm/Sec. 1.0 Cm/mV



I
STL 0.6
STS 0.6



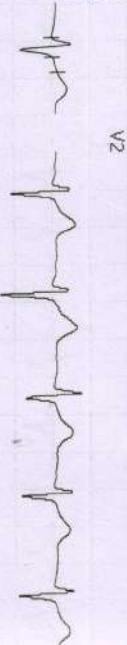
V1
-0.2
-0.3



II
1.1
1.0



V2
0.8
0.8
0.8



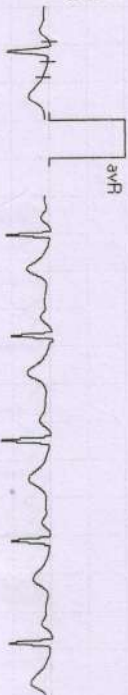III
0.4
0.4
0.3




V3
0.7
0.7
0.3



aVR
-0.8
-0.8



V4
0.8
0.8
0.9



aVL
0.1
0.1



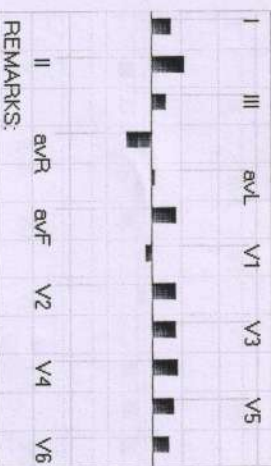
V5
0.7
0.7



aVF
0.8
0.8
0.7



V6
0.5
0.5
0.4



REMARKS:

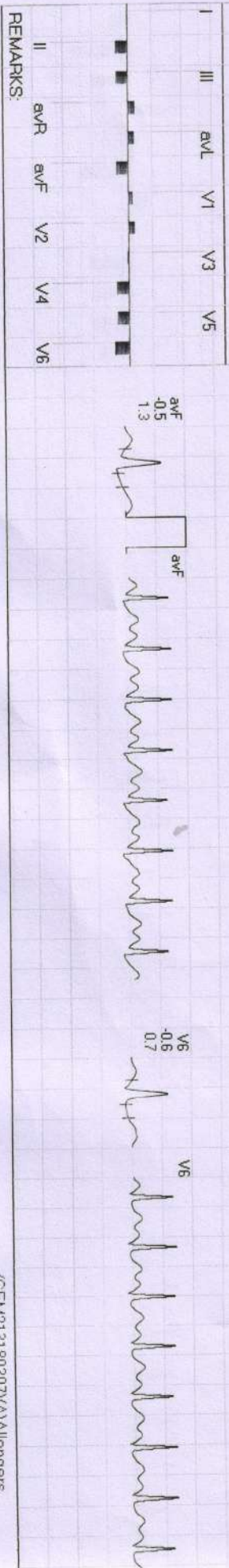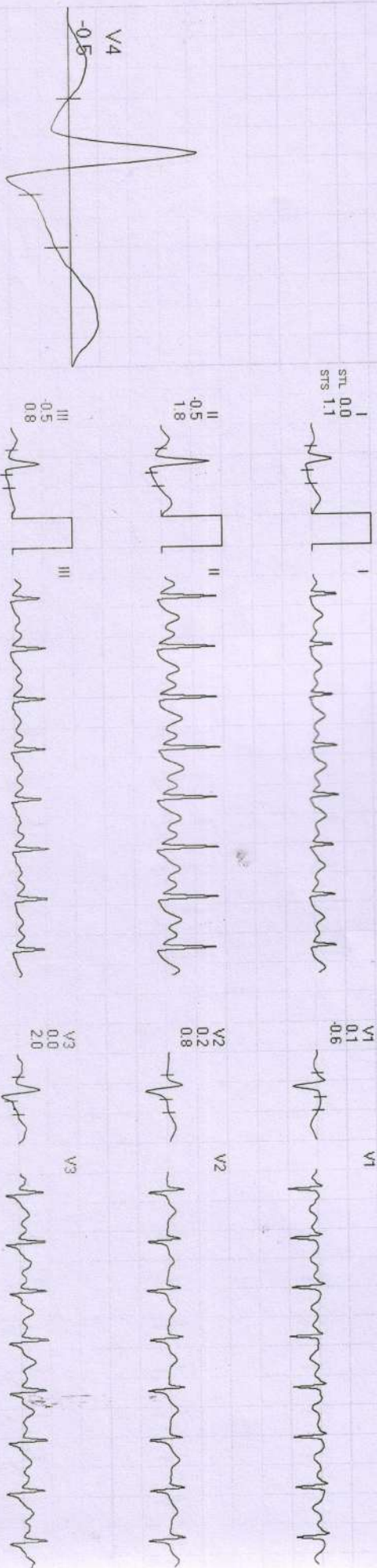
360 / MR. ANKIT SHRIVASTAVA / 32 Yrs / M / 172 Cms / 89 Kg / HR : 168

Date: 11-Sep-2021 03:29:52 PM METS: 4.7/153 bpm 81% of THR BP: 130/90 mmHg Raw ECG/ BLC On/ Natch On/ HF 0.05 Hz/LF 20 Hz

ExTime: 03:00 1.7 mph 10.0%

4X 60 ms Post J

25 mm/Sec. 1.0 Cm/mV



REMARKS:

Diwakar Diagnostic Centre


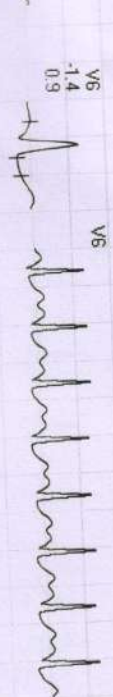


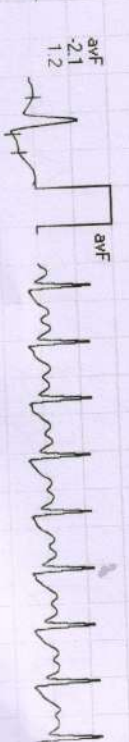

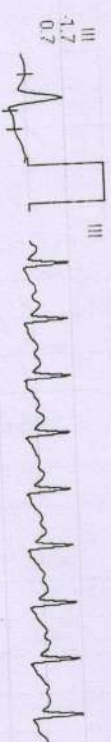


360 / MR. ANKIT SHRI VASTAVA / 32 Yrs / M / 172 Cms / 89 Kg / HR : 172

Date: 11-Sep-2021 03:29:52 PM METS: 5.8 / 172 bpm 91% of THR BP: 130/90 mmHg Raw ECG/BLC On/Notch On/ HF 0.05 Hz/LF 20 Hz

ExTime: 04:25 2.5 mph. 12.0%
25 mm/Sec. 1.0 Cm/Amv

PeakEx ACHPL

4X 60 ms Post J



REMARKS: