



THAREJA PHARMA

THAREJA CLINIC

Form with fields for patient information and medical notes, including a section for 'THAREJA CLINIC'.



SAROJ DEVI MEENA 56 Y BY DR M.N. THAREJA 34216.6 F CHEST, PA 12/10/2022
THAREJA NURSING HOME, COMPANY BAGH ROAD, ALWAR

 **भारत सरकार**
Government of India

 सरोज देवी मीना
Saroj Devi Meena
जन्म तिथि/ DOB: 30/07/1966
महिला / FEMALE



3008 0753 3011

मेरा आधार, मेरी पहचान



सरोज

 **भारतीय विशिष्ट पहचान प्राधिकरण**
Unique Identification Authority of India

पता:
W/O: देवकरण मीणा, ई-250,
अम्बेडकर नगर, अलवर, अलवर,
राजस्थान - 301001

Address:
W/O: Devkaran Meena, E-250,
Ambedkar Nagar, Alwar, Alwar,
Rajasthan - 301001

3008 0753 3011

 1967  help@uidai.gov.in  www.uidai.gov.in

Dr. M. N. THAREJA
MBBS
Thareja Nursing Home
Alwar-301001, (Raj.)



THAREJA NURSING HOME

1, Ram Kuteer Company Bagh Road, ALWAR - 301001 (Raj.)
Mob. 9982111801, Ph. 0144-2700184, 2331842, Telefax: 0144-2342339
E-mail: drmnthareja@yahoo.com



Name Saroj Devi Meena Age 56 Yr OPD/UHID..... Date 10-12-22
Address Mobile No. 94143 89936

VITALS	B.P.	Pulse	Temp.	Wt.	Ht.	Allergies
--------	------	-------	-------	-----	-----	-----------

Complaints

Pt. came for regular dental check-up.

Findings

*FPD 7654
Missing 6/6, CHA.*

Investigation

Treatment

Maintain. oral hygiene.

DR. M.N. THAREJA

7233 (RMC)
Male Infertility Specialist

DR. SAVITA THAREJA

7600 (RMC)
Female Infertility Specialist

DR. JAYANT THAREJA

A-0824 (RSDC)
M.D.S.
Oral & Maxillo - Facial Surgery
Ex Resident Trauma Centre,
AIIMS, Delhi

DR. SHIVANI THAREJA

10807 / 31220 (RMC)
Ophthalmologist
Cornea Specialist

DR. PRERNA THAREJA

A-3574
MDS (Endodontics)
Root Canal Specialist
Ex Resident
AIIMS, Jodhpur

DR. H.R. GUPTA

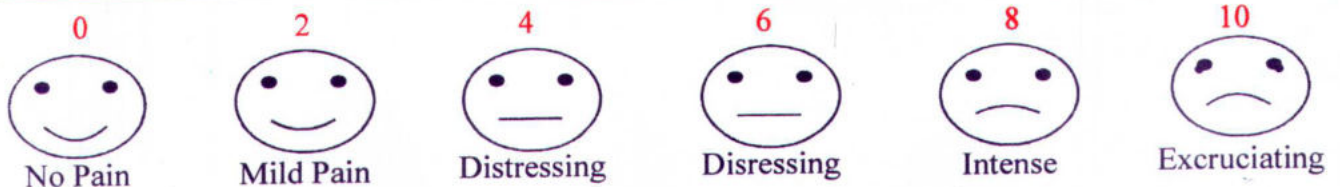
1744 (RMC)
Senior Consultant
M.S. Gen Surgeon

DR. VARUN SAPRA

Reg. No. 70990 (DMC)
MBBS DNB ORTHO, D.ORTHO
Joint Replacement &
Arthroscopy Surgeon

Dr. Prerna Thareja
MDS (Endodontics)
Diploma in Oral Implantology
Diploma in Hospital Administration
Ex Senior Resident AIIMS, Jodhpur
Life Member ICI A-3574

Pain Scale





THAREJA NURSING HOME

1, Ram Kuteer Company Bagh Road, ALWAR - 301001 (Raj.)
Mob. 9982111801, Ph. 0144-2700184, 2331842, Telefax: 0144-2342339
E-mail: drmnthareja@yahoo.com



Name Saroj Devi meena Age..... Yr OPD/UHID..... Date 10/12/22

Address Mobile No.....

VITALS	B.P.	Pulse	Temp.	Wt.	Ht.	Allergies
--------	------	-------	-------	-----	-----	-----------

Complaints Routine eye check-up

Findings
VA $\left\{ \begin{matrix} 6/9 \\ 6/9 \end{matrix} \right. = \text{glasses}$

Investigation
MA $\left\{ \begin{matrix} N6 \\ N6 \end{matrix} \right. = \text{glasses}$

Colour vision - B/E colour vision

Treatment with in normal limit

Adv.
① continue glasses.

DR. M.N. THAREJA
7233 (RMC)
Male Infertility Specialist

DR. SAVITA THAREJA
7600 (RMC)
Female Infertility Specialist

DR. JAYANT THAREJA
A-0824 (RSDC)
M.D.S.
Oral & Maxillo - Facial Surgery
Ex Resident Trauma Centre,
AIIMS, Delhi

DR. SHIVANI THAREJA
10807 / 31220 (RMC)
Ophthalmologist
Cornea Specialist

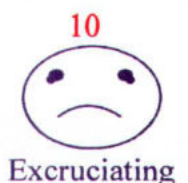
DR. PRERNA THAREJA
A-3574
MDS (Endodontics)
Root Canal Specialist
Ex Resident
AIIMS, Jodhpur

DR. H.R. GUPTA
1744 (RMC)
Senior Consultant
M.S. Gen Surgeon

DR. VARUN SAPRA
Reg. No. 70990 (DMC)
MBBS DNB ORTHO, D.ORTHO
Joint Replacement &
Arthroscopy Surgeon

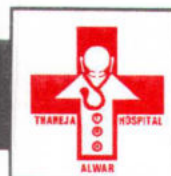Shivani
Dr. Shivani Thareja
M.S. (OPHTHAL)
Fellow (CORNEA)
L.V. Prasad Eye Institute
CORNEA CONSULTANT

Pain Scale





THAREJA NURSING HOME



DIGITAL X-RAY, OPG, COMPUTERISED ECG & EEG, DIAGNOSTIC LABORATORY EQUIPED WITH COMPUTERISED AUTO ANALYZER & CBC

1, Ram Kuteer, Company Bagh Road, ALWAR - 301001 (Raj.) Ph: 0144-2700184, 2331842

Name : **SAROJ DEVI MEENA** age **56** Sex : **FEMALE**
Ref. By : **M.N. THAREJA** Lab No. : Date : **December 10, 2022**

HORMONES & MARKERS

Test	Value	Units	Biological Ref. Values
T3 (Total Triiodothyronine)	1.12	ng/dL	0.60-1.81 ng/dL Adults
T4 (Total Thyroxine)	4.30	µg/dL	3.2-12.60 µg/dL : Adults
TSH (Thyroid Stimulating Hormone)	3.47	µIU/mL	Adults : 0.35-5.50 µIU/mL

Interpretation of TSH :-

Children

0 Days : 1.0~39.0 uIU/mL
5 days : 1.7~9.1 uIU/mL
1 year : 0.4~8.6 uIU/mL
2 years : 0.4~7.6 uIU/mL
3 years : 0.3~6.7 uIU/mL
4-19 years : 0.4~6.2 uIU/mL

Adults

20-54 years : 0.35-5.50 uIU/mL
55-87 years : 0.5-8.9 uIU/mL

Pregnancy

1st Trimester : 0.30 - 4.50 µIU/mL
2nd Trimester : 0.50 - 4.60 µIU/mL
3rd Trimester : 0.80 - 5.20 µIU/mL

Interpretation of TSH :-

Children

3.20 - 34.6 µIU/mL 1- 2 Days
0.70 - 15.4 µIU/mL 3 - 4 Days
0.70 - 9.10 µIU/mL 15 Days - 5 Months
0.70 - 6.40 µIU/mL 5 Months - 20 Years

Pregnancy

0.50 - 4.50 µIU/mL 1st Trimester
0.50 - 4.60 µIU/mL 2nd Trimester
0.80 - 5.20 µIU/mL 3rd Trimester

Method : **Fluorescence Immunoassay Technology**

Sample Type : **Fresh Blood Serum**

Remarks :

Primary malfunction of the Thyroid gland may result in excessive (hyper) or Low (hypo) release of T3 or T4. In addition, as TSH directly affect thyroid function, malfunction of the pituitary or the hypothalamus influences the thyroid gland activity.

Disease in any portion of the thyroid-pituitary-hypothalamus system may influence the level of T3 and T4 in the blood, in Primary Hypothyroidism,

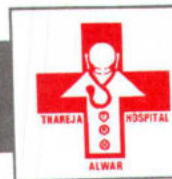TSH levels are significantly elevated, while in secondary and tertiary hypothyroidism, TSH levels may be low. In addition, in Euthyroid sick syndrome, multiple alterations in serum thyroid function test findings have been recognized.

Vijay
Signature of Technician

M.N. Thareja
Dr. M. N. THAREJA
Signature of Doctor
Thareja Nursing Home
Alwar-301001. (Raj.)



THAREJA NURSING HOME



DIGITAL X-RAY, OPG, COMPUTERISED ECG & EEG, DIAGNOSTIC LABORATORY EQUIPED WITH COMPUTERISED AUTO ANALYZER & CBC

1, Ram Kuteer, Company Bagh Road, ALWAR - 301001 (Raj.) Ph: 0144-2700184, 2331842

PROPOSAL NO. 155289

Patient Name SAROJ DEVI MEENA
Ref. By Dr. M. N. THAREJA

Date 10/12/2022
Age 56 Yrs.
Sex F

Details of packages		Patients report	Units	Normal value
HB		10.6	gm%	M-13.5-18, F-11.5-16.5
TRBC		4.65	million /cu mm	M-4.0-5.5, F-3.9-5.6
TWBC		8,800	cu mm	4000-11000
DLC	Polymorphs	56	%	42-75
	Lymphocytes	40	%	20-50
	Eosinophil	04	%	1-6
ESR		02	mm 1 st Hr.	M-0-9, F-0-20
Platelets		2,21,000	Lack / cu mm	1.5-4
PCV		32.9	%	37-54
MCV		70.8	Cubicmicrons	86-98
MCH		22.8	Picograms	26-34
MCHC		32.2	%	32-36
Blood Grouping & Rh Factor		" B "Rh+(POSITIVE)		
BUN		13.0	mg %	M-7-20
S. Creatinine		0.89	Mg/100ml	0.9-1.4 mg /100 ml
HBsAg		-		
HIV I & II		-	Elisa Method	
HbA1C		6.1	%	4-6%
VDRL		-		

Details of packages		Patients report	Units	Normal value
LFT	GGTP	20.0	U/L	5-60
	SGOT	23.0	Units / ml	Upto 40
	SGPT	24.0	Units / ml	Upto 40
S. Bilirubin	Total Bilirubin	0.63	mg%	Upto 1.2
	Direct Bilirubin	0.22	mg%	0-0.25
	Indirec Bilirubin	0.41	mg%	
	T. Protein	7.38	Gm%	6.2-8.3
	S. Albumin	4.26	Gm%	3.2-5.3
	Globulin	3.12	Gm%	
	Alkaline phosphate	102.0	IU/L	60 - 170
S. Calcium		-	Gm%	8.5-10.5
Uric Acid		3.8	Mg%	2.5-7 mg%
Blood Sugar Fasting		98.0	Mg%	60-110 mg %
Blood Sugar PP		136.0	Mg%	Upto 160
Lipid Profile	S. Cholesterol	210.0	mg%	120-220
	S. Triglycerides	130.0	mg/ml	Upto 170
	HDL Cholesterol	56.0	IU/L	
	LDL cholesterol	128.0	IU/L	450 at 37° C
	VLDL	26.0	mg %	Upto 35

Routine Urine Analysis

Physical/ Chemical	Microscopic:
Appearance	RBCs
Specific Gravity	WBCs
Ph	Epith. Cells
Albumin	Casts
Glucose F	Crystals
Ketones	Bacteria
Blood	Glucose P.P.

Signature of Technician

Signature of Doctor

This Report is not Valid for Medical Legal Purpose

Thareja Nursing Home - 301001, (Raj)



THAREJA NURSING HOME



DIGITAL X-RAY, OPG, COMPUTERISED ECG & EEG, DIAGNOSTIC
LABORATORY EQUIPED WITH COMPUTERISED AUTO ANALYZER & CBC

1, Ram Kuteer, Company Bagh Road, ALWAR - 301001 (Raj.) Ph: 0144-2700184, 2331842

PROPOSAL NO.

Patient Name SAROJ DEVI MEENA

Ref. By Dr. M. N. THAREJA

Date 10/12/2022


Age 56 Yrs.

Sex F

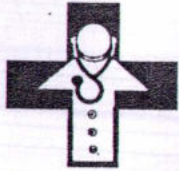PART - X-RAYED : X-RAY CHEST PA VIEW
REPORT : X-RAY CHEST P.A. VIEW
:- Chest is bilaterally symmetrical.
:- C.P. Angles are clear.

CONCLUSSION: NORMAL STUDY

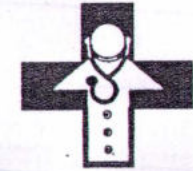
Signature of Technician


Dr. M. N. THAREJA
Signature of Doctor
WBBS
Thareja Nursing Home
Alwar-301001. (Raj.)

This Report is not Valid for Medical Legal Purpose



THAREJA CLINIC



1, Ram Kuteer Company Bagh Road, ALWAR (Raj.) ☎ 2700184, 2331842 (H)

POLY CLINIC EQUIPPED WITH COMPUTERISED AUTOANALYSER, CBC
SONOGRAPHY, X-RAY, OPG, COMPUTERISED ECG, EEG &
DIAGNOSTIC LABORATORY, COMPUTERISED LUNG FUNCTION TEST

DEADDICATION CENTRE

Dr. M.N. Thareja

M.B.B.S., F.C.G.P.

F.R.S.T.M. & H (London)

- ❖ Vice Chairperson of Sex Education & Parenthood International.
- ❖ Vice President of National Sexology Society of India
- ❖ Member of American Association of Sex Educator USA
- ❖ Executive Member of Indian Andro-Pause Society
- ❖ Life Member of Association for Prevention & Control of Rabies in India (APCRI)
- ❖ Life Member of Indian Red Cross Society
- ❖ Life Member of IMA College of General Practitioners
- ❖ Post Graduate Certificate Course of HIV/AIDS & STD Management Counsellor.
- ❖ Post Graduate Certificate Course Environmental & Occupational Health.

ELECTROCARDIOGRAM

Patient Name Saraj Devi Meena

Date 10-12-22 Age 56 Yr Sex F

Referred by Dr. M N Thareja

..... cm/ kg

10/12/22 mmHg

QRS	76 ms	S (V1)	-0.24 mV
QT	372 ms	R (V5)	0.93 mV
QTc	423 ms	Sokol.	1.36 mV

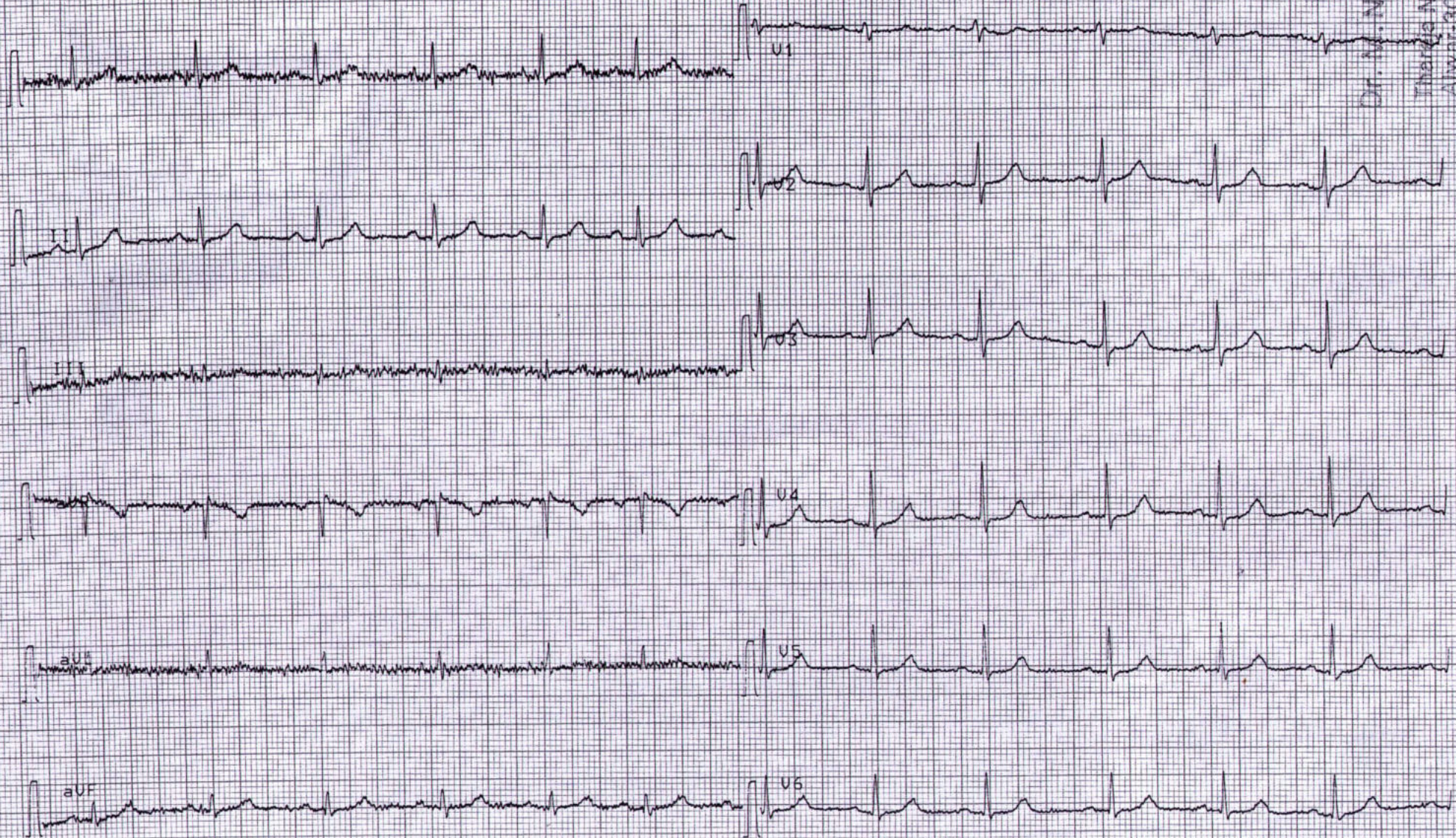
RAJY

MMVA

Dr. M. N. THARE
 MBBS
 Thare Nursing Home
 Alwar-301001, (Ra)

10 mm/mV

10 mm/mV



25 mm/s

0.05-35 Hz FS0 Sa 10-DEC-22 10:53:06

AT-2 C 3.03

SCHILLER

Part No.2.157017M CE 0123

S.BA



GUPTA ENT AND HEART CENTRE

Dayanand Marg, Nangli Circle, Alwar (Raj.) Ph. 0144-3591336 | M. 7378184427

Echocardiography Report

Name : Mrs. Saroj Devi Meena
Age / Sex : 56yrs./Female

Refd by: Dr. M. N. Thareja
Date : 10 December 2022

Clinical Diagnosis : For Cardiac Evaluation

2D Echocardiography Findings

Mitral Valve : Normal
Aortic Valve : Normal
Tricuspid Valve : Normal
Pulmonary Valve : Normal
Left Atrium : 3.4cm: Normal
Left Ventricle : Normal LV size with normal LV systolic function. No RWMA

LVIDd	3.5cm.	IVSd	0.9cm.	EF	60%	Visual
LVIDs	2.0cm.	PWd	0.9cm.	EF	%	F.S.

Right Atrium : Normal
Right Ventricle : Normal
Aorta : 2.4cm: Normal
Pulmonary Artery : Normal
Pulmonary Veins : Normal
Superior Venacava : Normal
Inferior Venacava : Normal
Pericardium : Normal
Intracardiac Masses : No Intracardiac masses seen
IAS/IVS : Intact

Doppler Findings:

Valve	Peak Velocity (cm/s)	Peak Gradient (mmHg)	Mean Gradient (mmHg)	Regurgitation Grade	others/comments
Mitral Valve	E-/A-87/63			No MR	
Aortic Valve	105				
Tricuspid Valve				Trace TR, No PAH.	
Pulmonary Valve	92				

Diagnosis : Transthoracic echo done in supine position at resting heart rate of 70bpm, shows **Normal LV size with normal LV systolic function. LVEF~60% (Visual). No RWMA.**
Other cardiac chambers are normal in Size.
No MR, Trace TR, No PAH.
Normal MIP.
No pericardial effusion /Vegetation /Clot Intracardiac masses seen.
Normal left sided arch of aorta, No Coarctation.

Dr. Prachi Gupta

MBBS, PGDCC

(Non-invasive cardiologist)

Gupta ENT and Heart Centre
Nangli Circle, Alwar

Please correlate clinically

This report is not valid for medico legal purpose.



MEHAR'S

SAHARA DIAGNOSTICS

Reg. No. NHM/434

Dr. R.D. Arora

M.D., D.M.R.E (Radio-dagnosis)

University Topper

R.M.C. Reg. No. 28052 & 009456

Mob.: 9829136035

The Healing Ashram, 12 Kailash Colony, Bhagat Singh Circle, Alwar

10 DEC 2022

NAME : smt SAROJ

Clinician: Dr. M N THAREJA

FOR : ABDOMEN

On history patient appeared to be postmenopausal

On real time B-mode sonography Liver is enlarged in size and echopattern is normal, no SOL is seen. Hepatic and portal veins are normal. CBD is normal in calibre, no obstruction is seen

Pancreas is normal in size and echopattern, no SOL is seen.

Spleen is normal in size and echopattern, no SOL is seen.

Kidneys, bilaterally are normal in size and shape, no calculus or dilated calyces are seen.

Right Iliac region appendix could not be traced at present + fecal matter loaded gut loops seen abdomen

No evidence of ascites, free Pleural effusion or lymphadenopathy is seen.

Urinary Bladder is normal in size, wall thickness is normal, no calculus or growth is seen.


Uterus is atrophied, no mass seen in walls, endometrium <3mm. cervix size appear normal and ovaries not identified
no Mass or free fluid is seen in the Pelvis.

IMPRESSION:

Hepatomegaly ?cause

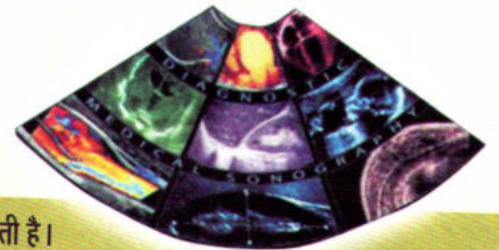
Patient information -Kindly note no luminal pathology can be detected in non distended urinary tract.

Further evaluation suggested.


Ram das arora -radiologist

Ultrasound scan is an investigation and therefore has technical limitations as well as inaccuracies inherent in the laboratory and statistical analysis of biological process. It should always be viewed in this perspective. Further this is a routine general scan grossly containing information sought by ref consultant and report generated thus, is for his perusal only. Considering pace of advances in the field of sonography, more specified information can also be obtained by prior intimation.

- Consultant of Radiology works
- Working hours 10 a.m. to 4 p.m. On Call Basis



“ भ्रूण लिंग परीक्षण करवाना जघन्य अपराध है तथा इसकी शिकायत 104 टोल फ्री सेवा पर की जा सकती है।

“ • “बेटी बचाओ – बेटी पढ़ाओ” • “