


<b>Name</b> : Mrs. Sasmita Das	<b>Age</b> : 48 Y	<b>UHID</b> :CKOR.0000248402
	<b>Sex</b> : F	
<b>Address</b> : KMG		<b>OP Number</b> :CKOROPV390060
<b>Plan</b> : ARCOFEMI MEDIWHEEL FEMALE AHC CREDIT PAN INDIA OP AGREEMENT		<b>Bill No</b> :CKOR-OCR-79316
		<b>Date</b> : 02.12.2023 09:34

Sno	Service Type/ServiceName	Department
1	ARCOFEMI - MEDIWHEEL - FULL BODY ANNUAL PLUS CHECK ADVANCED - FEMALE - 2D ECHO - PAN INDIA - FY2324	
✓1	URINE GLUCOSE(FASTING)	
✓2	GAMMA GLUTAMYL TRANSFERASE (GGT)	17
✓3	SONO MAMOGRAPHY - SCREENING	
✓4	HbA1c, GLYCATED HEMOGLOBIN	10
✓5	2 D ECHO	
✓6	LIVER FUNCTION TEST (LFT)	
✓7	X-RAY CHEST PA <i>VJY</i>	11
✓8	GLUCOSE, FASTING	
✓9	HEMOGRAM + PERIPHERAL SMEAR	
✓10	ENT CONSULTATION <i>Dr. Vijayalakshmi?</i>	23
11	FITNESS BY GENERAL PHYSICIAN	
✓12	GYNAECOLOGY CONSULTATION <i>✓</i>	63
13	DIET CONSULTATION	
✓14	COMPLETE URINE EXAMINATION	
✓15	URINE GLUCOSE(POST PRANDIAL)	
✓16	PERIPHERAL SMEAR	
✓17	ECG <i>✓</i>	14
✓18	BLOOD GROUP ABO AND RH FACTOR	
✓19	LIPID PROFILE	
20	BODY MASS INDEX (BMI)	
✓21	LBC PAP TEST- PAPSURE <i>✓</i>	63
✓22	OPHTHAL BY GENERAL PHYSICIAN	20
✓23	RENAL PROFILE/RENAL FUNCTION TEST (RFT/KFT)	
✓24	ULTRASOUND - WHOLE ABDOMEN <i>✓</i>	17
✓25	THYROID PROFILE (TOTAL T3, TOTAL T4, TSH)	
26	DENTAL CONSULTATION	
✓27	GLUCOSE, POST PRANDIAL (PP), 2 HOURS (POST MEAL)	

28 physio - (20) - cheryee - 5501 -  
 29 dental - (15)  
 30 ophthal screening  
 31 vita - D3.

Bp - 146/82 mm/Hg  
 Pulse - 82 bpm  
 Ht - 150cm  
 Wt - 66.2kg

## Apollo Clinic

### Consent Form

Patient Name: SASMITA DAS Age: 48

UHID Number: ..... Company Name: .....

I Ms SASMITA DAS Employee of BANK OF BARODA

(Company) want to inform you that I am not getting the.....

Test which is a part of health check package.

Reason If any: Physician and Dietician

And I claim the above statement in my full consciousness.

Consultation will be done by me only.

Patient Signature: [Signature] Date: 01-12-2023

Patient Name	: Mrs. Sasmita Das	Age	: 48 Y F
UHID	: CKOR.0000248402	OP Visit No	: CKOROPV390060
Reported on	: 03-12-2023 12:25	Printed on	: 03-12-2023 12:35
Adm/Consult Doctor	:	Ref Doctor	: SELF

**DEPARTMENT OF RADIOLOGY**

**X-RAY CHEST PA**

Both lungs fields appear normal.

Both hila are normal.

Both costophrenic and cardiophrenic angles are normal.

The cardiac and mediastinal shadows appear normal.

Bones and soft tissues appear normal.

**IMPRESSION : NORMAL STUDY.**

*For Vlog*

**DR VINOD JOSEPH DNB,DMRD  
RADIOLOGIST**

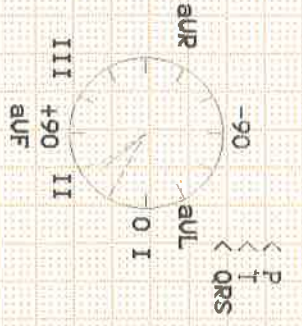
Printed on:03-12-2023 12:25

---End of the Report---



Arrow CE

AGE: 48  
 Measurement Results:  
 QRS : 88 ms  
 QT/QTcB : 362 / 445 ms  
 PR : 142 ms  
 P : 100 ms  
 RR/PP : 736 / 735 ms  
 P/ORS/T : 55 / 50 / 30 degrees  
 QTd/QTcBd : 66 / 77 ms  
 Sokolow : 1.1 mV  
 NK : 11

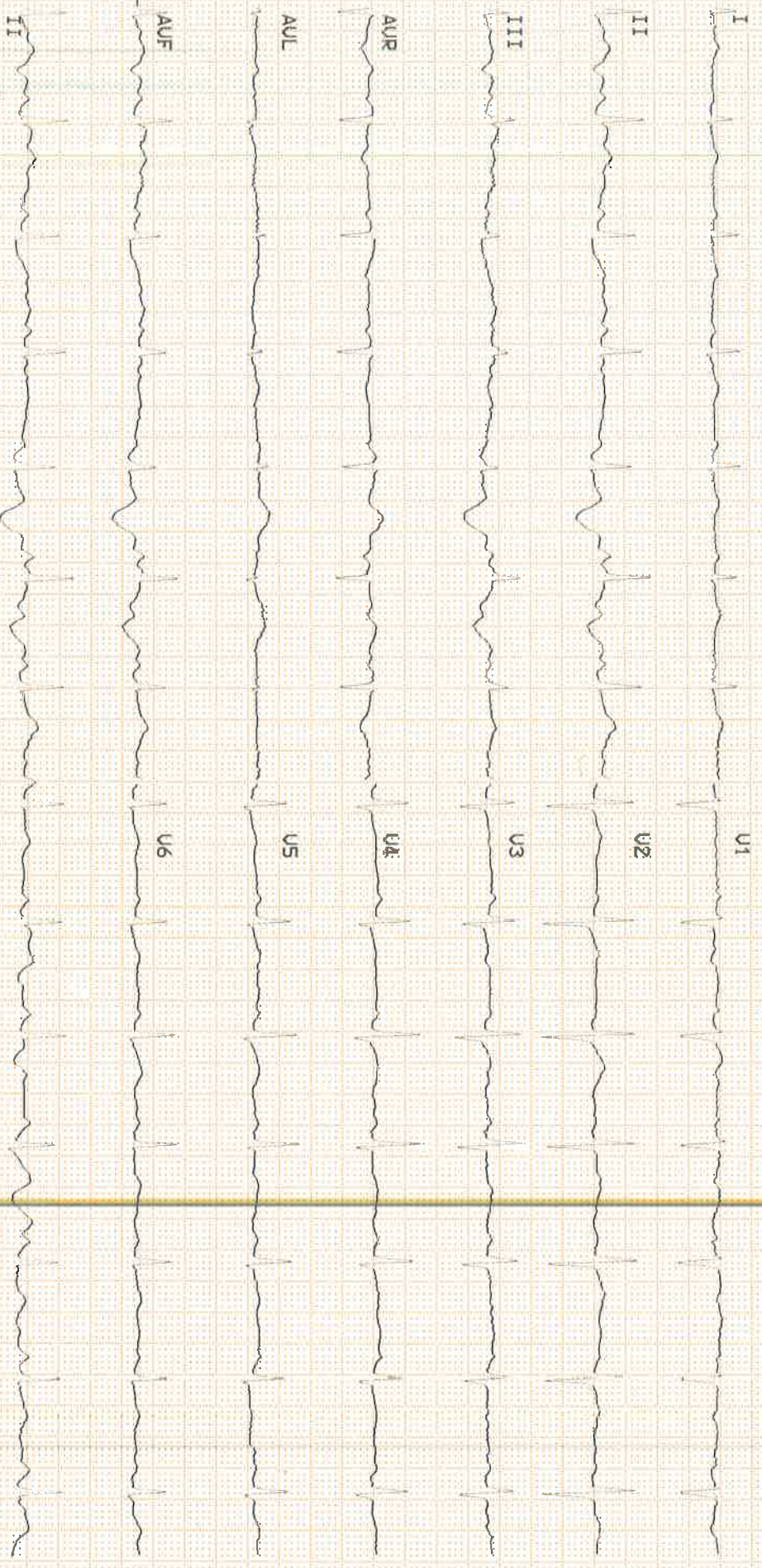


Interpretation:

Normal sinus rhythm

*Handwritten signature*

Unconfirmed report.





Patient Name	: Mrs. Sasmita Das	Age	: 48 Y/F
UHID	: CKOR.0000248402	OP Visit No	: CKOROPV390060
Reported By:	: Dr. TOBY ABRAHAM THOMAS	Conducted Date	: 03-12-2023 10:38
Referred By	: SELF		

### ECG REPORT

#### Observation :-

1. Normal Sinus Rhythm.
2. Heart rate is 83beats per minutes.
3. No pathological Q wave or S-T,T changes seen.
4. Normal P,Q,R,S,T waves and axis.
5. No evidence of chamber, hypertrophy or enlargement seen

#### Impression:

NORMAL RESTING ECG.

Dr. TOBY ABRAHAM THOMAS  
CARDIOLOGIST

NOTE : KINDLY TAKE A PHOTOCOPY OF THE GRAPH  
FOR FUTURE REFERENCE IF NEEDED.

----- END OF THE REPORT -----

**DR VIJAYA LAKSHMI M**  
**M.B.B.S, D.L.O, D.N.B(ENT)**  
**Phone No.9972044580,080-25633823/24/23**

**HEALTH CHECK- ENT**

02/12/23

**NAME:** *Susmita Das*      **P**      **AGE:** *48*

**EAR:**      **RE:**      **LE:**

EXTERNAL EAR

MIDDLE EAR

INNER EAR (FN)

*Normal*

**HEARING ASSESSMENT:**      **RE:**      **LE:**

RHINNE

WEBER

ABC

*Normal*

**NOSE**

**THROAT**

AIRWAY

ORAL CAVITY

SEPTUM

OROPHARYNX

TURBINATES

PHARYNX

OTHERS

LARYNX

*Normal*

**NECK**

NECK NODES

OTHER

*Normal*

**AUDIOMETRY**

**IMPRESSION**

*Normal*



**SIGNATURE:**

**Patient Name** : Mrs Sasmita Das

**Patient ID** : 248402

**Age** : 48Year(s)

**Sex** : Female

**Referring Doctor** : H/C

**Date** : 02.12 .2023

**ULTRASOUND ABDOMEN AND PELVIS**

**Liver** is normal in size and shows increased echo pattern. No biliary dilatation .No focal lesion

**Portal vein** is normal in size, course and caliber. CBD is not dilated.

**Gall bladder** is normal without evidence of calculi, wall thickening or pericholecystic fluid

**Pancreas** to the extent visualized, appears normal in size, contour and echogenicity

**Spleen** is normal in size, shape, contour and echopattern. No evidence of mass or focal lesion.

**Right kidney** is normal in size, position, shape and echopattern. Corticomedullary differentiation is maintained. No evidence of calculi or hydronephrosis.

**Left kidney** is normal in size, position, shape and echopattern.corticomedullary differentiation is maintained. No evidence of calculi or hydronephrosis.

**Urinary Bladder** is well distended. wall thickness is normal. No internal echoes.

**Uterus:** Post hysterectomy status

**Both ovaries:**Not visualized

There is no ascites.

**IMPRESSION:**

- **GRADE-I FATTY LIVER**

**DR VINOD JOSEPH DNB,DMRD**  
**RADIOLOGIST**

Patient Name : Mrs Sasmita Das

Age : 48Years

Referring Doctor : H/C

Patient ID : 248402

Sex : Female

Date : 02.12.23

**SONOMAMMOGRAPHY**

**There is 0.3x0.9cms septated cyst in the left central 4clock position**

Right breast shows normal parenchymal echotexture. There is no evidence of distortion of parenchymal architecture.

The nipple and areolar region show no abnormality.

The bilateral axillary region shows no abnormality and there is no evidence of enlarge lymph nodes.

**IMPRESSION: SEPTATED CYST LEFT BREAST – BIRADS III**

**DR VINOD JOSEPH DNB,DMRD  
RADIOLOGIST**



NAME: MR. SASMITA DAS

AGE: 48Y

SEX: MALE

DATE: 02/12/2023

## ECHOCARDIOGRAPHY REPORT

### MEASUREMENT

AO -23(20 – 35)mm	LIVD d – 41(36-52)mm	IVS - 10 (06 - 11)mm
LA -25(19- 40)mm	LVID s – 28(23- 39)mm	PWD – 10(06- 11)mm
EF - 60% (>50%)	RVID-22	

### VALVES

Mitral Valve : Normal  
Aortic Valve : Normal  
Tricuspid Valve : Normal  
Pulmonary Valve : Normal

### CHAMBERS

Left Atrium : Normal  
Right Atrium : Normal  
Left Ventricle : Normal  
Right Ventricle : Normal

### SEPTAE

IVS : Intact  
IAS : Intact

**GREAT ARTERIES**

Aorta : Normal  
Pulmonary Artery : Normal

**DOPPLER DATA**

Mitral : E > A  
Aortic : Normal  
Tricuspid : Normal  
Pulmonary : Normal

WALL MOTION ABNORMALITIES : No RWMA

Pericardium : Normal

**FINAL DIAGNOSIS**

**NORMAL CHAMBERS AND VALVES  
NORMAL BIVENTRICULAR FUNCTION  
NO RWMA AT REST, LV EF -60%**



**DR. MOHAN MURALI  
CONSULTANT  
CARDIOLOGIST**

**DR. MAHABALESHWAR.M**  
MBBS.(MYS), MD(AIIMS DELHI)FICS  
D.O (JIPMER)  
REG.NO:KMC:9748

DATE: 2/12/22  
OP NO:

**THE APOLLO MEDICAL CENTER KORAMANGALA**

NAME: *Palmela Dal.*  
AGE : *48*  
GENDER: *F*

OPHTHALMIC REPORT

RIGHT EYE

LEFT EYE

**GENERAL APPEARANCE**

**VISION - DISTANCE**

WITHOUT GLASS

*6/6*

*6/6*

WITH GLASS

GLASS POWER

**NEAR**

WITHOUT GLASS

*N6*

*N6*

WITH GLASS

GLASS POWER

**COLOUR**

*0*

*no color blindness*

ANTERIOR SEGMENT:-

*presbyopia*

FUNDUS

I.O.P: DIGITAL

  
**DOCTOR SIGNATURE**



Date : 2/2/23  
MRNO :  
Name : *mm sasmita*  
Age/Gender: 48yr

*U/c*

Department : OBSTERICS & GYNAECOLOGY  
Consultant : DR JYOTHI RAJESH  
KMC NO-42823  
Qualification : DGO (DNB)  
Consultation Timings: 9.30pm to 12.00pm  
PHONE NO: 9972044580

Height :	Weight :	BMI :	Waist Circum :
Temp :	Pulse :	Resp :	B.P :

General Examination / Allergies  
History

Clinical Diagnosis & Management Plan

*No gynae complaint*  
*? DM + BSO 10 yrs - fibroid*  
*OBG - P<sub>2</sub> G<sub>2</sub> P<sub>2</sub> D<sub>2</sub> CD - 23 yrs*  
*Post U - Hypothyroid on 6*  
*Family U - mother - HTN*  
*DL - P/A - 50k*  
*Trsca (+)*  
*P/SU - vacult (-)*

Follow up date:

Doctor Signature