



PANACEA HOSPITAL



A shelter for many hearts A Home for many lives

(An ISO 9001:2008 Certified Organisation)

Lab Attached with CMC Under EQAS Scheme

Dept. of Radiodiagnosis - 32 Slice CT Scan, 3D/4D USG, 2D ECHO, Colour Doppler, Intervention Procedures, Digital X-Ray

PATIENT'S NAME : RENU DEVI AGE/SEX: 47 Y/F
REF. BY : Dr. ASHUTOSH MISHRA (MD) Thursday, December 14, 2023

Echo - Cardiography

MITRAL VALVE Doppler	AML - normal morphology MV Flow - E - 0.5 A-0.6 E/A=0.81	PML - normal morphology MVA - 1.33 cm ² Mitral Regurgitation - No
TRICUSPID VALVE Doppler	Normal TV Flow -No	Tricuspid Regurgitation - No
PULMONARY VALVE Doppler	Normal PV Flow -No	Pulmonary Regurgitation - No
AORTIC VALVE Doppler	Trileaflet-No AV Flow - no	Aortic Regurgitation - No
MEASUREMENT	Aorta - 24.6 (20-38) mm IVS ed - 6.9 (6-12) mm LVID ed - 41.7 (35-55) mm LVPW ed - 11.4 (6-12) mm OA - 7 (> 5) mm	LA - 29.7 (24-32) mm IVS es - 13.1 (6-12) mm LVID es - 28.6 (24-40) mm LVPW es - 12.0 (6-12) mm EPSS - 4 (< 9) mm


CONCLUSION

All cardiac chamber dimensions are WNL
No valvular abnormalities
Good LV systolic function present Modified Simpson's method (4C, 2C) (LVEF-60%)
Grade I diastolic dysfunction present (E/A = ~~0.81~~ 0.9)
No RWMA
No pericardial effusion
Intact IAS / IV
No PAH
No intra cardiac mass /thrombus /vegetation

IMPRESSION

All cardiac chamber dimensions are WNL
No valvular abnormalities
Good LV systolic function present Modified Simpson's method (4C, 2C) (LVEF-60%)
Grade I diastolic dysfunction present (E/A = 0.9)
Rest all other finding are WNL


Niraj Mishra
Physician Assistant
(PAC)

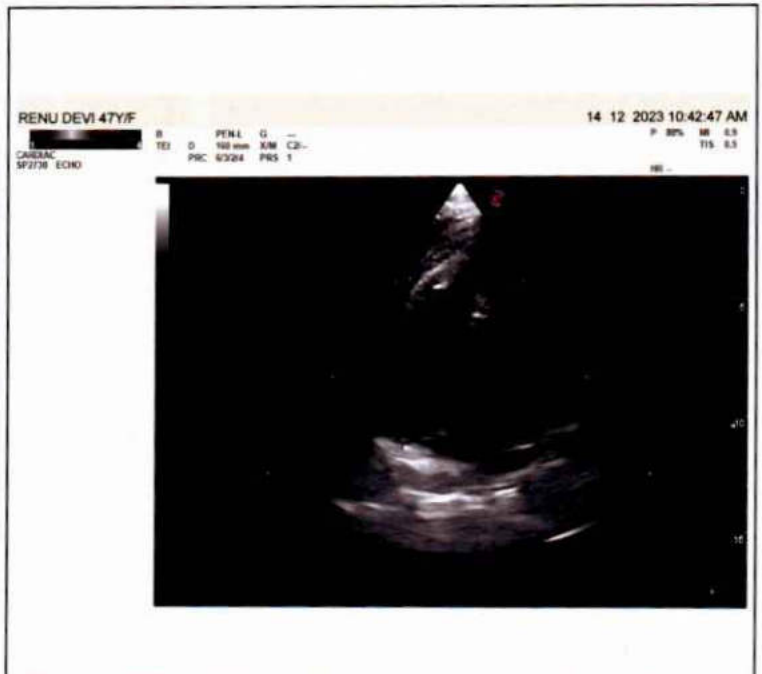
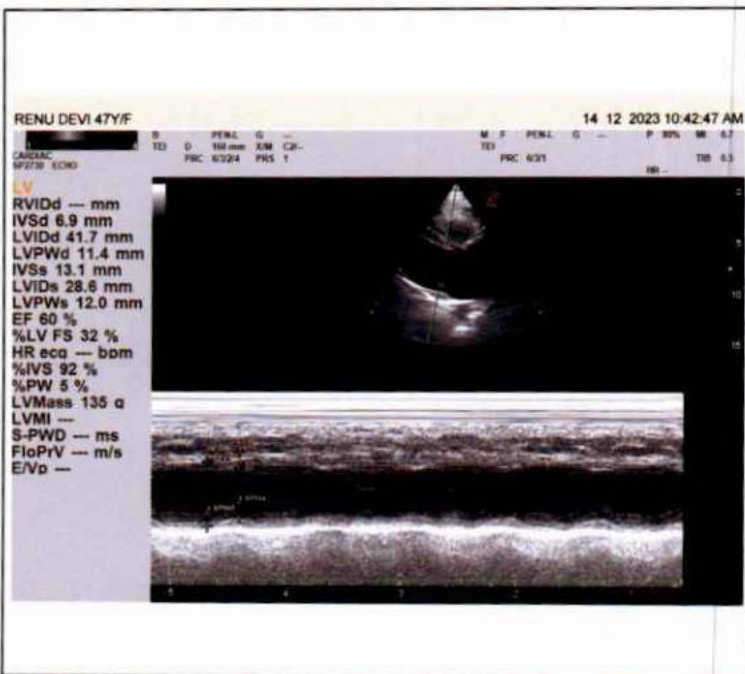
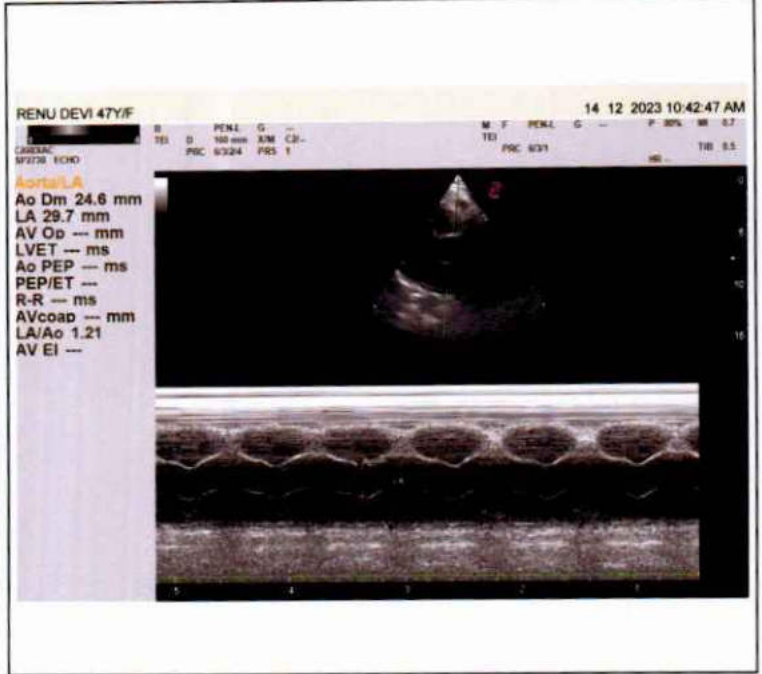
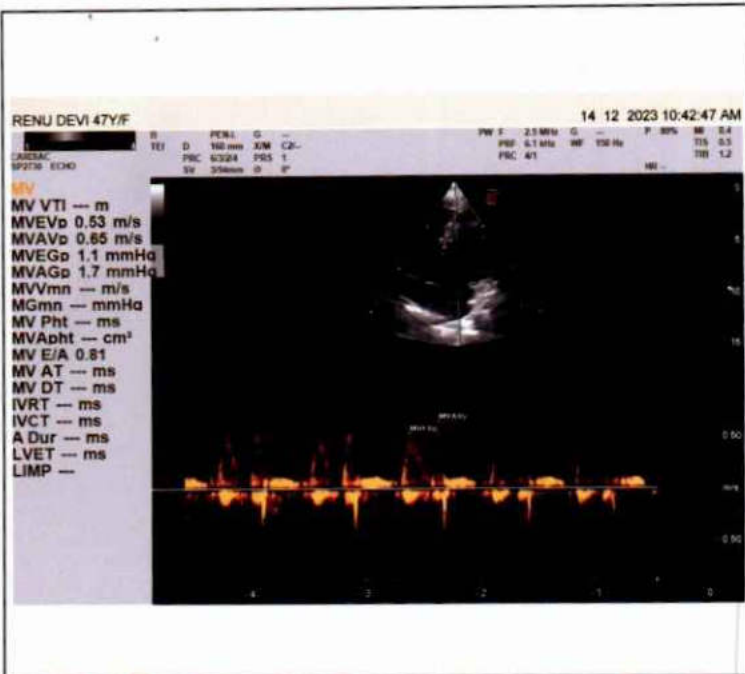

Dr. Pallavi Mishra
DR. Pallavi Mishra
MBBS, MD (GENERAL MEDICINE)
MCI Reg. No. 52033
Diabetocardiologist

Disclaimer: This report is not valid for Medicolegal or Judicial Purpose. Radiological diagnosis is solely interpretation of images produced by tissue & may not be always conclusive.

Address : B36/44 B4 Kabir Nagar (Near Sanjay Shiksha Niketan), Durgakund, Varanasi

Mobile : 9554572190 / 9453837595 / Recpn, 9389994334

Email : dramishra@gmail.com, drpallaviojha@gmail.com, Website : www.piire.org



**Panacea Pathology****Clinical Reference Lab**

Persistence, Preparedness and Precision
EQAS (CMC Vellore Attached) & IQAS System
पूर्वाचल की सर्वोत्तम गुणवत्ता वाली पैथोलॉजी

Facilities:
All clinical Biomedical & Hematology Investigations including Bone Marrow Examination
VPT, Podiascan & Complete Foot Care (First Time in Purvanchal)
All Hormonal Investigation by Chemiluminescent Method
Visceral Fat by (AB-140) Ambulatory BP Monitoring
CGMS & Insulin Pump Available
PFT, 2D-ECHO (Color Doppler), Holter, TMT, Cardiac-3 available
VIA, VILI, Colposcopy available
Special Endocrinological Investigation Protocols.

UHID No :- UD-23240004696 **Booking No/Date** :- 72 / 14-Dec-2023 12:51 PM
Patient Name :- Mrs RENU DEVI **Age/Sex** :- 47 Y/F
Husband :- RAVI SHANKAR RAI **OP No** :- OP-23240014790
Address :- 07 GAUTAM NAGAR COLONY **Mobile No** :- 7753996042
SUSUWAHI VARANASI 221004, varanasi
Consultant :- Dr ASHUTOSH MISHRA (MBBS MD IMS BHU)

Investigations Observations Biological Ref. Interval Unit


HAEMATOLOGY**CBC**

HAEMOGLOBIN <small>DefaultMethod / test Machine</small>	14.4	12.50 - 15.00	gm/dl
TLC <small>Methology / Carm</small>	5,200	4000.00 - 11000.00	Cells/cumm.
DLC DIFFERENTIAL LEUCOCYTE COUNT			
NEUTROPHILS	65	40.00 - 75.00	%
LYMPHOCYTES	28	20.00 - 45.00	%
EOSINOPHILS	04	1.00 - 6.00	%
MONOCYTES	03	2.00 - 10.00	%
BASOPHILS	00	<1-2	%
PLATELET COUNT	1.78	1.50 - 4.10	lacs /cumm
PCV	42.5	33.00 - 42.00	%
RBC <small>Methology / Carm</small>	4.58	3.50 - 4.50	million/cumm
MCV(MEAN CELL VOLUME)	92.8	83.00 - 101.00	fl
MCH(MEAN CELL HAEMOGLOBIN)	31.4	27.00 - 32.00	pg
MCHC	33.8	31.50 - 35.00	gm%

BIOCHEMISTRY**BLOOD SUGAR FASTING**

GLUCOSE	103.6	60.00 - 100.00	mg/dl
---------	-------	----------------	-------

Lab Technician


DR. UMESH KUMAR
MBBS, MD (PATHOLOGIST)
MCI Reg. No. 41413
M.D., Pathology

Timing : 24/7 hrs

This Report is not valid for medico legal purpose

Note: These tests have technical limitations. Clinico-pathological interpretation is necessary. In case of any disparity test may be repeated immediately.

Address : 36/44 FK Kabir Nagar, Durgakund, Varanasi - 221005

Email: dramishra@gmail.com, drpallaviojha@gmail.com Website: panaceahospital.org



Panacea Pathology

Clinical Reference Lab

Persistence, Preparedness and Precision
EQAS (CMC Vellore Attached) & IQAS System
पूर्वाचल की सर्वोत्तम गुणवत्ता वाली पैथोलॉजी

Facilities:

All clinical Biomedical & Hematology Investigations including Bone Marrow Examination
VPT, Podiascan & Complete Foot Care (First Time in Purvanchal)
All Hormonal Investigation by Chemiluminescent Method
Visceral Fat by (AB-140) Ambulatory BP Monitoring
CGMS & Insulin Pump Available
PFT, 2D-ECHO (Color Doppler), Holter, TMT, Cardiac-3 available
VIA, VILI, Colposcopy available
Special Endocrinological Investigation Protocols.

UHID No :- UD-23240004696 **Booking No/Date** :- 72 / 14-Dec-2023 12:51 PM
Patient Name :- Mrs RENU DEVI **Age/Sex** :- 47 Y/F
Husband :- RAVI SHANKAR RAI **OP No** :- OP-23240014790
Address :- 07 GAUTAM NAGAR COLONY **Mobile No** :- 7753996042
SUSUWAHI VARANASI 221004 , varanasi
Consultant :- Dr ASHUTOSH MISHRA (MBBS MD IMS BHU)

Investigations	Observations	Biological Ref. Interval	Unit
PRE-DIABETICS(IMPAIRED FASTING TOLER)	-	100.00 - 125.00	mg/dl
DIABETICS	-	upto 126	mg/dl
TARGET IN DM	-	80.00 - 130.00	mg/dl

BIOCHEMISTRY

PPBS(POST PRANDIAL BLOOD SUGAR)

POST PRANDIAL BLOOD GLUCOSE(2 HR AFTER MEAL)	156.0	110.00 - 150	mg/dl
IGT(2 HR 75GM GLUCOSE)	-	140.00 - 199.00	mg/dl
DIABETES	-	upto200	mg/dl
TARGET IN DM	-	80.00 - 130.00	mg/dl

URINE EXAMINATION

URINE ROUTINE EXAMINATION

PHYSICAL EXAMINATION

QUANTITY 25 mi

COLOR

Methodology

STRAW CLEAR YELLOW

APPEARANCE

DefaultMethod

CLEAR CLEAR

CHEMICAL EXAMINATION

SPECIFIC GRAVITY 1.015 1.01 - 1.03

PH 5.5 4.60 - 8.00

Lab Technician

DR. UMESH KUMAR Pathologist
MBBS, MD (PATHOLOGIST)
MCI Reg. No. 41413
M.D., Pathology

Timing : 24/7 hrs

This Report is not valid for medico legal purpose

Note: These tests have technical limitations. Clinico-pathological interpretation is necessary. In case of any disparity test may be repeated immediately.

Address : 36/44 FK Kabir Nagar, Durgakund, Varanasi - 221005

Email: dramishra@gmail.com, drpallaviojha@gmail.com Website: panaceahospital.org



Panacea Pathology


Clinical Reference Lab

Persistence, Preparedness and Precision
EQAS (CMC Vellore Attached) & IQAS System
पूर्वाचल की सर्वोत्तम गुणवत्ता वाली पैथोलॉजी

Facilities:
All clinical Biomedical & Hematology Investigations including Bone Marrow Examination
VPT, Podiascan & Complete Foot Care (First Time in Purvanchal)
All Hormonal Investigation by Chemiluminescent Method
Visceral Fat by (AB-140) Ambulatory BP Monitoring
CGMS & Insulin Pump Available
PFT, 2D-ECHO (Color Doppler), Holter, TMT, Cardiac-3 available
VIA, VILI, Colposcopy available
Special Endocrinological Investigation Protocols.

UHID No :- UD-23240004696 **Booking No/Date** :- 72 / 14-Dec-2023 12:51 PM
Patient Name :- Mrs RENU DEVI **Age/Sex** :- 47 Y/F
Husband :- RAVI SHANKAR RAI **OP No** :- OP-23240014790
Address :- 07 GAUTAM NAGAR COLONY
SUSUWAHI VARANASI 221004 , varanasi **Mobile No** :- 7753996042
Consultant :- Dr ASHUTOSH MISHRA (MBBS MD IMS BHU)

Investigations	Observations	Biological Ref. Interval	Unit
GLUCOSE	NIL	60.00 - 100.00	mg/dl
PROTEIN-	NIL		
<u>MICROSCOPIC EXAMINATION</u>			
PUS CELLS	01-02	2.00 - 3.00	/HPF
RBCS (RED BLOOD CELLS)	NIL	3.50 - 4.50	/HPF
EPITHELIAL CELLS	02-03		/HPF
CASTS	ABSENT	ABSENT	
CRYSTALS	ABSENT	ABSENT	
<u>HAEMATOLOGY</u>			
ESR	16.0	0.00 - 20.00	mm at 1 hr
<u>BLOOD GROUP ABO & RH FACTOR</u>			
BLOOD GROUP	"B"		
RH FACTOR	POSITIVE		
<u>IMMUNOLOGY</u>			
<u>THYROID PROFILE (T3,T4,TSH)</u>			
T3	1.01	0.60 - 1.81	ng/ml
T4	7.2	4.50 - 10.90	ug/dl


DR. UMESH KUMAR
MBBS, MD (PATHOLOGIST)
MCI Reg. No. 41413
M.D., Pathology

Lab Technician

Timing : 24/7 hrs

This Report is not valid for medico legal purpose

Note: These tests have technical limitations. Clinico-pathological interpretation is necessary. In case of any disparity test may be repeated immediately.

Address : 36/44 FK Kabir Nagar, Durgakund, Varanasi - 221005

Email: dramishra@gmail.com, drpallaviojha@gmail.com Website: panaceahospital.org



Panacea Pathology

Clinical Reference Lab

Persistence, Preparedness and Precision
EQAS (CMC Vellore Attached) & IQAS System
पूर्वांचल की सर्वोत्तम गुणवत्ता वाली पैथोलॉजी

Facilities:

All clinical Biomedical & Hematology Investigations including Bone Marrow Examination
VPT, Podiascan & Complete Foot Care (First Time in Purvanchal)
All Hormonal Investigation by Chemiluminescent Method
Visceral Fat by (AB-140) Ambulatory BP Monitoring
CGMS & Insulin Pump Available
PFT, 2D-ECHO (Color Doppler), Holter, TMT, Cardiac-3 available
VIA, VILI, Colposcopy available
Special Endocrinological Investigation Protocols.

UHID No :- UD-23240004696 **Booking No/Date** :- 72 / 14-Dec-2023 12:51 PM
Patient Name :- Mrs RENU DEVI **Age/Sex** :- 47 Y/F
Husband :- RAVI SHANKAR RAI **OP No** :- OP-23240014790
Address :- 07 GAUTAM NAGAR COLONY **Mobile No** :- 7753996042
SUSUWAHI VARANASI 221004, varanasi
Consultant :- Dr ASHUTOSH MISHRA (MBBS MD IMS BHU)

Investigations	Observations	Biological Ref. Interval	Unit
TSH	2.21	0.39 - 6.10	uIU/mL

THYROID PROFILE


Remarks:

- Total serum T3 and T4 concentration is dependent upon a multiplicity of factors: thyroid gland function and its regulation, thyroxin binding globulin (TBG) concentration, and the binding of T3 & T4 to TBG. Thus, total T3 & T4 concentration alone is not sufficient to assess the clinical status.
- A decrease in total tri - iodothyronine values is found with protein - wasting diseases, certain liver diseases & administration of testosterone, diphenylhydantoin or salicylates
- Serum TSH values may be elevated by pharmacological intervention, Domperidone, amidodazon, iodide, Phenobarbital, phenytoin have been reported to increase TSH levels

BIOCHEMISTRY

LIPID PROFILE

TOTAL CHOLESTROL	153.0	Desirable : - < 200 mg/dL Borderline: - 200 - 239 mg/dL High : - > 240mg/dL	mg/dl
TRIGLYCERIDES	144.0	35.00 - 160.00	mg/dl
HDL CHOLESTROL	41.0	42.00 - 88.00	mg/dl
LDL CHOLESTROL	83.2	<130	mg/dl
VLDL	28.80	<40	mg/dl


Consulting Pathologist
DR. UMESH KUMAR
MBBS, MD (PATHOLOGIST)
MCI Reg. No. 11413
M.D., Pathology

Lab Technician

Timing : 24/7 hrs

This Report is not valid for medico legal purpose

Note: These tests have technical limitations. Clinico-pathological interpretation is necessary. In case of any disparity test may be repeated immediately.

Address : 36/44 FK Kabir Nagar, Durgakund, Varanasi - 221005

Email: dramishra@gmail.com, drpallaviojha@gmail.com Website: panaceahospital.org



Panacea Pathology

Clinical Reference Lab

Persistence, Preparedness and Precision
EQAS (CMC Vellore Attached) & IQAS System
पूर्वाचल की सर्वोत्तम गुणवत्ता वाली पैथोलॉजी

Facilities:
All clinical Biomedical & Hematology Investigations including Bone Marrow Examination
VPT, Podiascan & Complete Foot Care (First Time in Purvanchal)
All Hormonal Investigation by Chemiluminescent Method
Visceral Fat by (AB-140) Ambulatory BP Monitoring
CGMS & Insulin Pump Available
PFT, 2D-ECHO (Color Doppler), Holter, TMT, Cardiac-3 available
VIA, VILI, Colposcopy available
Special Endocrinological Investigation Protocols.


UHID No :- UD-23240004696 **Booking No/Date** :- 72 / 14-Dec-2023 12:51 PM
Patient Name :- Mrs RENU DEVI **Age/Sex** :- 47 Y/F
Husband :- RAVI SHANKAR RAI **OP No** :- OP-23240014790
Address :- 07 GAUTAM NAGAR COLONY **Mobile No** :- 7753996042
SUSUWAHI VARANASI 221004 , varanasi
Consultant :- Dr ASHUTOSH MISHRA (MBBS MD IMS BHU)

Investigations	Observations	Biological Ref. Interval	Unit
CHOLESTROL/ HDL RATIO	3.73	<3.0 LOW RISK, 3.0-5.0 AVG RISK, >5.0 HIGH RISK	ratio
LDL/HDL RATIO	2.03	<3	ratio
LFT (LIVER FUNCTION TESTS)			
TOTAL BILIRUBIN	0.59	0.00 - 1.20	mg/dl
DIRECT BILIRUBIN	0.21	0.00 - 0.30	
INDIRECT BILIRUBIN	0.38	0.20 - 0.70	mg/dl
SGOT	21.0	2.00 - 31.00	U/L
SGPT	26.0	10.00 - 45.00	U/L
ALKALINE PHOSPHATASE	64.0	25.00 - 140.00	U/L
TOTAL PROTIENS	7.24	6.60 - 8.70	g/dl
ALBUMIN	4.10	3.50 - 5.20	gm%
GLOBULIN	3.14	1.50 - 3.60	gms/dl
A/G RATIO	1.30	2:1	RATIO
RFT (RENAL FUNCTION TESTS)			
BLOOD UREA	22.0	10.00 - 50.00	mg/dl
SERUM CREATININE	0.67	0.60 - 1.60	mg/dl

Lab Technician

Timing : 24/7 hrs

This Report is not valid for medico legal purpose


DR. UMESH KUMAR
MBBS, MD (PATHOLOGIST)
MCI Reg. No. 41413
M.D., Pathology

Note: These tests have technical limitations. Clinico-pathological interpretation is necessary. In case of any disparity test may be repeated immediately.

Address : 36/44 FK Kabir Nagar, Durgakund, Varanasi - 221005

Email: dramishra@gmail.com, drpallaviojha@gmail.com Website: panaceahospital.org

Facilities:

All clinical Biomedical & Hematology Investigations including Bone Marrow Examination
 VPT, Podiascan & Complete Foot Care (First Time in Purvanchal)
 All Hormonal Investigation by Chemiluminescent Method
 Visceral Fat by (AB-140) Ambulatory BP Monitoring
 CGMS & Insulin Pump Available
 PFT, 2D-ECHO (Color Doppler), Holter, TMT, Cardiac-3 available
 VIA, VILI, Colposcopy available
 Special Endocrinological Investigation Protocols.

ISO 9001:2008 Certified

Mobile: 9389994334, 9554572190, 9453837595



Panacea Pathology

Clinical Reference Lab

Persistence, Preparedness and Precision
 EQAS (CMC Vellore Attached) & IQAS System
 पूर्वांचल की सर्वोत्तम गुणवत्ता वाली पैथोलॉजी

UHID No :- UD-23240004696 **Booking No/Date** :- 72 / 14-Dec-2023 12:51 PM
Patient Name :- Mrs RENU DEVI **Age/Sex** :- 47 Y/F
Husband :- RAVI SHANKAR RAI **OP No** :- OP-23240014790
Address :- 07 GAUTAM NAGAR COLONY **Mobile No** :- 7753996042
 SUSUWAHI VARANASI 221004, varanasi
Consultant :- Dr ASHUTOSH MISHRA (MBBS MD IMS BHU)

Investigations	Observations	Biological Ref. Interval	Unit
URIC ACID	4.10	2.50 - 6.80	mg/dl

PARASITOLOGY

STOOL ROUTINE

GROSS EXAMINATON

COLOR <i>Methology</i>	YELLOW	CLEAR YELLOW	
CONSISTANCY	NORMAL		
BLOOD	ABSENT		
MUCUS	ABSENT		
<u>MICROSCOPIC EXAMINATON</u>			
OVA OR EGGS OF HELMINTHS	ABSENT		
CYST OF PROTOZOA	ABSENT		
PUS CELLS	02-04	2.00 - 3.00	/HPF
RBC <i>Methology / Carm</i>	NIL	3.50 - 4.50	million/cumm

* END OF REPORT *

Consulting Pathologist
 DR. UMESH KUMAR
 MBB, M.D. (PATHOLOGIST)
 MCI Reg. No. 10102
 M.D. Pathology

Lab Technician

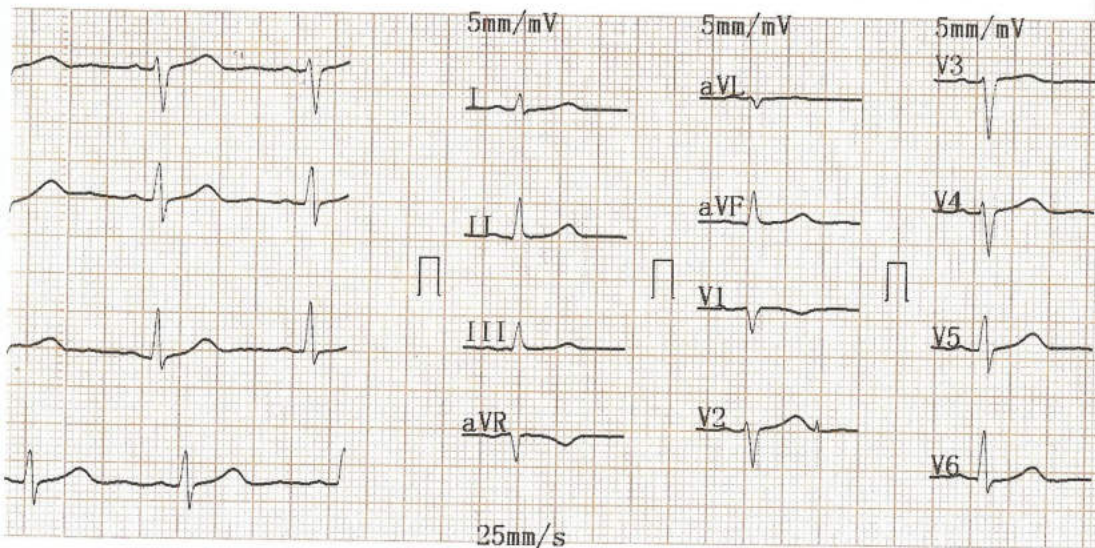
Timing : 24/7 hrs

This Report is not valid for medico legal purpose

Note: These tests have technical limitations. Clinico-pathological interpretation is necessary. In case of any disparity test may be repeated immediately.

Address : 36/44 FK Kabir Nagar, Durgakund, Varanasi – 221005

Email: dramishra@gmail.com, drpallaviojha@gmail.com Website: panaceahospital.org



2023-12-14 09:40

<< Conclusions >>

ID :
 Name : **Remu devi**
 Sex : **F.** Age : **47**
 Height : **148** Weight : **57** kg ****Report need physician confirm****
 SYS :
 DIA :

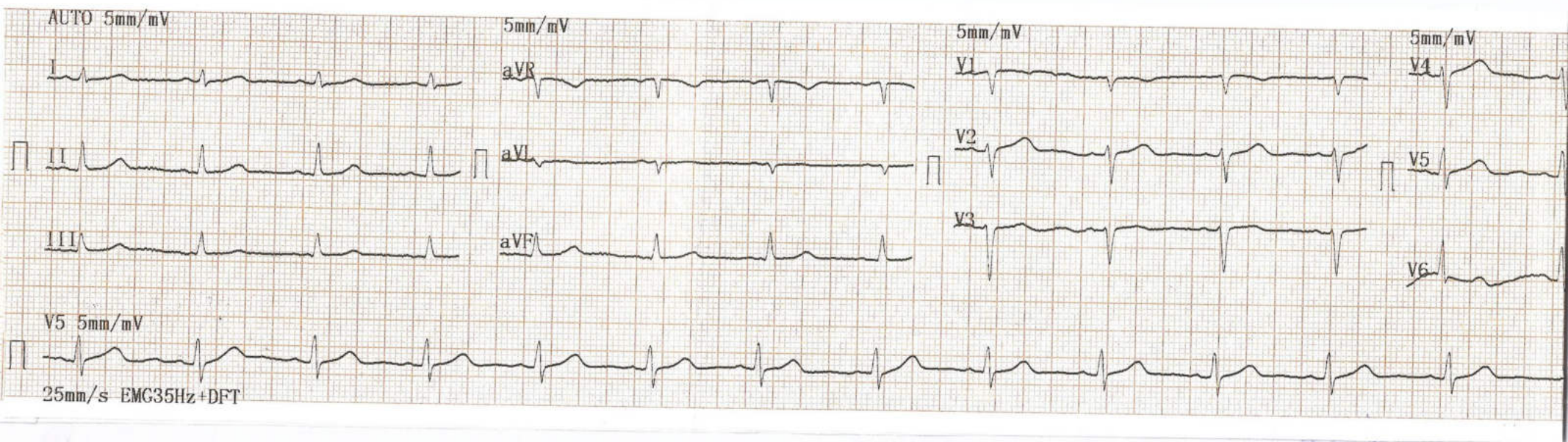
Normal Sinus Rhythm;
 Cardiac electric axis normal;

HR [bpm] : 76
 PR Interval ms : 149
 P Duration ms : 104
 QRS Duration ms : 78
 T Duration ms : 219
 QT/QTc ms : 398/448
 P/QRS/T Axis deg : 39.3/74.3/56.7
 R(V5)/S(V1) mV : 0.90/0.63
 R(V5)+S(V1) mV : 1.53

Pallavi

DR. Pallavi Misra
MBBS, MD(GENERAL MEDICINE)
MCI Reg. No.52033

Physician _____





भारत सरकार

Govt. of India

रेल मंत्रालय

Ministry of Railways

ब.रे.का.

Banaras Locomotive Works

वाराणसी

VARANASI



परिचय पत्र संख्या

I/Card No. 1707

कर्मचारी संख्या

Emp. No. 15768

नाम
Name

: श्रीमती रेनु देवी

: SM. RENU DEVI

पिता/पति का नाम

Father/Husband's name : Mr. Ravi Shankar Rai

पद
Designation

: Prg. man-I Fitter

विभाग
Department

: Mechanical

Renu

कर्मचारी के हस्ताक्षर
Sign. of Employee

निर्गम तिथि: 19.01.2022

सुरक्षा अधिकारी/रेनु देवी



GPS Map Camera

Varanasi, Uttar Pradesh, India

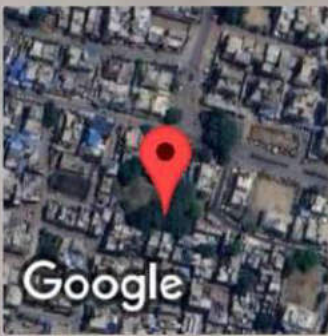
7XQV+CVP, Kabir Nagar Rd, near sanjay siksha niketan, Durgakund,

Jawahar Nagar Colony, Bhelupur, Varanasi, Uttar Pradesh 221010, India

Lat 25.288443°

Long 82.994672°

14/12/23 08:29 AM GMT +05:30



निवास स्थान Lane.no. 07 Gautam Nagar Colony Shushwahi
Resi. Address Varanasi 221011

जन्म तिथि 05.12.1976
Date of Birth

रक्त समूह AB+ve
Blood Group

पहचान चिन्ह cut mark on forehead
Identification Mark

दूरभाष कार्यालय 7753996042 निवास
Tel. No. Office Resi.
अनुदेश _____

1. स्थानांतरण या सेवानिवृत्ति होने पर इसे लौटाया जाये।
Return on Transfer/retirement.
2. इस पहचान पत्र के खो जाने पर कार्यालय तथा सीमावर्ती पुलिस स्टेशन को तत्काल रिपोर्ट की जाये।
In case of loss, report to the office and P.S. Immediately.
3. इस के खो जाने पर नये पहचान पत्र का मूल्य धारक को देना होगा।
In case of loss of I/Card, Holder will bear the cost of new I/Card.
4. यह परिचय पत्र निर्गम तिथि से 05 वर्ष के लिए वैध है।
This I/Card is valid for 05 years from date of issue



GPS Map Camera

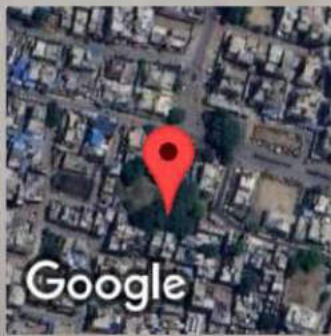
Varanasi, Uttar Pradesh, India

7XQV+CVP, Kabir Nagar Rd, near sanjay siksha niketan, Durgakund,
Jawahar Nagar Colony, Bhelupur, Varanasi, Uttar Pradesh 221010, India

Lat 25.288443°

Long 82.994672°

14/12/23 08:30 AM GMT +05:30





PANACEA HOSPITAL

B 36/44 F.K KABIR NAGAR, DURGAKUND
TOLLFREE NO-18001233070. Whatsapp No - 8795832852
www.piire.org
panaceaquery@gmail.com|panceahospitalit@gmail.com



OP Slip

Print Date : 14-Dec-2023 09:40AM



UHID No	:- UD-23240004696	OP No	:- OP-23240014790	OP Date	:- 14 Dec 2023 9:32AM
Patient Name	:- Mrs RENU DEVI	Age/Sex	:- 47 Y/Female	Mobile No	:- 7753996042
Husband	:- RAVI SHANKAR RAI	Department	:- GENERAL MEDICINE		
Pay Type	:- Cash	Consultant	:- Dr ASHUTOSH MISHRA (MBBS MD IMS BHU,MD)		
Token No	:- NOR. -3	Paid/Bal	:- 0.00 /530.00		
Patient Type	:- Normal				
Address	:- 07 GAUTAM NAGAR COLONY SUSUWAHI VARANASI 221004, varanasi				

11/0/80
 BP :-
 height :- 148
 Weight (kg) :- 57
 BMI :- 26
 SPO2 - 98
 PR - 79
 PEFr - 200
 NC - 30
 WC - 83
 Ch - 36

Rx

△ Hypothyroidism
headaches
CORD.

Diabet about 1400 mg/dl (CSM)
 Rotated - Annular Pt 2500 mg
 Tab. Menthman Rs 1000

⊗ 100. Dichebras (10) OD ✓
 ⊗ 20. Roumy (30) OD ✓

1/1 2 month

DR. ASHUTOSH MISHRA
 MBBS, MD (GENERAL MEDICINE)
 MCI, Reg. No. 45695

Printed By : Ms. RENUKA
 Created By : Ms. RENUKA



PANACEA HOSPITAL

B 36/44 F.K KABIR NAGAR, DURGAKUND
TOLLFREE NO-18001233070. Whatsapp No - 8795832852
www.piire.org
panaceaquery@gmail.com|panceahospitalit@gmail.com



OP Slip

Print Date : 14-Dec-2023 05:54PM



UHID No :- UD-23240004696	OP No :- OP-23240014866	OP Date :- 14 Dec 2023 5:52PM
Patient Name :- Mrs RENU DEVI	Age/Sex :- 47 Y/Female	Mobile No :- 7753996042
Husband :- RAVI SHANKAR RAI	Department :- OBST. & GYNAECOLOGY	
Pay Type :- Cash	Consultant :- Dr Tusharika Rai (MBBS,MS)	
Token No :- NOR.-6	Paid/Bal :- 0.00 /600.00	
Patient Type :- Normal		
Address :- 07 GAUTAM NAGAR COLONY SUSUWAHI VARANASI 221004,varanasi		

BP :-
height :-
Weight (kg) :-
BMI :-

Rx

P₂+0 (2A+H)
LD < 0 → 1 LSCS / 19 yrs
 0 → 2 LSCS / 12 yrs.

C/O. Irregular Pds x 2 yrs c.

LMP - 3/11/2023.
 1
 20/11/2023.

TSH - (N)
Sugar < F-106
 PP-155

Rx - PAP smear
 - S. FSH.

Review e Reports.

DR. TUSHARIKA RAI
MBBS,MS (GYNECOLOGIST)
MCI Reg No. 62980

Printed By : Mr SIDHANT
Created By : Mr SIDHANT



PANACEA HOSPITAL

B 36/44 F.K KABIR NAGAR, DURGAKUND
TOLLFREE NO-18001233070. Whatsapp No - 8795832852
www.piire.org
panaceaquery@gmail.com | panaceahospital@gmail.com



OP Slip

Print Date : 14-Dec-2023 09:37AM



UHID No :- UD-23240004696	OP No :- OP-23240014790	OP Date :- 14 Dec 2023 9:32AM
Patient Name :- Mrs RENU DEVI	Age/Sex :- 47 Y/Female	Mobile No :- 7753996042
Husband :- RAVI SHANKAR RAI	Department :- DENTAL	
Pay Type :- Cash	Consultant :- Dr MAYANK MISHRA (BDS,FDS)	
Token No :- NOR. - 2	Paid/Bal :- 0.00 /530.00	
Patient Type :- Normal		
Address :- 07 GAUTAM NAGAR COLONY SUSUWAHI VARANASI 221004, varanasi		

BP :- 110/80
 height :- 148
 Weight (kg) :- 57
 BMI :- 26
 SPO₂ - 98
 PR - 79
 PEFR - 200
 NL - 30
 WL - 83
 LH - 36

Rx
 cel + nt
 R.S.
 + A
 anxious
 + 8.
 admitted
 bet.
 + 9.
 p-ray
 + 0.

Printed By : Ms. RENUKA
Created By : Ms. RENUKA

Dr. Mayank Mishra





PANACEA HOSPITAL

B 36/44 F.K KABIR NAGAR, DURGAKUND
TOLLFREE NO-18001233070. Whatsapp No - 8795832852
www.piire.org
panaceaquery@gmail.com|panaceahospitalit@gmail.com



OP Slip

Print Date : 14-Dec-2023 09:39AM



UHID No	:- UD-23240004696	OP No	:- OP-23240014790	OP Date	:- 14 Dec 2023 9:32AM
Patient Name	:- Mrs RENU DEVI	Age/Sex	:- 47 Y/Female	Mobile No	:- 7753996042
Husband	:- RAVI SHANKAR RAI	Department	:- OPHTHALMOLOGY		
Pay Type	:- Cash	Consultant	:- Dr SANTOSH VERMA (MBBS,MS)		
Token No	:- NOR. - 2	Paid/Bal	:- 0.00 /530.00		
Patient Type	:- Normal				
Address	:- 07 GAUTAM NAGAR COLONY SUSUWAHI VARANASI 221004, varanasi				

BP 110/80
height :- 148
Weight (kg) :- 57
BMI :- 26

SPO2 - 98
PR - 79
PEFR - 200
NL - 30
WL - 83
CH - 36

Rx

VA $\left\{ \begin{array}{l} 616 \text{ --- NI } \checkmark \\ 616 \text{ --- } 616 \checkmark \end{array} \right.$

NV $\left\{ \begin{array}{l} +1.50 \text{ DS} \\ +1.50 \text{ DS} \end{array} \right\}$ N16.

orally.

2 - Ferte plus - OD
0 - 10 day.

Locally B/E

4 - Lubstone ultra - QID

0000.

Desma

Dr. SANTOSH VERMA
MBBS, MS (Ophthalmologist)
MCI Reg. No. 09-34327

Printed By : Ms. RENUKA
Created By : Ms. RENUKA



PANACEA HOSPITAL

B 36/44 F.K KABIR NAGAR, DURGAKUND
TOLLFREE NO-18001233070. Whatsapp No - 8795832852
www.piire.org
panaceaquery@gmail.com|panceahospitalit@gmail.com



OP Slip

Print Date : 14-Dec-2023 09:38AM



UHID No :- UD-23240004696	OP No :- OP-23240014790	OP Date :- 14 Dec 2023 9:32AM
Patient Name :- Mrs RENU DEVI	Age/Sex :- 47 Y/Female	Mobile No :- 7753996042
Husband :- RAVI SHANKAR RAI	Department :- DERMATOLOGY	
Pay Type :- Cash	Consultant :- Dr ASHUTOSH MISHRA (MBBS,MD)	
Token No :- NOR. -3	Paid/Bal :- 0.00 /530.00	
Patient Type :- Normal		
Address :- 07 GAUTAM NAGAR COLONY SUSUWAHI VARANASI 221004, varanasi		

BP :- 110/80
 height :- 148
 Weight (kg) :- 57
 BMI :- 26
 SPO₂ - 98
 PR - 79
 PEFR - 200
 NL - 30
 WL - 83
 CH - 36

Rx

Rx
 Hydrell or C
 . tone and clean -> xrt
 . salifex want C!

30day



Printed By : Ms. RENUKA
Created By : Ms. RENUKA

Panacea Hospital

A Shelter For Many Hearts

Home For Many Lives

Diabetes Care Organisation



AY I HELP YOU



GPS Map Camera

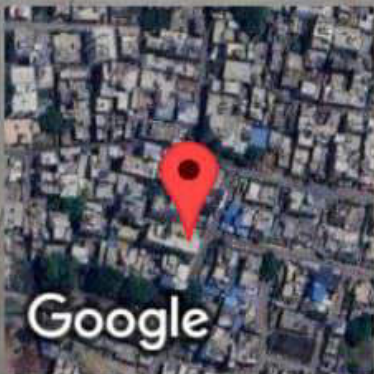
Varanasi, Uttar Pradesh, India

44-B3, Durgakund, Bhelupur, Varanasi, Uttar Pradesh 221001, India

Lat 25.289238°

Long 82.993328°

14/12/23 08:46 AM GMT +05:30





PANACEA HOSPITAL

Call Now - 1800-123-3070



A shelter for many hearts A Home for many lives

(An ISO 9001:2008 Certified Organisation)

Lab Attached with CMC Under EQAS Scheme

Dept. of Radiodiagnosis - 32 Slice CT Scan, 3D/4D USG, 2D ECHO, Colour Doppler, Intervention Procedures, Digital X-Ray

PATIENT'S NAME : RENU DEVI **AGE/SEX:** 47 Y/F
REF. BY : Dr. ASHUTOSH MISHRA (MD) **DATE:** 14/12/2023

U/S. WHOLE ABDOMEN

- LIVER** : Liver is normal in size(13.4cm), shape & echotexture. Intra hepatic biliary radicals are normal. Portal venous channels are normal.
- G. B.** : Gall bladder is normal in size, lumen is clear. Wall thickness normal.
- C.B.D.** : C.B.D. is normal in caliber.
- PANCREAS** : Pancreas is normal in size, shape and echotexture. No evidence of any inflammatory disease or mass.
- SPLEEN** : Spleen is normal in size(9.8cm), shape and echotexture.
- Rt. KIDNEY** : Normal in size, shape and echotexture. Renal sinus is normal Cortico medullary differentiation is normal. P. C. system is normal.
- Lt. KIDNEY** : Normal in size, shape and echotexture. Renal sinus is normal Cortico medullary differentiation is normal. P. C. system is normal.
- URI. BLADDER** : Urinary bladder is normal in size, position. Wall thickness normal. No evidence of calculus or mass.
- UTERUS** : Normal in size, shape & echotexture. Endometrial echo is normal(5.5mm).
- OVARIES** : Rt. Ovary:-Normal in size.
Lt. Ovary:-Normal in size.
No free fluid seen in P. O. D.
- IMPRESSION** : **NO OBVIOUS SONOLOGICAL ABNORMALITY SEEN.**

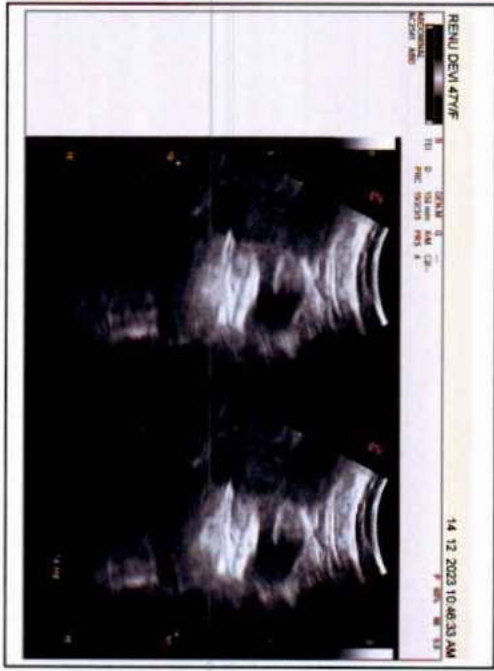
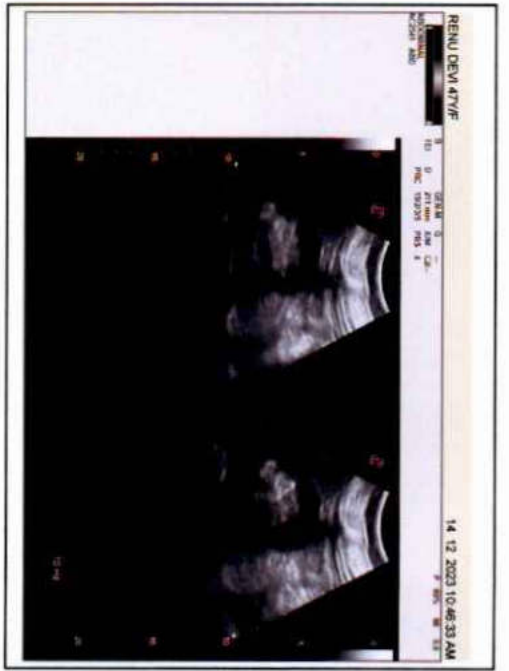
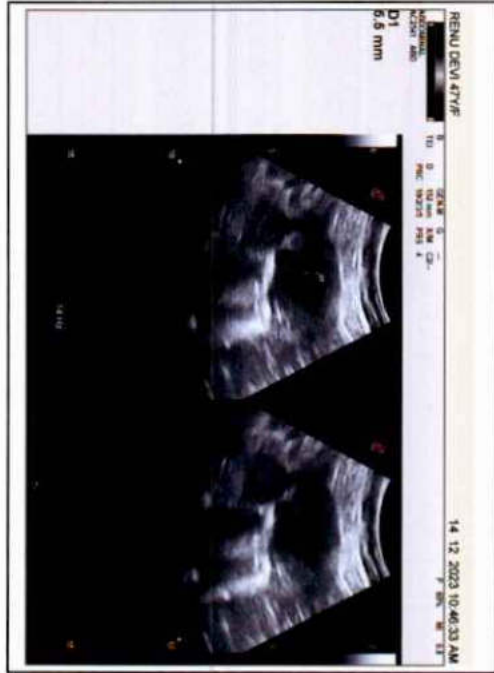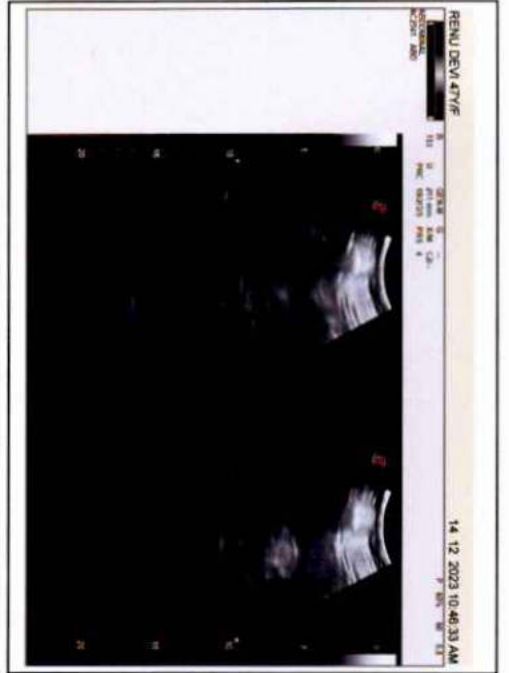
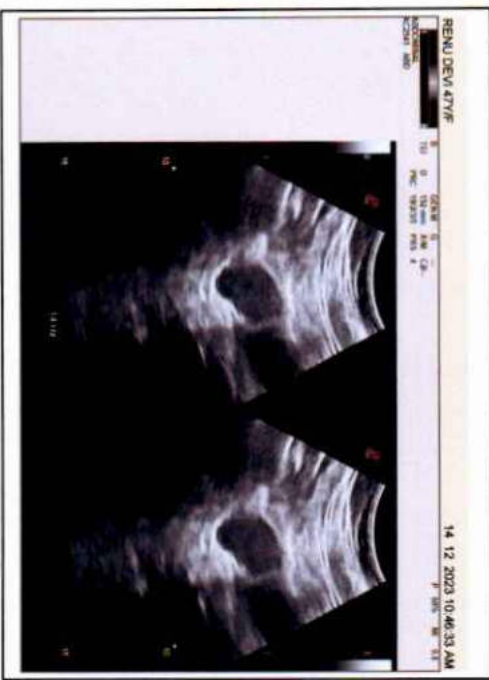
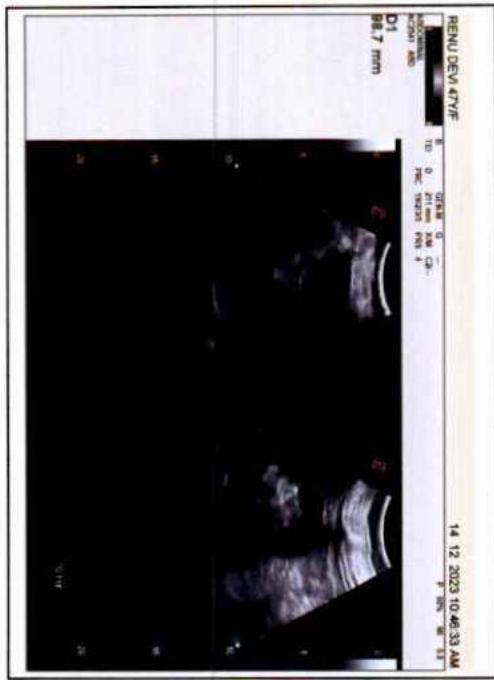
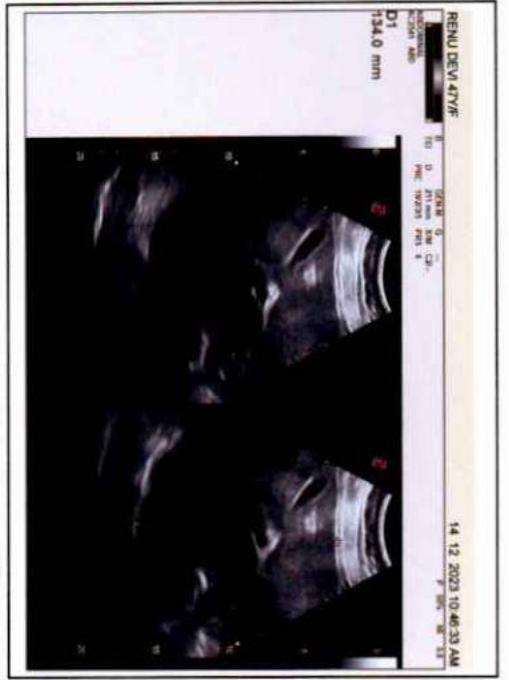
Sonologist

Dr. Renu Devi
MBBS, MD (Radio Diagonosis)
Reg. No. 57557

Thanks for reference.

Disclaimer: This report is not valid for Madicolegal or Judicial Purpose. Radiological diagnosis is solely interpretation of images produced by tissue & may not be always conclusive.

Address : B36/44 B4 Kabir Nagar (Near Sanjay Shiksha Niketan), Durgakund, Varanasi
Mobile : 9554572190 / 9453837595 / Recpn, 9389994334
Email : dramishra@gmail.com, drpallaviojha@gmail.com, Website : www.piire.org





PANACEA HOSPITAL



A shelter for many hearts A Home for many lives

(An ISO 9001:2008 Certified Organisation)
Lab Attached with CMC Under EQAS Scheme

Dept. of Radiodiagnosis - 32 Slice CT Scan, 3D/4D USG, 2D ECHO, Colour Doppler, Intervention Procedures, Digital X-Ray

PATIENT'S NAME :	RENU DEVI	AGE/SEX: 47Y/F
REF. BY :	Dr. ASHUTOSH MISHRA(MD)	DATE 14-12-2023

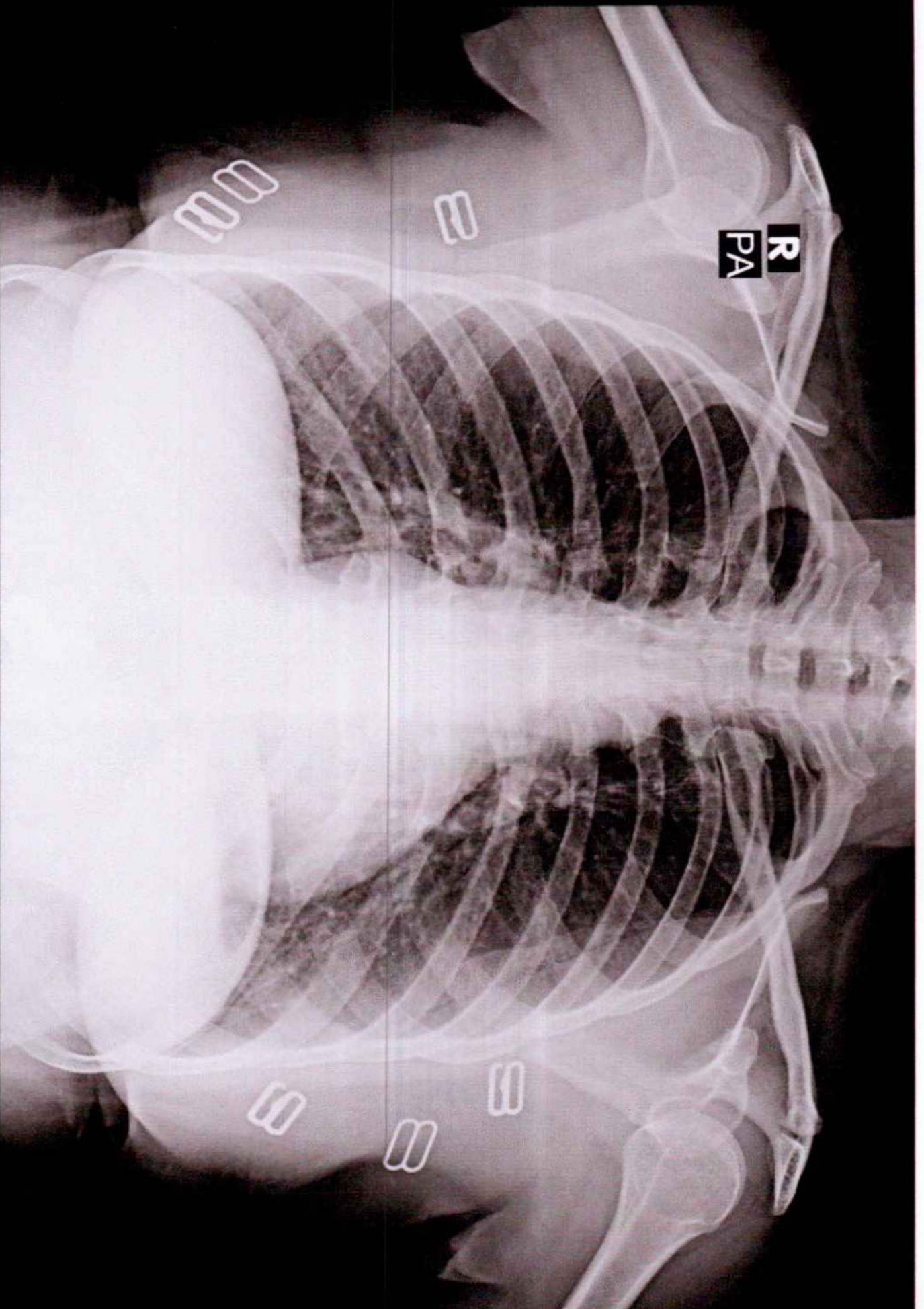
X-RAY CHEST (AP VIEW)

- Lung fields show hazy opacities in both parahilar, basal zone with mild prominent brochopulmonary markings findings suggestive of MILD BRONCHITIS.
- Rest visualized lung fields appear normal.
- Trachea appear normal in position and course.
- Both CP angles appear clear.
- Bony rib cage and soft tissue shadows appear normal.

Thanks for reference.

Radiologist

Dr. Rahul Kumar Tiwari
MBBS, MD (Radio Diagonosis)
Reg. No. 57557



RENU DEVI 47Y/F 4696 F CHEST P.A. 14-Dec-23 11:29 AM

PANACEA HOSPITAL, KABIR NAGAR, DURGAKUND, VARANASI