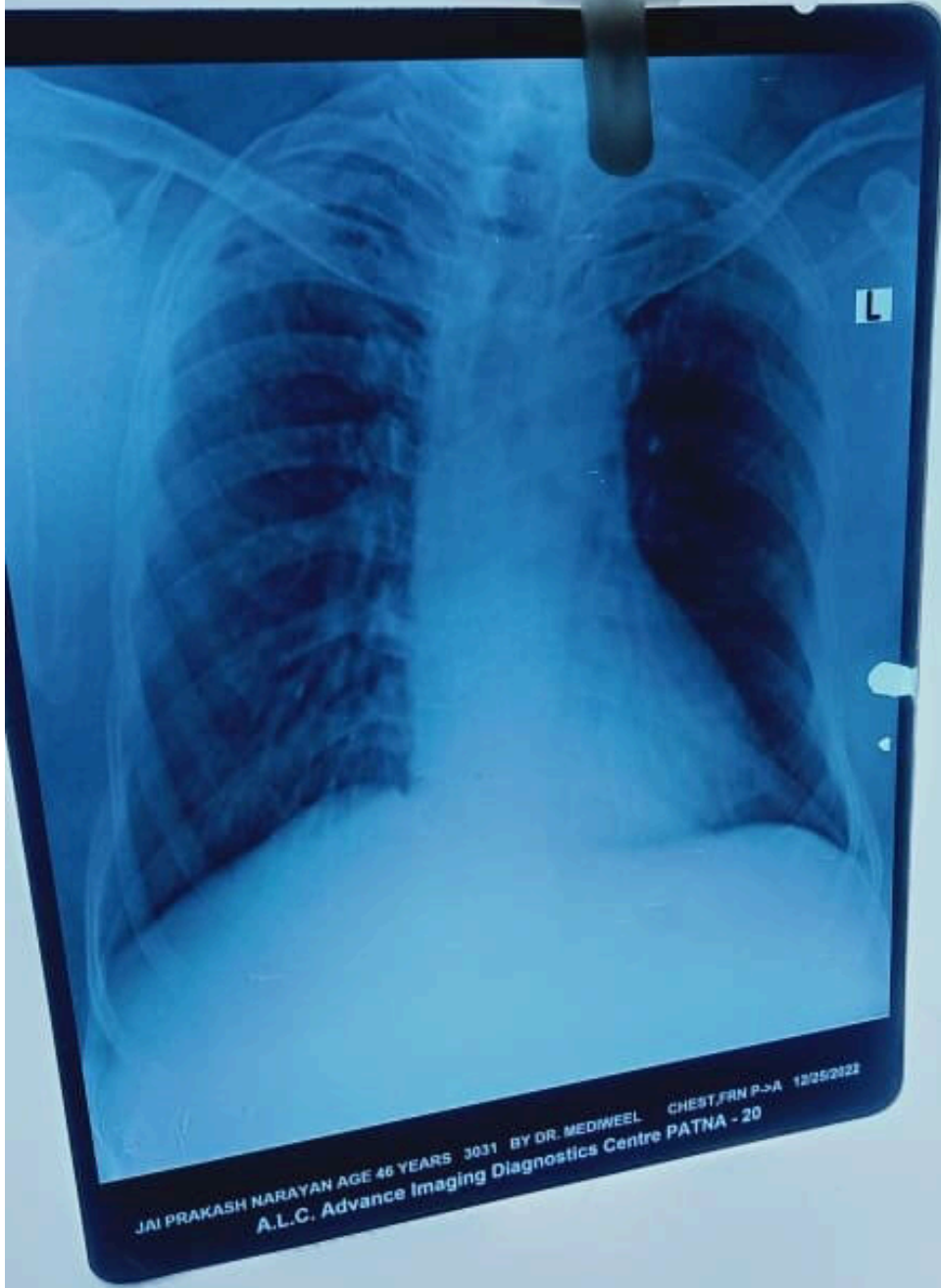





A.L.C. Advance Imaging Dignostics

(A Unit of Subham Imaging P.K. Arogyam Health & Wellness Centre)

E-95, P.C. Colony, Near Sal Netryalaya Transformer, Kankarbagh, Patna - 20

alcdignostics@gmail.com

www.pkarogyaamhealthcheckup.com

7346037474, 8711304194

OPINION MUST BE CORRELATES WITH CLINICALLY & OTHER INVESTIGATION (FOR FINAL DIAGNOSIS NOT FOR MEDICO LEGAL PURPOSE)

PATIENT NAME : Mr. JAI PRAKASH NARYAN PATIENT ID: 3031
COL DATE : 30/01/2023 REPORTING DATE: 30/01/2023 AGE SEX : 46 YRS/M
REF. BY : DR. / MEDIWHEEL

TEST NAME	RESULT	Unit	REF. RANGE
BLOOD SUGAR (F)	82.0	mg/dl	70 -110 mg/dl
LIPID PROFILE:-			
TOTAL CHOLESTROL	263.5	mg/dl	130 -250 mg/dl
TRIGLYCERIDE	146.4	mg/dl	50 -160 mg/dl
HDL CHOLESTROL	52.0	mg/dl	30 - 60 mg/dl
LDL CHOLESTROL	182.3	mg/dl	80 -130 mg/dl
VLDL CHOLESTROL	29.2	mg/dl	15 - 40 mg/dl
T.CH./HDL RATIO	5.0 : 1		Upto 5 : 1
LDL /HDL RATIO	3.5 : 1		2 - 4:1

30/1/23

Consultant Radiologist

ESTD BY:-

Dr. P. K. Tiwari
MD, M.Sc. Radio Imaging
F.D. (M) Nuclear Medicine
Consultant Interventional & Sonologist

Dr. S. Kumar
MD (Path)
Consultant Pathologist

Dr. Abhishek Kumar
MBBS, MD
Consultant Neuropatho Physiologist

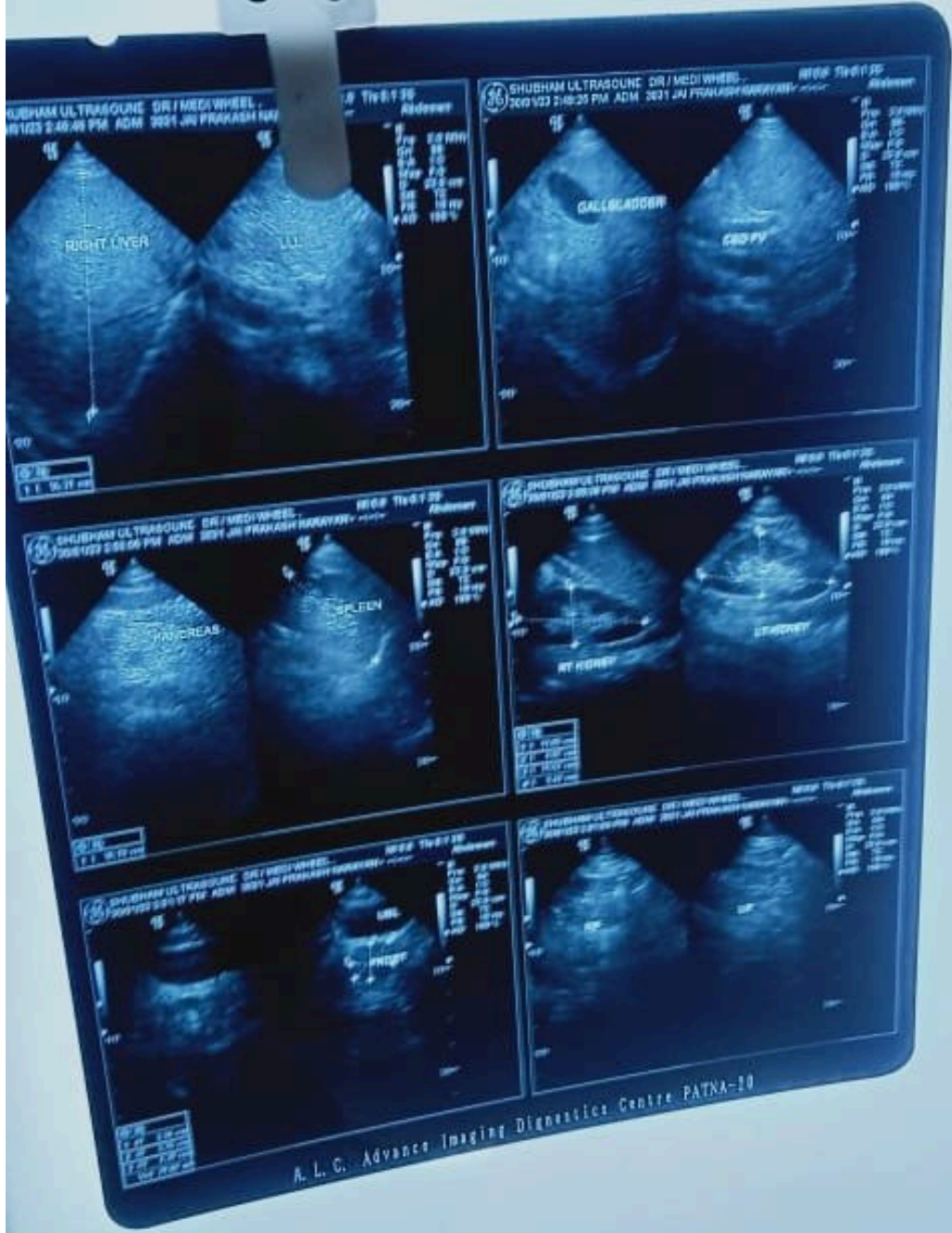
Dr. Kumari Suman
MBBS, DCO, MD
Consultant (TVS & HSG Specialist)

Dr. A. K. Singh
MBBS, FCIMRCH
Consultant Radiologist & Sonologist

PRINTING MISTAKE SHOULD BE REPORTED BACK IMMEDIATELY/यदि जना से पहले भुग का रिपन खीच नहीं होता है ।



Shot on realme C2



PATIENT NAME : MR. JAI PRAKASH NARAYAN
 COL DATE : 30/01/2023 REPORTING DATE: 30/01/2023 AGE SEX : 46 YRS/M
 REF BY : DR. / MEDWHEEL

ROUTINE EXAMINATION OF URINE

PHYSICAL EXAMINATION

Quantity 40 ml
 Appearance... Clear
 Specific gravity... 1.010
 Colour... Straw
 Sediment ... Nil

CHEMICAL EXAMINATION

Reaction 6.0
 Sugar Nil
 Albumin Nil
 Excess of Phosphate... Nil
 Nitrite..... Not done
 Bile Pigment ... Not done
 Urobilinogen ... Not done
 Chille..... Not done
 Bile Salt Not Done
 Acetone... Not done

MICROSCOPIC EXAMINATION

Erythrocytes... Nil
 Leucocytes... 1-5 / HPE
 Epith. Cell ... A. Few
 Casts ... Nil
 Crystals... Nil
 Others ... Nil

AK
 30/1/23

DR. S. KUNWAR, DR. ABHISHEK KUNWAR, DR. ANURAG KUNWAR, DR. ANSHU KUNWAR
 CONSULTANT BACTERIOLOGIST, CONSULTANT BACTERIOLOGIST, CONSULTANT BACTERIOLOGIST, CONSULTANT BACTERIOLOGIST
 PRINTING MISTAKE SHOULD BE REPORTED BACK IMMEDIATELY/सही जानकारी देना चाहिए तुरंत ही रिपोर्ट वापस लेनी चाहिए।

A.I.C. Advance Imaging Dignostics

(ISO 9001:2015 Certified Company)

(A Unit of Subham Imaging P.K. Arogyam Health & Wellness Center)

E-95, P.C. Colony, Near Sai Netralaya Transformer, Kakkarhahn, Faisla - 20

alic@imgnatics@gmail.com

www.pkarogyamhalthcheckup.com

Ph: 91-98150-11111

OPINION MUST BE CORRELATES WITH CLINICALLY & OTHER INVESTIGATION FOR FINAL DIAGNOSIS. NOT FOR MEDICO LEGAL PURPOSE


PATIENT NAME : Mr. JAI PRAKASH NARYAN PATIENT ID: 3031
COL DATE : 30/01/2023 REPORTING DATE: 30/01/2023 AGE SEX : 46 YRS/M
REF.BY : DR. / MEDIWHEEL

TEST NAME	RESULT	Unit	REF.RANGE
-----------	--------	------	-----------

BLOOD GROUP : ' B '

Rh Typing : POSITIVE

Note: Do always cross - matching before blood transfusion


30/1/20
Consultant Radiologist

ESTD BY:

Dr. P. K. Tiwari
M.D., M.Sc. (Radio Imaging)
M.D. (AB Nuclear Medicine)
Consultant Ingeradiologist & Dermatologist

Dr. S. Kumar
MD (PND)
Consultant Pathologist

Dr. Abhishek Kumar
MBBS, MD
Consultant Neurospathe Physiologist

Dr. Kumari Suman
MBBS, DGO, MCh
Consultant (TVS & HSG Specialist)

Dr. A. K. Singh
MBBS, PGDIPNH
Consultant Radiologist & Sonologist

PRINTING MISTAKE SHOULD BE REPORTED BACK IMMEDIATELY/यदि त्रुटि से पहले मुद्रण का रिपोर्ट जांच नहीं होता है।

PRINTING MISTAKE SHOULD BE REPORTED BACK IMMEDIATELY/यदि त्रुटि से पहले मुद्रण का रिपोर्ट जांच नहीं होता है।



Shot on realme C2



A.I.C. Advance Imaging Dignostics

A Unit of Siddhant Imaging P.K. Erogym Health & Wellness Centre

6-65, P.C. Colony, Near Sri Nityalaya Transformer, Kankarbagh, Patna - 20

CONTACT MUST BE ESTABLISHED WITH CONSULTANT & OTHER INVESTIGATION FOR FINAL DIAGNOSIS. NOT FOR MEDICAL LEGAL PURPOSE

PATIENT NAME : Mr. JAI PRAKASH BARIAN PATIENT BY: 9090
 COL DATE : 30/01/2023 REPORTING DATE: 02/02/2023 AGE SEX : 46-MALE
 REF BY : DR / MEDWHEEL

GLYCOSYLATED HEMOGLOBIN

TEST NAME	RESULT	UNIT	REF RANGE
HGA1c	5.9%		Below 5.7% - Normal 5.7 - 5.9% - Prediabetic ≥ 6.5% - Diabetic
AVERAGE PLASMA GLUCOSE	191.0 mg/dl		96 - 145 mg/dl - Good Control 173 - 150 mg/dl - Fair Control 155 - 180 mg/dl - Intermediate Control ≥ 185 mg/dl - Poor Control

Handwritten signature and date
 20/1/23

Consultant Radiologist

Dr. V. S. Thapar Dr. S. Kumar Dr. Anshu Kumar Dr. Kumari Suman Dr. A. K. Singh
 MB, BS, Radiology MBBS (Gen) MBBS, MD MBBS, MD, MRD MBBS, MD, MRD
 Consultant Radiologist Consultant Radiologist Consultant (TN) & USA (Specialist) Consultant Radiologist & Oncologist Consultant Radiologist & Oncologist

PRINTING MISTAKE SHOULD BE REPORTED BACK IMMEDIATELY / कृपया त्रुटि रिपोर्ट करने के लिए तुरंत सूचित करें।

Shot on realme C2



A.L.C. Advance Imaging Diagnostics

A Unit of **Advanced Imaging & Research Centre**
E-66, P.C. Colony, Near Sak Mediyalaya Translatory, Saranagarh, Patna - 85
www.patnaimaging.com | 9431000000 | 9431000000

Pt. Name :- **JAI PRAKASH NARAYAN**
Ref. By :- **DR. MEDDHHEEL**

Date :- **30-Jun-23**
Age/Sex :- **40 Yrs. M.**

Thanks for your kind referral.

X-RAY CHEST (P.A. VIEW)

The lungs on the either side show equal translucency.

The peripheral pulmonary vasculature is normal.

No focal lung lesion is seen.

The pleural spaces are normal.

Both hila are normal in size, have equal density and bear normal relationship.

The heart and trachea are central in position and no mediastinal abnormality is visible.

The cardiac size is normal.

The domes of the diaphragms are normal in position, and show smooth outline.

IMPRESSION

- NO EVIDENCE OF PULMONARY OR CARDIAC PATHOLOGY IS NOTED

20/11/23

Dr. P. K. Thapar
A.C. 100, Near Sak Mediyalaya
Patna - 85

Dr. S. Kumar
Dr. Abhishek Kumar
Dr. Kuntal Suman
Dr. A. K. Singh
Dr. P. K. Thapar
Dr. S. Kumar
Dr. Abhishek Kumar
Dr. Kuntal Suman
Dr. A. K. Singh

Consultant Radiologist

PRINTING MISTAKE SHOULD BE REPORTED BACK IMMEDIATELY/ त्रुटि कम में तुरत ग्राहक से रिपोर्ट करी। धन्यवाद !



ALC Advance Imaging Diagnostics

ALC Imaging Centre, 100, Galle Road, Colombo 03, Sri Lanka. Tel: 011 253 1111. Fax: 011 253 1112. Email: info@alcdiagnostics.com

ALC Imaging Centre, 100, Galle Road, Colombo 03, Sri Lanka. Tel: 011 253 1111. Fax: 011 253 1112. Email: info@alcdiagnostics.com

Pt. Name :- JAYAKASINARAVAN
Ref. By :- DR. MEDDI HIRLEL

Date :- 16-Jan-21
Age / Sex :- 46 Yrs. M.

REAL TIME U.S.G. OF WHOLE ABDOMEN

Thanks for your kind referral

(Report)

LIVER :- Measures 16.31 cm. Mild Enlarged in shape, size and echo texture fatty change seen in liver parenchyma. **TUBERC.** are not dilated.

Hepatic veins are normal. No SOL seen.

G.B.L. :- Lumen is echo free. Wall thickness appears normal.

C.B.D. :- Measures 3.5 mm in diameter with echo free lumen. No calculi or mass seen.

P.V. :- Measures 7.7 mm in diameter. Appears normal. No thrombus seen.

PANCREAS :- Normal in shape, size and echo texture. No calcification mass seen.

SPLEEN :- Measures 10.10 cm. Normal in shape, size and echo texture.

No SOL seen.

KIDNEY :- Both kidney shows normal shape, size & echotexture. **C.M.D.** intact.

P.C.S. is not dilated.

Right Kidney :- Measures 11.05X 4.97 cm.

Left Kidney :- Measures 11.57X 5.02 cm.

URETER :- Not dilated. No apparent calculi seen.

UBLADDER :- Shows normal in outline with echo free lumen. No calculi or mass seen.

Pro-void :- 340 ml. Post void :- 70 ml in significant

PROSTATE :- Measures 25 gms (approx). Appears mild enlarge in size, shape, and echo texture. No calcification, mass, growth seen, capsule is intact.

S.E. :- No evidence of lymphadenopathy or metastatic collection seen.

OTHERS :- No Aortic aneurysm, No pleural effusion seen on either side.

IMPRESSION

- Mild Hepatomegaly With fatty liver G-I
 - Mild enlarged prostate(BPH)G-I with 50ml PIR
- Adv:- Further work up other investigation
- Otherwise sonographically normal scans of rest organs

30/1/21

EMER

Dr. P. K. Jayawardena

MBBS, MRCP, MRCP(UK)

Consultant Radiologist

ALC Imaging Centre

100, Galle Road, Colombo 03, Sri Lanka

Tel: 011 253 1111

Fax: 011 253 1112

Email: info@alcdiagnostics.com

Consultant Radiologist

Dr. S. Kumar, Dr. Athipriya Kumari, Dr. Kumari Suman

MBBS, MRCP, MRCP(UK)

Consultant Radiologist

ALC Imaging Centre

100, Galle Road, Colombo 03, Sri Lanka

Tel: 011 253 1111

Fax: 011 253 1112

Email: info@alcdiagnostics.com

PRINTING MISTAKE SHOULD BE REPORTED BACK IMMEDIATELY

PRINTING MISTAKE SHOULD BE REPORTED BACK IMMEDIATELY





A.L.C. Advance Imaging Dignostics

(A Unit of Subham Imaging P.L. Aranyam Health & Wellness Center)

E-95, P.C. Colony, Near Sai Netralaya Transformer, Kankarbagh, Patna - 20

alcingmedic@gmail.com

www.pkorogoyamhealthcheckup.com

755607944, 9771324794

OPINION MUST BE CORRELATED WITH CLINICAL & OTHER INVESTIGATION FOR FINAL DIAGNOSIS. THIS REPORT IS FOR MEDICO LEGAL PURPOSE

PATIENT NAME : MR. JAI PRAKASH NARYAN

PATIENT ID : 1031

COL DATE : 30/01/2023 REPORTING DATE: 30/01/2023 AGE SEX:- 46 YRS/M

REF.BY : DR. / MEDIWHEEL .

TEST NAME	RESULT	Unit	REF.RANGE
LFT:-			
SGPT	42.3	IU/L	5 - 40 IU/L
S G O T	33.0	IU/L	5 - 40 IU/L
ALKALINE PHOSPHATASE	97.8	IU/L	M - 53 - 165 IU/L F - 42 - 136 IU/L
TOTAL PROTIN	7.9	g/dl	6.0 - 8.7 g/dl
SERUM ALBUMIN	4.8	g/dl	3.5 - 5.4 g/dl
SERIUM GLUBLINE	3.1	g/dl	2.3 - 3.6 g/dl
AG RATIO	1.5: 1		1.0 - 2.3 g/dl
BILIRUBIN			
TOTAL	0.64	mg/dl	0.1 - 1.1 mg/dl
DIRECT	0.21	mg/dl	0.0 - 0.32 mg/dl
INDIRECT	0.43	mg/dl	0.0 - 0.78 mg/dl
GGTP(GGT)	27.9	iu/L	8 - 38 iu/L
KFT/RFT			
URIC ACID	6.2	mg/dl	3.2 - 7.0 mg/dl
SERUM CREATNINE	1.1	mg/dl	0.6 - 1.5 mg/dl
BLOOD URIA	31.1	mg/dl	5 - 45 mg/dl
BLOOD URIA NITROZEN(BUN).	14.5	mg/dl	5 - 23 mg/dl

JSB
30/1/23

REF BY:-

Consultant Radiologist

Dr. P. K. Tiwari
MD, MBBS (Radio Imaging)
F-2 (MR Nuclear Medicine)
Consultant Imagingologist & Sonologist

Dr. S. Kumar
MD (Path)
Consultant Pathologist

Dr. Abhishek Kumar
MBBS, MD
Consultant Neurophysiologist

Dr. Kumari Suman
MBBS, DGO, MD
Consultant (GYN & HSG Specialist)

Dr. A. K. Singh
MBBS, PGDIPACB
Consultant Radiologist, Endocrinologist

PRINTING MISTAKE SHOULD BE REPORTED BACK IMMEDIATELY/यहाँ जग से पहले भुल का दिन जौन नहीं होय है ।



Shot on realme C2

ID: 3031 CASE
AGE 46Y 0M 0D
Cms 88ms

JAI PRAKASH NARAYAN
MALE

30/01/2023 13:12:25
ALC ADVANCE IMAGING DIAGNOSTICS
E95 PC COLONY KANKARBAGH PATNA

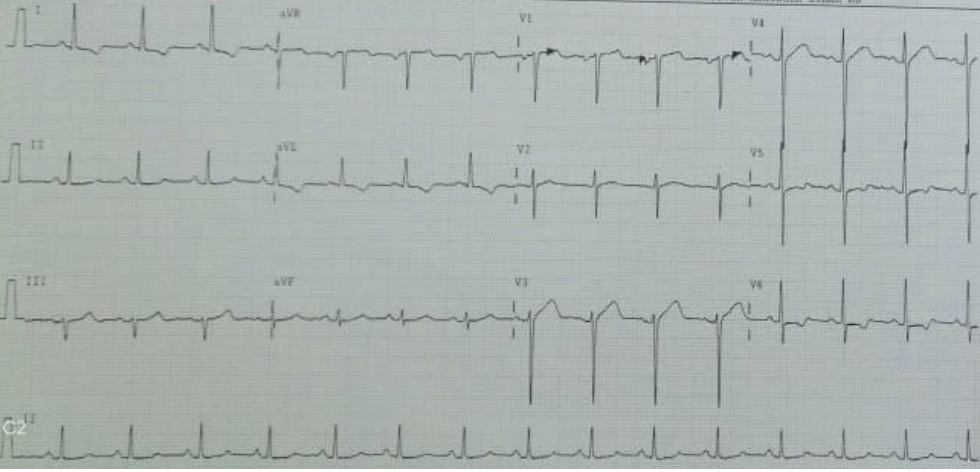
RATE 88 BPM SINGLE RHYTHM
P-R 87ms POSSIBLE ANTERIOR INFARCT - AGE UNDETERMINED
P-R 144ms LATERAL ST-T ABNORMALITY MAY BE DUE TO MYOCARDIAL ISCHEMIA
QRS 74ms
QT 364ms
QTc 415ms

--AXIS--
P 30°
QRS 11° ABNORMAL ECG
T 125°

12 SL REPORT FORMAT 124*11 50

REF DR MEDIWHEEL

Dr. DR. ABHIRAM KUMAR MD



ALC Advance Imaging
Case Memo
ADVANCE IMAGING DIAGNOSTICS
P.C. Colony, Near Sri Narayana Transformer, K. Bagh, Patna
3031
Date 30/01/23
Age 46 Y
T. Name: Jai Prakash Narayan
Ref. By: Dr. Abhiram Kumar
Mob. No. 9856123456
Region to be Scanned
Perkay



A.L.C. Advance Imaging Dignostics

(A Unit of Saham Imaging P.L. Arogyam Health & Wellness Center)

F-44, P.C. colony, Near Lal Netryulaya Transpinner, Komorbagh, Patna - 20

OPINION MUST BE CORRELATED WITH CLINICAL & OTHER INVESTIGATION FOR FINAL DIAGNOSIS. NOT FOR MEDICO LEGAL PURPOSE

PATIENT NAME : Mr. JAI PRAKASH NARYAN PATIENT ID: 3031
 COL DATE : 30/01/2023 REPORTING DATE: 30/01/2023 AGE SEX: 46 YRS/M
 REF. BY : DR. / MEDIWHEEL

TEST NAME	RESULT	Unit	REF. RANGE
ESR	12	mm/hr	<20 mm/hr
CBC			
Total W.B.C. Count	7,200	/cumm	4000 - 11,000 /cumm
R B C COUNT	4.79	Million/ CUmm	4 - 7 Million/ CUmm
Platelets count	2.05	Lakh/ cumm	1.5 - 5.0 Lakh/ cumm
Differential Count of W.B.C.			
Neutrophils	58 %		40 - 70%
Lymphocytes	35 %		25 - 40%
Eosinophils	05 %		01 - 05%
Mnonocytes	02 %		00 - 02%
Basophiles	00 %		00 - 0%
HAEMOGLOBIN	14.2	gm/dl (97.2 %)	14.6 gm/dl = 100%
PCV	43.5 %		35 - 47 %
MCV	90.9	fl	76 - 96 fl
MCH	29.8	pg	29 - 35 pg
MCHC	33.8 %		30 - 38 %

AK
30/1/23

Consultant Radiologist

ESTD BY:
 Dr. P. K. Tiwari Dr. S. Kumar Dr. Abhishek Kumar Dr. Kumari Suman Dr. A. K. Singh
 MD, M.Sc (Radio Imaging) MD (Pul) MBBS, MD MBBS, DGO, MD MBBS, FCGRICH
 PS D (AB Nuclear Medicine) Consultant Pathologist Consultant Neuropatho Physiologist Consultant (TUS & HSG Specialist) Consultant Radiologist & Sonologist
 Consultant Radiologist & Sonologist

PRINTING MISTAKE SHOULD BE REPORTED BACK IMMEDIATELY/ यदि जन्म से पहले सुन का लिंग जांच नहीं होता है ।

30/1/23