

**Indus Health Plus - General Medical Examination Form**

Health Checkup Center	SBMC
Health Checkup Date	25/11/2023
Name of the Company	APOLLO
Beneficiary Name	Shishir maheshwari

Age	36
Gender	M

Height	177
Weight	107
Blood Group	B+ve

Personal History	
Diet	Veg & Niveg.
Exercise	Not regular
Alcohol	occasional
Smoking	occasional

Vital Parameters	
BP (mm of Hg)	110/80 mm Hg
Pulse Rate (Min)	98/min
Respiratory Rate (Min)	18/min
Temperature	98°F

Past History	Diabetes/Hypertension/Asthma/COPD/TB Epilepsy/Bleeding Disorders/History of Trauma/History of Surgery	If Any Past History - (Mention)- ① Pulmonary Sarcoidosis on Rx: 2yrs foracort Rotecap 0-0-1 ② K140 - Allergic bronchitis on Rx (CDS)
--------------	---	---

Allergy History	Allergic to dust.
Family History	Mother - DM, HTN, Hypothyroidism + Father - Bronchial Asthma.
Menstrual History	-

**General Examination -**

Sr.No	System Review	Comments/Remarks
1	Pallor	NO
2	Icterus	NO
3	Clubbing	NO
4	Cyanosis	NO
5	Edema	NO
6	Lymphadenopathy	NO
7	Respiratory System (Breath Sound)	Regular
8	Cardiovascular System - S1 S2 <u>N</u>   Murmurs <u>NO</u>	
9	Central Nervous System	NAD
10	Per Abdomen	NAD
11	Skin (Optional)	NAD
12	Joints (Optional)	NAD
13	Ear - Nose and Throat (Optional)	NAD
14	Any Other Findings	

Indus Health Plus (P) Ltd.

Indus House, Pride Port, Model Colony, Pune - 411016

Contact. No - 02071772525 | Corporate Care - 02071772525 | Email: corporatecare@indushealthplus.com

www.indushealthplus.com

Ophthalmic (Eye) Checkup Details -

Eye Checkup		Corrected	Uncorrected
Visual	Right		6/6
	Left		6/6
Near Vision	Right		N5
	Left		N5

	Right Eye	Left Eye
Color Vision	N	N

	Right Eye	Left Eye
Color Blindness	NO	NO

Eye Checkup Impression/Remarks/Abnormalities -

Remarks/Observations/Medical Recommendations -

**Fitness Status** (Circle or Tick)

**Fit**

**Unfit**

For Examining Doctors -

Examining Doctor Name and Signature -

*[Signature]*  
Dr. MUKUL ARTE MBBS, DNB  
Regn. No. 44293 (MMC)  
Approved By DG Shipping (GOI)  
Consultant in Marine Medicine & Aviation Medicine  
A-101-102, Heritage Plaza, Teli Cross Lane,  
Andheri East, Mumbai-400 069  
SEA BIRD MEDICARE CENTRE

Stamp -



Examining Date & Time -

25/11/2023

**Indus Health Plus (P) Ltd.**

Indus House, Pride Port, Model Colony, Pune – 411016

**Contact. No** – 02071772525 | **Corporate Care** – 02071772525 | **Email:** corporatecare@indushealthplus.com

[www.indushealthplus.com](http://www.indushealthplus.com)



*Sea Bird*  
Sea Bird Medicare Centre

Report ID : **SMM251192544** Reg. : **25-Nov-2023**  
Patient Name : **Mr. SHISHIR MAHESHWARI** Report Date : **25-Nov-2023**  
Rank : Company Name : **M/S. APOLLO HEALTH AND LIFESTYLE**  
Ref By : **DR. MUKUL ARTE** Age/Sex : **36 Year / Male**

**CHEST X RAY REPORT**

X-Ray No : 12635

Investigation : Chest PA View.

Bony thoracic cage is normal.

Cardiac silhouette appears normal in size and configuration.


Both lungs shows equal translucency and normal vasculature.

Both Hemidiaphragm visualised normal.

No evidence of any active parenchymal lesion seen.

**Impression :**

**Normal Chest X-Ray.**

  
Dr. Jacob  
Mathew MD

**Proudly... Caring For You**

HO- Sea Bird Medicare Centre (ISO 9001:2015): A-101-102, Heritage Plaza, Teli Cross Lane, Andheri East (Nr. Station), Mumbai- 69. Tel: 022- 46032704

Powai: 022-25701053 / 25704157

Kochi: 0484- 2322022 / 4032022

Website: [www.seabirdhf.com](http://www.seabirdhf.com) | Email: [seabird@seabirdhf.com](mailto:seabird@seabirdhf.com)



*Sea Bird*  
Sea Bird Medicare Centre

Report ID : **SMM251192544** Reg. : **25-Nov-2023**  
Patient Name : **Mr. SHISHIR MAHESHWARI** Report Date : **25-Nov-2023**  
Rank : Company Name : **M/S. APOLLO HEALTH AND LIFESTYLE**  
Ref By : **DR. MUKUL ARTE** Age/Sex : **36 Year / Male**

**SONOGRAPHY (ABDOMEN)**

Ref No : 25/11/2023

Investigation : Abdomen Sonography

The real-time Sonography using 3.5 MHZ transducer shows:

Liver normal in size and echotexture.

The GB, Pancreas & Spleen are within normal limits.

Both Kidneys are normal in size, position and echogenicity; CM differentiation normal .  
No hydronephrosis or calculi noted.

Bladder normal in contour, capacity and wall thickness; No vesical calculi noted.

This sonography study does not rule out intestinal lesions or mucosal lesions of other Viscera.

Impression :

No Significant abnormality noted on the study.

Dr. Jacob  
Mathew MD

Dr. Jagmohan L. Chopra MD  
Dr. Asghar Majeed

**Proudly... Caring For You**

HO- Sea Bird Medicare Centre (ISO 9001:2015): A-101-102, Heritage Plaza, Teli Cross Lane, Andheri East (Nr. Station), Mumbai- 69. Tel: 022- 46032704

Powai: 022-25701053 / 25704157

Kochi: 0484- 2322022 / 4032022

Website: [www.seabirdhf.com](http://www.seabirdhf.com) | Email: [seabird@seabirdhf.com](mailto:seabird@seabirdhf.com)



Report ID : SMM251192544  
Patient Name : Mr. SHISHIR MAHESHWARI  
Rank :  
Ref By : DR. MUKUL ARTE  
Location : SEA BIRD- ANDHERI

Reg. : 25-Nov-2023  
Report Date : 25-Nov-2023  
Company Name : M/S. APOLLO HEALTH AND  
Age/Sex : 36 Year / Male

### HEMATOLOGY

#### INVESTIGATION

#### Complete Blood Count

INVESTIGATION	OBSERVED VALUE	UNITS	REFERENCE RANGE
Haemoglobin	14.6	gm/dl	13-18 gm/dl
Total W.B.C	6600	/cu.mm	4000-11000 /cu.mm
Neutrophils	62	%	50-70 %
Lymphocytes	36	%	20-40 %
Eosinophils	02	%	0-7 %
Monocytes	00	%	0-8 %
Basophils	00	%	0-2 %
R.B.C Total	4.95	millions/cu .mm	4.5-5.5 millions/cu.mm
P.C.V	37.6	%	42-55 %
MCV	76.1	femolitre	80-96 femolitre
MCH	29.5	picogram	27-33 picogram
MCHC	38.8	%	32-36 %
W.B.C Morphology	Normal		
R.B.C Morphology	Normal		
Platelet Count	261000	/cu.mm	150000-450000 /cu.mm
<b>Blood Group</b>			
Blood Group	B Positive		
<b>ESR</b>			
ESR	16	mm/hr	0-15 mm/hr

---END OF REPORT---

Kindly Correlate with clinical conditions.

Remark : ---

DR. SANDIP MOHANRAO HUDDERAR  
MBBS, DCP  
Pathologist

M O I C

SUPARNA B DAREKAR  
Lab Technician

Proudly... Caring For You

HO- Sea Bird Medicare Centre (ISO 9001:2015): A-101-102, Heritage Plaza, Teli Cross Lane, Andheri East (Nr. Station), Mumbai- 69. Tel: 022- 46032704

Powai: 022-25701053 / 25704157

Kochi: 0484- 2322022 / 4032022

Website: www.seabirdhf.com | Email: seabird@seabirdhf.com



*Sea Bird*  
Sea Bird Medicare Centre

Report ID : **SMM251192544**  
Patient Name : **Mr. SHISHIR MAHESHWARI**  
Rank :  
Ref By : **DR. MUKUL ARTE**  
Location : **SEA BIRD- ANDHERI**

Reg. : **25-Nov-2023**  
Report Date : **25-Nov-2023**  
Company Name : **M/S. APOLLO HEALTH AND**  
Age/Sex : **36 Year / Male**


### LIPID PROFILE

<u>INVESTIGATION</u>	<u>OBSERVED VALUE</u>	<u>UNITS</u>	<u>REFERENCE RANGE</u>
Serum. CHOLESTEROL (CHOD - PAP)	189	mg /dl	145-240 mg/dl
Serum. TRIGLYCERIDE (GPO - PAP)	<b>224</b>	mg /dl	25-160 mg/dl
S.HDL CHOLESTEROL	38	mg/dl	35-65 mg/dl
VLDL CHOLESTEROL	<b>44.8</b>	mg/dl	Upto 40
LDL CHOLESTEROL (calculate)	106.2	mg/dl	Upto 150
CHOL/HDL CHOL(Ratio)	4.9		Upto 5.0
LDL CHOL/HDL RATIO	2.7		0-3.0

---END OF REPORT---

**Kindly Correlate with clinical conditions.**

Remark : ---

  
DR.SANDIP MOHANRAO HUDDEDAR  
MBBS; DCP  
**Pathologist**

  
M O I C

  
SUPARNA B DAREKAR  
**Lab Technician**

**Proudly... Caring For You**

HO- Sea Bird Medicare Centre (ISO 9001:2015): A-101-102, Heritage Plaza, Teli Cross Lane, Andheri East (Nr. Station), Mumbai- 69. Tel: 022- 46032704

Powai: 022-25701053 / 25704157

Kochi: 0484- 2322022 / 4032022

Website: [www.seabirdhf.com](http://www.seabirdhf.com) | Email: [seabird@seabirdhf.com](mailto:seabird@seabirdhf.com)



# Sea Bird

Sea Bird Medicare Centre

Report ID : **SMM251192544**  
Patient Name : **Mr. SHISHIR MAHESHWARI**  
Rank :  
Ref By : **DR. MUKUL ARTE**  
Location : **SEA BIRD- ANDHERI**

Reg. : **25-Nov-2023**  
Report Date : **25-Nov-2023**  
Company Name : **M/S. APOLLO HEALTH AND**  
Age/Sex : **36 Year / Male**

## BIO-CHEMISTRY

### INVESTIGATION

#### **Liver Function Test**

	<u>OBSERVED VALUE</u>	<u>UNITS</u>	<u>REFERENCE RANGE</u>
SGOT	15	IU/L	0-37 IU/L
SGPT	37	IU/L	9-43 IU/L
GGT	<b>53</b>	IU/L	0-49 IU/L
Sr.Bilirubin (T)	0.4	mg/dl	0.2-1.2 mg/dl
Sr.Bilirubin (D)	0.1	mg/dl	0.0-0.3 mg/dl
Sr.Bilirubin (I)	0.3	mg/dl	
Total Protien	6.0	g/dl	6.0-8.0 g/dl
Sr.Albumin	3.7	g/dl	3.2-5.0 g/dl
Sr.Globulin	2.3	g/dl	2.0 3.5 g/dl
A/G Ratio	1.6		
Alkaline Phosphatase	59	IU/L	40-129 IU/L

#### **Renal Function Test**


BUN	10	mg/dl	6-21 mg/dl
Sr.Creatinine	0.7	mg/dl	0.7-1.4 mg/dl
Uric Acid	6.3	mg/dl	2.5-7.2 mg/dl

#### **Blood Sugar Estimation**

Fasting Blood Sugar	95	mg/dl	70-110 mg/dl
Fasting Urine Sugar	Absent		
Post Prandial Blood Sugar	132	mg/dl	70-140 mg/dl
Post Prandial Urine Sugar	Absent		
Glycosylated Haemoglobin (HBA1C)	5.1	%	4.5-6.3%

Kindly Correlate with clinical conditions.

Remark : ---

  
DR.SANDIP MOHANRAO HUDDEDAR  
MBBS, DCP  
Pathologist

  
M O I C

  
SUPARNA B DAREKAR  
Lab Technician

Proudly... Caring For You

HO- Sea Bird Medicare Centre (ISO 9001:2015): A-101-102, Heritage Plaza, Teli Cross Lane, Andheri East (Nr. Station), Mumbai- 69. Tel: 022- 46032704

Powai: 022-25701053 / 25704157

Kochi: 0484- 2322022 / 4032022

Website: [www.seabirdhf.com](http://www.seabirdhf.com) | Email: [seabird@seabirdhf.com](mailto:seabird@seabirdhf.com)



Report ID : **SMM251192544**  
Patient Name : **Mr. SHISHIR MAHESHWARI**  
Rank :  
Ref By : **DR. MUKUL ARTE**  
Location : **SEA BIRD- ANDHERI**


Reg. : **25-Nov-2023**  
Report Date : **25-Nov-2023**  
Company Name : **M/S. APOLLO HEALTH AND**  
Age/Sex : **36 Year / Male**


**SEROLOGY TESTS**

<b><u>INVESTIGATION</u></b>	<b><u>OBSERVED VALUE</u></b>	<b><u>UNITS</u></b>	<b><u>REFERENCE RANGE</u></b>
HIV I & II	NEGATIVE		

---END OF REPORT---

Kindly Correlate with clinical conditions.  
Remark : ---

  
DR.SANDIP MOHANRAO HUDDEDAR  
MBBS, DCP  
Pathologist

  
M O I C

  
SUPARNA B DAREKAR  
Lab Technician

**Proudly... Caring For You**

HO- Sea Bird Medicare Centre (ISO 9001:2015): A-101-102, Heritage Plaza, Teli Cross Lane, Andheri East (Nr. Station), Mumbai- 69. Tel: 022- 46032704

Powai: 022-25701053 / 25704157

Kochi: 0484- 2322022 / 4032022

Website: [www.seabirdhf.com](http://www.seabirdhf.com) | Email: [seabird@seabirdhf.com](mailto:seabird@seabirdhf.com)





Report ID : **SMM251192544**  
Patient Name : **Mr. SHISHIR MAHESHWARI**  
Rank :  
Ref By : **DR. MUKUL ARTE**  
Location : **SEA BIRD- ANDHERI**

Reg. : **25-Nov-2023**  
Report Date : **25-Nov-2023**  
Company Name : **M/S. APOLLO HEALTH AND**  
Age/Sex : **36 Year / Male**

**URINE ROUTINE**

<b><u>INVESTIGATION</u></b>	<b><u>OBSERVED VALUE</u></b>	<b><u>UNITS</u></b>	<b><u>REFERENCE RANGE</u></b>
Colour	PALE YELLOW		PALE YELLOW
Appearance	CLEAR		CLEAR
Specific Gravity	1.010		1.030
pH	ACIDIC		ACIDIC
Odour	AROMATIC		AROMATIC
Proteins (UR)	ABSENT		ABSENT
Sugar	ABSENT		ABSENT
Bile Salts	ABSENT		ABSENT
Bile Pigments	ABSENT		ABSENT
Ketones (UR)	ABSENT		ABSENT
Occult Blood	ABSENT		ABSENT
Urobilinogen(UR)	ABSENT		ABSENT
Pus Cells (UR)	2 -3	/hpf	2-3/hpf
RBC cells	ABSENT	/hpf	2-3/hpf
Epithelial Cells	1 - 2	/hpf	1-2/hpf
Casts (UR)	ABSENT	/hpf	
Crystals	ABSENT	/hpf	
Bacteria (UR)	ABSENT		ABSENT
Others (UR)	ABSENT		

---END OF REPORT---

Kindly Correlate with clinical conditions.  
Remark : ---

  
DR.SANDIP MOHANRAO HUDDEDAR  
MBBS, DCP  
Pathologist

  
M O I C

  
SUPARNA B DAREKAR  
Lab Technician

**Proudly.. Caring For You**

HO- Sea Bird Medicare Centre (ISO 9001:2015): A-101-102, Heritage Plaza, Teli Cross Lane, Andheri East (Nr. Station), Mumbai- 69. Tel: 022- 46032704

Powai: 022-25701053 / 25704157

Kochi: 0484- 2322022 / 4032022

Website: [www.seabirdhf.com](http://www.seabirdhf.com) | Email: [seabird@seabirdhf.com](mailto:seabird@seabirdhf.com)



*Sea Bird*  
**Sea Bird Medicare**

**NAME** : SHISHIR MAHESHWARI  
**AGE/SEX** : 37 YRS / M  
**COMPANY** : APOLLO  
**DATE** : 25/11/2023

**2D ECHOCARDIOGRAPHY AND COLOR DOPPLER STUDY**

**2D ECHOCARDIOGRAPHY FINDINGS:**


1. Normal sized LV with good contractility. LVEF appears to be 60 %.  
No regional wall motion abnormality seen.
2. Structurally normal cardiac valves.
3. Normal sized RV with good contractility.  
RA and LA are normal in size.
4. No obvious clot seen.
5. No vegetations or pericardial effusion.
6. Intact IVS/IAS.

**SPECTRAL AND COLOR DOPPLER STUDY:**

Normal flow velocities and color flow mapping seen across both atrioventricular and semilunar valves. No intracardiac shunt or regurgitation noticed.  
Doppler estimated Pulmonary artery pressure is 27 mm Hg.

**Impression**

Normal LV systolic function  
Normal sized cardiac chambers.  
Normal cardiac valves.  
No clots/ vegetations.  
No Pericardial effusion  
No Pulmonary Artery Hypertension

  
DR. JACOB MATHEW MD, DMM, DTCD  
PHYSICIAN MARINE MEDICINE

DR. JACOB MATHEW MD, DMM, DTCD  
Reg. No. (MMD) 41250  
'A' Wing 102, Nerradi, E-2, Tell Cross Lane,  
Near Andhra (4) Sec. Main, 400 900  
SEA BIRD MEDICARE

**NOTE:**

NORMAL 2D ECHOCARDIOGRAPHY REPORT DOES NOT RULE OUT CRITICAL CAD.  
KINDLY CORRELATE CLINICALLY.

**M-MODE MEASUREMENTS****NORMAL VALUES****MITRAL VALVE**

DE AMPLITUDE	17mm	(20-37mm)
EF SLOPE	160 mm/sec	(18-150mm/sec)
EPSS	04 mm	(less than 5mm)

**TRICUSPID VALVE****NORMAL****PULMONARY VALVE**

EF SLOPE	<b>NORMAL</b>
a WAVE	<b>NORMAL</b>
SYSTOLIC NOTCH	<b>ABSENT</b>

**AORTIC VALVE**

STRUCTURE	<b>NORMAL</b>	
CLOSURE LINE	<b>CENTRAL</b>	
CUSPAL OPENING	17 mm	(15-26mm)
AO ROOT	23 mm	(20-37mm)

LA	30 mm	(19-40mm)
----	-------	-----------

**RV/LV MEASUREMENTS**

RVID(d)	16 mm	(7-23mm)
LVID(d)	45 mm	(36-56mm)
LVID(s)	29 mm	(24-42mm)
IVS (d)	11 mm	(6-12mm)
LVPW(d)	12 mm	(6-11mm)
LVEF	60%	(50%-70%)



Report ID : SMM251192544  
Patient Name : Mr. SHISHIR MAHESHWARI  
Rank :  
Ref By : DR. MUKUL ARTE  
Location : SEA BIRD- ANDHERI

Reg. : 25-Nov-2023  
Report Date : 27-Nov-2023  
Company Name : M/S. APOLLO HEALTH AND  
Age/Sex : 36 Year / Male

### THYROID FUNCTION TEST

INVESTIGATION	OBSERVED VALUE	UNITS	REFERENCE RANGE
TSH	5.58	µIU/ml	0.25-5 µIU/ml
T3	2.05	nmol/l	0.92-2.33 nmol/l
T4	90.18	nmol/l	60-120 nmol/l

#### PRINCIPLE

The assay principle combines an enzyme immunoassay competition method with a final fluorescent detection (ELFA).

#### INTERPRETATION

**TSH** : A high TSH result often means an under active thyroid gland that is not responding adequately to the stimulation of TSH due to some type of acute or chronic thyroid dysfunction. A high TSH value can also occur when someone with a known thyroid disorder or who has had their thyroid gland removed is receiving too little thyroid hormone medication. A low TSH result can indicate an over active thyroid gland (hyperthyroidism) or excessive amounts of thyroid hormone medication in those who are being treated for an under active (or removed) thyroid gland. An abnormal TSH test result is usually followed by additional testing to investigate the cause of the increase or decrease.


**T3**: Triiodothyronine T3 contributes significantly to the maintenance of the euthyroid state, and the total T3 concentration has a role in screening for thyroid disease in conjunction with other tests. T3 alone cannot diagnose hypothyroidism, but it may be more sensitive than thyroxine (T4) for hyperthyroidism.

**T4** :Thyroxine accounts for at least 90% of circulating protein-bound iodine. While >99.9% of T4 is protein-bound, primarily to thyroglobulin (TBG), it is the free fraction that is biologically active. In most patients the total T4 level is a good indicator of thyroid status, however it can sometimes be inadequate, and diagnostic efficiency may be improved by use of a total T4 test in conjunction with other tests.


---END OF REPORT---

Kindly Correlate with clinical conditions.

Remark : ---

  
DR. SANDIP MOHANRAO HUDDEDAR  
MBBS, DCP  
Pathologist

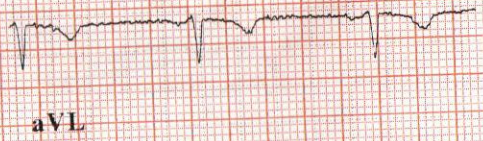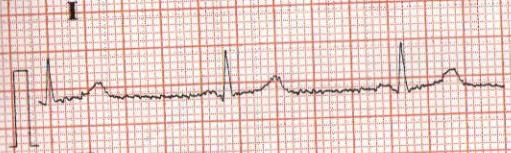M O I C

  
SUPARNA B DAREKAR  
Lab Technician

Proudly... Caring For You

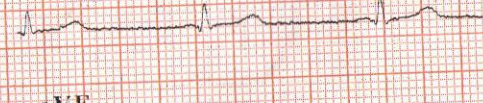
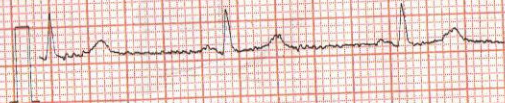
10mm/mV 0.67~25Hz AC50

08-06-2005 08:24:50



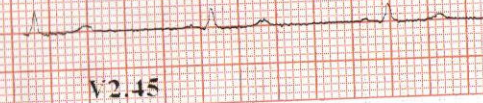
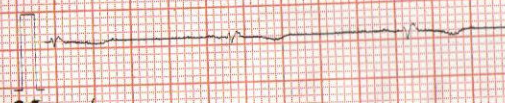I

aVR



II

aVL



III

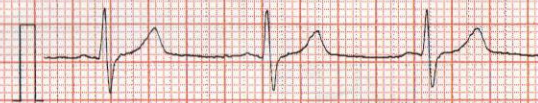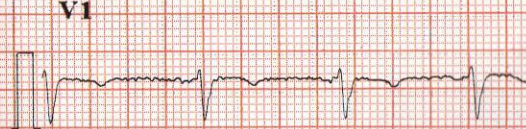aVF

25mm/s

V2.45

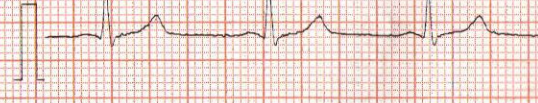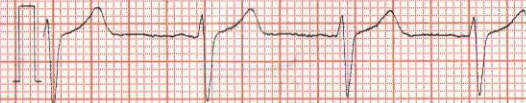10mm/mV 0.67~25Hz AC50

10mm/mV 0.67~25Hz AC50



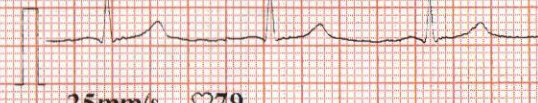
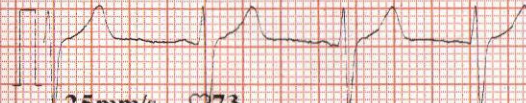
V1

V4



V2

V5



25mm/s ♡73

25mm/s ♡79

### E. C. G. REPORT

587 units

Q. WAVE \_\_\_\_\_ N \_\_\_\_\_

THM \_\_\_\_\_

Reg. rate

QRS COMPLEX \_\_\_\_\_ N \_\_\_\_\_

TAGE \_\_\_\_\_

N

ST. SEGMENT \_\_\_\_\_ i or. at rest

WAVE \_\_\_\_\_

N

T. WAVE \_\_\_\_\_

INTERVAL \_\_\_\_\_

  
Dr. MUKUL ARTE MBBS, DNB  
Regn. No: 44293 (MIMC)  
Approved By DC Shipping (GGI)  
Consultant in Marine Medicine & Aviation Medicine  
A-101-102, Heritage Plaza, Telli Cross Lane,  
Andheri East, Mumbai-400 069  
SEA BIRD MEDICARE CENTRE

MARKS \_\_\_\_\_

### ELECTROCARDIOGRAPHIC REPORT



Sea Bird  
Sea Bird Medicare Centre

NAME \_\_\_\_\_

Mr. Rishir Maheshwari

AGE \_\_\_\_\_

36y

DATE \_\_\_\_\_

25/11/2025

- 102, Heritage Plaza, Telli Cross Lane, Nr. Andheri (E) Stn., Andheri (East), Mumbai - 400 069. Tel.: 2682 1823, 5578 3905
- 102-103-104, Gateway Plaza, Central Avenue Road, Hiranandani Gardens, Powai, Mumbai - 400076 Tel.: 2570 4157