

आधार - आम आदमी का अधिकार

5780 7276 4816



भारत सरकार  
GOVERNMENT OF INDIA

नवदीप राठी  
Navdeep Rathie  
जन्म वर्ष / Year of Birth : 1987  
पुरुष / Male



Navdeep

Dr. NITIN AGARWAL  
MBBS, MD  
Regn. No. DMC-R-1436

ONEPLUS ULTRASOUND LAB  
47, Harsh Vihar, Pitam Pura,  
Delhi-110034  
Ph. 011-42480101, 9599913051  
E-mail: oneplusul@gmail.com



भारतीय विशिष्ट पहचान प्राधिकरण  
UNIQUE IDENTIFICATION AUTHORITY OF INDIA

पता: S/O बलराज सिंह राठी, विपिन  
सखोल बहादुरगढ़, संखोल, संखोल, झज्जर,  
हरियाणा, 124507  
Address: S/O Balraj Singh  
Rathie, vpo sankhol bahadurgarh,  
Sankhol, Sankhol, Jhajjar,  
Haryana, 124507



help@uidai.gov.in




www.uidai.gov.in

P.O. Box No.1947  
Bengaluru-560 001



1947  
1800 180 1947





*[Signature]*  
**DR. NITIN AGARWAL**  
 MBBS, MD  
 Regn. No. DMC-R-1436

*[Signature]*

**ONEPLUS ULTRASOUND LAB**  
 47, Harsh Vihar, Pitam Pura,  
 Delhi-110034  
 Ph. 011-42480101, 9599913051  
 E-mail: oneplusul@gmail.com

# ONEPLUS ULTRASOUND LAB

47, HARSH VIHAR, PITAMPURA, DELHI- 110034

Mr. NAVDEEP RATHEE  
 Age : 35/M  
 Ref. by : MEDIWHEEL  
 Indication1 :  
 Indication2 :  
 Indication3 :  
 COMMENTS :

ID : 2038  
 Ht/Wt : 170/82  
 Recorded : 8-11-2022 12:24  
 Medication1 :  
 Medication2 :  
 Medication3 :

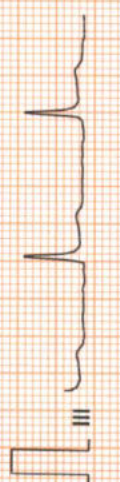
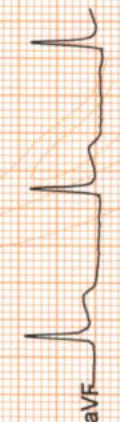
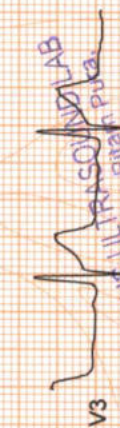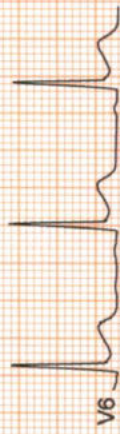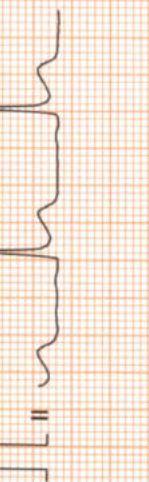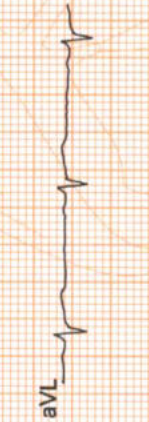
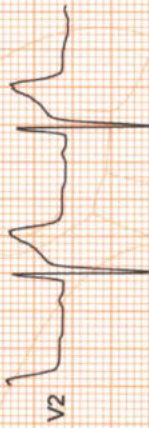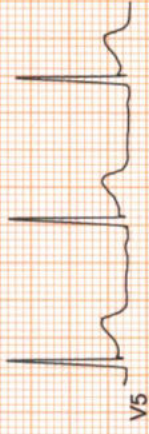

BPM : 81  
 BP : 134/86  
 P Axis : 19 deg  
 QRS Axis : 65 deg  
 T Axis : 53 deg

P duration : 76 msec  
 PR duration : 140 msec  
 QRS duration : 106 msec  
 QT interval : 316 msec  
 QTc interval : 352 msec

Raw E.C.G. (Sec)

Unconfirmed Report Reviewed By: **Dr. P.K. GUPTA**  
**MBBS, MD**

Cardiologist



*Filtered*

ONEPLUS ULTRASOUND LAB  
 47, Harsh Vihar, Pitampura  
 Delhi-110034  
 Ph: 011-42438101, 95999413051  
 E-mail: onepplus@gmail.com

# ONEPLUS ULTRASOUND LAB

47, HARSH VIHAR PITAMPURA DELHI 110034

Mr. NAVDEEP RATHEE  
 Age/Sex : 35/M  
 Ref. by : MEDIWHEEL  
 Indication1 :  
 Indication2 :  
 Indication3 :

ID : 995  
 Ht/Wt : 170/82  
 Recorded : 8-11-2022 12:28

TREADMILL TEST SUMMARY REPORT  
 Protocol: BRUCE  
 History:  
 Medication1 :  
 Medication2 :  
 Medication3 :

PHASE	PHASE TIME	STAGE TIME	SPEED (Km./Hr.)	GRADE (%)	H.R. (BPM)	B.P. (mmHg)	RPP X100	II	ST LEVEL (mm) V2	V5	METS
STANDING SUPINE					84 85	134/86 134/86	112 113	1.6 1.6	3.8 3.8	2.1 2.1	
STAGE 1	2:59	2:59	2.70	10.00	116	134/86	155	1.8	3.8	2.5	4.80
STAGE 2	5:59	2:59	4.00	12.00	123	146/88	179	1.3	4.4	2.4	7.10
STAGE 3	8:59	2:59	5.40	14.00	151	158/90	238	0.6	4.7	1.7	10.00
STAGE 4	9:14	0:14	6.70	16.00	159	170/92	270	0.7	4.5	1.2	10.31
PEAK EXER	9:23	0:23			165	170/92	280	0.4	4.3	1.0	10.51
RECOVERY	2:59	2:59	0.00	0.00	104	136/86	141	0.7	1.8	0.9	

### RESULTS

Exercise Duration : 9:23 Minutes  
 Max Heart Rate : 165 bpm 89 % of target heart rate 185 bpm  
 Max Blood Pressure : 170/92 mmHg  
 Max Work Load : 10.51 METS

*Negative for ischemic change*

### IMPRESSIONS

ONEPLUS ULTRASOUND LAB  
 47, Harsh Vihar, Pitam Pura,  
 Delhi-110034  
 Ph. 011-42880101, 9599913051  
 E-mail: oneplusul@gmail.com

Dr. P.K. GUPTA  
 M.B.B.S., MD  
 Reg. No. 071  
 Cardiologist

*Navdeep*

# ONEPLUS ULTRASOUND LAB

Mr. NAVDEEP RATHEE  
I.D. : 995

AGE/SEX : 35/M

RECORDED : 8-11-2022 12:28

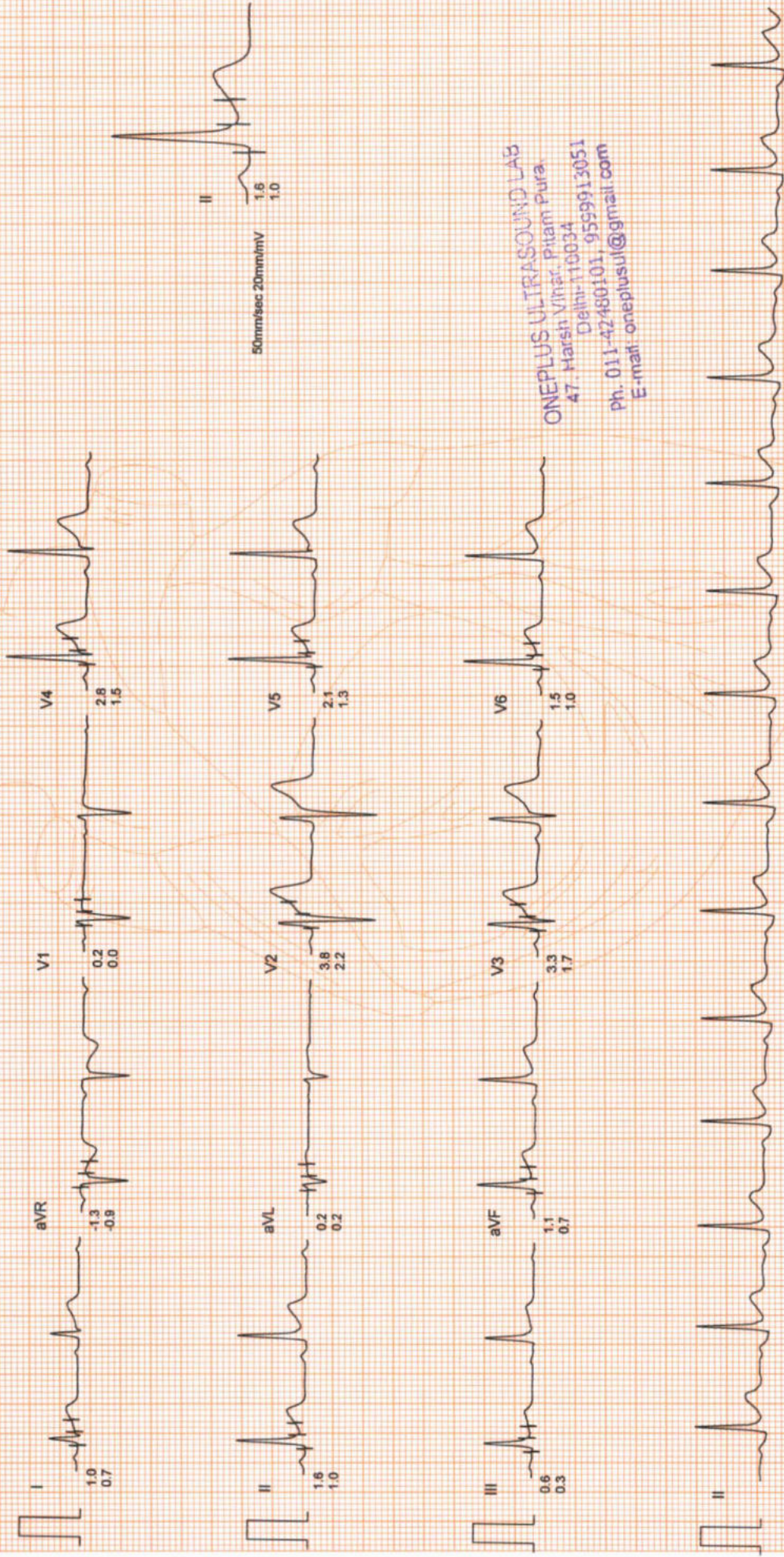
RATE : 84 BPM

B.P. : 134/86 mmHg

ST @ 10mm/mV  
80ms PostJ

STANDING  
PRETEST

LINKED MEDIAN



ONEPLUS ULTRASOUND LAB  
47, Harsh Vihar, Pitam Pura,  
Delhi-110034  
Ph. 011-42480101, 9599913051  
E-mail: oneplusul@gmail.com

# ONEPLUS ULTRASOUND LAB

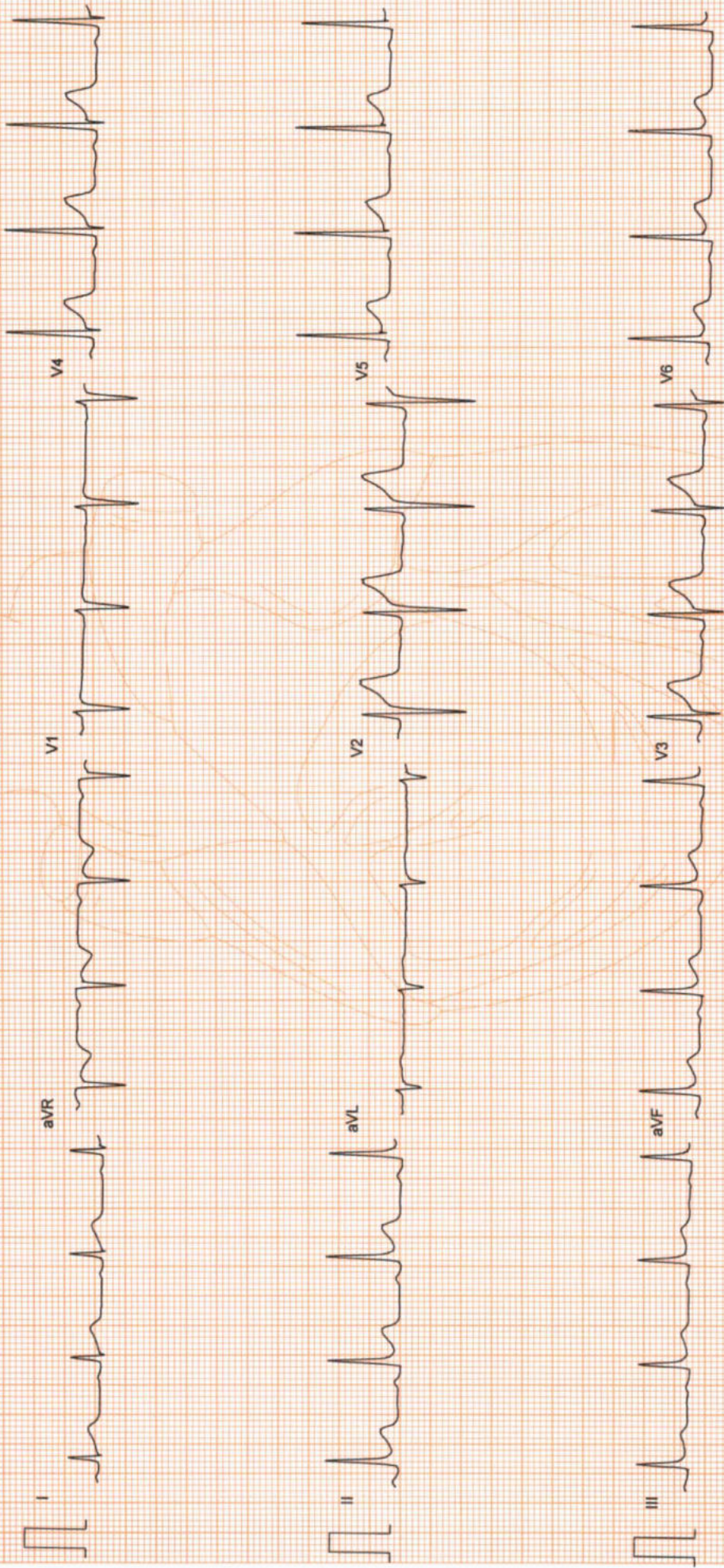
Mr. NAVDEEP RATHEE  
I.D. : 995  
AGE/SEX : 35/M

RECORDED : 8-11-2022 12:28  
RATE : 85 BPM  
B.P. : 134/86 mmHg

ST @ 10mm/mV  
80ms PostJ

SUPINE  
PRETEST

RAW E.C.G.



ONEPLUS ULTRASOUND LAB  
47, Haren Vihar, Pitam Pura,  
Delhi-110034  
ph. 011-42400101, 9599915051  
E-mail: oneplusuk@gmail.com

# ONEPLUS ULTRASOUND LAB

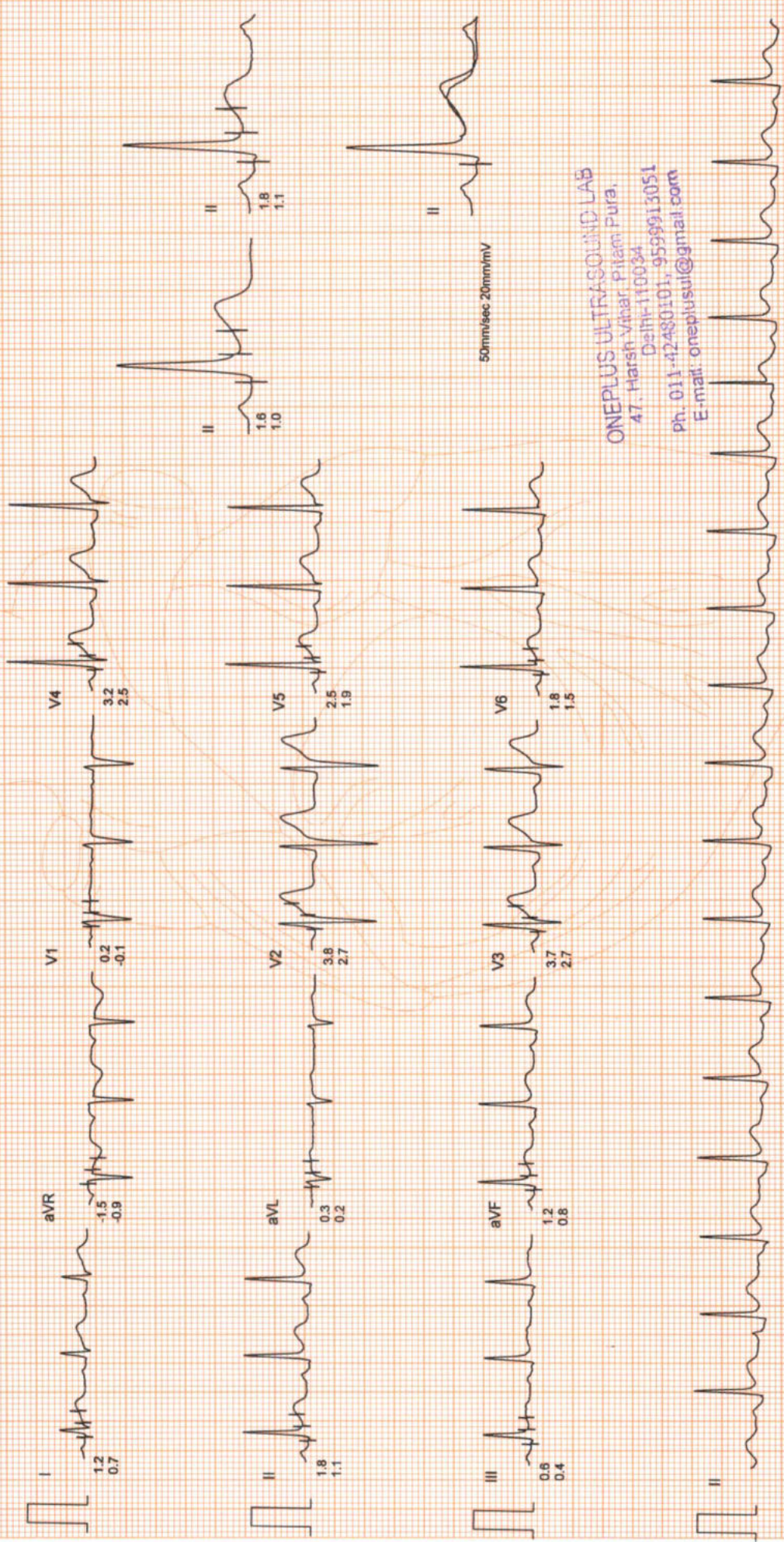
Mr. NAVDEEP RATHEE  
 I.D. : 995  
 AGE/SEX : 35/M  
 RECORDED : 8-11-2022 12:28

RATE : 116 BPM  
 B.P. : 134/86 mmHg

ST @ 10mm/mV  
 80ms PostJ  
 SPEED : 2.7 Km./Hr.  
 GRADE : 10.0 %

LINKED MEDIAN

BRUCE  
 EXERCISE 1  
 PHASE TIME : 2:59  
 STAGE TIME : 2:59



ONEPLUS ULTRASOUND LAB  
 47, Harsh Vihar Pitam Pura,  
 Delhi-110034  
 Ph. 011-42480101, 9599913051  
 E-mail: oneplusul@gmail.com



# ONEPLUS ULTRASOUND LAB

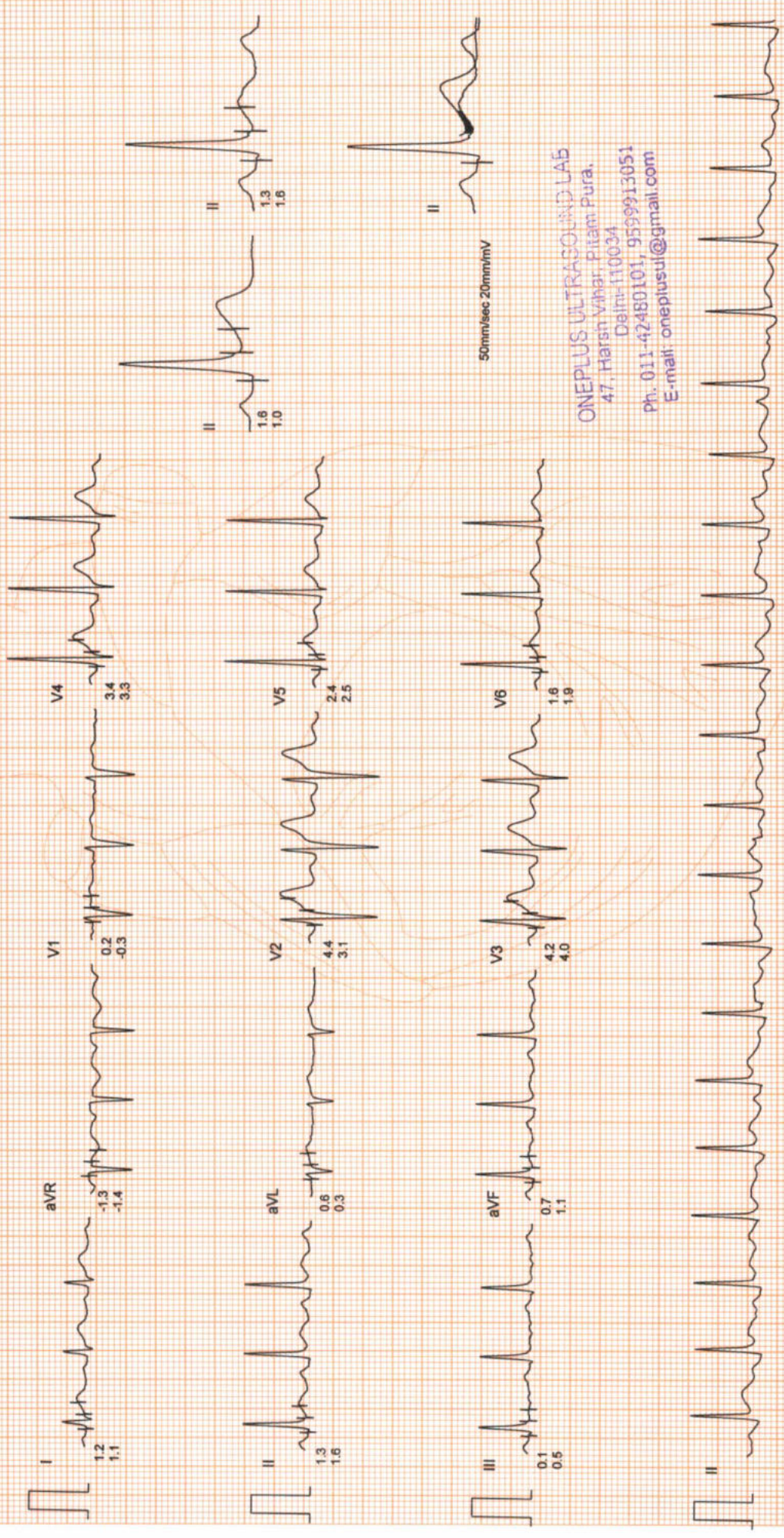
Mr. NAVDEEP RATHEE  
I.D. : 995  
AGE/SEX : 35/M  
RECORDED : 8-11-2022 12:28

RATE : 123 BPM  
B.P. : 146/88 mmHg

BRUCE  
EXERCISE 2  
PHASE TIME : 5:59  
STAGE TIME : 2:59

ST @ 10mm/mV  
80ms PostJ  
SPEED : 4.0 Km./Hr.  
GRADE : 12.0 %

LINKED MEDIAN



ONEPLUS ULTRASOUND LAB  
47, Harsh Vihar, Pitam Pura,  
Delhi-110034  
Ph. 011-42480101, 9599913051  
E-mail: oneplusul@gmail.com

# ONEPLUS ULTRASOUND LAB

Mr. NAVDEEP RATHEE

I.D. : 995

AGE/SEX : 35/M

RECORDED : 8-11-2022 12:28

RATE : 151 BPM

B.P. : 158/90 mmHg

BRUCE

EXERCISE 3

PHASE TIME : 8:59

STAGE TIME : 2:59

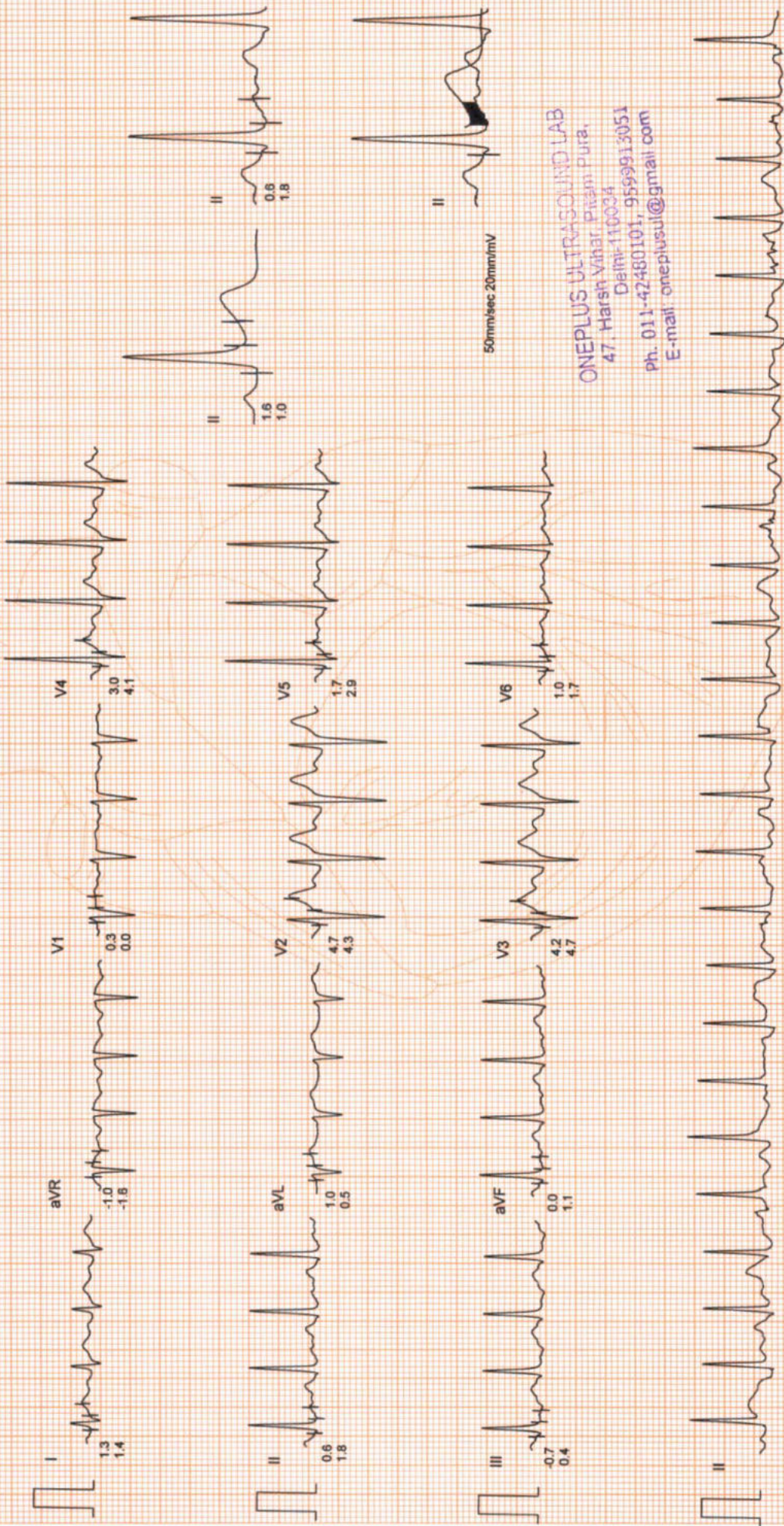
ST @ 10mm/mV

80ms PostJ

SPEED : 5.4 Km./Hr.

GRADE : 14.0 %

LINKED MEDIAN



ONEPLUS ULTRASOUND LAB  
47 Harsh Vihar, Pitam Pura,  
Delhi-110034  
Ph. 011-42480101, 9599913051  
E-mail: oneplusul@gmail.com

# ONEPLUS ULTRASOUND LAB

Mr. NAVDEEP RATHEE

I.D. : 995

AGE/SEX : 35/M

RECORDED : 8-11-2022 12:28

RATE : 159 BPM

B.P. : 170/92 mmHg

BRUCE

EXERCISE 4

PHASE TIME : 9:14

STAGE TIME : 0:14

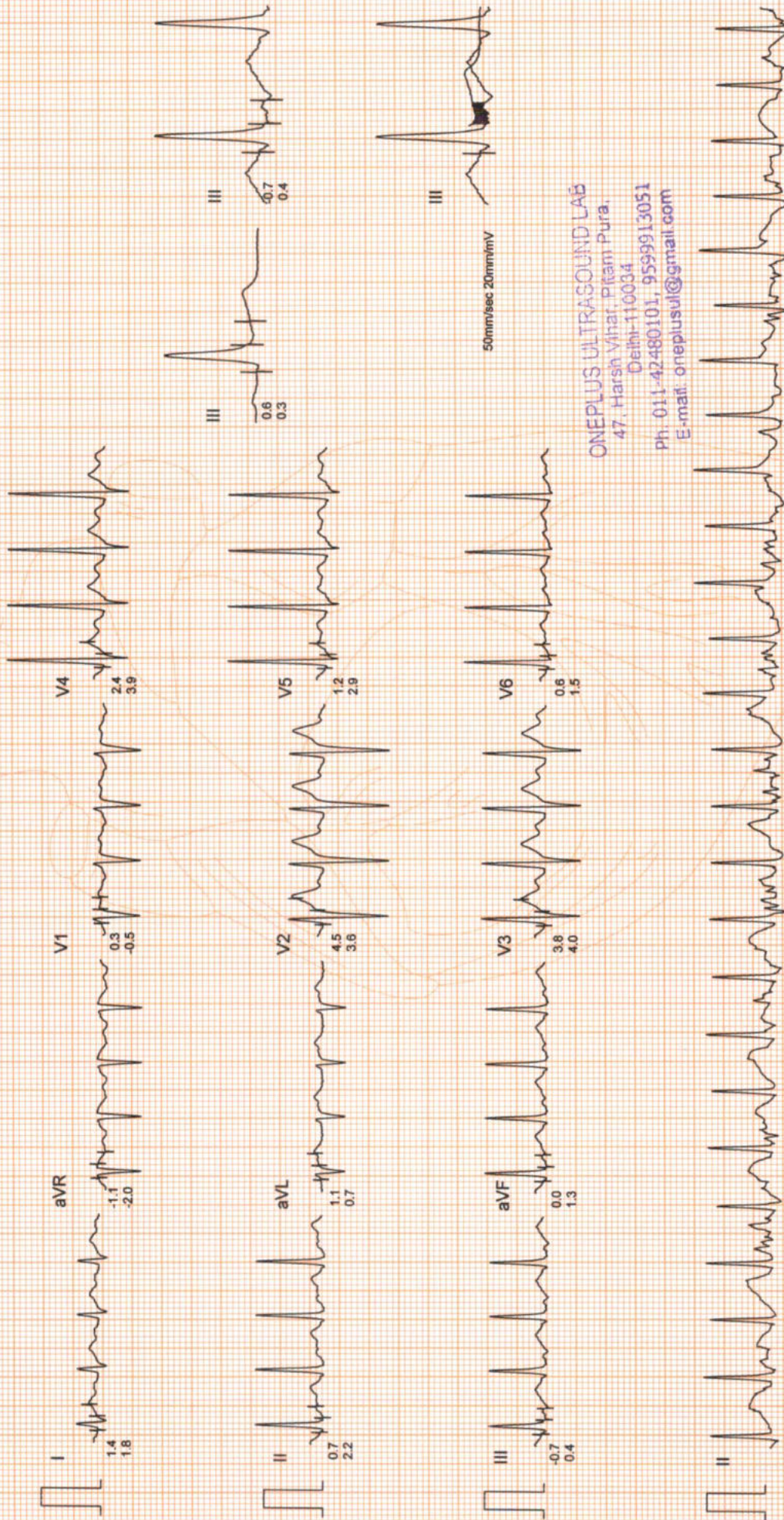
ST @ 10mm/mV

80ms PostJ

SPEED : 6.7 Km./Hr.

GRADE : 16.0 %

LINKED MEDIAN



ONEPLUS ULTRASOUND LAB

47, Harsh Vihar, Pitam Pura,

Delhi-110034

Ph-011-42480101, 9599913051

E-mail: onepplusul@gmail.com

# ONEPLUS ULTRASOUND LAB

Mr. NAVDEEP RATHEE

I.D. : 995

AGE/SEX : 35/M

RECORDED : 8-11-2022 12:28

RATE : 165 BPM

B.P. : 170/92 mmHg

BRUCE

PEAK EXER

PHASE TIME : 9:23

STAGE TIME : 0:23

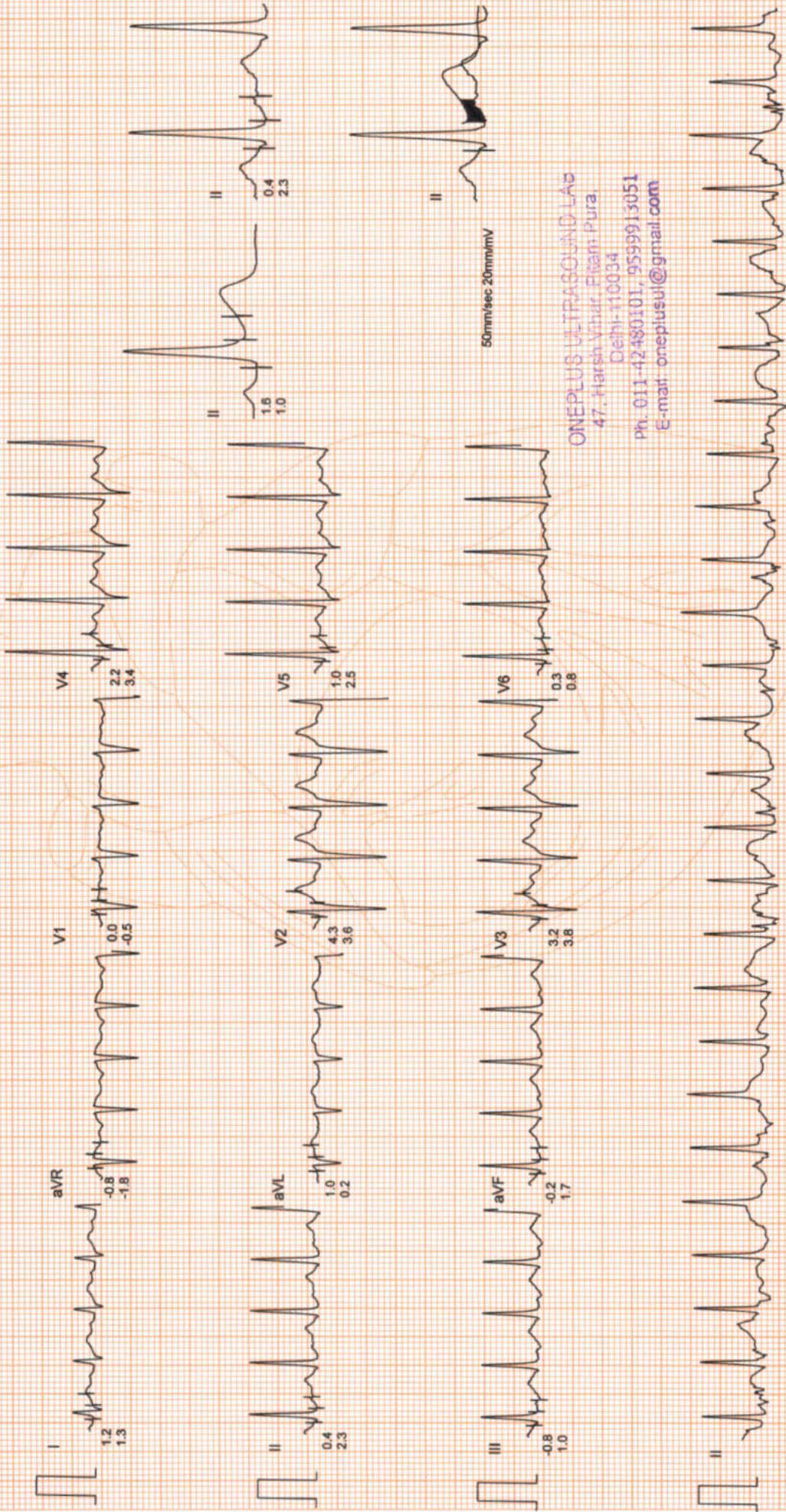
ST @ 10mm/mV

80ms PostJ

SPEED : 6.7 Km./Hr.

GRADE : 16.0 %

LINKED MEDIAN



50mm/sec 20mm/mV

ONEPLUS ULTRASOUND LAB  
47, Harsh Vihar, Preeti Pura,  
Delhi-110034  
Ph. 011-42480101, 9559913051  
E-mail: oneplusul@gmail.com

# ONEPLUS ULTRASOUND LAB

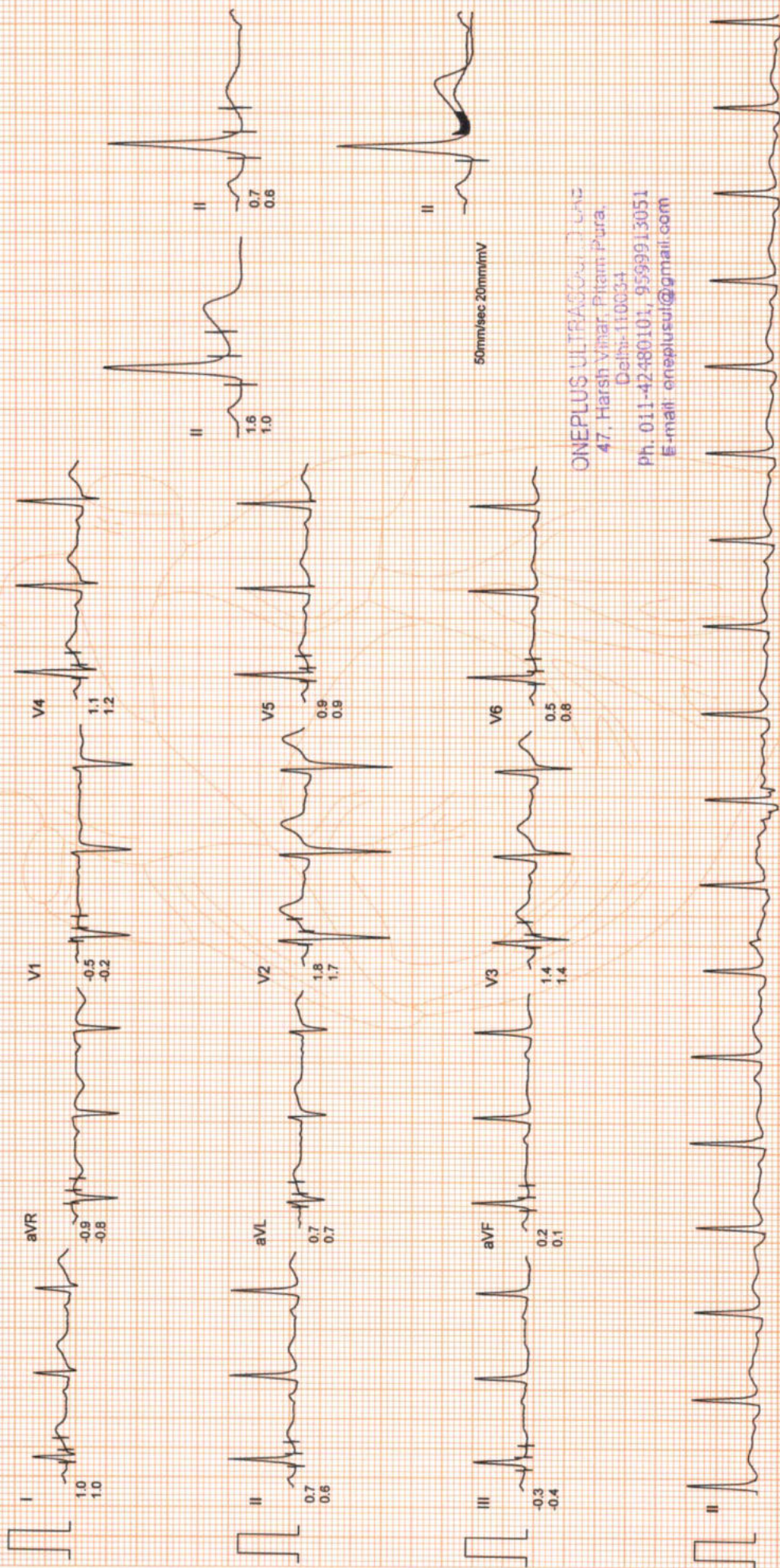
Mr. NAVDEEP RATHEE  
I.D. : 995

AGE/SEX : 35/M  
RECORDED : 8-11-2022 12:28  
RATE : 104 BPM  
B.P. : 136/86 mmHg

BRUCE  
RECOVERY  
PHASE TIME : 2:59

ST @ 10mm/mV  
80ms PostJ  
SPEED : 0.0 Km./Hr.  
GRADE : 0.0 %

LINKED MEDIAN



ONEPLUS ULTRASOUND LAB  
47, Harsh Vihar, Pitam Pura,  
Delhi-110034  
Ph. 011-42480101, 9599913051  
E-mail: oneplusul@gmail.com

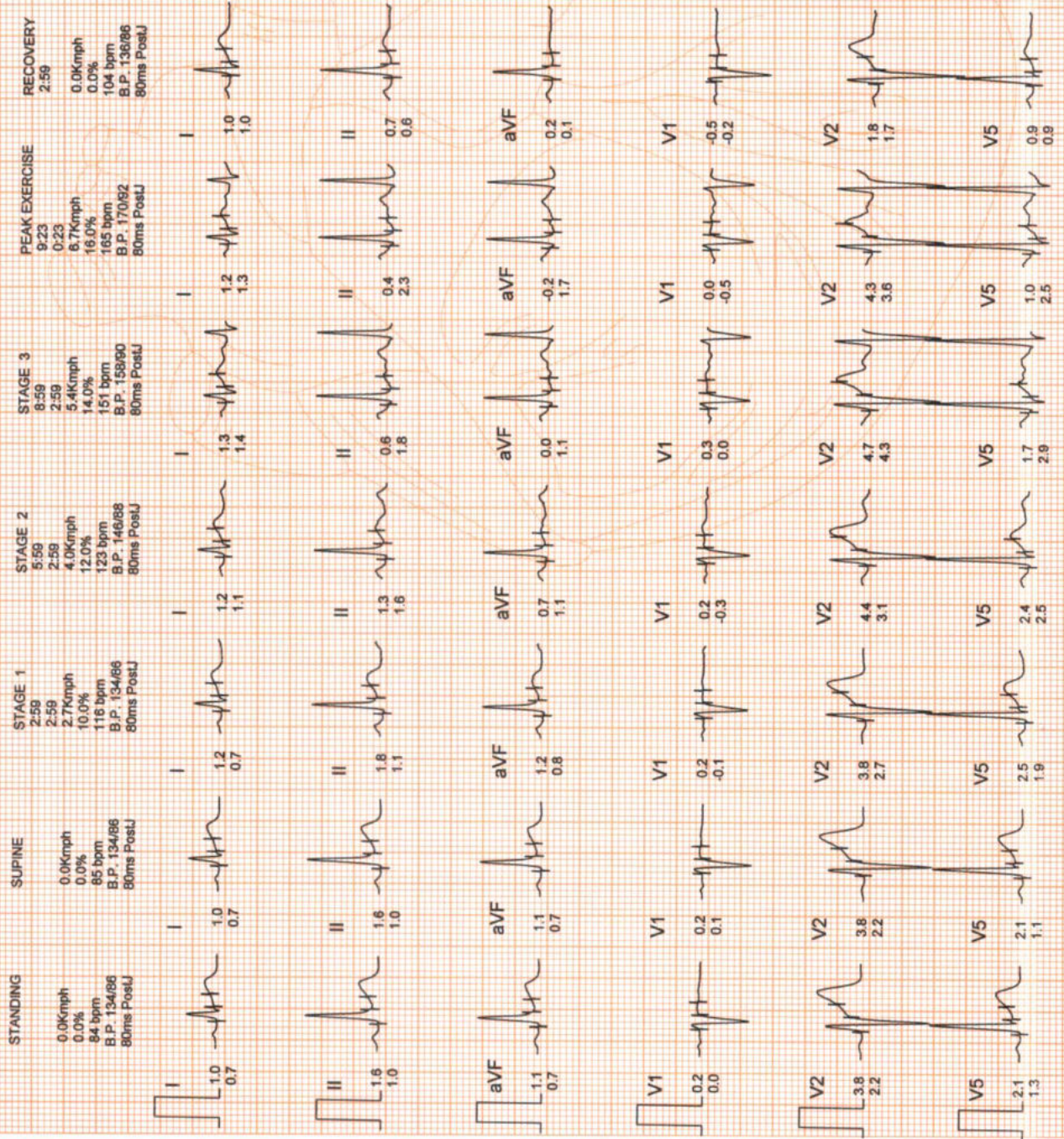# ONEPLUS ULTRASOUND LAB

Mr. NAVDEEP RATHEE I.D. : 995

AGE/SEX : 35/M

RECORDED : 8-11-2022 12:28

AVG E.C.G.



ONEPLUS ULTRASOUND LAB  
 47, Harsh Vihar Pitam Pura,  
 Delhi-110034  
 Ph. 011-42480101, 9599913051  
 E-mail: oneplusul@gmail.com

# ONEPLUS ULTRASOUND LAB

Mr. NAVDEEP RATHEE

I.D. : 995

AGE/SEX : 35/M

RECORDED : 8-11-2022 12:28

## COMPARISON REPORT

SUPINE

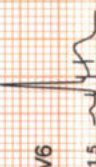
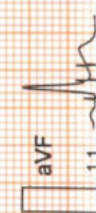
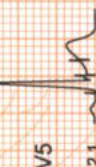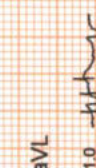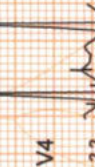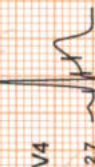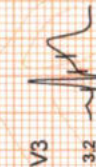

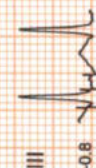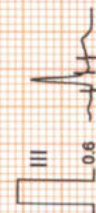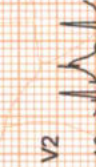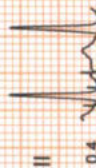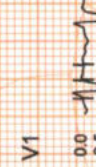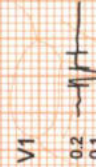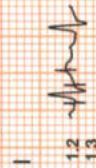0.0Kmph  
0.0%  
85 bpm  
B.P. 134/86  
80ms PostJ

PEAK EXERCISE

9.23  
0.23  
6.7Kmph  
16.0%  
165 bpm  
B.P. 170/92  
80ms PostJ

PEAK EXERCISE

9.23  
0.23  
6.7Kmph  
16.0%  
165 bpm  
B.P. 170/92  
80ms PostJ



ONEPLUS ULTRASOUND LAB  
47, Hares, Vihar, Patna, Bihar  
Ph: 031-26220740, 952993051  
E-mail: oneplusultrasound@gmail.com



**OnePLUS**  
Ultrasound Lab  
— QUALITY FIRST... ALWAYS! —

**Dr. Nitin Agarwal**

Pathologist & Director  
Ex. Sr. Res. MAMC  
& Lok Nayak Hospital  
Ex. Chief of Lab Dr. Lal Path Labs.

**Dr. Pooja (Garg) Agarwal**

Radiologist & Director  
MAMC & Lok Nayak Hospital

<b>Name</b>	: Mr. NAVDEEP RATHEE	<b>Age/Sex</b>	: 35 YRS/Male
<b>Ref. By</b>	: Dr. MEDIWHEEL	<b>Lab No</b>	: 012211080026
<b>Date</b>	: 08-Nov-2022	<b>Patient ID</b>	: LSHHI104401

**ULTRASOUND EXAMINATION---WHOLE ABDOMEN**

**Liver** is enlarged in size (16.8 cm) and normal in outline with altered echopattern. Diffuse increase in echogenicity of liver parenchyma is noted, suggestive of fatty infiltration (grade I). No abscess or mass lesion seen. Hepatic veins, portal vein, IVC and aorta are normal. Intrahepatic biliary radicles are not dilated. CBD is normal in caliber.

**Gall bladder** is well distended with anechoic lumen. Wall thickness is normal.

**Both kidneys** are normal in size, shape, position, outline and echopattern. Corticomedullary differentiation is maintained. No pelvicalyceal dilation or calculus or mass lesion is seen.

**Spleen** is normal in size and echotexture. No mass lesion seen.

**Pancreas** is normal in size, outline and echotexture.

**Urinary bladder** is normal in shape and position. No evidence of intravesical stone or mass seen.

**Prostate** is normal in size, shape and echopattern.

**Prostate measures** 4.0 x 2.9 x 2.5 cm. **Weight of prostate is 15.7 grams.**

No abnormal bowel wall thickening seen in right iliac fossa.

No mass or free fluid seen anywhere in abdomen.

**IMPRESSION:** Fatty infiltration of liver (grade I) with hepatomegaly.

**DR. POOJA GARG**  
RADIOLOGIST

**Dr. POOJA GARG**  
M.B.B.S., D.M.R.D.  
Reg No. DMC/R/03398  
Radiologist

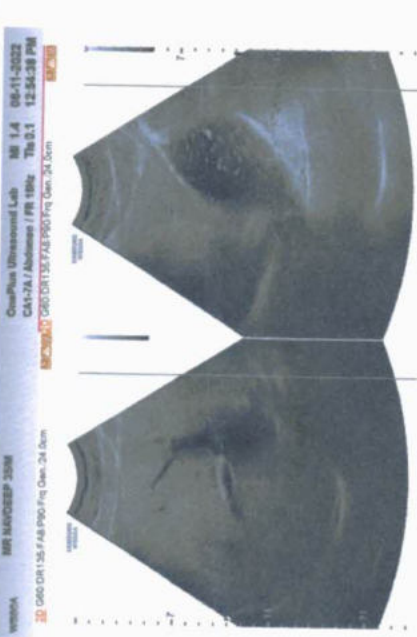Type By : darshita

47, Harsh Vihar, Pitampura, New Delhi-110034 | Ph.: 011-42480101, 9599913051

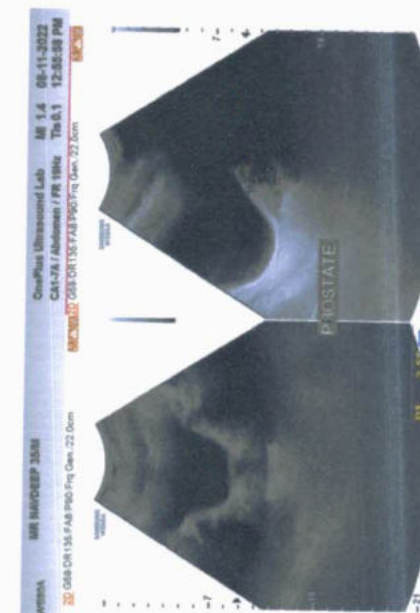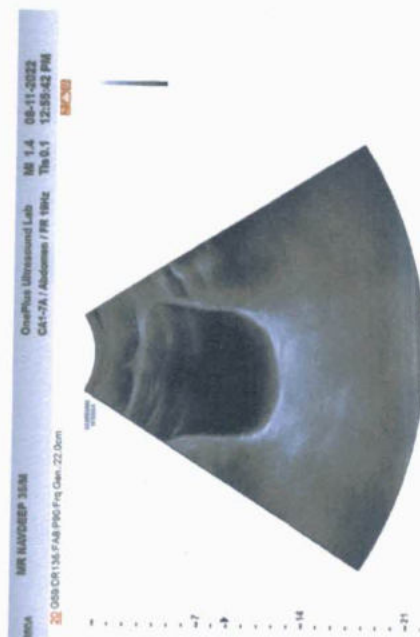
E-mail: oneplusul@gmail.com | Web.: www.oneplusul.in

Clinical correlation is essential for final diagnosis. • If test results are unsatisfactory please contact personally or on phone. • This report is for perusal of doctors only.  
• All disputes Subject to Delhi Jurisdiction only. • Not for medicolegal purposes. • All congenital anomalies in a foetus may not be diagnosed in routine obstetric ultrasound.








D1\_ 16.84 cm



D1\_ 5.49 cm  
D2\_ 3.89 cm  
D3\_ 4.02 cm  
Vol\_ 15.78 ml



Wassermann Injektion

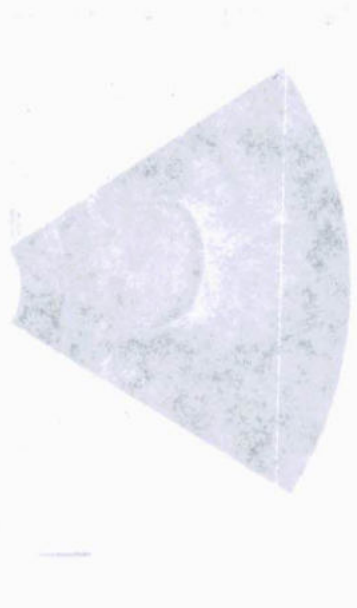
Wassermann Injektion  
Wassermann Injektion  
Wassermann Injektion



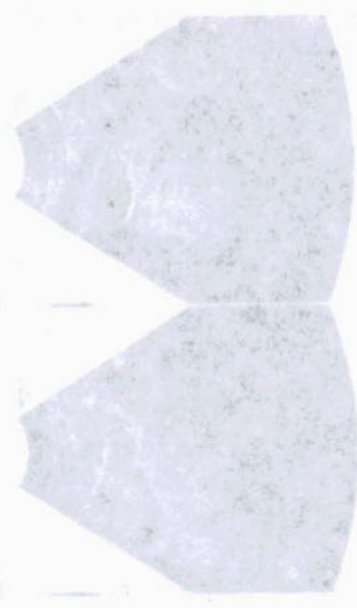
Wassermann Injektion  
Wassermann Injektion  
Wassermann Injektion



Wassermann Injektion  
Wassermann Injektion  
Wassermann Injektion



Wassermann Injektion  
Wassermann Injektion  
Wassermann Injektion




Wassermann Injektion  
Wassermann Injektion  
Wassermann Injektion



Wassermann Injektion  
Wassermann Injektion  
Wassermann Injektion



Wassermann Injektion  
Wassermann Injektion  
Wassermann Injektion



Wassermann Injektion  
Wassermann Injektion  
Wassermann Injektion



Wassermann Injektion  
Wassermann Injektion  
Wassermann Injektion





# OnePLUS

## Ultrasound Lab

— QUALITY FIRST... ALWAYS! —

**Dr. Nitin Agarwal**  
Pathologist & Director  
Ex. Sr. Res. MAMC  
& Lok Nayak Hospital  
Ex. Chief of Lab Dr. Lal Path Labs.

**Dr. Pooja (Garg) Agarwal**  
Radiologist & Director  
MAMC & Lok Nayak Hospital



NAME	:Mr. NAVDEEP RATHEE	Barcode No	:10131159
AGE/GENDER	:35 YRS/Male	SPECIMEN DATE	:08/Nov/2022 11:05AM
PATIENT ID	:104401	SPECIMEN RECEIVED	:08/Nov/2022 01:28PM
REFERRED BY	:Dr. MEDIWHEEL	REPORT DATE	:08/Nov/2022 03:23PM
CENTRE NAME	:ONEPLUS ULTRASOUND LAB	LAB NO.	:012211080026

Test Name	Result	Unit	Ref. Range
-----------	--------	------	------------

### HAEMATOLOGY

#### Health checkup 2 Male

<b>Glycosylated Hemoglobin (HbA1c)</b>	5.3	%	Non Diabetic adults <5.7 Prediabetic (at risk) 5.7-6.4 Diabetes >6.4
--	-----	---	--

<b>Estimated average blood glucose (eag)</b>	105
--	-----

#### Reference range (mg/dl):

90 - 120:Excellent control, 121 - 150:Good Control, 151 - 180:Average Control, 181 - 210:Action Suggested

>211:Panic value

<b>BLOOD GROUP (ABO)</b>	B
<b>Rh typing</b>	POSITIVE

#### NOTE :

- \* Apart from major A,B,H antigens which are used for ABO grouping and Rh typing, many minor blood group antigens exist. Agglutination may also vary according to titre of antigen and antibody.
- \* So before transfusion, reconfirmation of blood group as well as cross-matching is needed.
- \* Presence of maternal antibodies in newborns, may interfere with blood grouping.
- \* Auto agglutination (due to cold antibody, falciparum malaria, sepsis, internal malignancy etc.) may also cause erroneous result.

### CBC

Haemoglobin	13.6	g/dl	13.0-17.0
Total Leucocyte Count	7200	/cumm	4000-10000
<b>Differential leucocyte count</b>			
Neutrophils	54.6	%	40-80
Lymphocyte	38.60	%	20-40
Monocytes	4.80	%	2-10
Eosinophils	01	%	1-6
Basophils	01	%	0-2
RBC Count	5.20	million/cumm	4.5 - 5.5

Checked By.

Dr NITIN AGARWAL  
M B B S , MD (Path)  
DMC/R/01436  
DR. NITIN AGARWAL  
MBBS,MD(PATHOLOGIST)

47, Harsh Vihar, Pitampura, New Delhi-110034 | Ph.: 011-42480101, 9599913051

E-mail: [oneplusul@gmail.com](mailto:oneplusul@gmail.com) | Web.: [www.oneplusul.in](http://www.oneplusul.in)

Page 1 of 6



# OnePLUS Ultrasound Lab

— QUALITY FIRST... ALWAYS! —

**Dr. Nitin Agarwal**  
Pathologist & Director  
Ex. Sr. Res. MAMC  
& Lok Nayak Hospital  
Ex. Chief of Lab Dr. Lal Path Labs.

**Dr. Pooja (Garg) Agarwal**  
Radiologist & Director  
MAMC & Lok Nayak Hospital



NAME	:Mr. NAVDEEP RATHEE	Barcode No	:10131159
AGE/GENDER	:35 YRS/Male	SPECIMEN DATE	:08/Nov/2022 11:05AM
PATIENT ID	:104401	SPECIMEN RECEIVED	:08/Nov/2022 01:28PM
REFERRED BY	:Dr. MEDIWHEEL	REPORT DATE	:08/Nov/2022 03:23PM
CENTRE NAME	:ONEPLUS ULTRASOUND LAB	LAB NO.	:012211080026

Test Name	Result	Unit	Ref. Range
PCV(Hematocrit)	43.8	%	40-50
MCV	84.6	fL	83-101
MCH	26.3	Pg	27-32
MCHC	31.1	G/dL	32-35
Platelet count	196000	/cumm	150000-450000
RDW-CV	14.4	%	11.4-14.0
ESR(WESTEGRENs METHOD)	16	mm in 1st hr	0-20

### BIOCHEMISTRY

<u>Blood sugar fasting</u>	92	mg/dL	70-110
<u>Blood sugar pp</u>	102	mg/dL	70.0-140.0
<u>Bun (blood urea nitrogen )</u>	13.60	mg/dl	8.9-21.6
<u>Uric acid, serum</u>	4.6	mg/dl	3.5-7.2
<u>Creatinine, serum</u>	0.7	mg/dl	0.60-1.2

### LFT(LIVER FUNCTION TEST)

Bilirubin Total	0.57	mg/dl	0.1-1.2
Bilirubin Conjugated	0.23	mg/dl	0-0.4
Bilirubin Unconjugated	0.34	mg/dl	up to 0.7
SGOT (AST)	34	U/L	0-46
SGPT (ALT)	57	U/L	0-49
Alkaline phosphatase	95	U/L	40-129
Gamma glutamyl transpeptidase	24	U/L	10-45
Total Protein	7.4	gm/dl	6.60 - 8.70
Albumin serum	4.9	g/dL	3.0-5.2
Globulin	2.50	gm/dl	1.8-3.4
Albumin/Globulin Ratio	1.96		1.10 - 2.50

### LIPID PROFILE

Cholesterol	278	mg/dl	50-200
Triglycerides	727	mg/dL	25-150

Checked By.

Dr. NITIN AGARWAL  
M B B S . MD (Path)  
DMC/R/01436  
DR. NITIN AGARWAL  
MBBS, MD (PATHOLOGIST)

47, Harsh Vihar, Pitampura, New Delhi-110034 | Ph.: 011-42480101, 9599913051

E-mail: [oneplusul@gmail.com](mailto:oneplusul@gmail.com) | Web.: [www.oneplusul.in](http://www.oneplusul.in)

Page 2 of 6

Clinical correlation is essential for final diagnosis. \* If test results are unsatisfactory please contact personally or on phone. \* This report is for perusal of doctors only. \* All disputes Subject to Delhi Jurisdiction only. \* Not for medicolegal purposes. \* All congenital anomalies in a foetus may not be diagnosed in routine obstetric ultrasound.



# OnePLUS Ultrasound Lab

— QUALITY FIRST... ALWAYS! —

**Dr. Nitin Agarwal**

Pathologist & Director  
Ex. Sr. Res. MAMC  
& Lok Nayak Hospital  
Ex. Chief of Lab Dr. Lal Path Labs.

**Dr. Pooja (Garg) Agarwal**

Radiologist & Director  
MAMC & Lok Nayak Hospital



NAME	:Mr. NAVDEEP RATHEE	Barcode No	:10131159
AGE/GENDER	:35 YRS/Male	SPECIMEN DATE	:08/Nov/2022 11:05AM
PATIENT ID	:104401	SPECIMEN RECEIVED	:08/Nov/2022 01:28PM
REFERRED BY	:Dr. MEDIWHEEL	REPORT DATE	:08/Nov/2022 03:23PM
CENTRE NAME	:ONEPLUS ULTRASOUND LAB	LAB NO.	:012211080026

Test Name	Result	Unit	Ref. Range
HDL Cholesterol	47	mg/dL	40 - 60
LDL cholesterol	86	mg/dL	<130
VLDL cholesterol	145.4	mg/dL	5-40
Cholesterol/HDL Ratio	5.9		Low Risk 3.3-4.97 Average Risk 4.4-7.1 Moderate Risk 7.1-11.0 High Risk >11.0
LDL/HDL Ratio	1.8		0 - 3.55

According to ATP III and NCEP guidelines

Parameter	Normal	Desirable	Borderline	High
Total cholesterol	<200		200-239	240
Triglycerides	<150	150-199	200-499	500
LDL	Optimal <100 Near Optimal 100-129	130-159	160-180	190
HDL	<40 : LOW 60 : HIGH			

## ENDOCRINOLOGY


### PSA TOTAL

Prostatic specific antigen, Total 0.40 ng/ml <4.0

< 40 years	0.21 to 1.72 ng/ml
40 - 49	0.27 to 2.19 ng/ml
50 - 59	0.27 to 3.42 ng/ml
60 - 69	0.22 to 6.16 ng/ml
> 69	0.21 to 6.77 ng/ml

### Notes:

Checked By.

  
**DR. NITIN AGARWAL**  
 M.B.B.S., M.D. (PATHOLOGIST)  
 DMC/R/01436

47, Harsh Vihar, Pitampura, New Delhi-110034 | Ph.: 011-42480101, 9599913051

E-mail: [oneplusul@gmail.com](mailto:oneplusul@gmail.com) | Web.: [www.oneplusul.in](http://www.oneplusul.in)

Page 3 of 6



**OnePLUS**  
Ultrasound Lab

— QUALITY FIRST... ALWAYS! —

**Dr. Nitin Agarwal**  
Pathologist & Director  
Ex. Sr. Res. MAMC  
& Lok Nayak Hospital  
Ex. Chief of Lab Dr. Lal Path Labs.

**Dr. Pooja (Garg) Agarwal**  
Radiologist & Director  
MAMC & Lok Nayak Hospital



NAME	:Mr. NAVDEEP RATHEE	Barcode No	:10131159
AGE/GENDER	:35 YRS/Male	SPECIMEN DATE	:08/Nov/2022 11:05AM
PATIENT ID	:104401	SPECIMEN RECEIVED	:08/Nov/2022 01:28PM
REFERRED BY	:Dr. MEDIWHEEL	REPORT DATE	:08/Nov/2022 03:23PM
CENTRE NAME	:ONEPLUS ULTRASOUND LAB	LAB NO.	:012211080026

Test Name	Result	Unit	Ref. Range
-----------	--------	------	------------

PSA is principally produced by the glandular epithelium of the prostate, and is secreted in the seminal fluid. PSA is also present in urine and blood. PSA acts on seminal fluid to fluidify and increase sperm mobility. PSA levels rise in prostatic pathologies such as benign prostatic hyperplasia (BPH) or prostate cancer.

**THYROID PROFILE(T3,T4,TSH)**

Triiodothyronine total [t3]	0.58	ng/dl	0.52-1.9
Thyroxine total [t4]	4.90	µg/dl	4.4 - 10.8
TSH (Thyroid Stimulating Hormone)	2.80	µIU/ml	0.25-5.0

**AGE WISE VARIATION IN TSH**

AGE	TSH(µIU/ml)	AGE	TSH(µIU/ml)
1-4 weeks	1.00 - 19.0	16-20 yrs	0.25 - 5.0
1-12 mths	1.70 - 9.1	21 - 80 yrs	0.25 - 5.0
1-5 yrs	0.80 - 8.2	I <sup>st</sup> trimester	0.25 - 5.0
6-10 yrs	0.25 - 5.0	II <sup>nd</sup> trimester	0.50 - 5.0
11-15 yrs	0.25 - 5.0	II <sup>rd</sup> trimester	0.4 - 6.0

**Reference ranges - Interpretation of Diagnostic tests - (Jacques Wallach)**

1. Primary hypothyroidism is accompanied by depressed serum T3 and T4 values and elevated serum TSH level.
2. Primary hyperthyroidism is accompanied by elevated serum T3 and T4 levels along with depressed TSH values.
3. Slightly elevated T3 levels may be found in pregnancy and estrogen therapy, while depressed levels may be encountered in severe illness, renal failure and during therapy with drugs like propranolol and propyl thiouracil.
4. Although elevated TSH levels are nearly always indicative of primary hypothyroidism, and may be seen in secondary thyrotoxicosis

**CLINICAL PATHOLOGY**

**URINE ROUTINE**

**Physical examination**

Quantity	20	ML
Colour	PALE YELLOW	
Transparency	SLIGHTLY TURBID	CLEAR
Sp.gravity	1.015	1.010-1.030
pH	7.50	

Checked By.

Dr. NITIN AGARWAL  
M B B S, MD (Path)  
DMC/R/01436  
DR. NITIN AGARWAL  
MBBS,MD(PATHOLOGIST)

47, Harsh Vihar, Pitampura, New Delhi-110034 | Ph.: 011-42480101, 9599913051

E-mail: oneplusul@gmail.com | Web.: www.oneplusul.in



# OnePLUS Ultrasound Lab

— QUALITY FIRST... ALWAYS! —

**Dr. Nitin Agarwal**  
Pathologist & Director  
Ex. Sr. Res. MAMC  
& Lok Nayak Hospital  
Ex. Chief of Lab Dr. Lal Path Labs.


**Dr. Pooja (Garg) Agarwal**  
Radiologist & Director  
MAMC & Lok Nayak Hospital



NAME	:Mr. NAVDEEP RATHEE	Barcode No	:10131159
AGE/GENDER	:35 YRS/Male	SPECIMEN DATE	:08/Nov/2022 11:05AM
PATIENT ID	:104401	SPECIMEN RECEIVED	:08/Nov/2022 01:28PM
REFERRED BY	:Dr. MEDIWHEEL	REPORT DATE	:08/Nov/2022 03:23PM
CENTRE NAME	:ONEPLUS ULTRASOUND LAB	LAB NO.	:012211080026

Test Name	Result	Unit	Ref. Range
Reaction	ALKALINE		ACIDIC
<b><u>Chemical examination</u></b>			
Urine protein	NIL		NIL
Urine sugar	NIL		NIL
Bilirubin, urine	NEGATIVE		NEGATIVE
Urobilinogen	NORMAL		NORMAL
Ketones	NEGATIVE		NEGATIVE
<b><u>Microscopic examination</u></b>			
Pus cells.	1-2	/HPF	0-2
Epithelial cells	0-1	/HPF	NIL
R.B.C.	NIL	/HPF	NIL
Casts	NIL	/HPF	NIL
Crystals	NIL	/HPF	NIL
Bacteria	NIL	/HPF	NIL
Others.	NIL	NIL	NIL
<b>STOOL ROUTINE</b>			
<b><u>Physical examination</u></b>			
Colour	BROWNISH		
Consistency	SEMI FORMED		Semi Formed
Blood	ABSENT		Absent
Mucus	ABSENT		Absent
<b><u>Chemical examination, stool</u></b>			
pH	6.00		
<b><u>Microscopic examination</u></b>			
Pus cells	0-1	/HPF	
R.B.C.	NIL	/HPF	NIL
Ova	NIL		NIL
Cysts	NIL		NIL
Bacteria	NIL	/HPF	NIL

Checked By.

  
Dr. NITIN AGARWAL  
M B B S , MD (Path)  
MBBS, MD (PATHOLOGIST)  
DMC/R/01436

47, Harsh Vihar, Pitampura, New Delhi-110034 | Ph.: 011-42480101, 9599913051

E-mail: [oneplusul@gmail.com](mailto:oneplusul@gmail.com) | Web.: [www.oneplusul.in](http://www.oneplusul.in)

Page 5 of 6



# OnePLUS Ultrasound Lab

— QUALITY FIRST... ALWAYS! —

**Dr. Nitin Agarwal**

Pathologist & Director  
Ex. Sr. Res. MAMC  
& Lok Nayak Hospital  
Ex. Chief of Lab Dr. Lal Path Labs.

**Dr. Pooja (Garg) Agarwal**

Radiologist & Director  
MAMC & Lok Nayak Hospital



NAME	:Mr. NAVDEEP RATHEE	Barcode No	:10131159
AGE/GENDER	:35 YRS/Male	SPECIMEN DATE	:08/Nov/2022 11:05AM
PATIENT ID	:104401	SPECIMEN RECEIVED	:08/Nov/2022 01:28PM
REFERRED BY	:Dr. MEDIWHEEL	REPORT DATE	:08/Nov/2022 03:23PM
CENTRE NAME	:ONEPLUS ULTRASOUND LAB	LAB NO.	:012211080026

Test Name	Result	Unit	Ref. Range
Others	NIL		

\*\*\* End Of Report \*\*\*

Checked By.

Dr NITIN AGARWAL  
M B B S , MD (Path)  
DMC/R/0143  
DR. NITIN AGARWAL  
MBBS, MD (PATHOLOGIST)

47, Harsh Vihar, Pitampura, New Delhi-110034 | Ph.: 011-42480101, 9599913051

E-mail: [oneplusul@gmail.com](mailto:oneplusul@gmail.com) | Web.: [www.oneplusul.in](http://www.oneplusul.in)

Page 6 of 6





**OnePLUS**  
Ultrasound Lab

— QUALITY FIRST... ALWAYS! —

**Dr. Nitin Agarwal**  
Pathologist & Director  
Ex. Sr. Res. MAMC  
& Lok Nayak Hospital  
Ex. Chief of Lab Dr. Lal Path Labs.


**Dr. Pooja (Garg) Agarwal**  
Radiologist & Director  
MAMC & Lok Nayak Hospital

<b>Name</b>	: Mr. NAVDEEP RATHEE	<b>Age/Sex</b>	: 35 YRS/Male
<b>Ref. By</b>	: Dr. MEDIWHEEL	<b>Lab No</b>	: 012211080026
<b>Date</b>	: 08-Nov-2022	<b>Patient ID</b>	: LSHHI104401

### X-ray-Chest PA view

Bony cage and soft tissues are normal.  
Cardiothoracic ratio is normal.  
Mediastinum is normal.  
Both hila are normal.  
Both costophrenic angles are clear.  
Both domes of diaphragm are normal.  
Lung fields are clear. No parenchymal lesion seen.

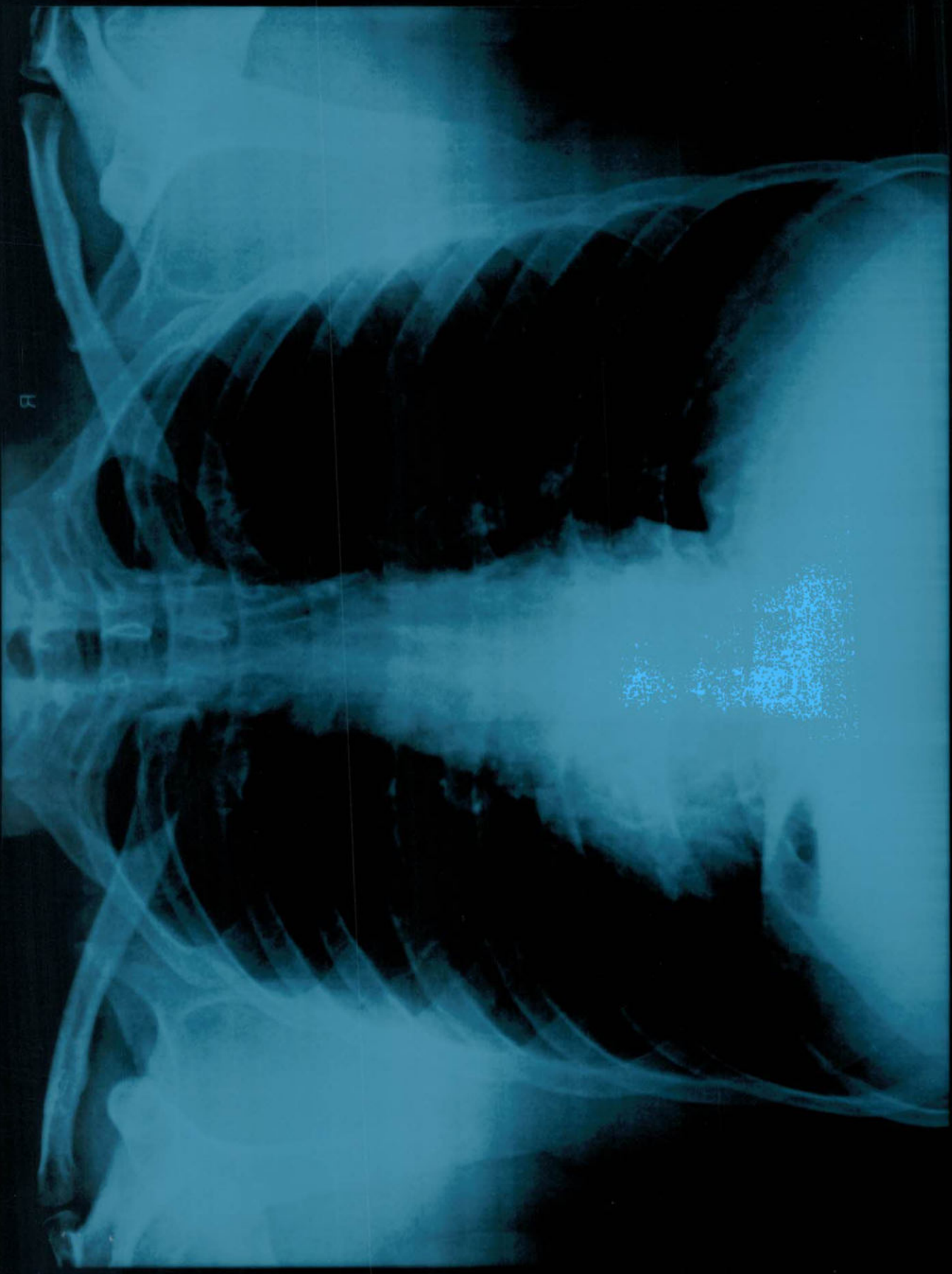
**IMPRESSION: Normal Study.**

  
**DR. POOJA GARG**  
RADIOLOGIST  
REG NO. DMC/R/03398  
M.B.B.S., D.M.R.D.  
Reg No. DMC/R/03398  
Radiologist

Type By : darshita

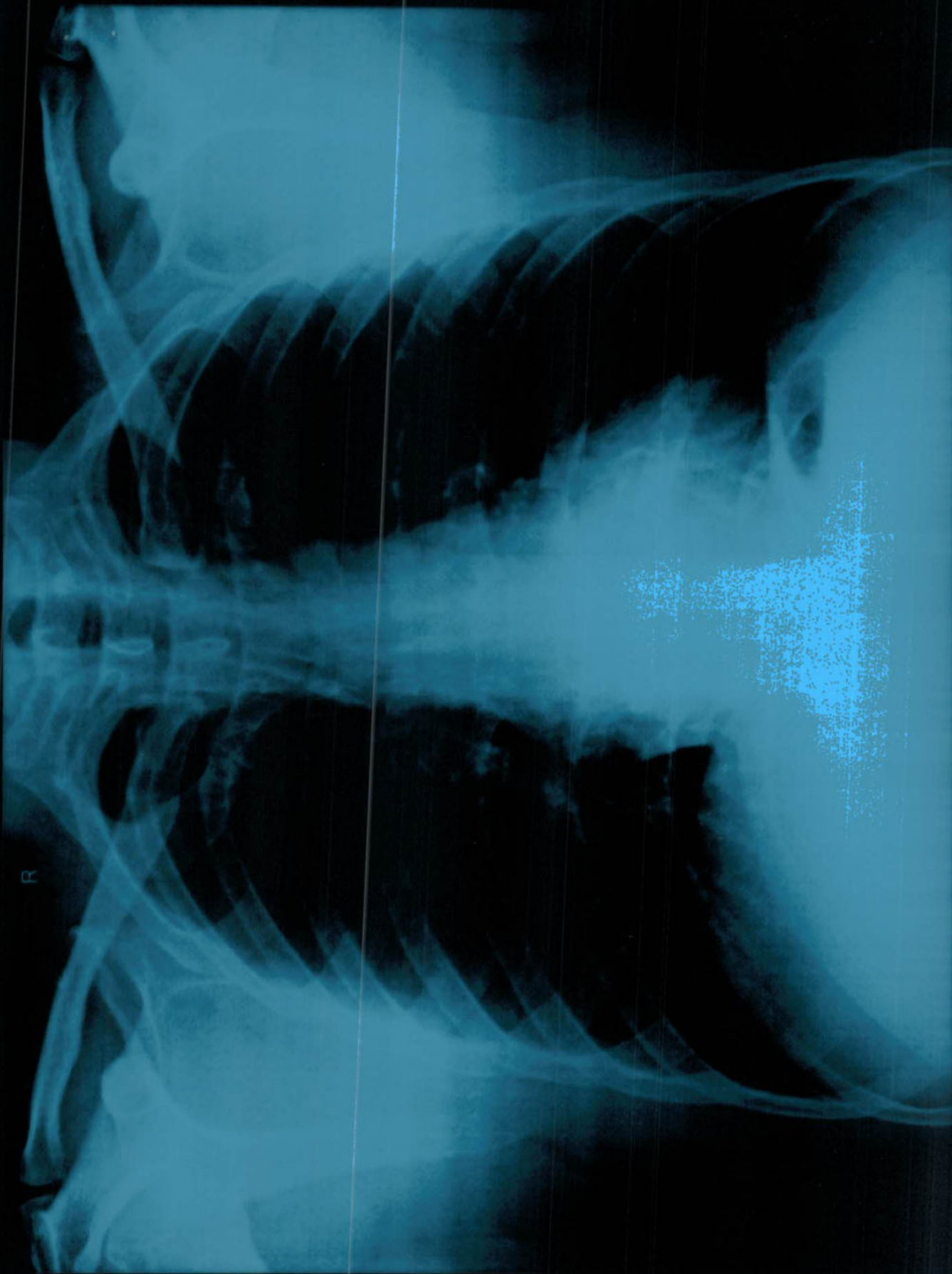
47, Harsh Vihar, Pitampura, New Delhi-110034 | Ph.: 011-42480101, 9599913051  
E-mail: oneplusul@gmail.com | Web.: www.oneplusul.in

ONEPLUS ULTRASOUND LAB 41-HARSH VIHAR PITAMPURA  
MR NVADEEP RATHHEE 32 YRS 08/11/5055 M CHEST BY VIEW 11/8/5055



R

R



MR NAVDEEP RATHEE 35 YRS 08/11/2022 M CHEST PA VIEW 11/8/2022  
ONEPLUS ULTRASOUND LAB, 47-HARSH VIHAR, PITAMPURA