



भारतीय विशिष्ट पहचान प्राधिकरण
UNIQUE IDENTIFICATION AUTHORITY OF INDIA

ਪਤਾ:

W/O: ਯਸ਼ਵੰਤ ਕੁਮਾਰ ਸਿੰਘ, 173
ਐਸ ਯੂ, ਏਅਰ ਫੋਰਸ, ਰਾਜਾ ਸੰਸੀ,
ਅੰਮ੍ਰਿਤਸਰ,
ਪੰਜਾਬ - 143101

Address:

W/O: Yashwant Kumar Singh, 173 s
u, air force, Raja Sansi, Amritsar,
Punjab - 143101

8971 0174 4769



GPS Map Camera

वाराणसी, उत्तर प्रदेश, भारत

B36/44B-3, पदमपुरी कॉलोनी, दुर्गाकुंड, नगवा, वाराणसी, उत्तर प्रदेश
221005, भारत

Lat 25.289201°

Long 82.993409°

26/08/23 09:59 AM GMT +05:30

Google



भारत सरकार

GOVERNMENT OF INDIA



सारिका कुमारी

Sarika Kumari

ਜਨਮ ਮਿਤੀ/ DOB: 01/03/1980

ਔਰਤ / FEMALE



8971 0174 4769



GPS Map Camera

वाराणसी, उत्तर प्रदेश, भारत

B36/44B-3, पदमपुरी कॉलोनी, दुर्गाकुंड, नगवा, वाराणसी, उत्तर प्रदेश

221005, भारत

Lat 25.289201°

Long 82.993409°

26/08/23 09:59 AM GMT +05:30

Google

Facilities:

All clinical Biomedical & Hematology Investigations including Bone Marrow Examination
 VPT, Podiascan & Complete Foot Care (First Time in Purvanchal)
 All Hormonal Investigation by Chemiluminescent Method
 Visceral Fat by (AB-140) Ambulatory BP Monitoring
 CGMS & Insulin Pump Available
 PFT, 2D-ECHO (Color Doppler), Holter, TMT, Cardiac-3 available
 VIA, VILI, Colposcopy available
 Special Endocrinological Investigation Protocols.

ISO 9001:2008 Certified
 Mobile: 9389994334, 9554572190, 9453837595



Panacea Pathology

Clinical Reference Lab

Persistence, Preparedness and Precision
 EQAS (CMC Vellore Attached) & IQAS System
 पूर्वांचल की सर्वोत्तम गुणवत्ता वाली पैथोलॉजी

PATIENT NAME : SARIKA KUMARI	AGE/GENDER : 43 YRS/FEMALE
REFD BY DR. : ARCO FEMI HEALTHCARE LTD.	RECEIVED DATE : 26-07-2023 (10:00AM)
SAMPLE : BLOOD & URINE	REPORT DATE : 26-07-2023 (06:00PM)

PATHOLOGY REPORT

COMPLETE BLOOD COUNT (CBC)

TEST	LAB TEST VALUES	NORMAL RANGE
HEMOGRAM		
HEMOGLOBIN (FLOW CYTOMETRY)	10.4	13 – 16 gm/dl
TOTAL LEUCOCYTE COUNT (TLC)	8,200	4000 – 11000
RBC COUNT	3.64	3.5 – 5.5
PCV (HCT)	33.3	37 – 47
MCV	91.4	80 – 95
MCH	28.6	28 – 34
MCHC	31.3	30 – 36
PLATELET COUNT	2,46,000	1,50,000 – 4,00,000
E.S.R. (WINTROBE FIRST HOURS)	26.0	20 mm/1 st hr
DIFFERENTIAL LEUCOCYTE		
NEUTROPHILS	48	40 – 75%
LYMPHOCYTES	37	20 – 45%
EOSINOPHILS	07	1 – 6%
MONOCYTES	08	2 – 8%
BASOPHILS	00	< 2%

FASTING /POSTPRANDIAL BLOOD SUGAR

TEST	LAB TEST VALUES	NORMAL RANGE
FBS /PP		
FASTING BLOOD SUGAR	69.0	70-125 mg/dl
POSTPRANDIAL BLOOD SUGAR	140.0	125-140 mg/dl

GLYCOSYLATED HEMOGLOBIN (HBA1C)

TEST	LAB TEST VALUES	NORMAL RANGE
HBA1C	5.7	Normal : <5.97 % Good Control : 5.97 – 6.81% Fair Control : 6.81 – 7.65% Poor Control : >7.65%

PAGE 1

Lab Technician

PANACEA HOSPITAL
 (A UNIT OF ARCO FEMI HEALTHCARE PVT. LTD.)
 REG NO. AL-1500
 B-36/44, B-1, KABIR NAGAR,
 GURBAKUND, VARANASI - 221005

Timing : 8.00 a.m. to 9.00 p.m. (Sunday 8.00 a.m. to 3.00 p.m.)

This Report is not valid for medico legal purpose

Note: These tests have technical limitations. Clinico-pathological interpretation is necessary. In case of any disparity test may be repeated immediately.

Facilities:

All clinical Biomedical & Hematology Investigations
 including Bone Marrow Examination
 VPT, Podiascan & Complete Foot Care (First Time in Purvanchal)
 All Hormonal Investigation by Chemiluminescent Method
 Visceral Fat by (AB-140) Ambulatory BP Monitoring
 CGMS & Insulin Pump Available
 PFT, 2D-ECHO (Color Doppler), Holter, TMT, Cardiac-3 available
 VIA, VILI, Colposcopy available
 Special Endocrinological Investigation Protocols.

ISO 9001:2008 Certified
 Mobile: 9389994334, 9554572190, 9453837595



Panacea Pathology

Clinical Reference Lab

Persistence, Preparedness and Precision
 EQAS (CMC Vellore Attached) & IQAS System
 पूर्वांचल की सर्वोत्तम गुणवत्ता वाली पैथोलॉजी

PATIENT NAME : SARIKA KUMARI	AGE/GENDER : 43 YRS/FEMALE
REFD BY DR. : ARCO FEMI HEALTHCARE LTD.	RECEIVED DATE : 26-07-2023 (10:00AM)
SAMPLE : BLOOD & URINE	REPORT DATE : 26-07-2023 (06:00PM)

PATHOLOGY REPORT

LIPID PROFILE, SERUM

TEST	LAB TEST VALUES	NORMAL RANGE
BLOOD CHEMISTRY		
TOTAL CHOLESTEROL (SERUM)	144.0	Desirable :- < 200 mg/dl Borderline:- 200 – 239 mg/dl High:- > 240 mg/dl
TRIGLYCERIDES (SERUM)	156.0	35 – 170 mg/dl
HDL CHOLESTEROL(SERUM)	42.0	35.30 – 79.50 mg/dl
LDL CHOLESTEROL (SERUM)	70.8	< 130 mg/dl
VLDL	31.2	< 40 mg/dl
CHOLESTROL/HDL RATIO	3.42	< 3.0 Low Risk Ratio 3.0 – 5.0 Avg Risk < 5.0 High Risk
LDL/HDL RATIO	1.68	< 3 Ratio

BLOOD GROUP

TEST	LAB TEST VALUES
BLOOD GROUP ABO & RH FACTOR	
BLOOD GROUP	"AB"
RH FACTOR	POSITIVE

LIVER PROFILE TEST, SERUM

TEST	LAB TEST VALUES	NORMAL RANGE
BIO CHEMISTRY		
TOTAL BILIRUBIN	0.68	0.0 – 1.1 mg/dl
DIRECT BILIRUBIN	0.28	0.0 – 0.2 mg/dl
INDIRECT BILIRUBIN	0.40	< 0.90 mg/dl
SGOT (AST)	21.0	0 – 52 mg/dl
SGPT (ALT)	25.0	0 – 39 mg/dl
GGT (GYT)	16.0	< 55 U/L

THYROID PROFILE (T3, T4, TSH)

TEST	LAB TEST VALUES	NORMAL RANGE
THYROID FUNCTION TEST		
T3	1.10	0.60 – 1.81 ng/ml
T4	7.5	4.50 – 10.90 ug/dl
TSH	2.43	0.39 – 6.10 uIU/ml

PAGE 2

Lab Technician

PANACEA HOSPITAL
 (A UNIT OF ARCO FEMI HEALTHCARE PVT. LTD.)
 M.D. Pathology

REG. NO. AL-1500

353004, B-4, KABIR NAGAR

GURSAKUND, VARANASI - 221005

Timing : 8.00 a.m. to 9.00 p.m. (Sunday 8.00 a.m. to 3.00 p.m.)

This Report is not valid for medico-legal purpose

Note: These tests have technical limitations. Clinico-pathological interpretation is necessary. In case of any disparity test may be repeated immediately.

Facilities:

All clinical Biomedical & Hematology Investigations including Bone Marrow Examination
 VPT, Podiascan & Complete Foot Care (First Time in Purvanchal)
 All Hormonal Investigation by Chemiluminescent Method
 Visceral Fat by (AB-140) Ambulatory BP Monitoring
 CGMS & Insulin Pump Available
 PFT, 2D-ECHO (Color Doppler), Holter, TMT, Cardiac-3 available
 VIA, VILI, Colposcopy available
 Special Endocrinological Investigation Protocols.

ISO 9001:2008 Certified

Mobile: 9389994334, 9554572190, 9453837595

**Panacea Pathology****Clinical Reference Lab**

Persistence, Preparedness and Precision
 EQAS (CMC Vellore Attached) & IQAS System
 पूर्वांचल की सर्वोत्तम गुणवत्ता वाली पैथोलॉजी

PATIENT NAME : SARIKA KUMARI

AGE/GENDER : 43 YRS/FEMALE

REFD BY DR. : ARCO FEMI HEALTHCARE LTD.

RECEIVED DATE : 26-07-2023 (10:00AM)

SAMPLE : BLOOD & URINE

REPORT DATE : 26-07-2023 (06:00PM)

PATHOLOGY REPORT**RENAL & KIDNEY PROFILE, SERUM**

TEST	LAB TEST VALUES	NORMAL RANGE
RENAL FUNCTION TESTS		
BLOOD UREA NITROGEN (BUN)	10.0	10 - 50 mg/dl
SERUM CREATININE	0.72	0.60 - 1.60 mg/dl
URIC ACID	4.10	3.60 - 7.70 mg/dl
ALKALINE PHOSPHATASE (ALP)	68.0	142 - 353 mg/dl
TOTAL PROTEINS	7.32	0 - 39 mg/dl
ALBUMIN	4.12	3.8 - 5.4 mg/dl
SERUM GLOBULIN	3.20	2.1 - 3.5 mg/dl
AG RATIO	1.28	-

URINE ROUTINE EXAMINATION

TEST	LAB TEST VALUES	NORMAL RANGE
PHYSICAL EXAMINATION		
QUANTITY	30	ML
COLOUR	STRAW	PALE YELLOW
APPEARANCE	CLEAR	CLEAR
SPECIFIC GRAVITY	1.015	1.01 - 1.03
PH	5.5	4.7 - 7.5
CHEMICAL EXAMINATION		
GLUCOSE	Not Detected	Not Detected
PROTEIN	NIL	Not Detected
MICROSCOPIC EXAMINATION		
PUS CELLS	01-02	0-5
RBC	Not Detected	Not Detected
EPITHELIAL CELLS	01-02	0-5
CASTS	Not Detected	Not Detected
CRYSTALS	Not Detected	Not Detected
BACTERIA	Not Detected	Not Detected

----- End of Report -----

Lab Technician

PANACEA HOSPITAL
 (A UNIT OF ARCO FEMI HEALTHCARE PVT. LTD.)
 REG NO. AL/1500
 B-26/44, B.A. NAGAR,
 PRAKASH, VARANASI - 221005

Timing : 8.00 a.m. to 9.00 p.m. (Sunday 8.00 a.m. to 3.00 p.m.)

This Report is not valid for medico legal purpose

Note: These tests have technical limitations. Clinico-pathological interpretation is necessary. In case of any disparity test may be repeated immediately.



PANACEA HOSPITAL

B 36/44 F.K KABIR NAGAR, DURGAKUND
TOLLFREE NO-18001233070. Whatsapp No - 8795832852
www.piire.org
panaceaquery@gmail.com|panaceahospital@gmail.com



OP Slip

Print Date : 26-Aug-2023 09:59AM



UHID No	:- UD-23240002274	OP No	:- OP-23240007804	OP Date	:- 26 Aug 2023 9:58AM
Patient Name	:- Mrs SARIKA KUMARI	Age/Sex	:- 43 Y/Female	Mobile No	:- 8427102166
Husband	:- YASHWANT KUMAR SINGH	Department	:- OBST. & GYNAECOLOGY		
Pay Type	:- Cash	Consultant	:- Dr VANDANA SINGH (MBBS,MS)		
Token No	:- NOR. - 1	Paid/Bal	:- 0.00 /30.00		
Patient Type	:- Normal				
Address	:- 1735 U, AIR FORCE RAJA SANSI, AMRITSAR,PUNJAB				

BP :- 120/70
 Height :-
 Weight (kg) :- 55
 BMI :-

Rx clo-mil

SpO2 - 99
 PR - 103

LMP - 20/8/23
 Regular / 2d / 4 flow
 Pgt 0 L1 - 13y. LSCS.
 → expired after birth.

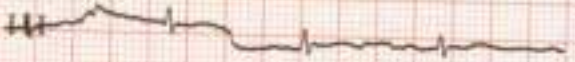
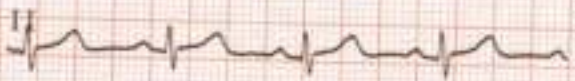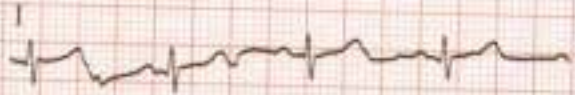
Sm
Pap smear
 ↓

Pt. refused for Pap smear
 despite counselling.
 No active intervention req.

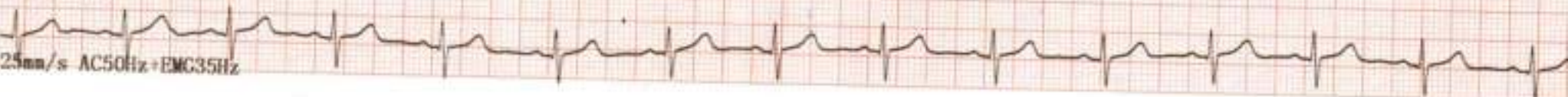Printed By : Ms. RENUKA
 Created By : Ms. RENUKA

Vandana

AUTO 10mm/mV

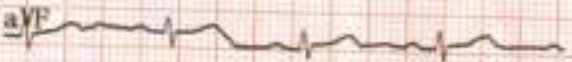
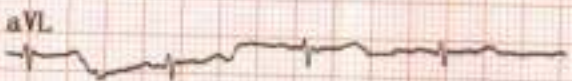
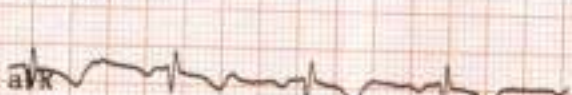V5 10mm/mV

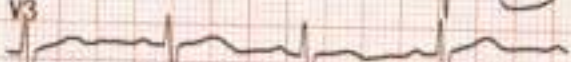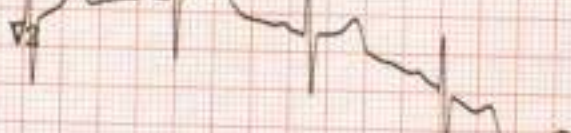

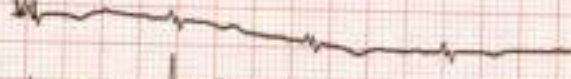
25mm/s AC50Hz+EMC35Hz

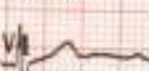10mm/mV

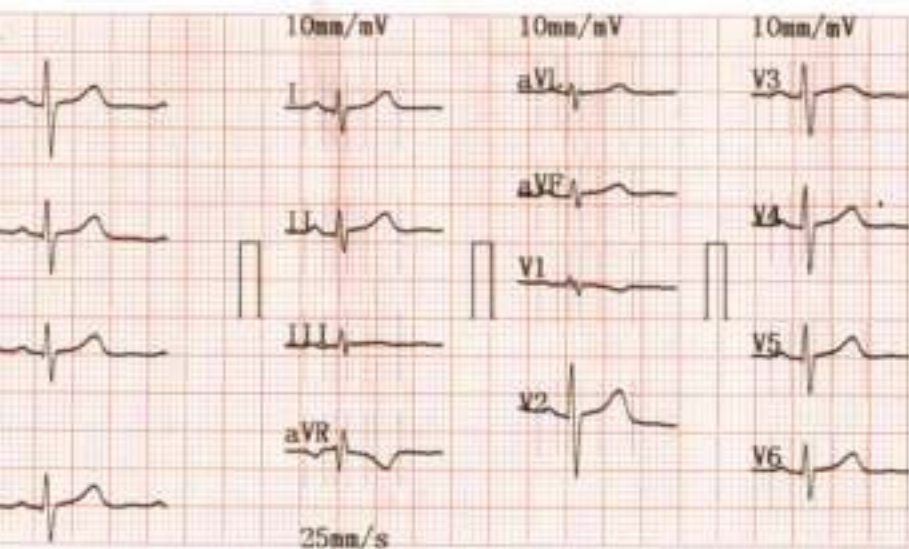


10mm/mV



10mm/mV





2023-08-26 10:37

ID :
 Name : Sonika Kumari
 Sex : FEMALE Age : 43
 Height : _____ Weight : _____ kg
 SYS : _____
 DIA : _____

HR [bpm] : 79
 PR Interval [ms] : 167
 P Duration [ms] : 104
 QRS Duration [ms] : 67
 T Duration [ms] : 183
 QT/QTc [ms] : 352/405
 P/QRS/T Axis [deg] : 26.8/83.4/36.0
 R(V5)/S(V1) [mV] : 0.45/0.00
 R(V5)+S(V1) [mV] : 0.45

<< Conclusions >>

Normal Sinus Rhythm.
 Cardiac electric axis normal.
 Report need physician confirm

Ecg is within Normal Limit

DR. PALLAVI MISHRA
 MBBS, MD, GENERAL MEDICINE
 Reg. No. 52033

Physician _____



PANACEA HOSPITAL

A shelter for many hearts A Home for many lives

(An ISO 9001:2008 Certified Organisation)

Lab Attached with CMC Vellore Under EQAS Scheme

NAME: MRS.SARIKA KUMARI

AGE/SEX: 43 YRS / FEMALE

REF BY: DR. ASHUTOSH MISHRA (MD)

DATE: 26/08/2023

Echo - Cardiography

MITRAL VALVE Doppler	AML - normal morphology MV Flow - E - 0.8 A-0.5 E/A=1.49	PML - normal morphology MVA - 3.0 cm ² Mitral Regurgitation - Trivial MR
TRICUSPID VALVE Doppler	Normal TV Flow -No	Tricuspid Regurgitation - No
PULMONARY VALVE Doppler	Normal PV Flow -No	Pulmonary Regurgitation - No
AORTIC VALVE Doppler	Trileaflet-No AV Flow - no	Aortic Regurgitation - No
MEASUREMENT	Aorta - 21.7 (20-38) mm IVS ed - 10.9 (6-12) mm LVID ed - 43.4 (35-55) mm LVPW ed - 8.6 (6-12) mm OA - 7 (> 5) mm	LA -28.9 (24-32) mm IVS es -13.1 (6-12) mm LVID es - 30.6 (24-40) mm LVPW es - 10.9 (6-12) mm EPSS - 6 (< 9) mm

CONCLUSION

All cardiac chamber dimensions are WNL

Trivial MR is present, rest other valve are WNL

Good LV systolic function present Modified Simpson's method (4C, 2C) (LVEF-58%)

No diastolic dysfunction present (E/A = 0.75)

No pericardial effusion

No RWMA

Intact IAS / IV

No PAH

No intra cardiac mass /thrombus /vegetation

IMPRESSION

All cardiac chamber dimensions are WNL

Trivial MR is present, rest other valve are WNL

Good LV systolic function present Modified Simpson's method (4C, 2C) (LVEF-58%)

No diastolic dysfunction present (E/A = 0.75)

Rest all other finding are WNL

Niraj Mishra
Physician Assistant
(PARE)

Dr. Pallavi Mishra

MBBS, MD (DCC) cardiology
Echocardiography Specialist, MBBS
Non-invasive cardiologist
Women Cardiologist
Diabeto-cardiologist



PANACEA HOSPITAL

B 36/44 F.K KABIR NAGAR, DURGAKUND
TOLLFREE NO-18001233070. Whatsapp No - 8795832852
www.paire.org
panaceaquery@gmail.com|panaceahospital@gmail.com



OP Slip

Print Date : 26-Aug-2023 12:07PM



UHID No :- UD-23240002274 OP No :- OP-23240007829 OP Date :- 26 Aug 2023 12:06PM
 Patient Name :- Mrs SARIKA KUMARI Age/Sex :- 43 Y/Female Mobile No :- 8427102166
 Husband :- YASHWANT KUMAR SINGH Department :- OPHTHALMOLOGY
 Pay Type :- Cash Consultant :- Dr ANKIT SONI (MBBS,MS)
 Token No :- NOR - 3 Paid :- 0.00
 Patient Type :- Normal
 Address :- 173S U, AIR FORCE RAJA SANSI, AMRITSAR,PUNJAB

BP :-
 height :-
 Weight (kg) :-
 BMI :-

Rx

VA 6/9
6/6

AR $\left\{ \begin{array}{l} +0.00 DS - 1.50 DC \times 88 \\ +0.00 DS - 0.75 DC \times 81 \end{array} \right.$

[ST $\left\{ \begin{array}{l} -1.25 DC \times 90 \\ -0.50 DC \times 80 \end{array} \right. \right] 6/6$

[NV ^{ADD} $\left\{ \begin{array}{l} +1.00 DS \\ +1.00 DS \end{array} \right. \right] N/6$

G. Kishanilal + co

0000

Printed By : Ms. RENUKA

Created By : Ms. RENUKA



GPS Map Camera

वाराणसी, उत्तर प्रदेश, भारत

B36/44B-3, पदमपुरी कॉलोनी, दुर्गाकुंड, नगवा, वाराणसी, उत्तर प्रदेश

221005, भारत

Lat 25.289201°

Long 82.993409°

26/08/23 10:10 AM GMT +05:30



Google

nacea Hospital

A Shelter For Many Hearts

Home For Many Lives

Abel's Care Organisation



GPS Map Camera

वाराणसी, उत्तर प्रदेश, भारत

B36/44B-3, पदमपुरी कॉलोनी, दुर्गाकुंड, नगवा, वाराणसी, उत्तर प्रदेश

221005, भारत

Lat 25.289201°

Long 82.993409°

26/08/23 09:56 AM GMT +05:30

Google



Call Now - 1800-123-3070

PANACEA HOSPITAL

A shelter for many hearts A Home for many lives

(An ISO 9001:2008 Certified Organisation)

Lab Attached with CMC Vellore Under EQAS Scheme

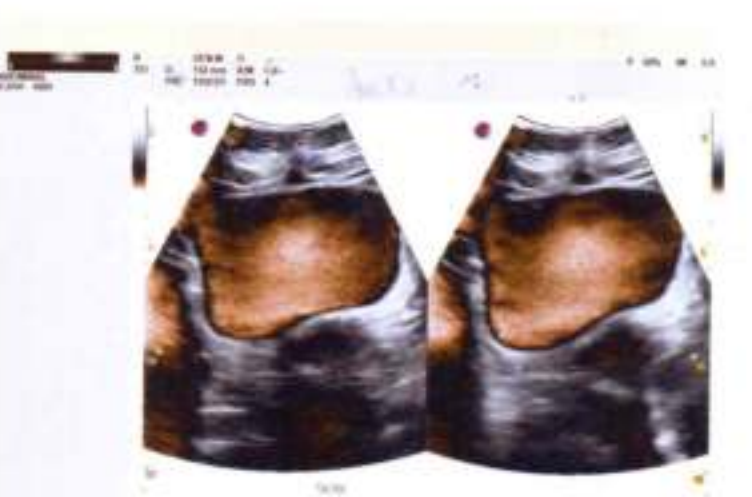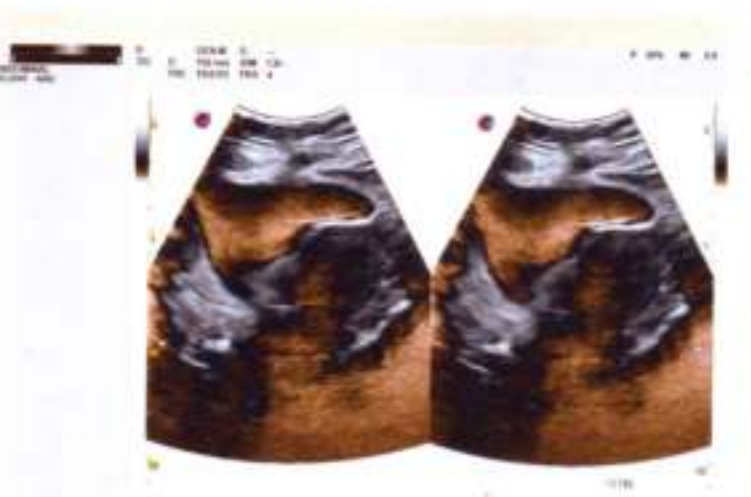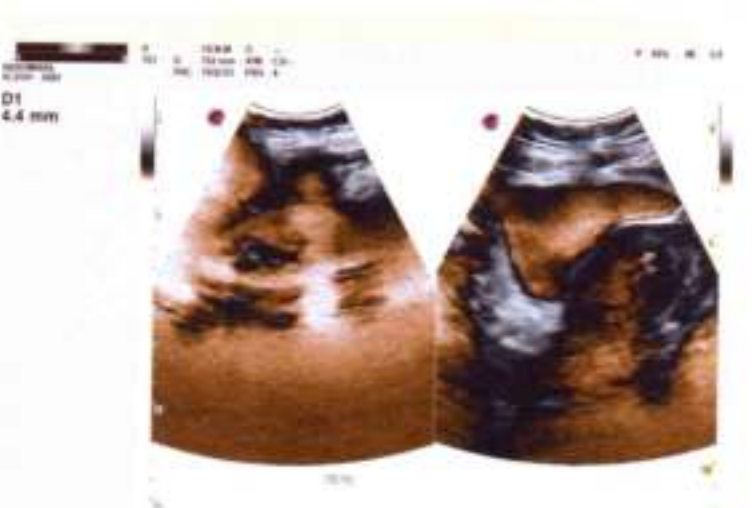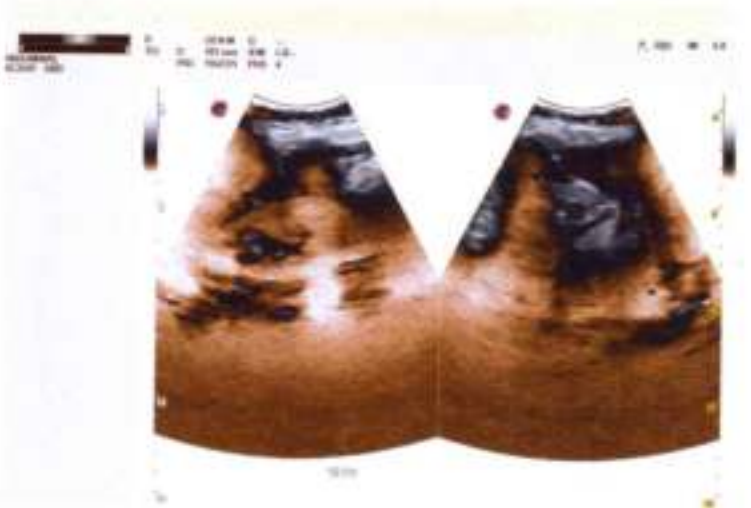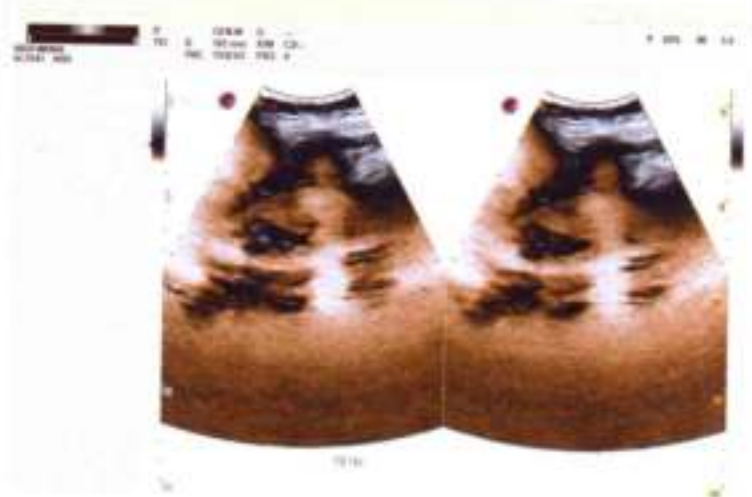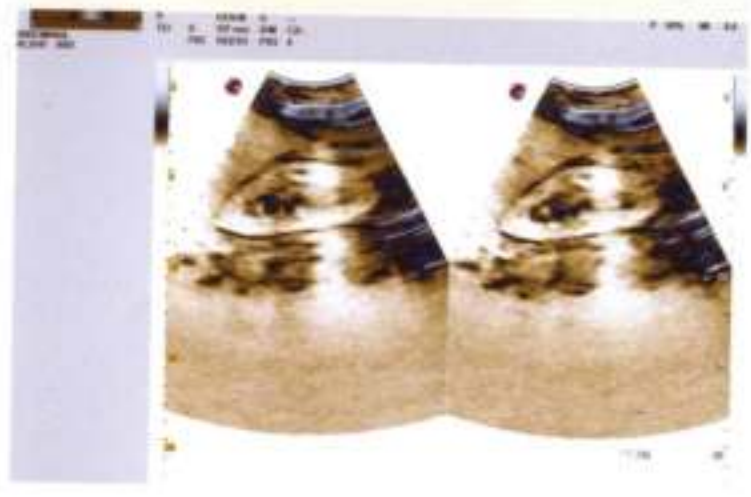
PATIENT'S NAME : SARIKA KUMARI AGE/SEX: 43 Y/F
REF. BY : DR.ASHUTOSH MISHRA (MD) Saturday, August 26, 2023

U/S. WHOLE ABDOMEN

- LIVER** : Liver is normal in size, shape & echotexture. Intra hepatic biliary radicals are normal. Portal veinous channels are normal.
- G. B.** : Gall bladder is not visualized-(H/O-Cholecystectomy)
- C.B.D.** : C.B.D. is normal in caliber.
- PANCREAS** : Pancreas is normal in size, shape and echotexture. No evidence of any inflammatory disease or mass.
- SPLEEN** : Spleen is normal in size, shape and echotexture.
- Rt. KIDNEY** : Normal in size, shape and echotexture. Renal sinus is normal
Cortico medullary differentiation is normal. P. C. system is normal.
- Lt. KIDNEY** : Normal in size, shape and echotexture. Renal sinus is normal
Cortico medullary differentiation is normal. P. C. system is normal.
- URI. BLADDER** : Urinary bladder is normal in size, position. Wall thickness normal.
No evidence of calculus or mass.
- UTERUS** : Normal in size shape & echotexture. Endometrial echo is normal (4.4mm).
- OVARIES** : Rt. Ovary: - Normal in size.
Lt. Ovary:- Normal in size.
No free fluid seen in P. O. D.
- IMPRESSION** : **NO OBVIOUS SONOLOGICAL ABNORMALITY SEEN.**


Sonologist

Thanks for reference.





Call Now - 1800-123-3070

PANACEA HOSPITAL

A shelter for many hearts A Home for many lives

(An ISO 9001:2008 Certified Organisation)

Lab Attached with CMC Vellore Under EQAS Scheme

PATIENT'S NAME : SARIKA KUMARI

AGE/SEX: 43 Y/M

REF. BY : Dr. ASHUTOSH MISHRA

DATE:26/08/2023

X-RAY CHEST (PA VIEW)

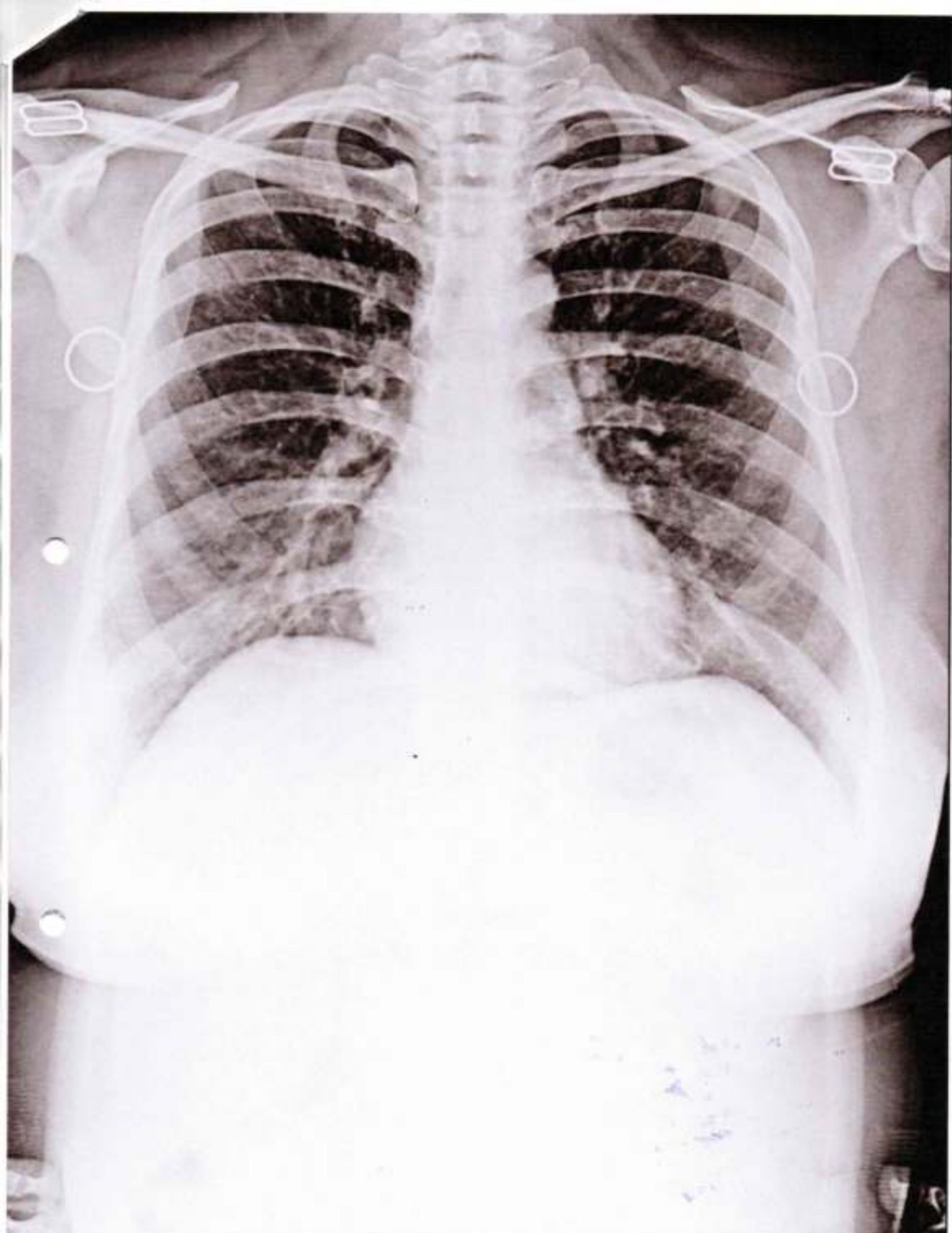
- Bilateral visualized lung fields appear normal.
- Trachea appears normal in position.
- Both hila appear normal in size and are symmetrical.
- Cardiac shadow within normal limits.
- Both CP angles appear clear.
- Bony rib cage and soft tissue shadows appear normal.

IMPRESSION

- **No obvious abnormality noted in the chest radiograph.**

DR. R. K. TIWARI
MD RADIODIAGNOSIS (GOLD MEDALIST)
KGMU, LUCKNOW
EX-RESIDENT (IMS BHU)

Thanks for reference.



SARIKA KUMARI 43Y/F 2274 O CHEST P.A. 26-Aug-23 10:52 AM