

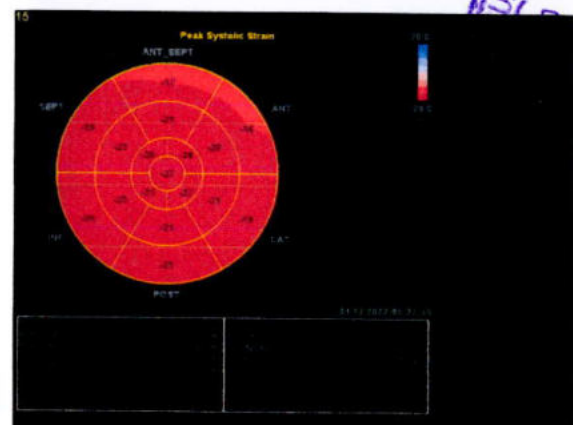
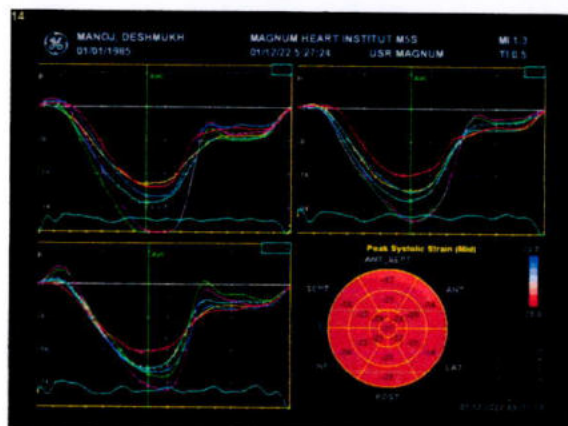
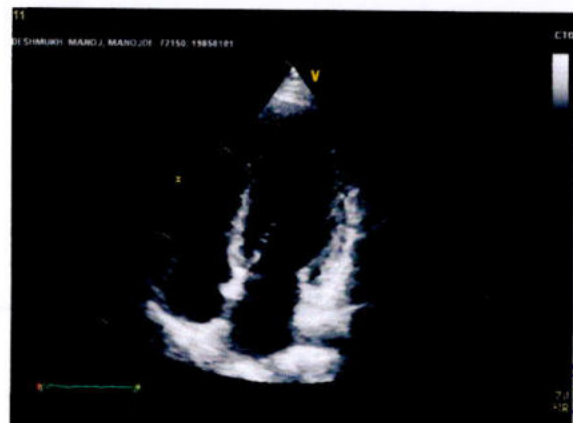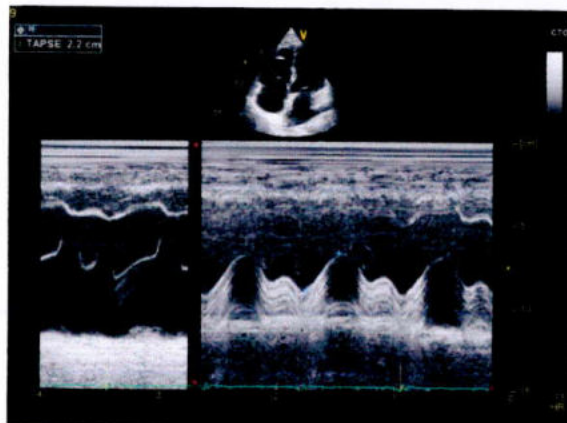
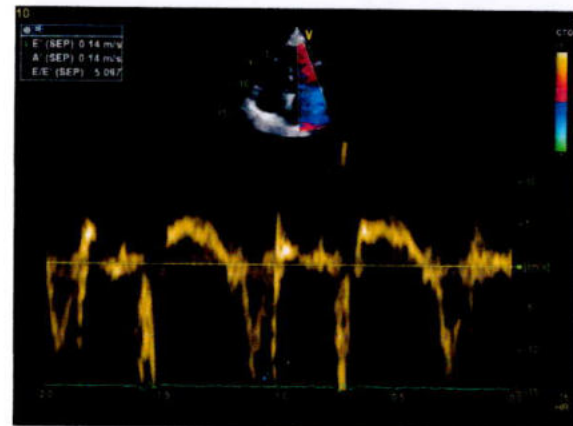
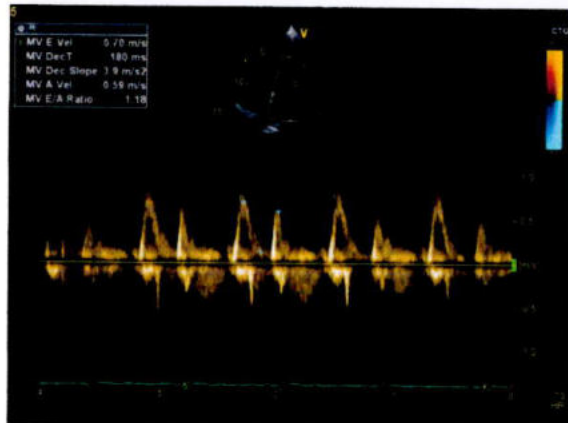
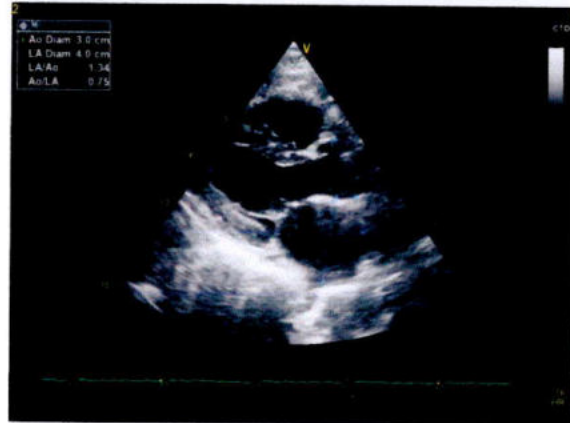
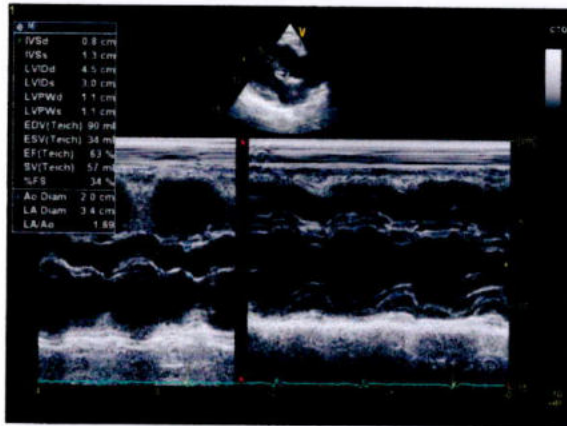
MAGNUM MULTISPECIALITY HOSPITAL NASIK ROAD, NASHIK

Name **MANOJ, DESHMUKH**

Sex **Male**

Age **37**

Date **01/12/2022**



MAGNUM MULTISPECIALITY HOSPITAL
NASIK ROAD, NASHIK
Regd. No. 1884



Chopda Medicare & Research Centre Pvt. Ltd's

MAGNUM

HEART INSTITUTE

ISO 9001 : 2008 CERTIFIED HOSPITAL

ECHOCARDIOGRAPHY AND COLOUR DOPPLER IMAGING

NAME:-MANOJ DESHMUKH

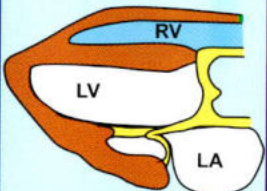
Date :- 01/12/2022

AGE:-37YEARS /FEMALE

REF DOCTOR:-HEALTH CHEKUP

REGIONAL ANALYSIS OF THE HEART

PARASTERNAL LONG AXIS

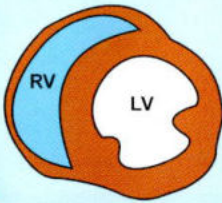


NORMAL SIZE LV WITH MILD MR WITH TRIVIAL TR GOOD LV FUNCTION EF= 60%

LEFT VENTRICLE - NORMAL SIZED
NO REGIONAL WALL MOTION ABNORMALITY
NO S/O LV HYPERTROPHY IVS = 2mm, PW = 11mm PRESENT
NO S/O DIASTOLIC DYSFUNCTION.
OVERALL GOOD LV FUNCTION..EF= 60%
NO LVOT GRADIENT = mm Hg

LEFT ATRIUM - NORMAL SIZED (34mm)

PARASTERNAL SHORT AXIS



TAPSE - 22MM

RIGHT ATRIUM /VENTRICLE - NORMAL SIZED
OVERALL GOOD RV FUNCTION.

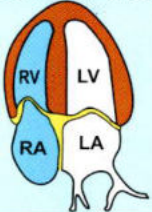
TRIVIAL MITRAL REGURGITATION.
MILD TRICUSPID REGURGITATION.

NO S/O PULMONARY HYPERTENSION PRESENT
PULMONARY ARTERY SYSTOLIC PRESSURE = 35mm Hg

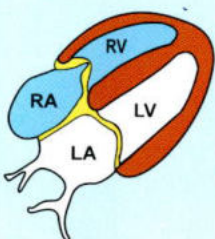
NO S/O PERICARDIAL EFFUSION NOTED.
IVC NORMAL.

Ao Diam : 20mm

APICAL FOUR CHAMBER



SUBCOSTAL



DR. RAHUL SHEWALE

M.D. (Medicine)

D.M. (Cardiology)

Consultant Cardiologist
Regd. No. 2010041390

Dr. MANOJ B. CHOPDA

M.D. (Medicine) D.M. (Cardiology)

INTERVENTIONAL CARDIOLOGIST

LETTER OF APPROVAL / RECOMMENDATION

To,

The Coordinator,
Mediwheel (Arcofemi Healthcare Limited)
Helpline number: 011- 41195959

Dear Sir / Madam,

Sub: Annual Health Checkup for the employees of Bank of Baroda

This is to inform you that the following employee wishes to avail the facility of Cashless Annual Health Checkup provided by you in terms of our agreement.

PARTICULARS	EMPLOYEE DETAILS
NAME	MR. DESHMUKH MANOJ SURESHRAO
EC NO.	175206
DESIGNATION	BRANCH HEAD
PLACE OF WORK	TRYAMBAKESHWAR
BIRTHDATE	06-02-1985
PROPOSED DATE OF HEALTH CHECKUP	01-12-2022
BOOKING REFERENCE NO.	22D175206100032186E

This letter of approval / recommendation is valid if submitted along with copy of the Bank of Baroda employee id card. This approval is valid from **30-11-2022** till **31-03-2023** The list of medical tests to be conducted is provided in the annexure to this letter. Please note that the said health checkup is a **cashless facility** as per our tie up arrangement. We request you to attend to the health checkup requirement of our employee and accord your top priority and best resources in this regard. The EC Number and the booking reference number as given in the above table shall be mentioned in the invoice, invariably.


We solicit your co-operation in this regard.

Yours faithfully,

Sd/-

Chief General Manager
HRM Department
Bank of Baroda

(Note: This is a computer generated letter. No Signature required. For any clarification, please contact Mediwheel (Arcofemi Healthcare Limited))



बैंक ऑफ़ बड़ोदा
Bank of Baroda

कूट क्र. | E.C.No. **175206**

नाम | Name **Manoj Suresh Rao Deshmukh**

पदनाम | Desi. **Manager**

धारक के हस्ताक्षर | Signature of Holder

Manoj Deshmukh

01/03/2022

जारी करने की तारीख

Date of Issue

S. P. Deshmukh

जारीकर्ता प्राधिकारी

Issuing Authority





भारत सरकार
GOVERNMENT OF INDIA



मनोज सुरेशराव देशमुख
Manoj Suresh Rao Deshmukh
जन्म वर्ष/YoB:1985
पुरुष Male



5384 7815 2618

आधार - सामान्य माणसाचा अधिकार



भारतीय विशिष्ट पहचान प्राधिकरण
UNIQUE IDENTIFICATION AUTHORITY OF INDIA

पत्ता:
463, वकील मळा
धान्दरफळ बुद्रुक, धंधारफळ,
अहमदनगर
महाराष्ट्र, 422603

Address:
463, vakil mala Dhandarphal
Bk, Dhandarphal,
Ahmadnagar
Maharashtra, 422603

Aadhaar - Aam Aadmi ka Adhikar

**MAGNUM MULTISPECIALITY HOSPITAL
NASIK ROAD, NASHIK**

Name **MANOJ, DESHMUKH**

Sex **Male**

Age **37**

Date **01/12/2022**

Operator Name **Default user**

<u>2D</u>		<u>M MODE</u>		<u>Dop</u>	
Ao Diam	3.0 cm	IVSd	0.8 cm	MV E Vel	0.73 m/s
LA Diam	4.0 cm	LVIDd	4.5 cm	MV DecT	157 ms
LA/Ao	1.34	LVPWd	1.1 cm	MV Dec Slope	4.8 m/s ²
Ao/LA	0.75	IVSs	1.3 cm	MV A Vel	0.50 m/s
AVC	341 ms	LVIDs	3.0 cm	MV E/A Ratio	1.54
G peak SL (APLAX)	-21 %	LVPWs	1.1 cm	AV Vmax	1.20 m/s
G peak SL (A4C)	-24 %	EDV(Teich)	90 ml	AV maxPG	5.80 mmHg
G peak SL (A2C)	-22 %	ESV(Teich)	34 ml	TR Vmax	2.71 m/s
G peak SL (Avg)	-22 %	EF(Teich)	63 %	TR maxPG	29.31 mmHg
		%FS	34 %	A' (SEP)	0.14 m/s
		SV(Teich)	57 ml	E' (SEP)	0.14 m/s
		Ao Diam	2.0 cm	E/E' (SEP)	5.37
		LA Diam	3.4 cm		
		LA/Ao	1.69		
		TAPSE	2.25 cm		



Dr. Rahul Shewale
MD (Medicine) , DM (Cadiology)
Interventional Cadiologist

DATE: 2/12/22

HEIGHT -

WEIGHT:- 67.1 kg



MAGNUM NASHIK HEALTHCARE LLP

MAGNUM

MULTISPECIALITY HOSPITAL

S/B DR. JAYDEEP BHAMBARE

[9850086022]

PATIENT NAME :- manoj Deshmukh AGE/SEX:- 37/m

40

- Good exercise tolerance
- No any new complaints.

predominant r/f

O/G

BP

HR

SpO₂

St

CVS - S1S2 ⊕

CNS - Conscious

RS -

120/80/76 ⊕

? better

Gen.

clw -



S/B DR. D.K. Chandvani 02/12/2022

Routine Eye Checkup
Her Spots

↓ BE Ext Examination NAD
Pupils NDR (BD)
JIT (C)

(R) 6/18 Unaided ↑ 6/6 E glasses Dist
NG Unaided Near

(L) 6/12 Unaided ↑ 6/6 E glasses Dist
NG Unaided Near

fundus BE NAD

Color Vision Normal

Squint Nil

Movements Normal

A BE Myopia

Chandvani

Dr. D.K. Chandvani
M



Patient's Name : Mr. Manoj Deshmukh

Date : 01/12/2022

Ref. By : Dr. Manoj Chopda (MD,DM)

Age/Sex : 37 yrs / M

BLOOD EXAMINATION REPORT

(By Fully Automated cell counter)

Haemoglobin : 14.1 gm % (11.0 – 17.0 gm %)

White Blood Cells

Total Count : 5700 / cmm (4500 – 10500 / cmm)

Differential Count

Neutrophils : 62 % (45 – 75 %)
Lymphocytes : 34 % (20 – 48 %)
Eosinophils : 01 % (01 – 04 %)
Monocytes : 03 % (04 – 10 %)
Basophils : 00 % (00 – 01 %)

Platelets : 2.66 Lacs/cmm (1.5 – 4.5 Lacs/cmm)

R.B.C. : 4.38 mil/cmm (4.00 – 6.00 mil/cmm)
Haematocrit (P.C.V.) : 42.4 % (35 - 50 %)
M.C.V. : 97 fL (80 – 99 fL)
M.C.H. : 32.3 pg (27 – 32 pg)
M.C.H.C. : 33.3 g/dl (31.5 – 36 g/dl)
R.D.W. : 13.2 % (10.0 – 15.0 %)



Pathologist
Dr. Sudhir Sankalecha
MD (Path)
Reg. No. 70405

Patient's Name : Mr. Manoj Deshmukh

Date : 01/12/2022

Ref. By : Dr. Manoj Chopda (MD,DM)

Age/Sex : 37 yrs / M

BLOOD EXAMINATION REPORT

Test


Result

Blood Group

: ' B '

Rh Factor

: Positive



Pathologist
Dr. Sudhir Sankalecha
1884 MD (Path)
Reg. No. 70405

Patient's Name : Mr. Manoj Deshmukh

Date : 01/12/2022

Ref. By : Dr. Manoj Chopda (MD,DM)

Age/Sex : 37 yrs / M

BIOCHEMISTRY REPORT

<u>TEST</u>	<u>OBSERVED VALUE</u>	<u>NORMAL RANGE</u>
Blood Sugar (Fasting):	97.3 mg/dl	60 – 110 mg/dl
Blood Sugar (PP) :	102.3 mg/dl	60 – 140 mg/dl

<u>Test</u>	<u>Result</u>	<u>Reference Range</u>
HBA1C :	5.5 %	
METHOD :	HPLC METHOD	

Performed On : Biorad D 10

Reference Range As per ADA

Normal : Below 5.7%

Pre-Diabetes : 5.7% - 6.4%

Diabetes : \geq 6.5%

Guidance For Known Diabetes

Good Control : Below 6.5%

Fair Control : 6.5% - 7.0%

Unsatisfactory Control : 7.0% - 8.0%

Poor Control : $>$ 8.0%



Pathologist
Dr. Sudhir Sankalecha
MD (Path)
Reg.No - 70405

Patient's Name : Mr. Manoj Deshmukh


Date : 01/12/2022

Ref. By : Dr. Manoj Chopda (MD,DM)

Age/Sex : 37 yrs / M

BIOCHEMISTRY REPORT

<u>TEST</u>	<u>OBSERVED VALUE</u>	<u>NORMAL VALUE</u>
<u>LIPID PROFILE</u>		
S. Cholesterol :	117.7 mg/dl	Up to 200 mg/dl
S. Triglyceride :	71.3 mg/dl	Up to 160 mg/dl
HDL Cholesterol :	29.2 mg/dl	30 – 65 mg/dl
LDL Cholesterol :	74.24 mg/dl	75 – 165 mg/dl
VLDL Cholesterol :	14.26 mg/dl	6.0 – 38.0 mg/dl
LDL/HDL Ratio :	2.54	2.5 – 4
Chol/HDL Chol Ratio :	4.03	3 – 5.5



MS
Pathologist
Dr. Sudhir Sankalecha
MD (Path)
Reg. No. 70405

Patient's Name : Mr. Manoj Deshmukh

Date : 01/12/2022

Ref. By : Dr. Manoj Chopda (MD,DM)

Age/Sex : 37 yrs / M

BIOCHEMISTRY REPORT

<u>TEST</u>	<u>OBSERVED VALUE</u>	<u>NORMAL RANGE</u>
Blood Urea	: 16.6 mg/dl	15 – 45 mg/dl
S.Creatinine	: 1.05 mg/dl	0.6 – 1.4 mg/dl
S.Uric acid	: 4.7 mg/dl	2.5 – 7.2 mg/dl
LFT :		
S.Bilirubin		
Total	: 0.8 mg/dl	0.2 – 1.1 mg/dl
Direct	: 0.5 mg/dl	0.0 – 0.4 mg/dl
Indirect	: 0.3 mg/dl	0.2 – 0.6 mg/dl
S.G.O.T.	: 16.2 IU/L	8 – 40 IU/L
S.G.P.T.	: 10.4 IU/L	5 – 50 IU/L
S.Alk PO4	: 81.0 IU/L	70 – 306 IU/L
S.Proteins		
Total	: 7.1 g/dl	6 – 7.8 g/dl
Albumin	: 4.3 g/dl	3.2 – 4.6 g/dl
Globulin	: 2.8 g/dl	2.3 – 3.5 g/dl
A/G Ratio	: 1.53	
Gamma –GT	: 30.7 IU/L	0 – 45 IU/L



SSS
 Pathologist
 Dr. Sudhir Sankalecha
 MD (Path)

Patient's Name : Mr. Manoj Deshmukh

Date : 01/12/2022

Ref. By : Dr. Manoj Chopda (MD,DM)

Age/Sex : 37 yrs/Male

THYROID FUNCTION TEST REPORT

<u>TEST</u>	<u>OBSERVED VALUE</u>	<u>NORMAL RANGE</u>
T3	1.064 ng/ml	0.69 – 2.15 ng/ml
T4	8.166 ug/dl	5.2 – 12.7 ug/
TSH Ultra-Sensitive	1.927 uIU/ml	0.4 – 4.5 uIU/ml

METHOD : By Chemiluminescence System



Pathologist
Dr. Sudhir Sankalecha
MD (Path)
Reg.No - 70405

Patient's Name : Mr. Manoj Deshmukh

Date : 01/12/2022

Ref. By : Dr. Manoj Chopda (MD,DM)

Age/Sex : 37 yrs / M

URINE EXAMINATION REPORT

PHYSICAL CHARACTERISTICS

Volume : 20 ml

Appearance : Clear

Colour : Yellow

Reaction : Acidic

CHEMICAL EXAMINATION

Albumin : Absent

Bile Salts : Absent

Sugar : Absent

Bile Pigments : Absent

Ketones : Absent

MICROSCOPIC EXAMINATION

Epithelial Cells : 1 - 2/hpf

R.B.C.s : Absent

Pus Cells : 1 - 2/hpf

Casts : Absent

Crystals : Absent

Bacilli : Absent

Other : Absent



Pathologist
Dr. Sudhir Sankalecha
MD (Path)
Reg. No. 70405

NAME: MR. MANOJ DESHMUKH	DATE: 01/12/2022
AGE/ SEX: 37 YEARS/ MALE	REFERRED BY: DR. MANOJ CHOPDA (MEDIWHEEL HEALTH CHECKUP)

XRAY CHEST PA (VIEW)

Clinical profile- Health checkup.

Both the lungs are clear and do not show any obvious focal lesion.
Bilateral costo-phrenic and cardio-phrenic angles appear clear.

There is no evidence of pleural effusion or pneumothorax on either side.

Both the hilum appear normal.

Domes of diaphragm have normal contours and positions.

Visualised bones and soft tissues reveal no abnormality.

CONCLUSION:

- No significant abnormality is seen.





NAME: MR. MANOJ DESHMUKH	DATE: 01/12/2022
AGE/ SEX: 37 YEARS/ MALE	REFERRED BY: DR. MANOJ CHOPDA (MEDIWHEEL HEALTH CHECKUP)

ULTRASOUND ABDOMEN & PELVIS

Clinical profile- Health check up

Liver: Normal in size(12.9 cm), shape and shows normal echotexture. No evidence of any space occupying lesion seen. Intrahepatic biliary radicals are not dilated. Portal vein is normal in caliber.

Gallbladder: GB is partially distended. No evidence of any calculus seen. No wall thickening/pericholecystic fluid collection noted. CBD is normal in caliber.

Pancreas: Visualized in entire extent , appears normal in bulk & echotexture.

Spleen: Appears normal in size (10.4 cm), shape and echotexture. No calcification or mass is seen. Splenic vein is not dilated.

Kidneys: Right kidney – 11.2 x 3.8 cm. Left kidney - 9.8 x 4.2 cm.

Both kidneys are normal in shape, positions and echotexture. Bilateral corticomedullary differentiation appears normal. No hydronephrosis seen. No evidence of any calculus or mass lesion seen.

Urinary Bladder: is well distended. No evidence of calculus/ wall thickening noted.

Prostate is normal in size and echotexture.

Lymphadenopathy: No significant lymphadenopathy noted.

Free fluid: No evidence of any free fluid in peritoneal cavity.

IMPRESSION:

- No other significant abnormality seen.

Clinical correlation is suggested.



DR. TRIPTI PAREEK
(DNB RADIODIAGNOSIS)

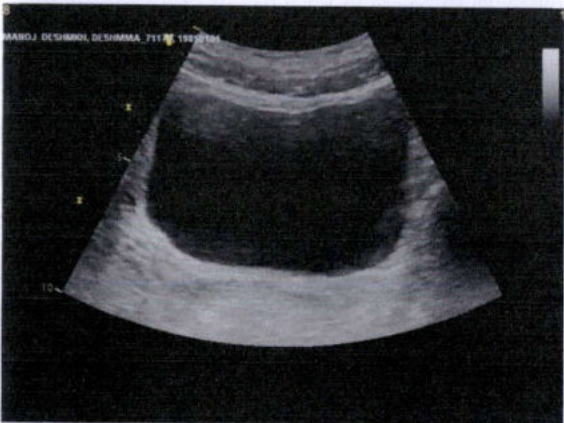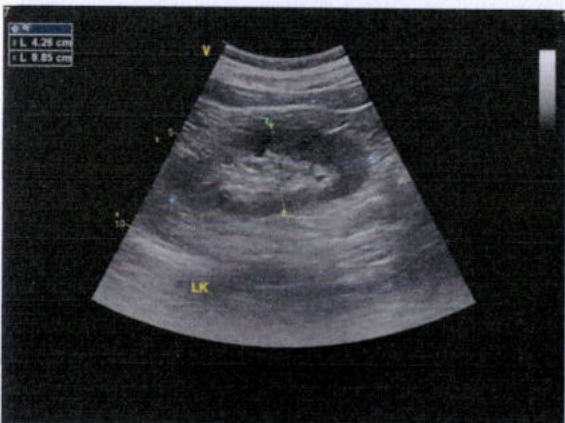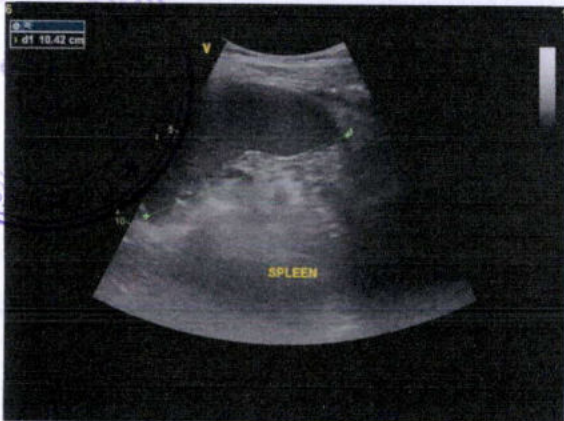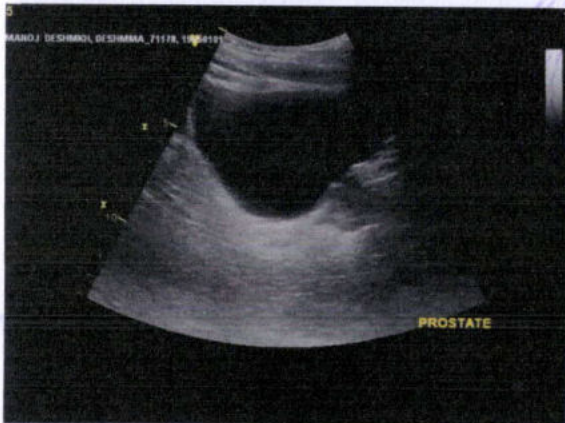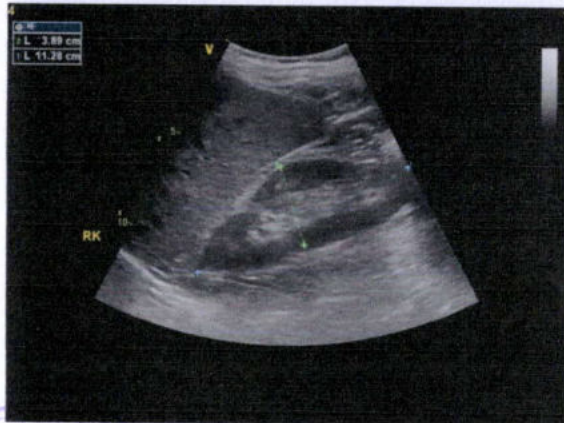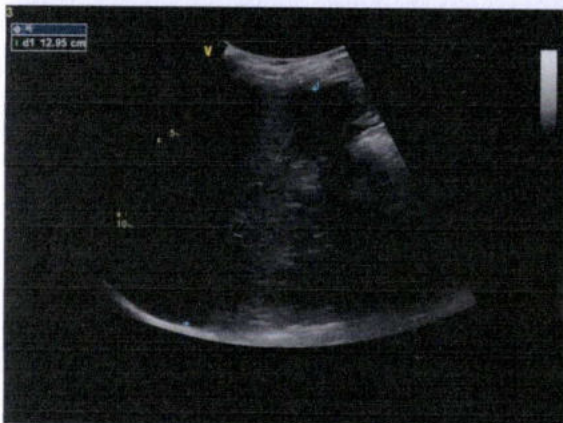
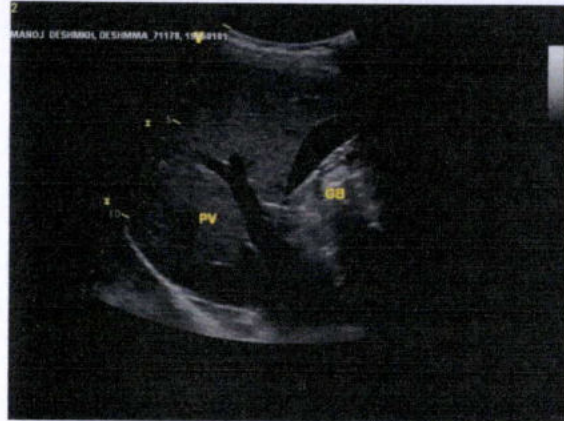
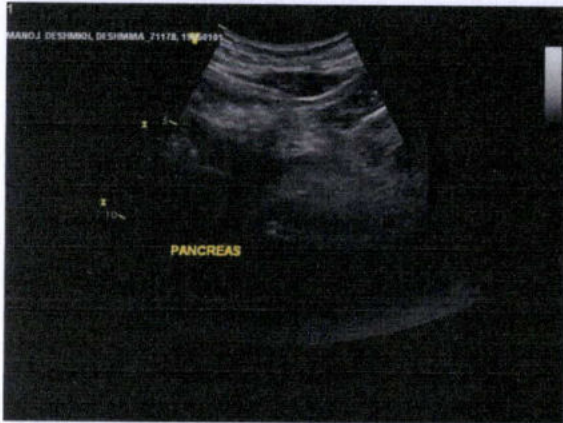
MAGNUM MULTISPECIALITY HOSPITAL NASIK ROAD, NASHIK

Name **DESHMKH, MANOJ**

Sex **Male**

Age **37**

Date **01/12/2022**

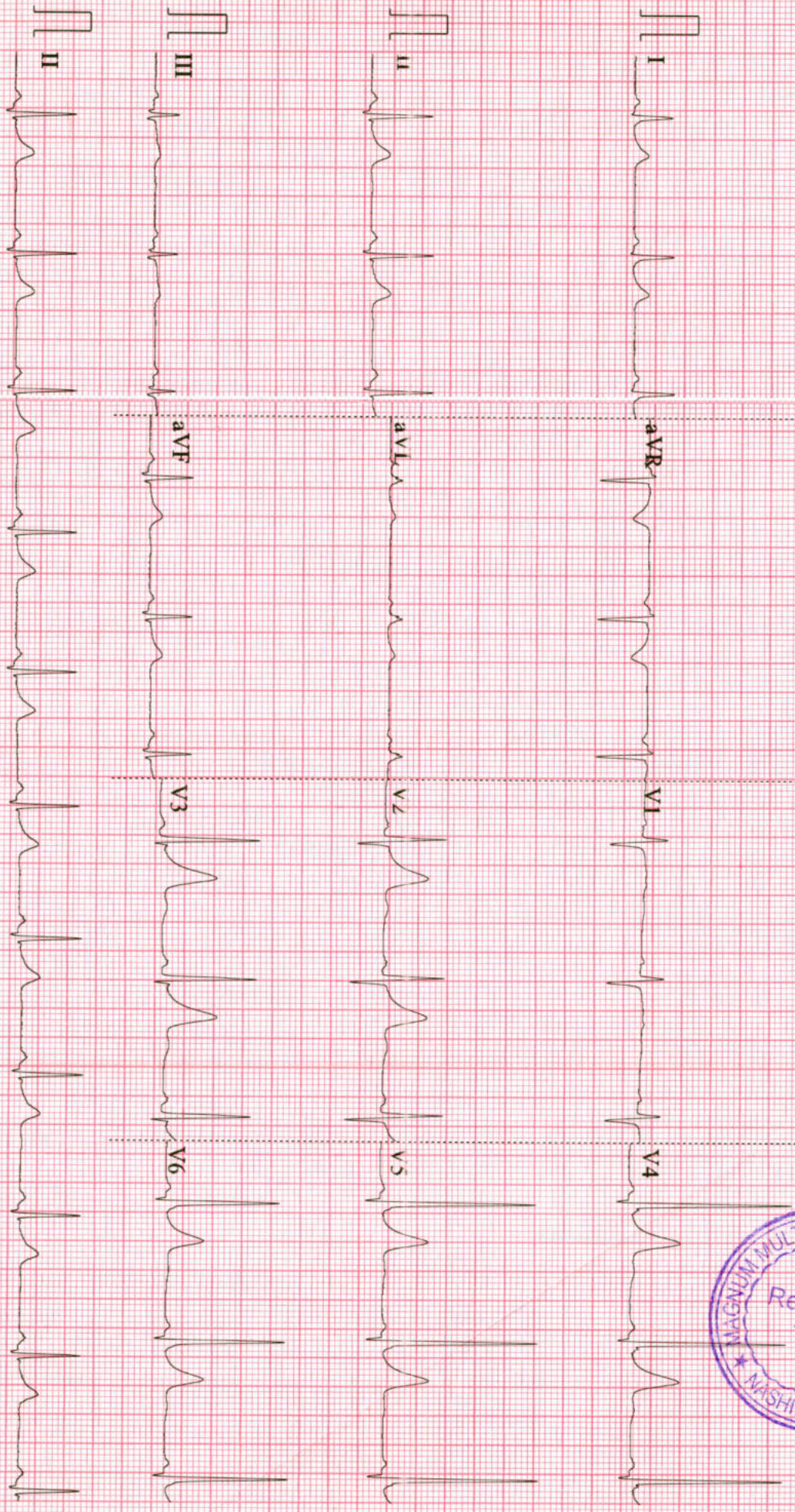


ID: 0
MANOJ DESHMUKH
Male 37Years
Department:

01-12-2022 09:38:28 AM
HR : 63 bpm
P : 102 ms
PR : 130 ms
QRS : 92 ms
QT/QTc : 394/404 ms
P/ORS/ST : 55/45/46 °
RV5/SV1 : 2.645/0.542 mV

Diagnosis Information:
Sinus rhythm
Normal ECG

Report Confirmed by:



0.05~35Hz AC50 25mm/s 10mm/mV 4.2.5s+1r 63 SE-1200Express V2.21 Glasgow V28.6.0 MAGNUM MULTISPECIALITY