



MC-4282

DEPT IMMUNOCHEMISTRY



Name : Mr. RAVADA ANIL KUMAR Age : 38Yr 2Mth 20Days Gender : Male
 UHID : AHS.0000249025 / AHSOPP790695 W/BNo/RefNo : OP
 SIN \ LRN : 8009898 \ 3508474
 Specimen : Blood
 Ref Doctor : SELF REFERRAL



Collected on : 10-SEP-2022 10:57:46 AM Received on : 10-SEP-2022 11:12:51 AM Reported on : 10-SEP-2022 01:00:50 PM

MEDIWHEEL FULL BODY HC MALE BELOW 40

TEST NAME	RESULT	BIOLOGICAL REFERENCE INTERVALS	UNITS
TOTAL T4: THYROXINE - SERUM (Chemiluminescence)	9.81	4.87 - 11.72	µg/dL
THYROID STIMULATING HORMONE [TSH] (Chemiluminescence)	6.15 *	0.35 - 4.94	µIU/mL
TOTAL T3: TRI IODOTHYRONINE - SERUM (Chemiluminescence)	99	87 - 178	ng/dL

Report Status:Final

* - Abnormal Value

* END OF REPORT *

CHECKED BY 1125307
719788

First Report Printed On : 10-SEP-2022 04:41:20 PM
Printed On : 10-SEP-2022 04:41:21 PM

Dr DEEPA MAHESH

Page 1 of 1



MC-4282

HAEMATOLOGY



Name : Mr. RAVADA ANIL KUMAR Age : 38Yr 2Mth 20Days Gender : Male
 UHID : AHS.0000249025 / AHSOPP790695 W/BNo/RefNo : OP
 SIN ILRN : 8009894 \ 3508474
 Specimen : Blood
 Ref Doctor : SELF REFERRAL



Collected on : 10-SEP-2022 10:57:45 AM Received on : 10-SEP-2022 11:13:37 AM Reported on : 10-SEP-2022 12:07:36 PM

MEDIWHEEL FULL BODY HC MALE BELOW 40

TEST NAME	RESULT	BIOLOGICAL REFERENCE INTERVALS	UNITS
ERYTHROCYTE SEDIMENTATION RATE (ESR)			
ERYTHROCYTE SEDIMENTATION RATE (ESR) [Capillary photometry]	2	Adult Male- 0 - 10	mm/1st hr
CBC			
Hemoglobin (Photometry)	16	13-17	g/dL
RBC COUNT (Electrical impedance)	4.88	4.5 - 5.5	x(10) ¹² /l
Packed cell volume (Calculated)	47	40 - 50	%
WBC Count (Electrical impedance)	6.3	4 - 11	x(10) ⁹ /l
Differential Count (Flowcytometry/ Microscopy)			
Neutrophils	65	40 - 80	%
Lymphocytes	23	20 - 40	%
Monocytes	10	2 - 10	%
Eosinophils	02	1 - 6	%
Basophils	00	0 - 2	%
Platelet Count (Electrical impedance)	223	150 - 450	x(10) ⁹ /l

Report Status:Final

* - Abnormal Value

* END OF REPORT *

CHECKED BY : 147052
 150725

First Report Printed On : 10-SEP-2022 04:43:08 PM
 Printed On : 10-SEP-2022 04:43:10 PM

Dr. TRIVENI M

Name : Mr. RAVADA ANIL KUMAR Age : 38Yr 2Mth 20Days Gender : Male
 UHID : AHS.0000249025 / AHSOPP790695 W/BNo/RefNo : OP
 SIN ILRN : 8009896 \ 3508474
 Specimen : Blood
 Ref Doctor : SELF REFERRAL



Collected on : 10-SEP-2022 10:57:45 AM Received on : 10-SEP-2022 11:30:35 AM Reported on : 10-SEP-2022 12:57:45 PM

MEDIWHEEL FULL BODY HC MALE BELOW 40

<u>TEST NAME</u>	<u>RESULT</u>
BLOOD GROUPING AND TYPING (ABO and Rh)	
BLOOD GROUP	A
Rh (D) Type:	POSITIVE
Method:	COLUMN AGGLUTINATION
Report Status:Final	

* - Abnormal Value

* END OF REPORT *

CHECKED BY : 1186181
150725

First Report Printed On : 10-SEP-2022 04:44:33 PM
Printed On : 10-SEP-2022 04:44:34 PM



Dr. TRIVENI M

DEPARTMENT OF RADIOLOGY

Patient's Details	: Mr. RAVADA ANIL KUMAR	M 38 Years
UHID	: AHS.0000249025	Ward/Bed No. : OP /
I.P.No./Bill No.	: AHSOPP790695	Scanned on : 10-Sep-2022 11:0
Accession Number	: 10391.122095288	Reported On : 10-Sep-2022 13:22
Referring Doctor	:	

X-RAY CHEST - PA VIEW

X-ray No: 547

Clinical Information: Not provided at the time of reporting.

=====
FINDINGS:

Mild bronchiectatic changes noted in right upper and middle zones.

Rest of the lung fields are clear.

Cardia appears normal.

Costophrenic angles appear normal on both sides.

Domes of the diaphragm appear normal.

Both hila are unremarkable.

- *For clinical correlation.*

=====
(H)

Dr. Punith Kumar B M
Radiologist
Dept. Of Radiology and Imaging

---END OF THE REPORT---

N.B. : This is only a professional opinion and not the final diagnosis. Radiological investigations are subject to variations due to technical limitations. Hence, correlation with clinical findings and other investigations should be carried out to know true nature of illness.

DEPARTMENT OF RADIOLOGY

Patient's Details	: Mr. RAVADA ANIL KUMAR	M 38 Years
UHID	: AHS.0000249025	Ward/Bed No. : OP /
I.P.No./Bill No.	: AHSOPP790695	Scanned on : 10-Sep-2022 11:3
Accession Number	: 10391.222078560	Reported On : 10-Sep-2022 11:57
Referring Doctor	: SELF REFERRAL	

ULTRASOUND ABDOMEN AND PELVIS

Clinical information: Health checkup.

FINDINGS:

Liver appears normal in size, shape and echopattern measuring~ 12.0 cm. No focal parenchymal lesions identified. No evidence of intra/extrahepatic biliary tree dilatation noted. Portal vein appears to be of normal size.

Gall bladder moderately distended. No definite calculi identified. No evidence of abnormal wall thickening noted. CBD is normal.

Spleen appears normal in size, shape and echopattern measuring~ 7.9 cm. No focal parenchymal lesions identified.

Visualized portion of pancreas appears normal in size, shape and echopattern. No definite calcification or ductal dilatation noted.

Both kidneys appear normal in size, shape and echopattern. Corticomedullary differentiation appears maintained. No evidence of calculi or hydronephrosis seen on either side.

Right kidney measures ~ 9.0 x 1.7 cm. Left kidney measures ~ 9.2 x 1.8 cm.

Urinary bladder distended and appears normal. No evidence of abnormal wall thickening noted.


Prostate appears normal in size (Volume 16 cc). Normal echopattern noted within the gland.

No evidence of ascites seen.

IMPRESSION:

- No significant abnormality detected.

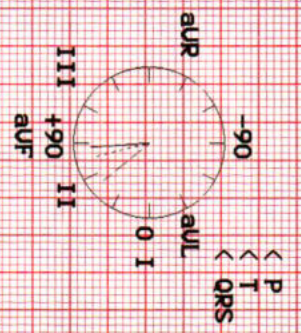
(u)


Dr. Mohammed Hashim Rashid
Radiologist
Dept. of Radiology & Imaging

---END OF THE REPORT---

N.B. : This is only a professional opinion and not the final diagnosis. Radiological investigations are subject to variations due to technical limitations. Hence, correlation with clinical findings and other investigations should be carried out to know true nature of illness.

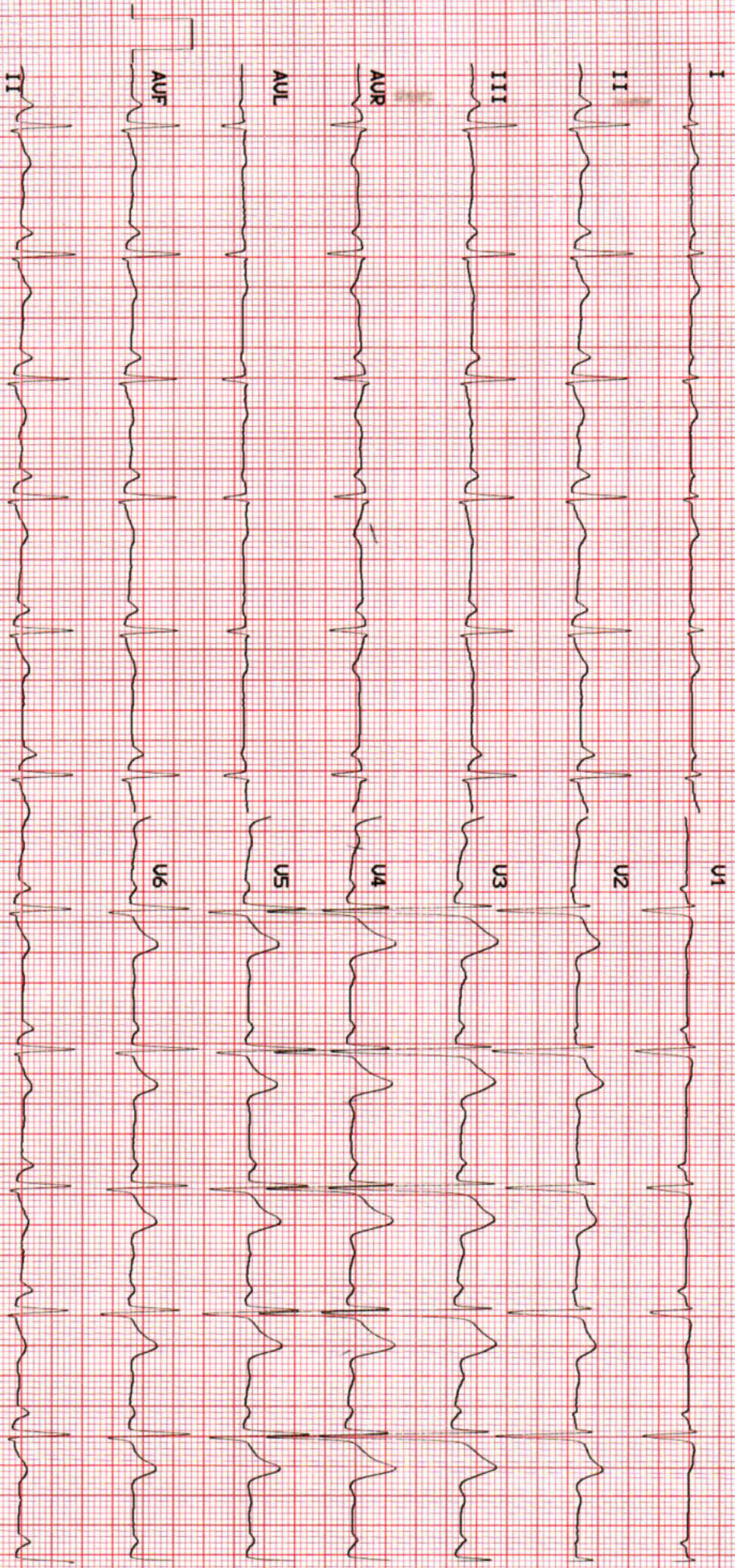
TEST: Measurement Results: M:
 QRS : 102 ms
 QT/QTcB : 382 / 410 ms
 PR : 156 ms
 P : 114 ms
 RR/PP : 870 / 840 ms
 P/QRS/T : 75 / 85 / 50 degrees
 QTd/QTcBd : 30 / 32 ms
 Sokolow : 1.7 mV
 NK : 10



AGE: Interpretation:

Mr. Ravada Pril Kumar
PHS-249085

Unconfirmed report.



DEPT. OF APOLLO HEALTH CHECK



CASE RECORD

Name : <i>MR Ravada Anil Kumar</i>	Age : <i>38</i>	Sex : <i>M/F</i>
Age :		UHID :

Physical Examination

General : Build _____ Height *170cm* Weight *55.9kg* BMI : _____

Anaemia _____ Icterus _____ Cyanosis _____ Clubbing _____

Oedema _____ Glands _____

HEAD & NECK :

Temp 98.2°

SpO2 100%

PR: 60b/min

ENT :

CVS :

Heart Rate & Rhythm

B.P. : Supine

Sitting *110/90/70* Standing _____

Chest shape

Heart Sounds

Murmurs

Thrills

RS :

Rate & Type

Breath Sounds

AHS. 249025
OPHTHALMIC EXAMINATION



NAME : Mrs. Ravada Anil
Kumar

AGE : 38 y

SEX : male

VISION :

RIGHT EYE :

LEFT EYE :

VISION WITH GLASS :

Vu 6/6 6/6 NM/6

OCULAR MOVEMENTS :


ANTERIOR SEGMENT :

Normal Both Eyes

FUNDUSCOPY :

ANY OTHER ABNORMALITY :

IMPRESSION :



DATE : 10/9/22

BANGALORE : Sheshadri Puram