


भारत सरकार
GOVERNMENT OF INDIA




उत्तम सिंह भंडारी
 Uttam Singh Bhandari
 जन्म वर्ष / Year of Birth : 1966
 पुरुष / Male

2552 5122 0294 

आधार — आम आदमी का अधिकार

Uttam Singh

[Signature]
Dr. NITIN AGARWAL
 MBBS, MD
 Regn. No. DMC-R-1436


भारतीय विशिष्ट पहचान प्राधिकरण
UNIQUE IDENTIFICATION AUTHORITY OF INDIA

पता : S/O डी एस. भंडारी, ए/६, म.न. १६, सेक्टर- १७, न्यू दिल्ली, नॉर्थ वेस्ट दिल्ली, दिल्ली, 110089

Address : S/O D.S. Bhandari, A/6, H.NO. 16, SECTOR- 17, NEW DELHI, North West Delhi, Delhi, 110089

Aadhaar - Aam Aadmi Ka Adhikaar


ONEPLUS ULTRASOUND LAB
 47, Marsh Vihar, Pitam Pura,
 Delhi-110034
 Ph. 011-42480101, 9599913051
 E-mail: oneplusul@gmail.com



Dr. NITIN AGARWAL
MBBS, MD
Regn. No. DMC-R-1436

ONEPLUS ULTRASOUND LAB
47, Harsh Vihar, Pitam Pura,
Delhi-110034
Ph. 011-42480101, 9599913051
E-mail: oneplusul@gmail.com

ONEPLUS
Ultras Lab



ONEPLUS ULTRASOUND LAB

47, HARSH VIHAR, PITAMPURA, DELHI- 110034

Mr. UTTAM SINGH BHANDARI
Age : 56/M
Ref. by : MEDIWHEEL
Indication 1 :
Indication 2 :
Indication 3 :
COMMENTS : Normal ECG.

ID : 1979
H/Wt : 170/75
Recorded : 30-6-2022 10:24
Medication 1 :
Medication 2 :
Medication 3 :

BPM : 74
BP : 124/80
P Axis : 60 deg
QRS Axis : 60 deg
T Axis : 53 deg

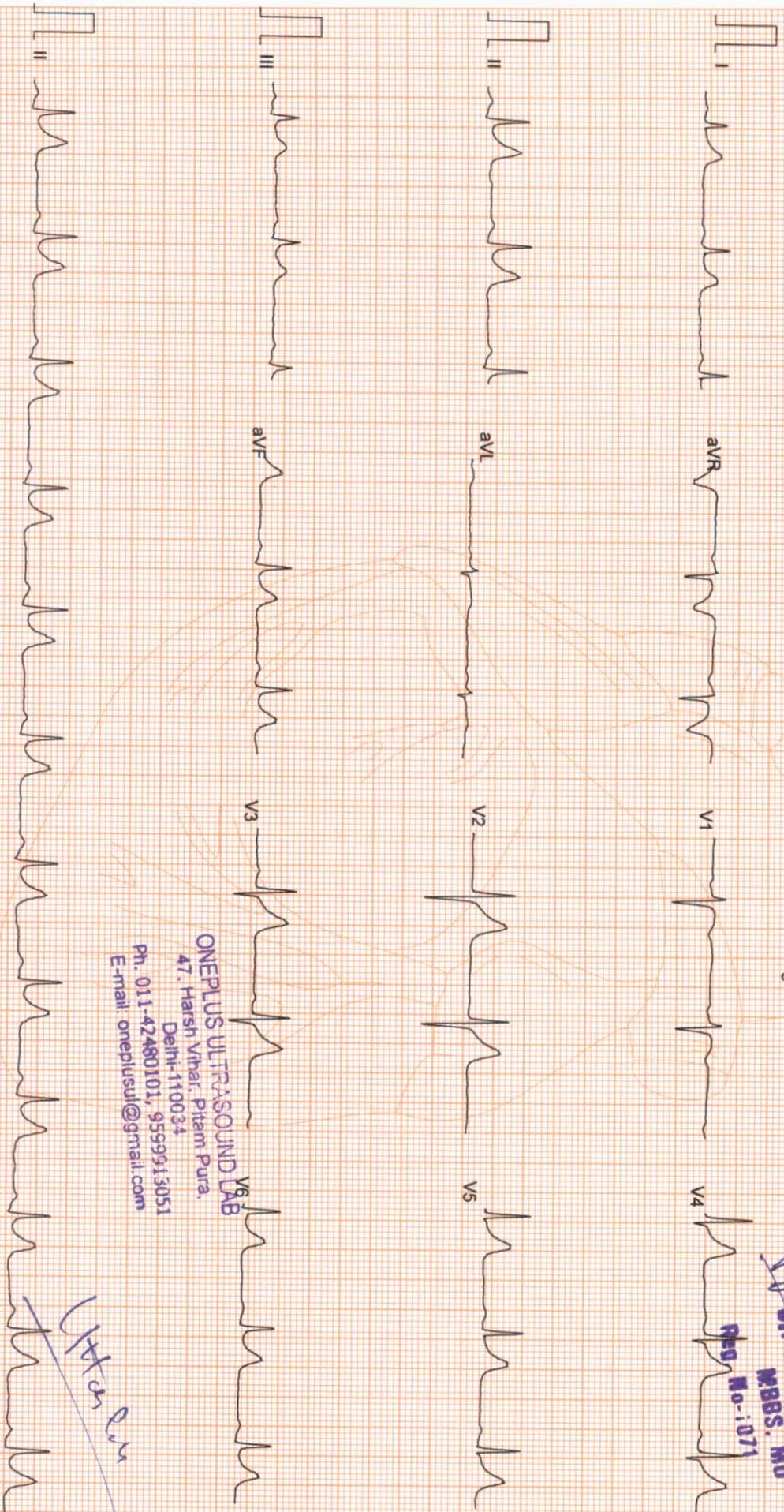
P duration : 90 msec
PR duration : 146 msec
QRS duration : 106 msec
QT interval : 293 msec
QTc interval : 317 msec

Raw E.C.G.(Seq)

Unconfirmed Report Reviewed By:

Cardiologist

Dr. P.K. GUPTA
Dr. P.K. GUPTA
MBBS, MD
Reg. No-1071



ONEPLUS ULTRASOUND LAB
47, Harsh Vihar, Pitam Pura,
Delhi-110034
Ph. 011-42480101, 9559913051
E-mail: oneplussul@gmail.com

Dr. Harsh Vihar

Filtered

25mm/sec 10mm/mV

CardiCom, INDIA

ONEPLUS ULTRASOUND LAB

47, HARSH VIHAR PITAMPURA DELHI 110034

MR. UTTAM SINGH BHANDARI

Age/Sex : 56/M
Ref. by : MEDWHEEL

Indication 1 :
Indication 2 :
Indication 3 :

ID : 996
H/Wt : 170/75
Recorded : 30-6-2022 10:29

TREADMILL TEST SUMMARY REPORT
Protocol: BRUCE

History:
Medication 1 :
Medication 2 :
Medication 3 :

PHASE	PHASE TIME	STAGE TIME	SPEED (Km./Hr.)	GRADE (%)	H.R. (BPM)	B.P. (mmHg)	RPP X100	II	ST LEVEL (mm) V2	V5	METS
STANDING											
SUPINE					78	124/80	96	1.3	2.6	1.3	
					79	124/80	97	1.3	2.6	1.3	
STAGE 1	2:59	2:59	2.70	10.00	107	134/82	143	1.3	2.5	1.4	4.80
STAGE 2	5:59	2:59	4.00	12.00	125	146/86	182	1.3	2.7	1.6	7.10
STAGE 3	6:59	0:59	5.40	14.00	146	160/90	233	0.4	2.3	0.8	8.06
PEAK EXER	6:59	0:59			146	160/90	233	0.4	2.3	0.8	8.06
RECOVERY	2:59	2:59	0.00	0.00	83	130/82	107	0.6	1.4	0.6	8.06

RESULTS

Exercise Duration : 6:59 Minutes
Max Heart Rate : 146 bpm
Max Blood Pressure : 160/90 mmHg
Max Work Load : 8.06 METS
Reason of Termination :

89 % of target heart rate 164 bpm

Negative for ischaemic disease

Dr. Harsh Vihar
Cardiologist
MBBS, MD

Reg. No. 1071

ONEPLUS ULTRASOUND LAB
47, Harsh Vihar, Pitam Pura,
Delhi-110034
Ph. 011-42480101, 9599913051
E-mail: oneplusul@gmail.com

Uttam Singh

MR. UTTAM SINGH BHANDARI

I.D. : 996

AGE/SEX : 56M

RECORDED : 30-6-2022 10:29

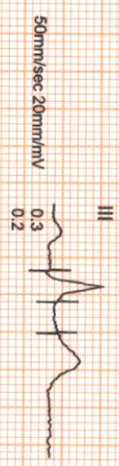
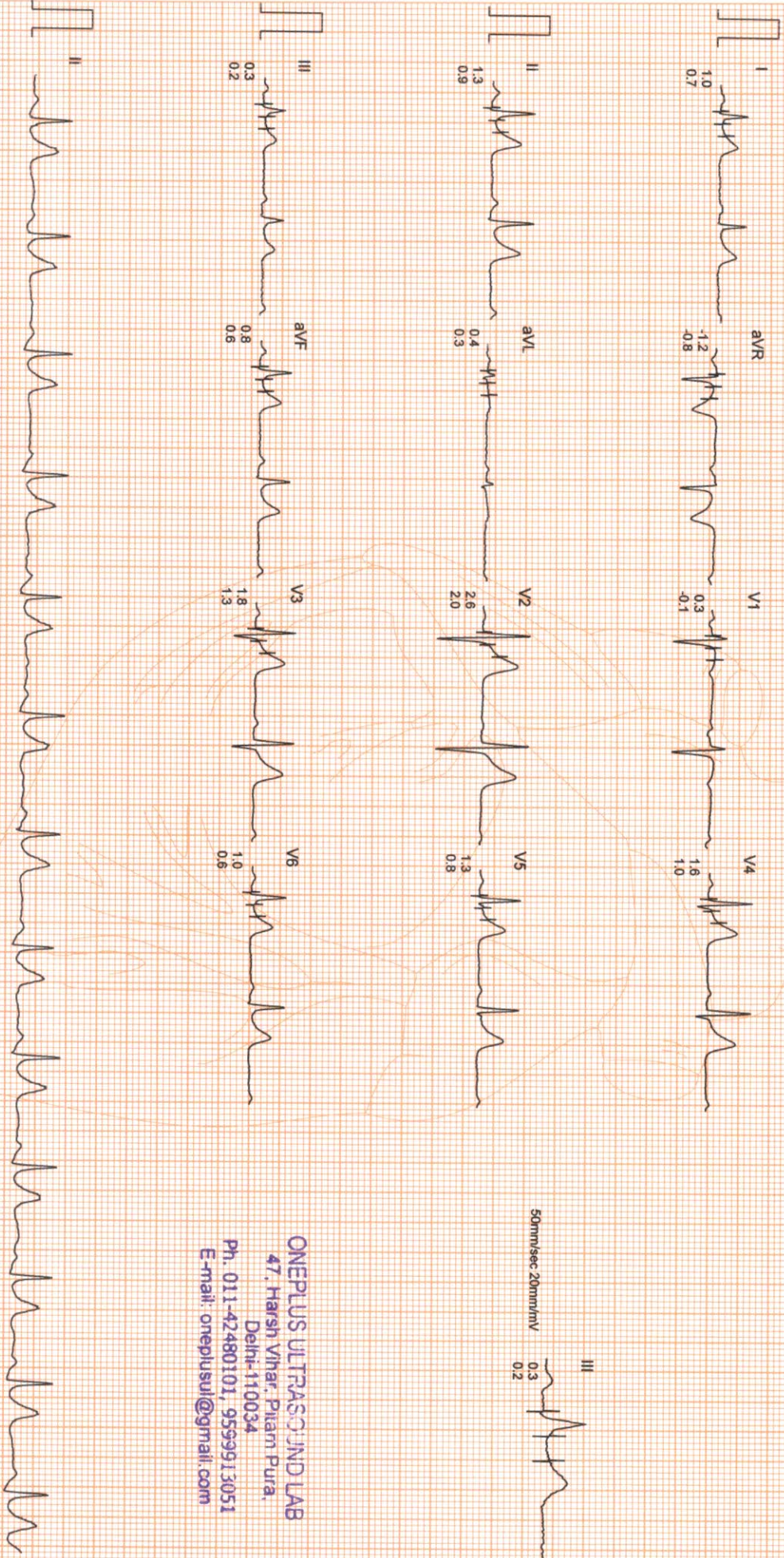
ONEPLUS ULTRASOUND LAB

STANDING
PRETEST

ST @ 10mm/mV
80ms PostJ

RATE : 78 BPM
B.P. : 124/80 mmHg

LINKED MEDIAN



ONEPLUS ULTRASOUND LAB
 47, Harsh Vihar, Pitam Pura,
 Delhi-110034
 Ph. 011-42480101, 9559913051
 E-mail: oneplusul@gmail.com

Filtered

Computer Corrected Baseline

25mm/sec 10mm/mV

CardiCom, INDIA Ph.:091-731-2620740, TeleFax:091-731-2431214

ONEPLUS ULTRASOUND LAB

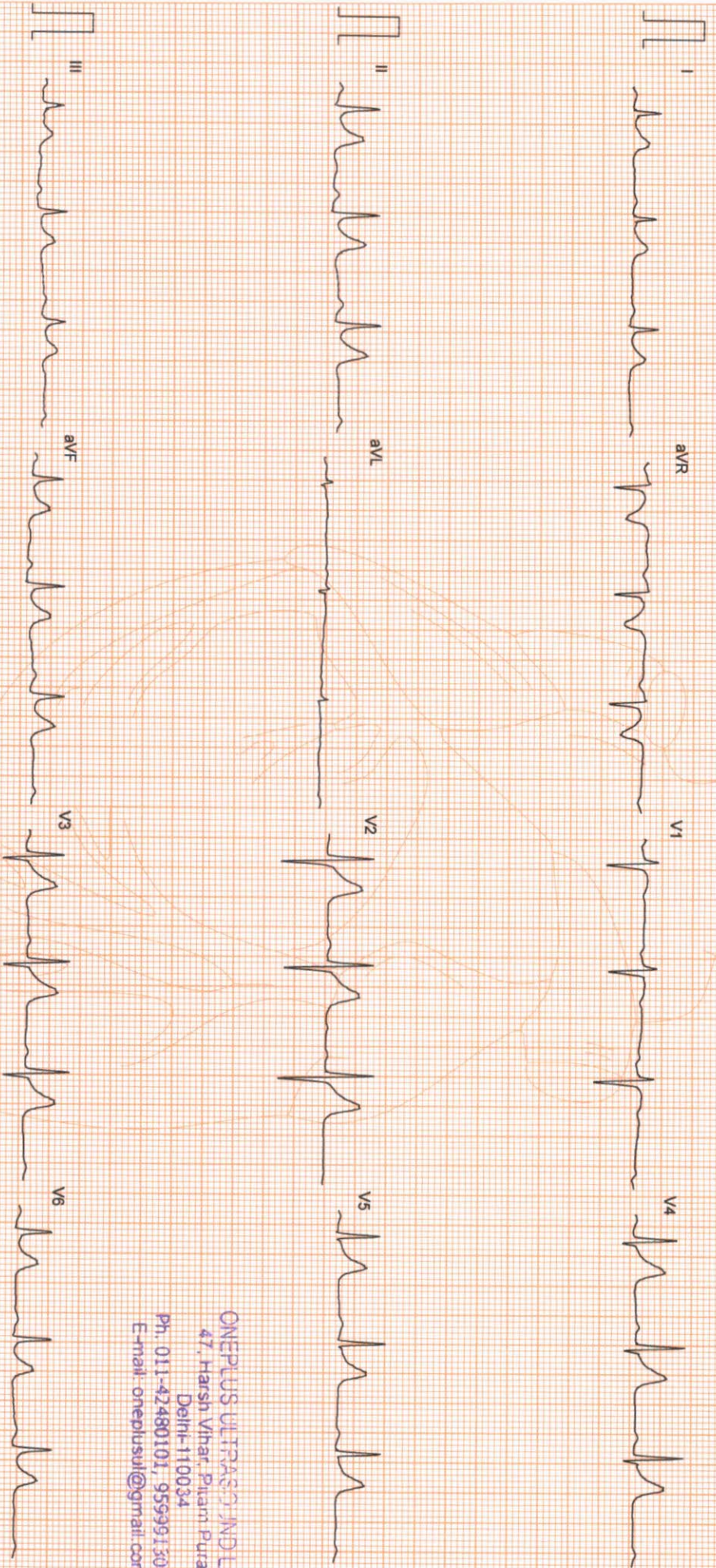
SUPINE
PRETEST

ST @ 10mm/mV
80ms PostJ

M. UTTAM SINGH BHANDARI
I.D. : 996
AGE/SEX : 56/M
RECORDED : 30-6-2022 10:29

RATE : 79 BPM
B.P. : 124/80 mmHg

RAW E.C.G.



ONEPLUS ULTRASOUND LAB
47, Harsh Vihar, Pitam Pura,
Delhi-110034
Ph. 011-42480101, 9559913051
E-mail: oneplusul@gmail.com

Filtered

25mm/sec 10mm/mV

CardiCom, INDIA Ph.:091-731-2620740, TeleFax:091-731-2431214

MR. UTTAM SINGH BHANDARI

I.D. : 996

AGE/SEX : 56/M

RECORDED : 30-6-2022 10:29

ONEPLUS ULTRASOUND LAB

BRUCE EXERCISE 1

PHASE TIME : 2:59

STAGE TIME : 2:59

ST @ 10mm/mV

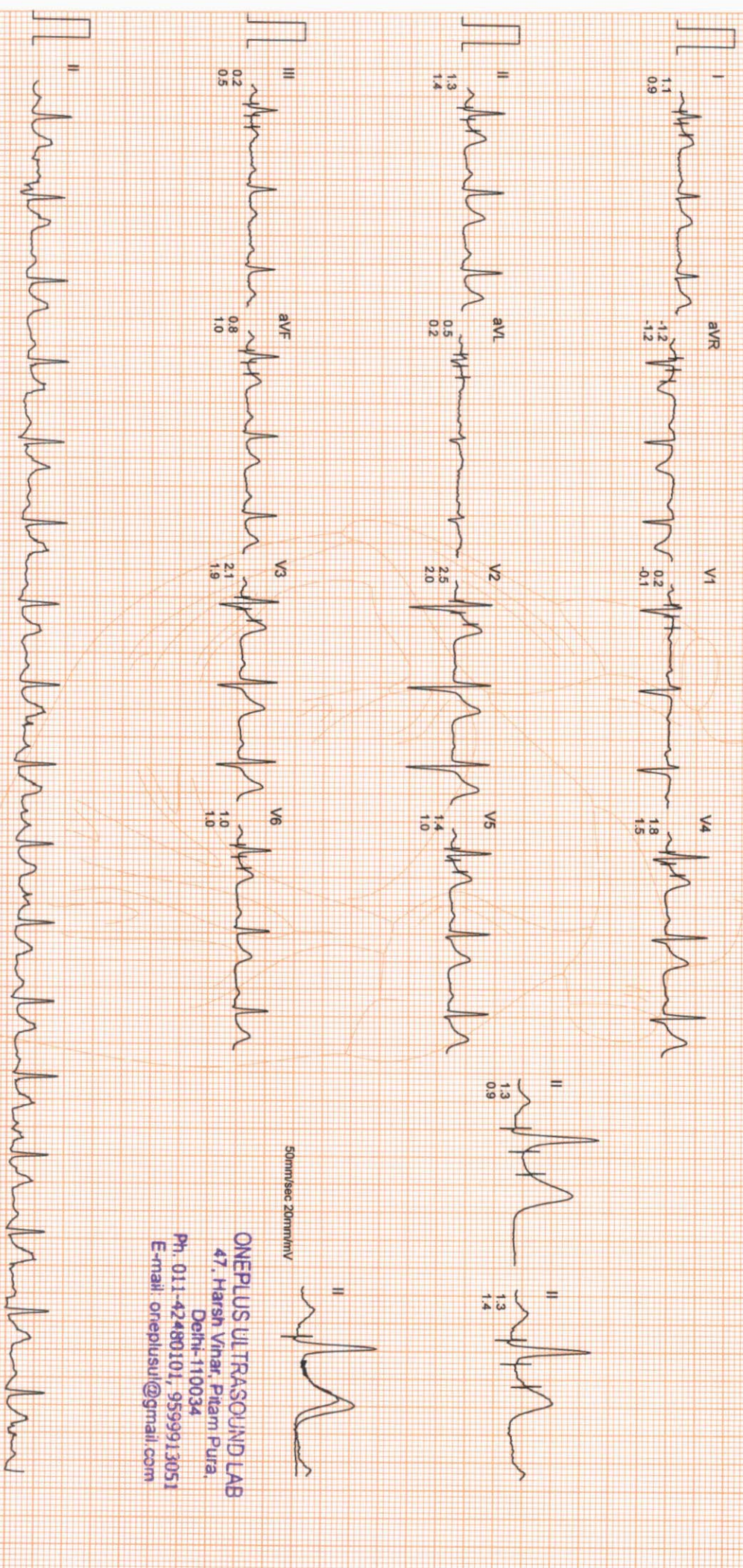
80ms PostJ

SPEED : 2.7 Km./Hr.

GRADE : 10.0 %

LINKED MEDIAN

RATE : 107 BPM
B.P. : 134/82 mmHg



50mm/sec 20mm/mV

ONEPLUS ULTRASOUND LAB
 47, Harsh Vihar, Pitam Pura,
 Delhi-110034
 Ph. 011-42480101, 9599913051
 E-mail: oneplusul@gmail.com

Filtered

Computer Corrected Baseline

25mm/sec 10mm/mV

CardiCom, INDIA Ph.:091-731-2620740, TeleFax:091-731-2431214

ONEPLUS ULTRASOUND LAB

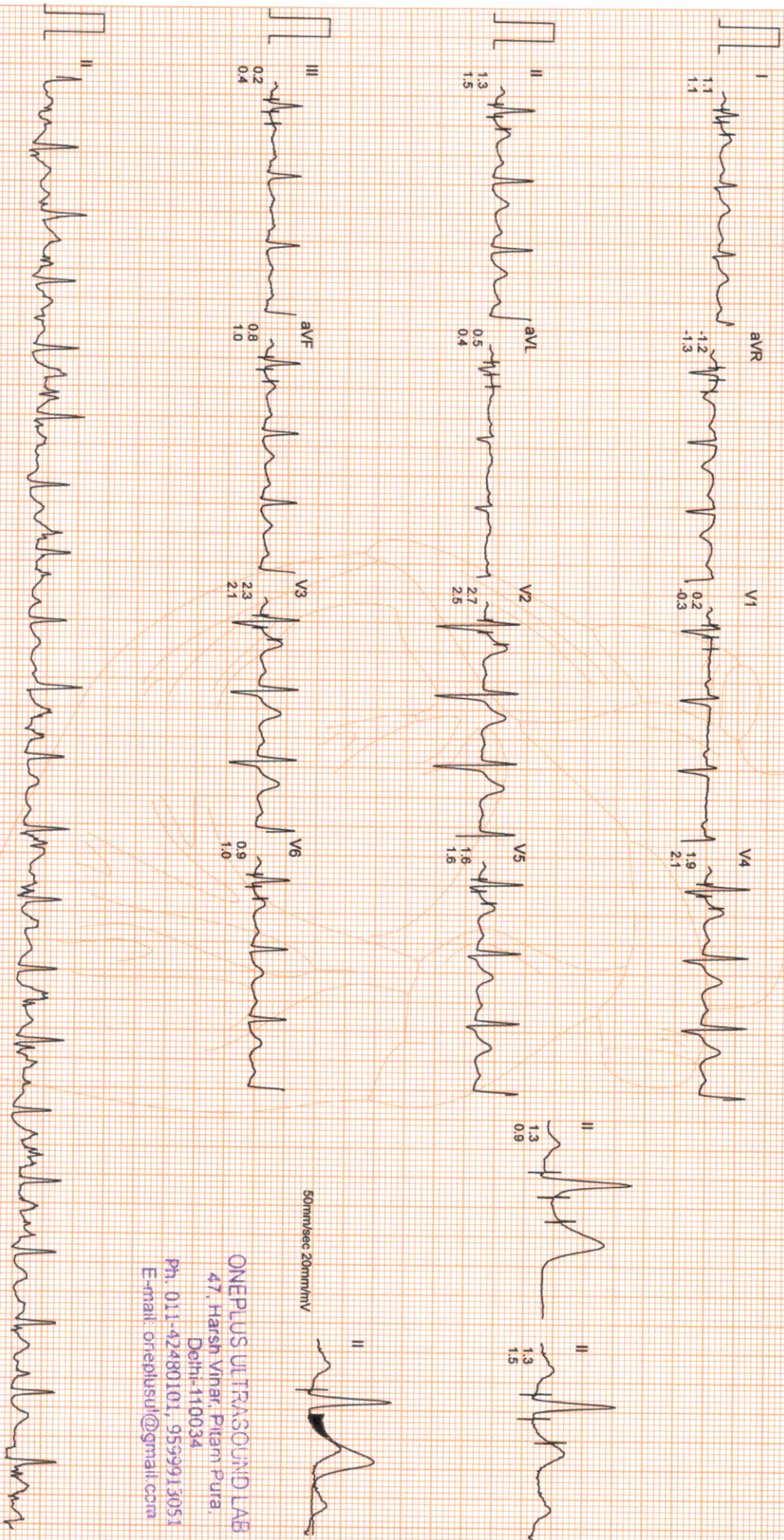
MR. UTTAM SINGH BHANDARI

I.D. : 996
AGE/SEX : 56/M
RECORDED : 30-6-2022 10:29

RATE : 125 BPM
B.P. : 146/86 mmHg

BRUCE
EXERCISE 2
PHASE TIME : 5:59
STAGE TIME : 2:59

ST @ 10mm/mV
80ms PostJ
SPEED : 4.0 Km./Hr.
GRADE : 12.0 %
LINKED MEDIAN



ONEPLUS ULTRASOUND LAB
47, Harsh Vihar, Pitam Pura,
Delhi-110034
Ph. 011-42480101, 9599913051
E-mail: oneplusul@gmail.com

MR. UTTAM SINGH BHANDARI

I.D. : 996

AGE/SEX : 56/M

RECORDED : 30-6-2022 10:29

ONEPLUS ULTRASOUND LAB

BRUCE

EXERCISE 3

PHASE TIME : 6:59

STAGE TIME : 0:59

ST @ 10mm/mV

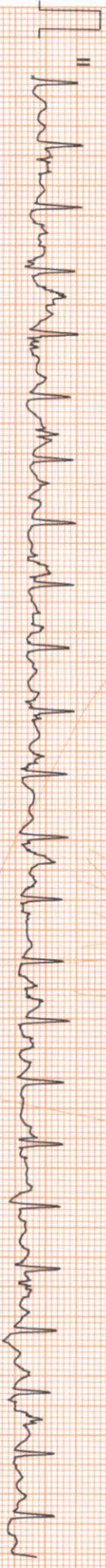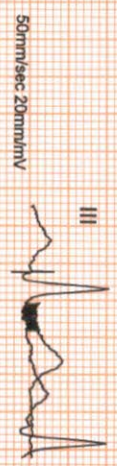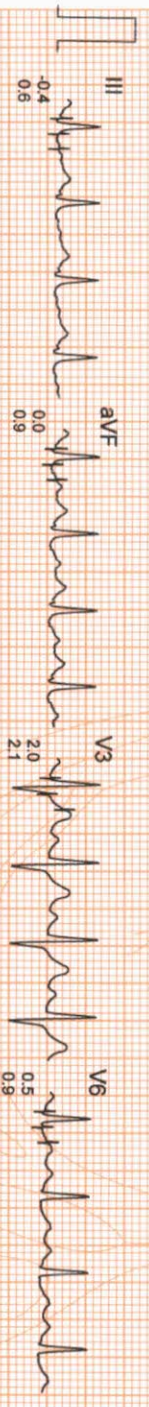
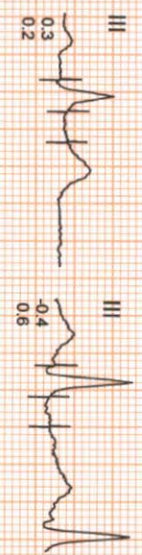
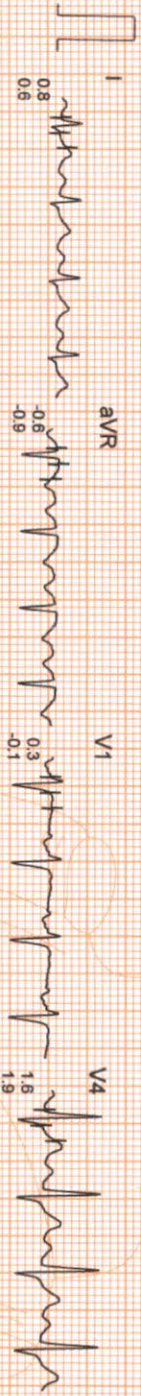
80ms PostJ

SPEED : 5.4 Km./Hr.

GRADE : 14.0 %

LINKED MEDIAN

RATE : 146 BPM
B.P. : 160/90 mmHg



ONEPLUS ULTRASOUND LAB
 47, Harsh Vihar, Pitam Pura,
 Delhi-110034
 Ph. 011-2480101, 9599913051
 E-mail: onepiusu@gmail.com

Filtered Computer Corrected Baseline

25mm/sec 10mm/mV

CardiCom, (INDIA) Ph.:091-731-2620740, TeleFax:091-731-2431214

ONEPLUS ULTRASOUND LAB

Mr. UTTAM SINGH BHANDARI

ID : 996

AGE/SEX : 56M

RECORDED : 30-6-2022 10:29

RATE : 146 BPM
B.P. : 160/90 mmHg

BRUCE
PEAK EXER

PHASE TIME : 6:59
STAGE TIME : 0:59

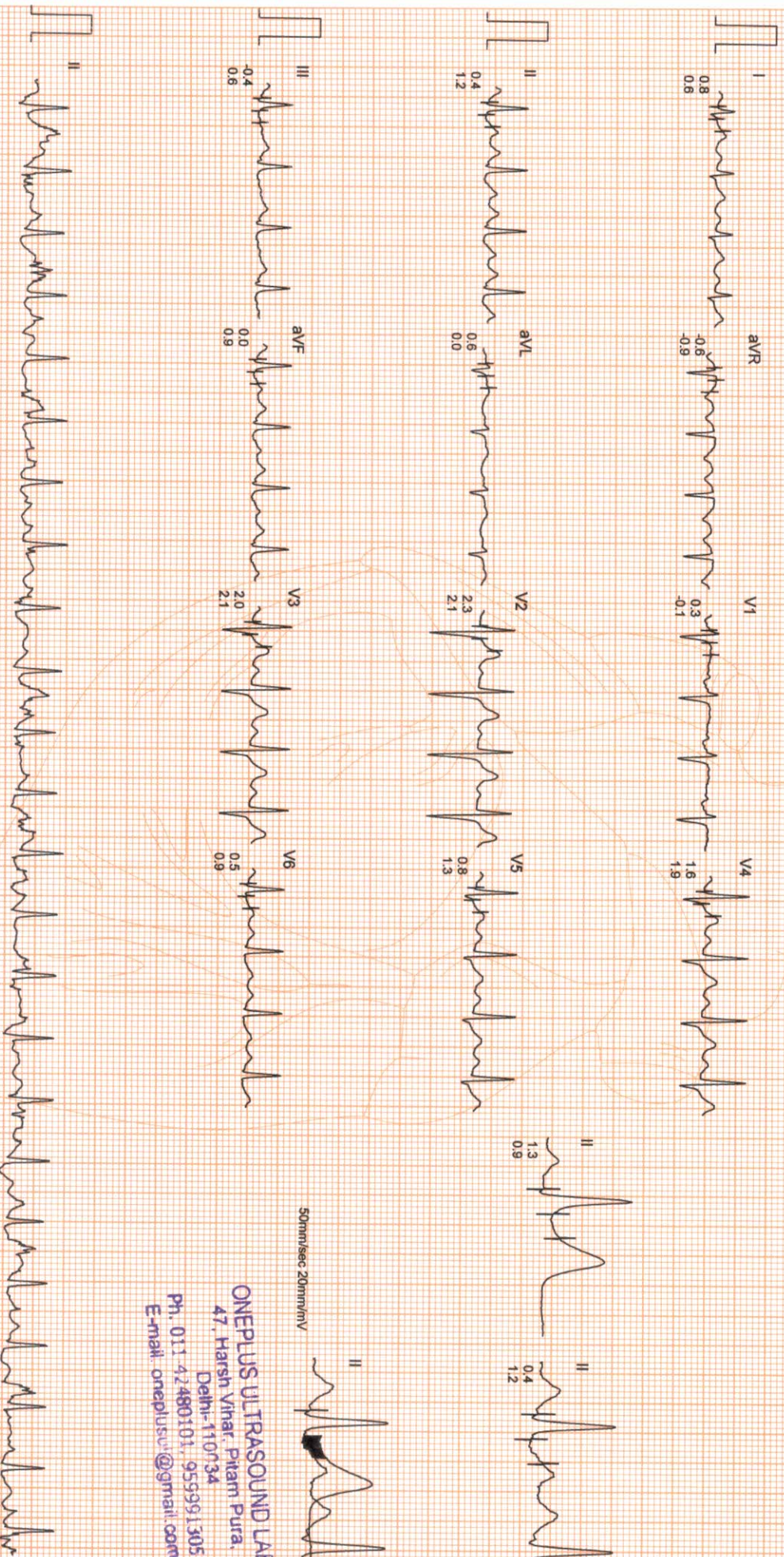
ST @ 10mm/mV

80ms PostJ

SPEED : 5.4 Km./Hr.

GRADE : 14.0 %

LINKED MEDIAN



50mm/sec 20mm/mV

ONEPLUS ULTRASOUND LAB
47, Harsh Vihar, Pitam Pura,
Delhi-110034
Ph. 011 42480101, 9559913051
E-mail: oneplusul@gmail.com

Filtered

Computer Corrected Baseline

25mm/sec 10mm/mV

CardiCom, INDIA Ph.:091-731-2620740, TeleFax:091-731-2431214

MR. UTTAM SINGH BHANDARI

I.D. : 996

AGE/SEX : 56/M

RECORDED : 30-6-2022 10:29

ONEPLUS ULTRASOUND LAB

BRUCE

RECOVERY

PHASE TIME : 2:59

RATE : 83 BPM

B.P. : 130/82 mmHg

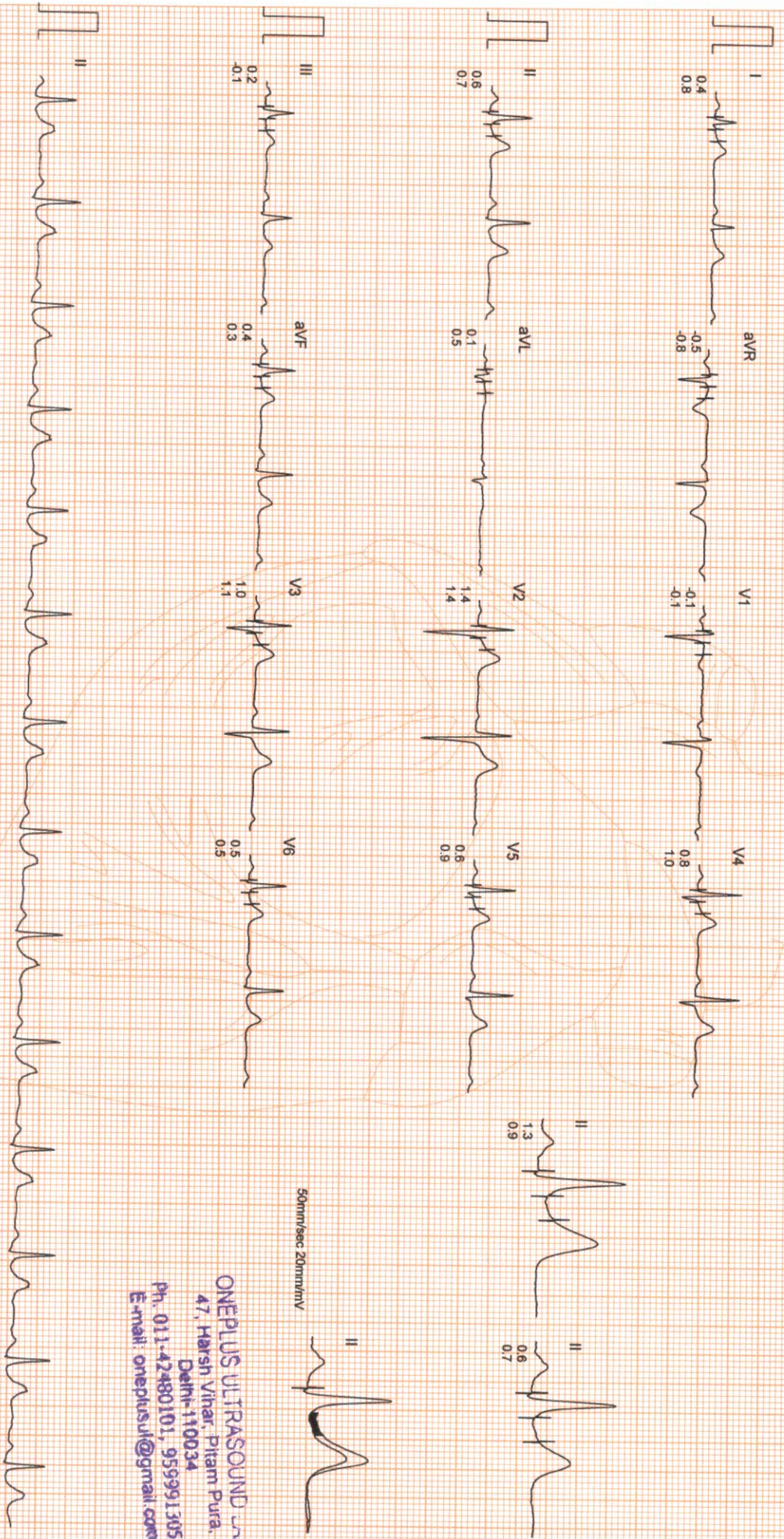
ST @ 10mm/mV

80ms PostI

SPEED : 0.0 Km./Hr.

GRADE : 0.0 %

LINKED MEDIAN



50mm/sec 20mm/mV

ONEPLUS ULTRASOUND
 47, Harsh Vihar, Pitam Pura,
 Delhi-110034
 Ph: 011-42480101, 9599913051
 E-mail: oneplusul@gmail.com

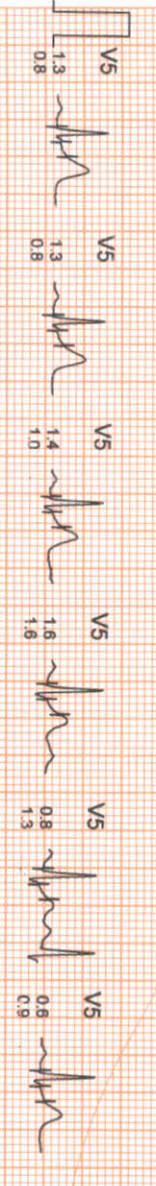
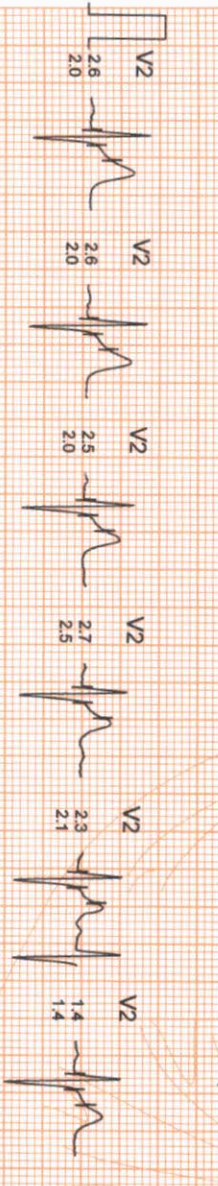
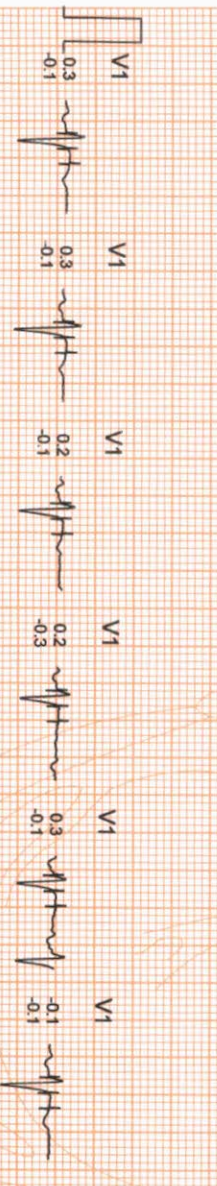
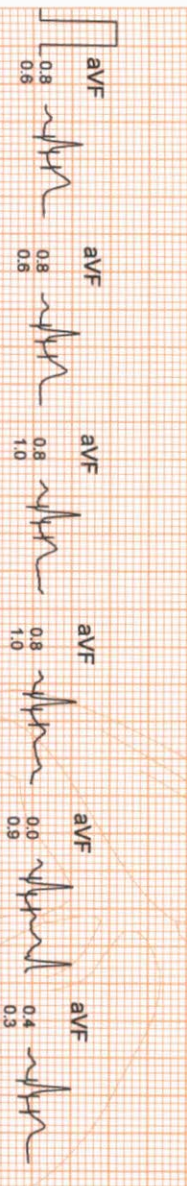
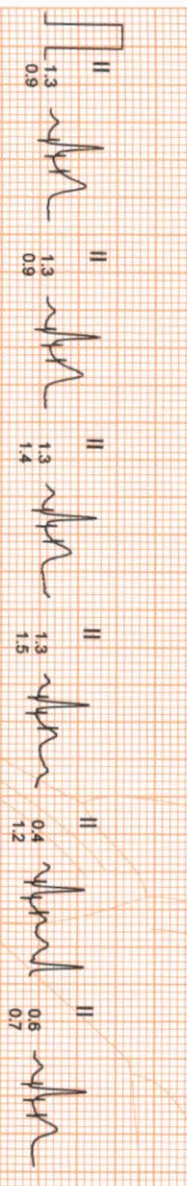
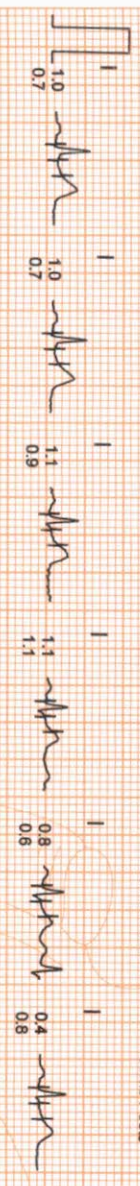
Filtered

Computer Corrected Baseline

25mm/sec 10mm/mV

CardiCom, INDIA Ph.:091-731-2620740, Telefax:091-731-2431214

STANDING	SUPINE	STAGE 1	STAGE 2	PEAK EXERCISE	RECOVERY
0.0Kmph 0.0% 78 bpm B.P. 124/80 80ms PostJ	0.0Kmph 0.0% 79 bpm B.P. 124/80 80ms PostJ	2.59 2.59 2.7Kmph 10.0% 107 bpm B.P. 134/82 80ms PostJ	5:59 2:59 4.0Kmph 12.0% 125 bpm B.P. 146/86 80ms PostJ	6:59 0:59 5.4Kmph 14.0% 145 bpm B.P. 160/90 80ms PostJ	2:59 0.0Kmph 0.0% 83 bpm B.P. 130/82 80ms PostJ



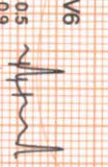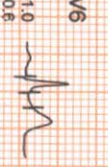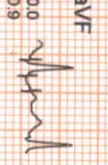
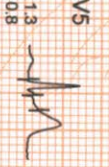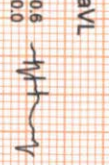

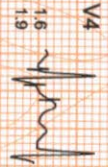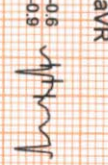

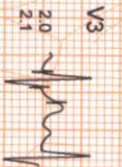
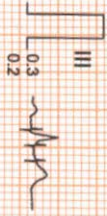
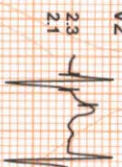
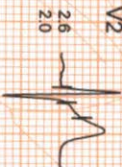
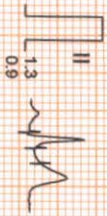
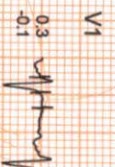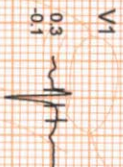
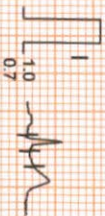
ONEPLUS ULTRASOUND LAB
 47, Harsh Vihar, Pitam Pura,
 Delhi-110034
 Ph. 011-42480101, 9559913051
 E-mail: oneplusul@gmail.com

SUPINE
 PEAK EXERCISE
 6:58
 0.56
 0.0Kmph
 0.0%
 79 bpm
 B.P. 124/80
 80ms PostJ

SUPINE
 PEAK EXERCISE
 6:58
 0.56
 5.4Kmph
 14.0%
 146 bpm
 B.P. 160/90
 80ms PostJ

SUPINE
 PEAK EXERCISE
 6:58
 0.56
 0.0Kmph
 0.0%
 79 bpm
 B.P. 124/80
 80ms PostJ

SUPINE
 PEAK EXERCISE
 6:58
 0.56
 5.4Kmph
 14.0%
 146 bpm
 B.P. 160/90
 80ms PostJ



ONEPLUS ULTRASOUND LAB
 47, Harsh Vihar, Pitam Pura,
 Delhi-110034
 Ph. 011-42480101, 9599913051
 E-mail: oneplus.ii@gmail.com



OnePLUS Ultrasound Lab

QUALITY FIRST... ALWAYS!

Dr. Nitin Agarwal
Pathologist & Director
Ex. Sr. Res. MAMC
& Lok Nayak Hospital
Ex. Chief of Lab Dr. Lal Path Labs.

Dr. Pooja (Garg) Agarwal
Radiologist & Director
MAMC & Lok Nayak Hospital



NAME	:Mr. UTTAM SINGH BHANDARI	Barcode No	:10122357
AGE/GENDER	:56 YRS/Male	SPECIMEN DATE	:30/Jun/2022 09:47AM
PATIENT ID	:97885	SPECIMEN RECEIVED	:30/Jun/2022 10:02AM
REFERRED BY	:Dr. MEDIWHEEL	REPORT DATE	:30/Jun/2022 01:26PM
CENTRE NAME	:ONEPLUS ULTRASOUND LAB	LAB NO.	:012206300012

Test Name	Result	Unit	Ref. Range
-----------	--------	------	------------

HAEMATOLOGY

Health checkup 2 Male

<u>Glycosylated Hemoglobin (HbA1c)</u>	5.3	%	Non Diabetic adults <5.7 Prediabetic (at risk) 5.7-6.4 Diabetes >6.4
--	-----	---	--

<u>Estimated average blood glucose (eag)</u>	105
--	-----

Reference range (mg/dl):

90 - 120:Excellent control, 121 - 150:Good Control, 151 - 180:Average Control, 181 - 210:Action Suggested
>211:Panic value

<u>BLOOD GROUP (ABO)</u>	A
<u>Rh typing</u>	POSITIVE

NOTE :

- * Apart from major A,B,H antigens which are used for ABO grouping and Rh typing, many minor blood group antigens exist. Agglutination may also vary according to titre of antigen and antibody.
- * So before transfusion, reconfirmation of blood group as well as cross-matching is needed.
- * Presence of maternal antibodies in newborns, may interfere with blood grouping.
- * Auto agglutination (due to cold antibody, falciparum malaria, sepsis, internal malignancy etc.) may also cause erroneous result.

CBC

Haemoglobin	11.3	g/dl	13.0-17.0
Total Leucocyte Count	5510	/cumm	4000-10000
<u>Differential leucocyte count</u>			
Neutrophils	61.2	%	40-80
Lymphocyte	29.10	%	20-40
Monocytes	6.70	%	2-10
Eosinophils	2.7	%	1-6
Basophils	0.3	%	0-2
RBC Count	3.49	million/cumm	4.5 - 5.5

Checked By.

DR. NITIN AGARWAL
MBBS, MD (PATHOLOGIST)

47, Harsh Vihar, Pitampura, New Delhi-110034 | Ph.: 011-42480101, 9599913051

E-mail: oneplusul@gmail.com | Web.: www.oneplusul.in



OnePLUS Ultrasound Lab

QUALITY FIRST... ALWAYS!

Dr. Nitin Agarwal
Pathologist & Director
Ex. Sr. Res. MAMC
& Lok Nayak Hospital
Ex. Chief of Lab Dr. Lal Path Labs.

Dr. Pooja (Garg) Agarwal
Radiologist & Director
MAMC & Lok Nayak Hospital



NAME	:Mr. UTTAM SINGH BHANDARI	Barcode No	:10122357
AGE/GENDER	:56 YRS/Male	SPECIMEN DATE	:30/Jun/2022 09:47AM
PATIENT ID	:97885	SPECIMEN RECEIVED	:30/Jun/2022 10:02AM
REFERRED BY	:Dr. MEDIWHEEL	REPORT DATE	:30/Jun/2022 01:26PM
CENTRE NAME	:ONEPLUS ULTRASOUND LAB	LAB NO.	:012206300012

Test Name	Result	Unit	Ref. Range
PCV(Hematocrit)	35.3	%	40-50
MCV	101.1	fL	83-101
MCH	32.3	Pg	27-32
MCHC	31.9	G/dL	32-35
Platelet count	152000	/cumm	150000-450000
RDW-CV	13.4	%	11.4-14.0
ESR(WESTEGRENs METHOD)	16	mm in 1st hr	0-20
<u>BIOCHEMISTRY</u>			
<u>Blood sugar fasting</u>	102	mg/dL	70-110

Checked By.

Dr. NITIN AGARWAL
MBBS, MD (Path)
DMC/R/01436
DR. NITIN AGARWAL
MBBS, MD (PATHOLOGIST)

47, Harsh Vihar, Pitampura, New Delhi-110034 | Ph.: 011-42480101, 9599913051
E-mail: oneplusul@gmail.com | Web.: www.oneplusul.in

Page 2 of 7

Clinical correlation is essential for final diagnosis. • If test results are unsatisfactory please contact personally or on phone. • This report is for perusal of doctors only.
• All disputes Subject to Delhi Jurisdiction only. • Not for medicolegal purposes. • All congenital anomalies in a foetus may not be diagnosed in routine obstetric ultrasound.



OnePLUS Ultrasound Lab

QUALITY FIRST... ALWAYS!

Dr. Nitin Agarwal
Pathologist & Director
Ex. Sr. Res. MAMC
& Lok Nayak Hospital
Ex. Chief of Lab Dr. Lal Path Labs.

Dr. Pooja (Garg) Agarwal
Radiologist & Director
MAMC & Lok Nayak Hospital



NAME	:Mr. UTTAM SINGH BHANDARI	Barcode No	:10122357
AGE/GENDER	:56 YRS/Male	SPECIMEN DATE	:30/Jun/2022 09:47AM
PATIENT ID	:97885	SPECIMEN RECEIVED	:30/Jun/2022 01:47PM
REFERRED BY	:Dr. MEDIWHEEL	REPORT DATE	:30/Jun/2022 02:46PM
CENTRE NAME	:ONEPLUS ULTRASOUND LAB	LAB NO.	:012206300012

Test Name	Result	Unit	Ref. Range
BIOCHEMISTRY			
<u>Blood sugar pp</u>	149	mg/dL	70.0-140.0

Checked By.

Dr. NITIN AGARWAL 
MBBS, MD (Path)
DMC/R/01436
MBBS, MD (PATHOLOGIST)

47, Harsh Vihar, Pitampura, New Delhi-110034 | Ph.: 011-42480101, 9599913051
E-mail: oneplusul@gmail.com | Web.: www.oneplusul.in



OnePLUS

Ultrasound Lab

QUALITY FIRST... ALWAYS!

Dr. Nitin Agarwal
Pathologist & Director
Ex. Sr. Res. MAMC
& Lok Nayak Hospital
Ex. Chief of Lab Dr. Lal Path Labs.

Dr. Pooja (Garg) Agarwal
Radiologist & Director
MAMC & Lok Nayak Hospital



NAME	:Mr. UTTAM SINGH BHANDARI	Barcode No	:10122357
AGE/GENDER	:56 YRS/Male	SPECIMEN DATE	:30/Jun/2022 09:47AM
PATIENT ID	:97885	SPECIMEN RECEIVED	:30/Jun/2022 12:08PM
REFERRED BY	:Dr. MEDIWHEEL	REPORT DATE	:30/Jun/2022 01:26PM
CENTRE NAME	:ONEPLUS ULTRASOUND LAB	LAB NO.	:012206300012

Test Name	Result	Unit	Ref. Range
-----------	--------	------	------------

BIOCHEMISTRY

<u>Bun (blood urea nitrogen)</u>	12.60	mg/dl	8.4-25.7
<u>Uric acid, serum</u>	4.2	mg/dl	3.4-7.0
<u>Creatinine, serum</u>	1.1	mg/dl	0.60-1.1

LFT(LIVER FUNCTION TEST)


Bilirubin Total	0.65	mg/dl	0.1-1.2
Bilirubin Conjugated	0.24	mg/dl	0-0.4
Bilirubin Unconjugated	0.41	mg/dl	up to 0.7
SGOT (AST)	28	U/L	0-35
SGPT (ALT)	23	U/L	<45.0
Alkaline phosphatase	95	U/L	40-129
Gamma glutamyl transpeptidase	27	U/L	<66
Total Protein	6.7	gm/dl	6.60 - 8.70
Albumin serum	3.8	g/dL	3.8-5.1
Globulin	2.90	gm/dl	1.8-3.4
Albumin/Globulin Ratio	1.31		1.10 - 2.50

LIPID PROFILE

Cholesterol	146	mg/dl	50-240
Triglycerides	173	mg/dL	25-150
HDL Cholesterol	48	mg/dL	30-70
LDL cholesterol	63	mg/dL	<130
VLDL cholesterol	34.6	mg/dL	5-40
Cholesterol/HDL Ratio	3.0		Low Risk 3.3-4.97 Average Risk 4.4-7.1 Moderate Risk 7.1-11.0 High Risk >11.0
LDL/HDL Ratio	1.3		0 - 3.55

According to ATP III and NCEP guidelines

Checked By.

Dr NITIN AGARWAL
M B B S , MD (Path)
DMC/R/01436

DR. NITIN AGARWAL
MBBS,MD(PATHOLOGIST)

47, Harsh Vihar, Pitampura, New Delhi-110034 | Ph.: 011-42480101, 9599913051

E-mail: oneplusul@gmail.com | Web.: www.oneplusul.in



OnePLUS

Ultrasound Lab

QUALITY FIRST... ALWAYS!

Dr. Nitin Agarwal
Pathologist & Director
Ex. Sr. Res. MAMC
& Lok Nayak Hospital
Ex. Chief of Lab Dr. Lal Path Labs.

Dr. Pooja (Garg) Agarwal
Radiologist & Director
MAMC & Lok Nayak Hospital



NAME	:Mr. UTTAM SINGH BHANDARI	Barcode No	:10122357
AGE/GENDER	:56 YRS/Male	SPECIMEN DATE	:30/Jun/2022 09:47AM
PATIENT ID	:97885	SPECIMEN RECEIVED	:30/Jun/2022 12:08PM
REFERRED BY	:Dr. MEDIWHEEL	REPORT DATE	:30/Jun/2022 01:26PM
CENTRE NAME	:ONEPLUS ULTRASOUND LAB	LAB NO.	:012206300012

Test Name	Result	Unit	Ref. Range	
Parameter	Normal	Desirable	Borderline	High
Total cholesterol	<200	200-239		240
Triglycerides	<150	150-199	200-499	500
LDL	Optimal <100 Near Optimal 100-129	130-159	160-180	190
HDL	<40 : LOW 60 : HIGH			

ENDOCRINOLOGY

PSA TOTAL

Prostatic specific antigen, Total 0.98 ng/ml <4.0

< 40 years	0.21 to 1.72 ng/ml
40 - 49	0.27 to 2.19 ng/ml
50 - 59	0.27 to 3.42 ng/ml
60 - 69	0.22 to 6.16 ng/ml
> 69	0.21 to 6.77 ng/ml

Notes:

PSA is principally produced by the glandular epithelium of the prostate, and is secreted in the seminal fluid. PSA is also present in urine and blood. PSA acts on seminal fluid to fluidify and increase sperm mobility. PSA levels rise in prostatic pathologies such as benign prostatic hyperplasia (BPH) or prostate cancer.

THYROID PROFILE(T3,T4,TSH)

Triiodothyronine total [t3]	0.96	ng/dl	0.52-1.9
Thyroxine total [t4]	7.60	µg/dl	4.4 - 10.8
TSH (Thyroid Stimulating Hormone)	4.10	µIU/ml	0.25-5.0

AGE WISE VARIATION IN TSH

AGE	TSH(µIU/ml)	AGE	TSH(µIU/ml)
-----	-------------	-----	-------------

Checked By.

Dr. NITIN AGARWAL
MBBS, MD (Path)
DMC/R/01436
DR. NITIN AGARWAL
MBBS, MD (PATHOLOGIST)

47, Harsh Vihar, Pitampura, New Delhi-110034 | Ph.: 011-42480101, 9599913051

E-mail: oneplusul@gmail.com | Web.: www.oneplusul.in



OnePLUS

Ultrasound Lab

QUALITY FIRST... ALWAYS!

Dr. Nitin Agarwal
Pathologist & Director
Ex. Sr. Res. MAMC
& Lok Nayak Hospital
Ex. Chief of Lab Dr. Lal Path Labs.

Dr. Pooja (Garg) Agarwal
Radiologist & Director
MAMC & Lok Nayak Hospital



NAME	:Mr. UTTAM SINGH BHANDARI	Barcode No	:10122357
AGE/GENDER	:56 YRS/Male	SPECIMEN DATE	:30/Jun/2022 09:47AM
PATIENT ID	:97885	SPECIMEN RECEIVED	:30/Jun/2022 12:08PM
REFERRED BY	:Dr. MEDIWHEEL	REPORT DATE	:30/Jun/2022 01:26PM
CENTRE NAME	:ONEPLUS ULTRASOUND LAB	LAB NO.	:012206300012

Test Name	Result	Unit	Ref. Range
1-4 weeks	1.00 - 19.0	16-20 yrs	0.25 - 5.0
1-12 mths	1.70 - 9.1	21 - 80 yrs	0.25 - 5.0
1-5 yrs	0.80 - 8.2	I st trimester	0.25 - 5.0
6-10 yrs	0.25 - 5.0	II nd trimester	0.50 - 5.0
11-15 yrs	0.25 - 5.0	III rd trimester	0.4 - 6.0

Reference ranges - Interpretation of Diagnostic tests - (Jacques Wallach)

1. Primary hypothyroidism is accompanied by depressed serum T3 and T4 values and elevated serum TSH level.
2. Primary hyperthyroidism is accompanied by elevated serum T3 and T4 levels along with depressed TSH values.
3. Slightly elevated T3 levels may be found in pregnancy and estrogen therapy, while depressed levels may be encountered in severe illness, renal failure and during therapy with drugs like propranolol and propyl thiouracil.
4. Although elevated TSH levels are nearly always indicative of primary hypothyroidism, and may be seen in secondary thyrotoxicosis

CLINICAL PATHOLOGY

URINE ROUTINE

Physical examination

Quantity	30	ML
Colour	PALE YELLOW	
Transparency	CLEAR	CLEAR
Sp.gravity	1.015	1.010-1.030
pH	6.00	
Reaction	ACIDIC	ACIDIC

Chemical examination

Urine protein	NIL	NIL
Urine sugar	NIL	NIL
Bilirubin, urine	NEGATIVE	NEGATIVE
Urobilinogen	NORMAL	NORMAL
Ketones	NEGATIVE	NEGATIVE

Microscopic examination

Pus cells.	1-2	/HPF	0-2
------------	-----	------	-----

Checked By.

Dr NITIN AGARWAL
M B B S , MD (Path)
DMC/R/01436
DR. NITIN AGARWAL
MBBS,MD(PATHOLOGIST)

47, Harsh Vihar, Pitampura, New Delhi-110034 | Ph.: 011-42480101, 9599913051 :

E-mail: oneplusul@gmail.com | Web.: www.oneplusul.in



OnePLUS

Ultrasound Lab

QUALITY FIRST... ALWAYS!

Dr. Nitin Agarwal
Pathologist & Director
Ex. Sr. Res. MAMC
& Lok Nayak Hospital
Ex. Chief of Lab Dr. Lal Path Labs.

Dr. Pooja (Garg) Agarwal
Radiologist & Director
MAMC & Lok Nayak Hospital



NAME	:Mr. UTTAM SINGH BHANDARI	Barcode No	:10122357
AGE/GENDER	:56 YRS/Male	SPECIMEN DATE	:30/Jun/2022 09:47AM
PATIENT ID	:97885	SPECIMEN RECEIVED	:30/Jun/2022 12:08PM
REFERRED BY	:Dr. MEDIWHEEL	REPORT DATE	:30/Jun/2022 01:26PM
CENTRE NAME	:ONEPLUS ULTRASOUND LAB	LAB NO.	:012206300012

Test Name	Result	Unit	Ref. Range
Epithelial cells	0-1	/HPF	NIL
R.B.C.	NIL	/HPF	NIL
Casts	NIL	/HPF	NIL
Crystals	NIL	/HPF	NIL
Bacteria	NIL	/HPF	NIL
Others.	NIL	NIL	NIL

STOOL ROUTINE

Physical examination

Colour	BROWNISH		
Consistency	SEMI LOOSE		Semi Formed
Blood	ABSENT		Absent
Mucus	ABSENT		Absent

Chemical examination, stool

pH	6.00		
----	------	--	--

Microscopic examination

Pus cells	NIL	/HPF	
Red blood cells	NIL	/HPF	NIL
Ova	NIL		NIL
Cysts	NIL		NIL
Bacteria	PRESENT	/HPF	NIL
Others	NIL		

*** End Of Report ***

Checked By.

Dr NITIN AGARWAL
MBBS, MD (Pathology)
DMC/R/01436
NITIN AGARWAL
MBBS,MD(PATHOLOGIST)

47, Harsh Vihar, Pitampura, New Delhi-110034 | Ph.: 011-42480101, 9599913051
E-mail: oneplusul@gmail.com | Web.: www.oneplusul.in



OnePLUS
Ultrasound Lab

— QUALITY FIRST... ALWAYS! —

Dr. Nitin Agarwal

Pathologist & Director
Ex. Sr. Res. MAMC
& Lok Nayak Hospital
Ex. Chief of Lab Dr. Lal Path Labs.

Dr. Pooja (Garg) Agarwal

Radiologist & Director
MAMC & Lok Nayak Hospital

Name	: Mr. UTTAM SINGH BHANDARI	Age/Sex	: 56 YRS/Male
Ref. By	: Dr. MEDIWHEEL	Lab No	: 012206300012
Date	: 30-Jun-2022	Patient ID	: LSHHI97885

ULTRASOUND EXAMINATION----WHOLE ABDOMEN

Liver is normal in size (14.4 cm) and outline **with altered echopattern. Diffuse increase in echogenicity of liver parenchyma is noted, suggestive of fatty infiltration (grade I).** No abscess or mass lesion seen. Hepatic veins, portal vein, IVC and aorta are normal. Intrahepatic biliary radicles are not dilated. CBD is normal in caliber.

Gall bladder is well distended with anechoic lumen. Wall thickness is normal.

Both kidneys are normal in size, shape, position, outline and echopattern. Corticomedullary differentiation is maintained. No pelvicalyceal dilation or calculus or mass lesion is seen.

Spleen is normal in size and echotexture. No mass lesion seen.

Pancreas is normal in size, outline and echotexture.

Urinary bladder is normal in shape and position. No evidence of intravesical stone or mass seen.

Prostate is normal in size, shape and echopattern.

Prostate measures 3.6 x 2.3 x 1.9 cm. Weight of prostate is 8.5 grams.

No abnormal bowel wall thickening seen in right iliac fossa.

No mass or free fluid seen anywhere in abdomen.

IMPRESSION: Fatty infiltration of liver (grade I) with no hepatomegaly.

DR. POOJA GARG
RADIOLOGIST
REG NO- DMC/R/03398

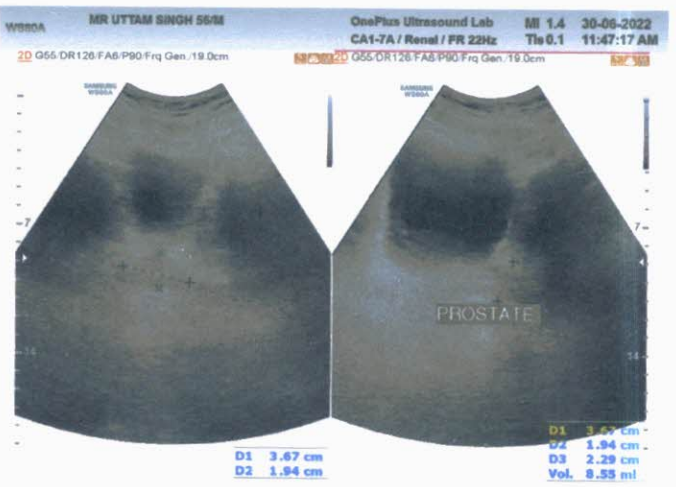
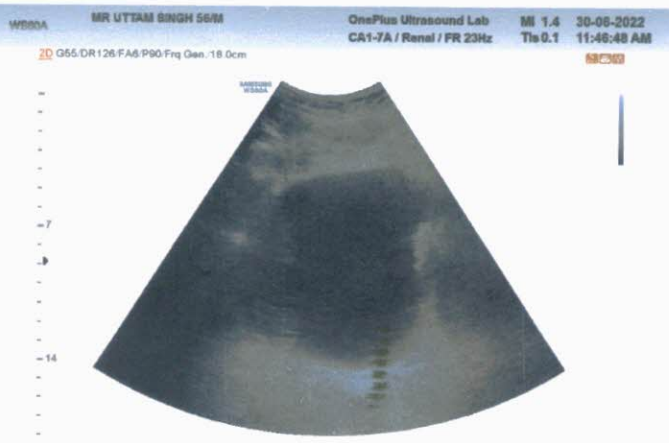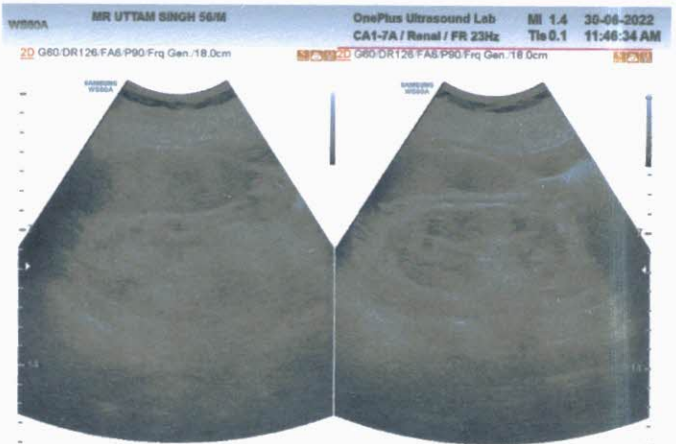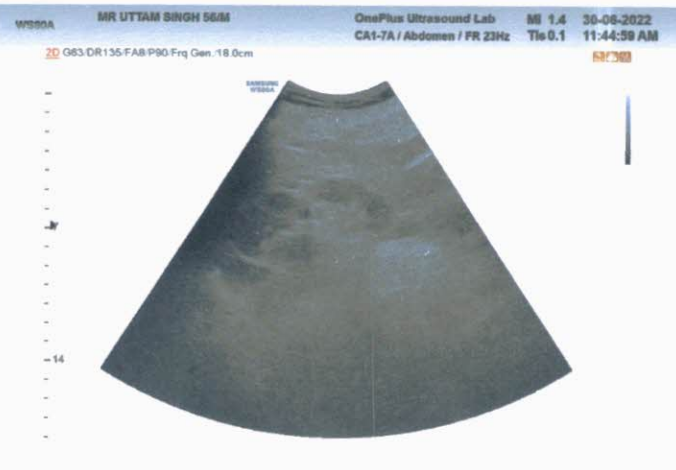
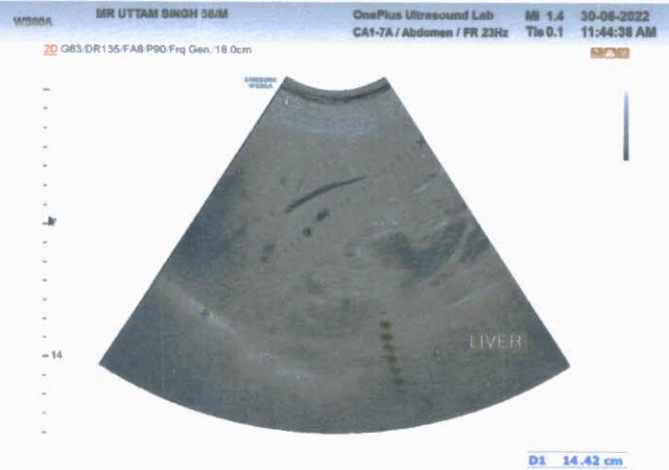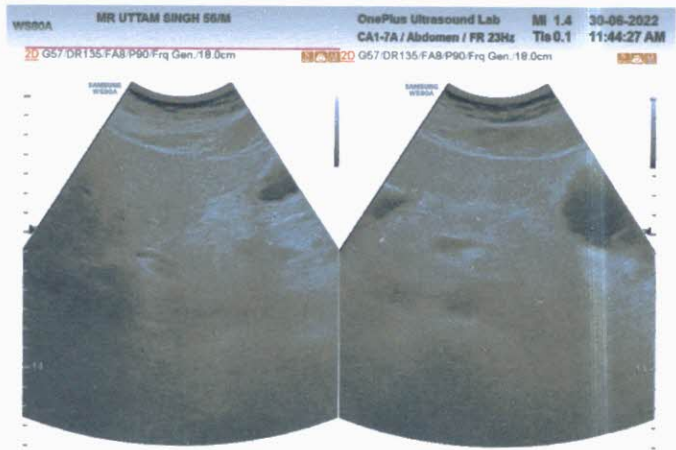
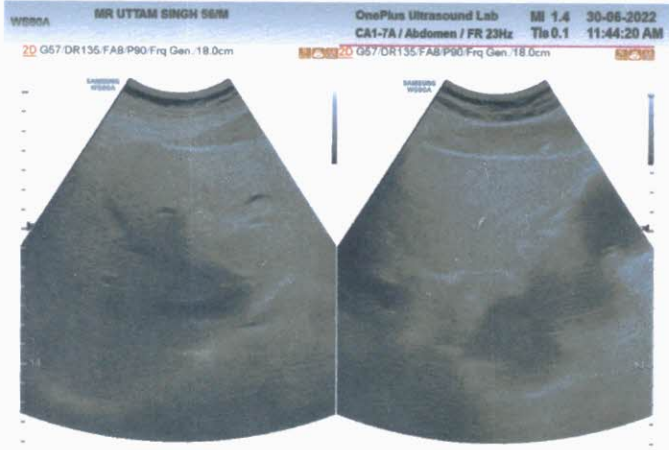
Dr. POOJA GARG
M.B.B.S., D.M.R.D
Reg No. DMC/R/03398
Radiologist

Type By : DARSHITA

47, Harsh Vihar, Pitampura, New Delhi-110034 | Ph.: 011-42480101, 9599913051

E-mail: oneplusul@gmail.com | Web.: www.oneplusul.in

Clinical correlation is essential for final diagnosis. • If test results are unsatisfactory please contact personally or on phone. • This report is for perusal of doctors only.
• All disputes Subject to Delhi Jurisdiction only. • Not for medicolegal purposes. • All congenital anomalies in a foetus may not be diagnosed in routine obstetric ultrasound.





OnePLUS
Ultrasound Lab

— QUALITY FIRST... ALWAYS! —

Dr. Nitin Agarwal

Pathologist & Director
Ex. Sr. Res. MAMC
& Lok Nayak Hospital
Ex. Chief of Lab Dr. Lal Path Labs.

Dr. Pooja (Garg) Agarwal

Radiologist & Director
MAMC & Lok Nayak Hospital

Name	: Mr. UTTAM SINGH BHANDARI	Age/Sex	: 56 YRS/Male
Ref. By	: Dr. MEDIWHEEL	Lab No	: 012206300012
Date	: 30-Jun-2022	Patient ID	: LSHHI97885

X-ray-Chest PA view

Bony cage and soft tissues are normal.

Cardiomegaly is present.

Mediastinum is normal.


Both hila are normal.

Both costophrenic angles are clear.

Both domes of diaphragm are normal.

Pulmonary vascular markings are prominent. Fibroatelectatic opacity is seen in left lower zone. No other parenchymal lesion seen.

Please correlate clinically


DR. POOJA GARG
RADIOLOGIST
REG NO- DMC/R/03398

DR. POOJA GARG
M.B.B.S., D.M.R.D
Reg No DMC/R/03398

Type By : DARSHITA

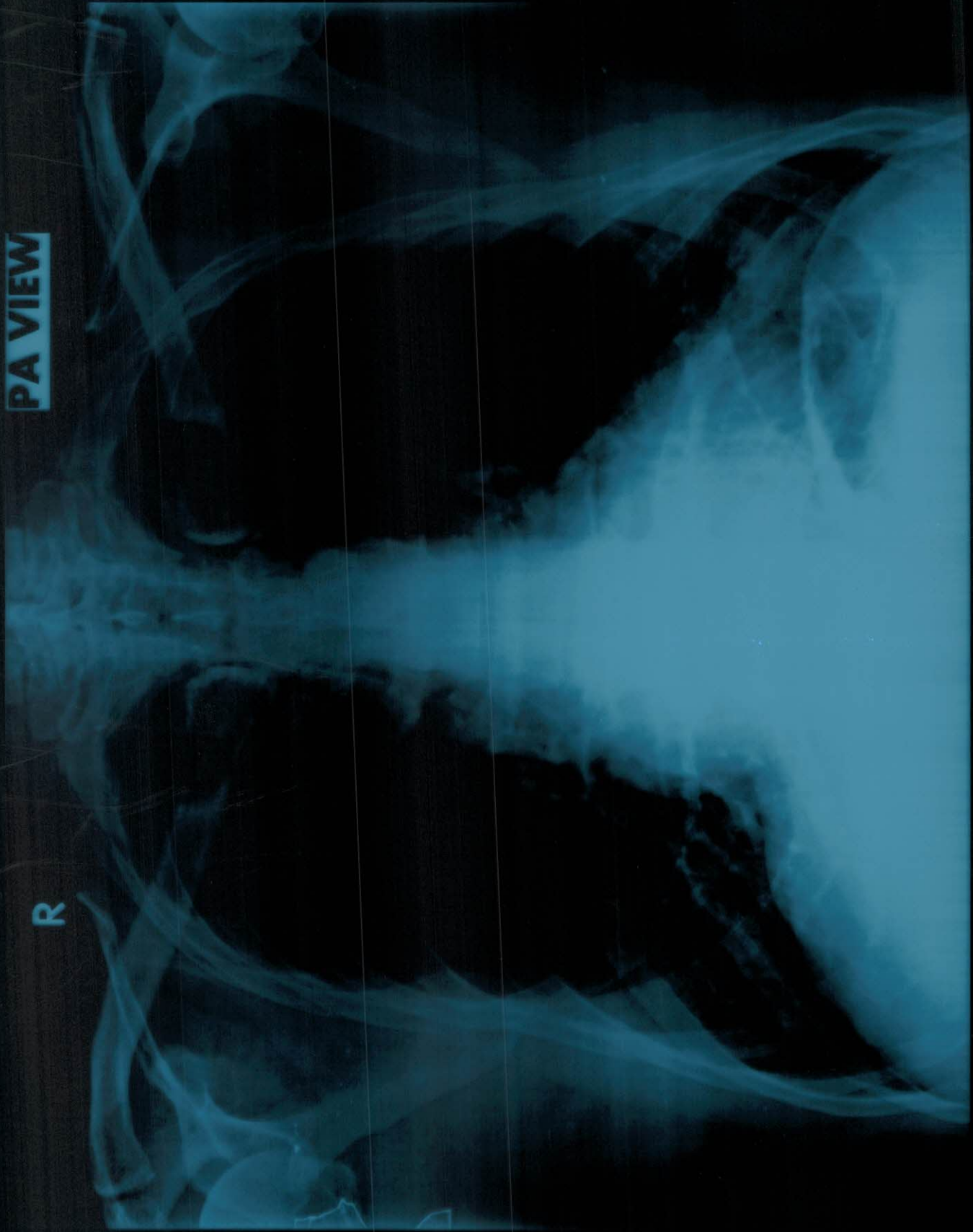
47, Harsh Vihar, Pitampura, New Delhi-110034 | Ph.: 011-42480101, 9599913051

E-mail: oneplusul@gmail.com | Web.: www.oneplusul.in

Clinical correlation is essential for final diagnosis. • If test results are unsatisfactory please contact personally or on phone. • This report is for perusal of doctors only.
• All disputes Subject to Delhi Jurisdiction only. • Not for medicolegal purposes. • All congenital anomalies in a foetus may not be diagnosed in routine obstetric ultrasound.

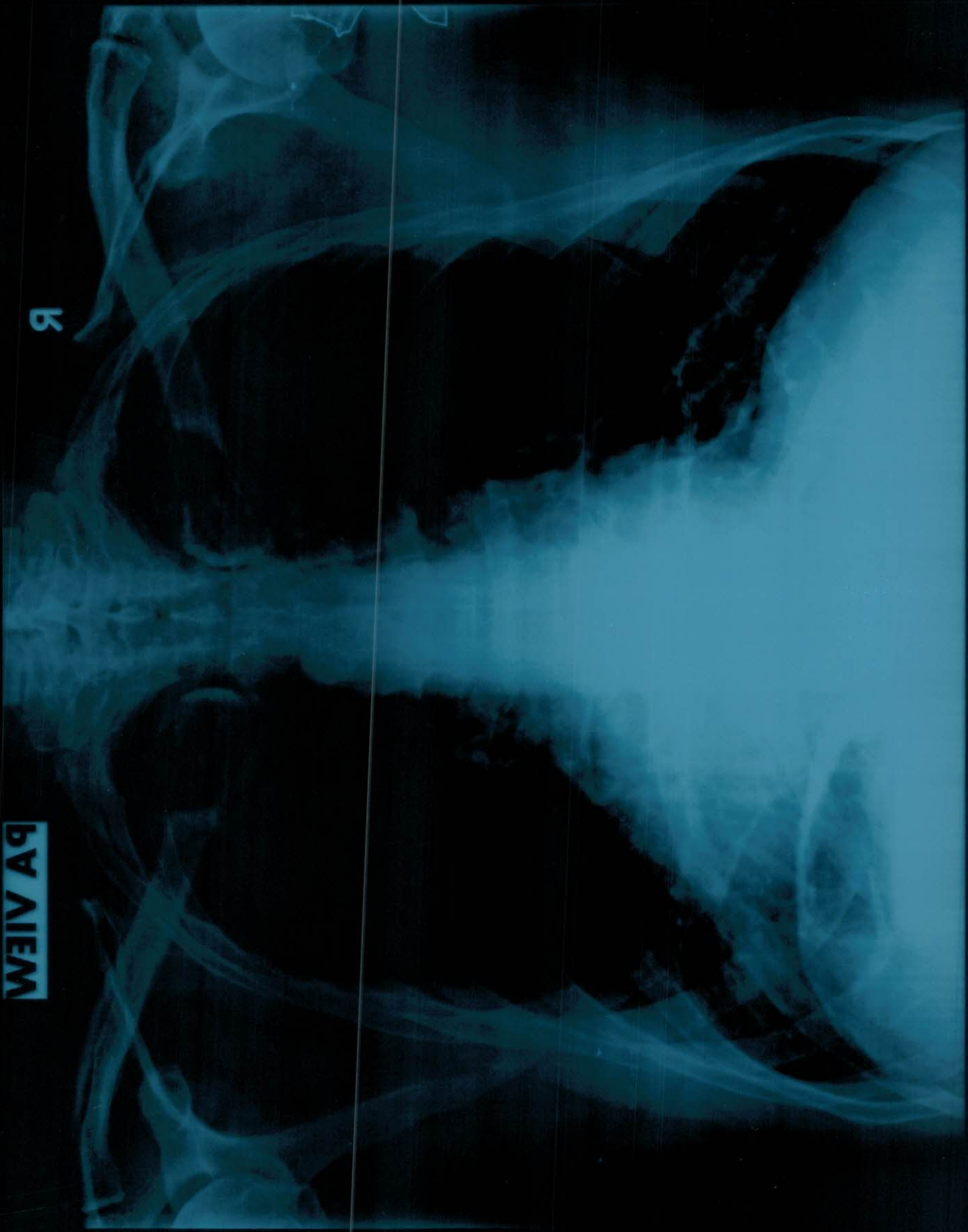
R

PA VIEW



MR UTTAM SINGH BHANDARI AGE 56 YRS 30-06-2022 M CHEST PA VIEW
ONEPLUS ULTRASOUND LAB, 47-HARSH VIHAR, PITAMPURA

ONEPLUS ULTRASOUND LAB, 41-HARSH NIHAR, PITAMPURA
MR UTTAM SINGH BHANDARI AGE 28 YRS 30-08-2025 M CHEST PA VIEW



R

PA VIEW