

Mr. - Santosh Ku. Panda
Age: - 46y/m

BP: - 130/80
P: - 80mm
H: - 165 cm
Wt: - 67 kg
BMI: - 24.6

Case for Postural changes
kalelo immo. on 7/14

User shows Inequality
cl. Abd. fulcrum

Advice
① Tab. Ranprax-50 1-0 x today

Continue Anti immo

Ankit
Dr. Ankit Sharma
MD Medicine
Reg. No. - CGMC 7971/2018
Apollo Clinic, Raipur



Dr. Sweety Lath

BDS (Cosmetic Dental Surgeon)



Dr. Vivek Lath

Chief Dental Consultant
BDS, MDS, Diplomate (WCOI, Japan)
Professor, MCDRC - Durg
Reg. No. CGDC/14/PG/45

- Consult for : Digital Dentistry • Fixed Teeth • RCT • Dental Implants • Gums Diseases • Dentures • Cosmetic Filling • Tooth Jewellery
- Digital OPG • Braces Treatment • Tooth Removal • Kids Dental Treatment • All Kind of Dental Surgeries

Mr. Santosh Kumar Panda .

25/3/2023

46/M.

C/c. - 11 sample came for routine dental checkup.

Sp

Distal + Cal +

Distal Caries

2/

Ad

Subul =

2/

Signature



Apollo Clinic

LICENSEE : SAMRIDDHI AROGYAM PVT. LTD.

Apollo Clinic @ Tiara Complex A.T. Classic Near Ashoka Ratan, VIP Estate, Raipur (C.G.)

Email : raipur1@apolloclinic.com

Online appointments: www.askapollo.com | Online reports: https://phr.apolloclinic.com

X-ray - 200

0771 4033341/42

+91 9691826363

www.apolloclinic.com

Patient Name : Mr. Santosh Kumar Panda
Age/Sex : 46 Y/M
Pres Doctor :
Ref.by : Bank of Baroda

MR No : FRAI.0000027260
Visit No : FRAIOPV49656
Bill Date : 25-03-2023 01:52
Report Date : 26-03-2023 10:50

CHEST X - RAY PA VIEW

FINDINGS:

- Both the domes of diaphragm and CP angles are normal.
- Both the hila and mediastinum are normal.
- Both the lung fields are clear. No e/o focal parenchymal lesion.
- Cardio-thoracic ratio is normal.
- Soft tissues and bony cage are unremarkable.

IMPRESSION:

- NO SIGNIFICANT ABNORMALITY SEEN.

Advised: Clinical correlation and further evaluation if clinically indicated.

Dr. Zeeshan Ateeb Dani
MBBS, MD
DR. ZEESHAN ATEEB DANI
Reg. No. CGMC-~~MBBS/MD~~
RADIOLOGIST

Technician



Patient Name : Mr. Santosh Kumar Panda
UHID/MR No. : FRAI.0000027260
Visit Date : 25-03-2023 13:52
Sample Collected on : 26-03-2023 09:13
Ref Doctor : Bank of Baroda
Emp/Auth/TPA ID : 4564536
Sponsor Name : MEDIWHEEL PVT LTD

Age / Gender : 46Y/Male
OP Visit No : FRAIOPV49656
Reported on : 27-03-2023 13:56
Specimen : Whole Blood (Edta)
Pres Doctor: :

DEPARTMENT OF LABORATORY MEDICINE

| TEST NAME | RESULT | BIOLOGICAL REFERENCE INTERVALS | UNITS |
|-----------------------------|--------|--------------------------------|--------------|
| COMPLETE BLOOD COUNT | | | |
| HAEMOGLOBIN | 14.7 | 13.0 - 17.2 | gm% |
| Method: CELL COUNTER | | | |
| RBC COUNT | 4.92 | 3.5 - 5.5 | million/cumm |
| Method: CELL COUNTER | | | |
| HEMATOCRIT(PCV) | 44.1 | 37 - 50 | % |
| Method: CELL COUNTER | | | |
| MCV | 89.6 | 76 - 96 | fl |
| Method: CELL COUNTER | | | |
| MCH | 29.8 | 27 - 32 | pg |
| Method: CELL COUNTER | | | |
| MCHC | 33.3 | 31 - 35 | gm/dl |
| Method: CELL COUNTER | | | |
| RDW | 13.0 | 12 - 15.10 | % |
| Method: CELL COUNTER | | | |
| TOTAL WBC COUNT | 11.29* | 4 - 11 | thous/cumm |
| Method: CELL COUNTER | | | |
| NEUTROPHIL | 51 | 40 - 75 | % |
| Method: CELL COUNTER | | | |
| LYMPHOCYTE | 40 | 20 - 40 | % |
| Method: CELL COUNTER | | | |
| EOSINOPHIL | 02 | 01 - 06 | % |
| Method: CELL COUNTER | | | |
| MONOCYTE | 07 | 02 - 08 | % |
| Method: CELL COUNTER | | | |
| BASOPHIL | 00 | 00 - 01 | % |
| Method: CELL COUNTER | | | |
| PLATELET COUNT | 258 | 150 - 450 | lacs/cumm |
| Method: CELL COUNTER | | | |
| ESR | 20 | 00 - 20 | mm/hr |
| Method: CELL COUNTER | | | |

End of the report

*THIS PAPER IS USED FOR CLINICAL REPORTING PURPOSE ONLY
 Results are to be correlated clinically

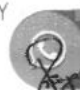
Apollo Clinic

LICENSEE : SAMRIDDI AROGYAM PVT. LTD.

Apollo Clinic @ Tera Complex A.T. Glassic Near Ashoka Ratan, VIP Estate, Shankar Nagar, Raipur (C.G.)

Email: RITU_JANGDE@apolloclinic.com | Website: www.apolloclinic.com

Online appointments: www.askapollo.com | Online reports: <https://pdr.apolloclinic.com>

+91 96918 26363

Dr. PRIYANKA R SAHAI
M.B.B.S. MD 171 4033341/42
PATHOLOGIST

Patient Name : Mr. Santosh Kumar Panda
 UHID/MR No. : FRAI.0000027260
 Visit Date : 25-03-2023 13:52
 Sample Collected on : 26-03-2023 09:13
 Ref Doctor : Bank of Baroda
 Emp/Auth/TPA ID : 4564536
 Sponsor Name : MEDIWHEEL PVT LTD

Age / Gender : 46Y/Male
 OP Visit No : FRAIOPV49656
 Reported on : 27-03-2023 13:56
 Specimen : EDTA Blood
 Pres Doctor: :


DEPARTMENT OF LABORATORY MEDICINE

| TEST NAME | RESULT | BIOLOGICAL REFERENCE INTERVALS | UNITS |
|---|----------|---|-------|
| BLOOD GROUP AND RH TYPE | | | |
| BLOOD GROUP Method: Slide Test | O | A, B, O, AB | |
| RH: | Positive | POSITIVE, NEGATIVE | |
| TEST NAME | RESULT | BIOLOGICAL REFERENCE INTERVALS | UNITS |
| GLUCOSE - (FASTING) | | | |
| GLUCOSE - (FASTING) Method: REAGENT GRADE WATER | 84.0 | 60 - 120 | mg/dl |
| GLUCOSE - (POST PRANDIAL) | | | |
| GLUCOSE - (POST PRANDIAL) Method: REAGENT GRADE WATER | 118.0 | 70 - 140 | mg/dl |
| KFT - RENAL PROFILE-SERUM | | | |
| BUN : Method: Spectrophotometric | 12 | 7 - 20 | mg/dL |
| Creatinine . Method: Jaffe | 1.0 | 0.6 - 1.2 | mg/dL |
| Uric Acid Method: Enzymatic | 3.96 | 2.6 - 7.2 | mg/dL |
| GLYCOSYLATED HEMOGLOBIN (HBA1C) | | | |
| GLYCOSYLATED HEMOGLOBIN (HBA1C) - WHOLE BLOOD.. Method: TURBIDOMETRY | 5.6 | Non-diabetic: <= 5.6 Pre-diabetic: 5.7 - 6.4 Diabetic: >= 6.5 | % |

End of the report

Results are to be correlated clinically

Lab Technician / Technologist
RITU_JANGDE


 Dr. PRIYANKA R SAHAI
 M.B.B.S, MD
 PATHOLOGIST

Apollo Clinic

LICENSEE : SAMRIDDHI AROGYAM PVT. LTD.

Apollo Clinic @ Tiara Complex A.T. Classic Near Ashoka Ratan, VIP Estate, Shankar Nagar, Raipur (C.G.)

Email : raipur1@apolloclinic.com | Website : www.apolloclinic.com

Online appointments: www.askapollo.com | Online reports: https://phr.apolloclinic.com

*THIS PAPER IS USED FOR CLINICAL REPORTING PURPOSE ONLY

 +91 96918 26363

 0771 4033341/42

Patient Name : Mr. Santosh Kumar Panda
UHID/MR No. : FRAI.0000027260
Visit Date : 25-03-2023 13:52
Sample Collected on : 26-03-2023 09:13
Ref Doctor : Bank of Baroda
Emp/Auth/TPA ID : 4564536
Sponsor Name : MEDIWHEEL PVT LTD

Age / Gender : 46Y/Male
OP Visit No : FRAIOPV49656
Reported on : 27-03-2023 13:56
Specimen : Serum
Pres Doctor: :


DEPARTMENT OF LABORATORY MEDICINE

| TEST NAME | RESULT | BIOLOGICAL REFERENCE INTERVALS | UNITS |
|--|--------|--------------------------------|-------|
| LFT WITH GGT | | | |
| TOTAL BILIRUBIN (DPD) Method: Enzymatic | 0.8 | 0.1 - 1.2 | mg/dl |
| DIRECT BILIRUBIN (DPD) Method: Spectrophotometric | 0.2 | 0.05 - 0.3 | mg/dl |
| INDIRECT BILLIRUBIN Method: Spectrophotometric | 0.6 | 0.1 - 1 | mg/dl |
| SGPT/ALT (IFCC) Method: Enzymatic | 29 | 6 - 40 | U/L |
| SGOT/AST (IFCC) Method: Enzymatic | 25 | 6 - 32 | U/L |
| S.ALKALINE PHOSPHATASE Method: Spectrophotometric | 86 | 25 - 147 | IU/L |
| GGT (IFCC) Method: Spectrophotometric | 62 | 5 - 80 | U/L |
| TOTAL PROTEIN (BIURET) Method: Spectrophotometric | 6.8 | 6 - 8 | g/dl |
| ALBUMIN (BCG) Method: Spectrophotometric | 4.4 | 3.5 - 5.0 | g/dl |
| S.GLOBULIN Method: Spectrophotometric | 2.4 | 1.5 - 3.6 | g/dl |
| S.A/G RATIO Method: Spectrophotometric | 1.83 | | |

End of the report

Results are to be correlated clinically

Lab Technician / Technologist
RITU_JANGDE


Dr. PRIYANKA R SAHAI
M.B.B.S, MD
PATHOLOGIST

Patient Name : Mr. Santosh Kumar Panda
UHID/MR No. : FRAI.0000027260
Visit Date : 25-03-2023 13:52
Sample Collected on : 26-03-2023 09:13
Ref Doctor : Bank of Baroda
Emp/Auth/TPA ID : 4564536
Sponsor Name : MEDIWHEEL PVT LTD

Age / Gender : 46Y/Male
OP Visit No : FRAIOPV49656
Reported on : 27-03-2023 13:56
Specimen : Serum
Pres Doctor: :


DEPARTMENT OF LABORATORY MEDICINE

| TEST NAME | RESULT | BIOLOGICAL REFERENCE INTERVALS | UNITS |
|---|--------|--------------------------------|-------|
| LIPID PROFILE TEST (PACKAGE) | | | |
| Total Cholesterol Method: Spectrophotometric | 135.0 | 00 - 200 | mg/dl |
| Triglyceride Method: Spectrophotometric | 98.0 | 60 - 150 | mg/dl |
| HDL Method: Spectrophotometric | 42.0 | 35 - 60 | mg/dl |
| LDL Method: Spectrophotometric | 73.4 | 60 - 130 | mg/dl |
| VLDL Method: Spectrophotometric | 19.6 | 10 - 50 | mg/dl |
| Cholesterol/HDL Method: Spectrophotometric | 3.21 | | |

End of the report

Results are to be correlated clinically

Lab Technician / Technologist
RITU_JANGDE


Dr. PRIYANKA R SAHAI
 M.B.B.S, MD
 PATHOLOGIST

Patient Name : Mr. Santosh Kumar Panda
UHID/MR No. : FRAI.0000027260
Visit Date : 25-03-2023 13:52
Sample Collected on : 26-03-2023 09:13
Ref Doctor : Bank of Baroda
Emp/Auth/TPA ID : 4564536
Sponsor Name : MEDIWHEEL PVT LTD

Age / Gender : 46Y/Male
OP Visit No : FRAIOPV49656
Reported on : 27-03-2023 13:56
Specimen : Urine
Pres Doctor: :

DEPARTMENT OF LABORATORY MEDICINE


URINE ROUTINE EXAMINATION

| Test | Result | Bio. Ref. Interval |
|---------------------------------|-------------|--------------------|
| PHYSICAL EXAMINATION: | | |
| Volume of urine | 30 ml | |
| Colour | Pale Yellow | |
| Specific Gravity | 1.010 | 1.001 - 1.030 |
| Deposit | Absent | Absent |
| Appearance | Clear | Clear |
| pH | 6.5 | 5.0 - 7.5 |
| CHEMICAL EXAMINATION: | | |
| Protein | Absent | Absent |
| Sugar | Absent | Absent |
| Ketone Bodies | Absent | Absent |
| Blood | Absent | Absent |
| Leukocytes | Absent | Absent |
| Urobilinogen | Absent | Absent |
| Bili Pigments | Absent | Absent |
| MICROSCOPIC EXAMINATION: | | |
| Pus Cell | 2 - 4 | 0 - 5 / hpf |
| Red Blood Cells | Not Seen | 0 - 2 / hpf |
| Epithelial Cells | Occasional | 0 - 5 / hpf |
| Cast | Not Seen | Not seen |
| Crystals | Not Seen | Not seen |

End of the report

Results are to be correlated clinically

Lab Technician / Technologist
RITU_JANGDE



Dr. PRIYANKA R SAHAI
M.B.B.S, MD
PATHOLOGIST

PATIENT NAME:- MR. SANTOSH KUMAR PANDA
REF BY :- BOB

AGE/SEX:-46YRS/M
DATE:-25.03.2021

USG ABDOMEN

Liver: Liver is normal in size, smooth in outline with normal echotexture. IHBR's are not dilated. CBD is not dilated. Portal vein and hepatic veins are normal. **33.5x 24 mm size well defined hyperechoic lesion notes in right lobe of liver likely hemangioma.**

Gall bladder: Distended & normal

Pancreas & Paraaortic Region: Normal.

Spleen: Is normal in size, and echotexture.

| Kidneys | RIGHT | LEFT |
|----------------------------------|-------------|-------------|
| SIZE | 9.67X4.2cm | 8.9X4.8cm |
| CORTICAL ECHOGENICITY | Normal | Normal |
| CORTICOMEDULLARY DIFFERENTIATION | Maintained | Maintained |
| PCS | Not dilated | Not dilated |
| Any other remarks | Nil | Nil |

Urinary bladder: Distended & normal.

Prostate: is normal in size, shape & echotexture.

No free fluid in abdomen.

Visualized bowel loops are normal.

No significant intra-abdominal lymphadenopathy seen.

IMPRESSION:

- **HEPATIC HEMANGIOMA**

Advised clinical correlation/further evaluation if clinically indicated



Dr. Zeeshan Ateeb Dani
MBBS, DNB
Consultant Radiologist
Reg. No. CGMC-2524/2007
DR. ZEESHAN ATEEB DANI
(MD)
CONSULTANT RADIOLOGIST

This report is for perusal of the doctor only not the definitive diagnosis; findings have to be clinically correlated. Ultrasound has its limitations in obese patients and in retroperitoneal organs. All congenital abnormalities cannot be detected on ultrasound. This report is not for medico-legal purposes.

*THIS PAPER IS USED FOR CLINICAL REPORTING PURPOSE ONLY

Apollo Clinic

CENSEE : SAMRIDDI AROGYAM PVT. LTD.

Apollo Clinic @ Tiara Complex A.T. Classic Near Ashoka Ratan, VIP Estate, Shankar Nagar, Raipur (C.G.)

Mail : raipur1@apolloclinic.com | Website : www.apolloclinic.com

Online appointments: www.askapollo.com | Online reports: https://phr.apolloclinic.com

+91 96918 26363

0771 4033341/42

MR SANTOSH KUMAR PANDA
Male 46Y ears

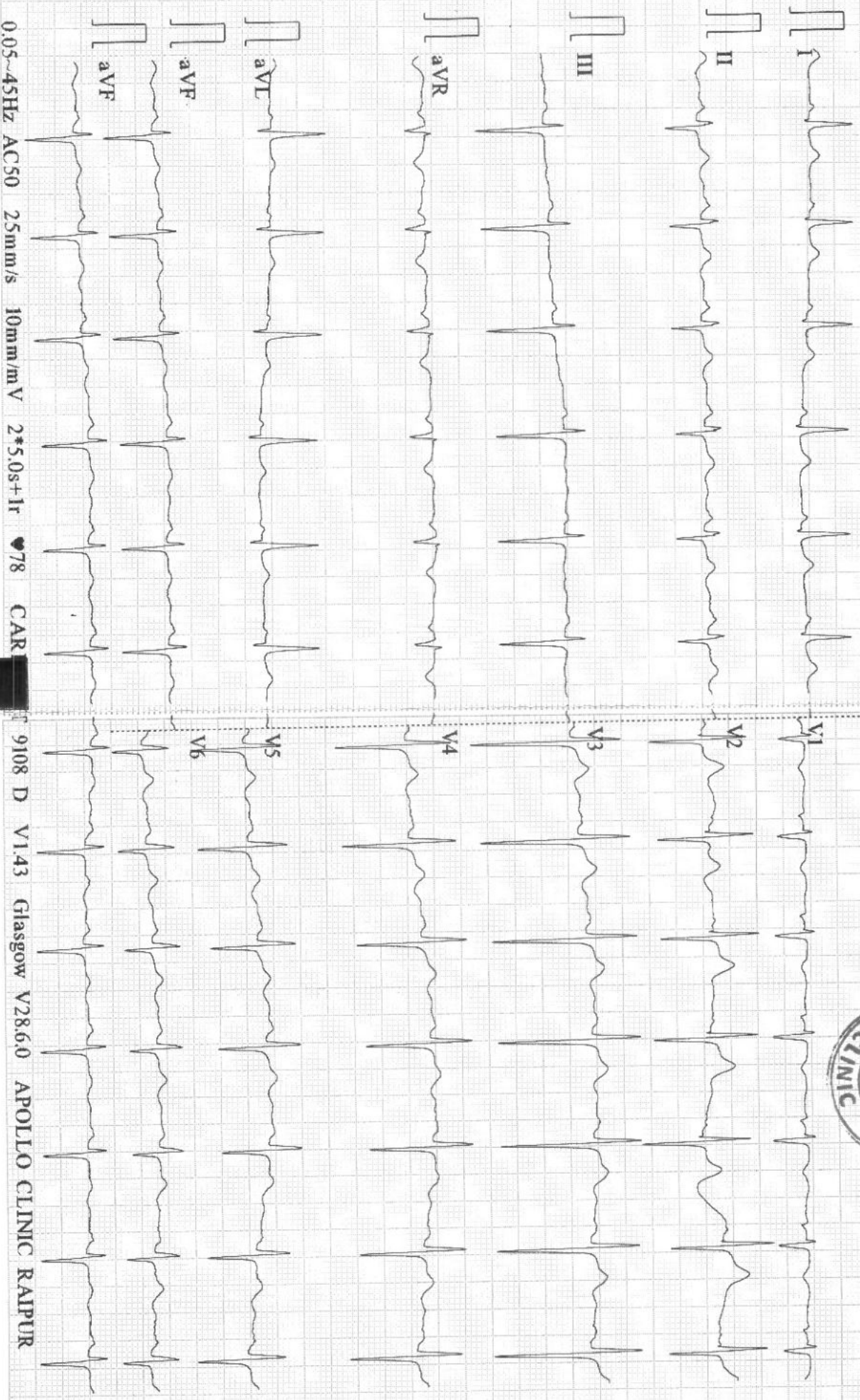
HR : 78 bpm
P : 126 ms
PR : 162 ms
QRS : 90 ms
QT/QTc : 374/426 ms
P/QRS/T : 58-40/31 °
RV5/SV1 : 0.666/0.521 mV

Diagnosis Information:
Sinus rhythm
Possible left anterior fascicular block
Borderline ECG

Report Confirmed by:



Dr. Ankit Sharma
MD Medicine
Reg. No.: CGMC 7971/2018
Apollo Clinic, Raipur



0.05-45Hz AC50 25mm/s 10mm/mV 2*5.0s+1r 78 CAR

9108 D V1.43 Glasgow V28.6.0 APOLLO CLINIC RAIPUR

ECHOCARDIOGRAPHY REPORT

| | | |
|--------------------------------|------------------------|------------------------|
| NAME : MR. SANTOSH KUMAR PANDA | Age/Sex: 46rs/male | ECG : Sinus Rhythm |
| OPD/ IPD : OPD | STUDY DATE: 25/03/2023 | REGN. NO. : FRAI.00000 |
| Ref. By Dr : BOB | | |

M-Mode Measurements:-

| | Patient Value (cm) | Normal Value (cm) | | Patient Value (cm) | Normal Value (cm) |
|----------------------|--------------------|-------------------|--------------------------|--------------------|-------------------|
| Aortic Root Diameter | 3.3 | 2.0 – 3.7 | IVS Thickness | ED = 1.1 ES = 1.5 | 0.6 – 1.1 |
| Aortic Valve Opening | 2.0 | 1.5 – 2.6 | PW Thickness | ED = 1.0 ES = 1.4 | 0.6 – 1.1 |
| LA Dimension | 3.2 | 1.9 – 4.0 | RA Dimension | --- | 2.6 |
| LVID(D) | 4.5 | 3.7 – 5.5 | RV Dimension | --- | 2.6 |
| LVID(s) | 2.8 | 2.2 – 4.0 | TAPSE | ---- | 1.6 – 2.6 |
| LV EJECTION FRACTION | > 60% | | (NORMAL VALUE: 55 – 60%) | | |

2D Echo, Color Flow & Doppler Assessment.

- Left Ventricle : LV Size & contractility is Normal, NO RWMA, Calculated EF IS > 60%
- Left Atrium : LA Size Is Normal
- Right Ventricle : Normal
- Right Atrium : Normal
- IAS/IVS : Intact
- Pericardium : Normal, there is no Pericardial Effusion.
- Mitral Valve : E>A, Normal
- Tricuspid Valve : Normal
- Aortic Valve : BICUSPID AORTIC VALVE, NO AS (PG-8mmHg), NO AR
- Pulmonary Valve : Pulmonary valve appears normal in morphology.
- Systemic venous : IVC normal in size with normal Inspiratory collapse.
- Diastolic Function : Normal.

FINAL IMPRESSION : BICUSPID AORTIC VALVE, NO AS, NO AR
NO RWMA AT REST.
NORMAL BIVENTRICULAR SYSTOLIC FUNCTION
NO I/C CLOT VEGITATION, PE OR CoA .



DR. DEEPAN DAS
MBBS, DIP. CARDIOLOGY
CONSULTANT DEPT. OF NIC

Apollo Clinic

LICENSEE : SAMRIDDHI AROGYAM PVT. LTD.

Apollo Clinic @ Tiara Complex A.T. Classic Near Ashoka Ratan, VIP Estate, Shankar Nagar, Raipur (C.G.)

Email : raipur1@apolloclinic.com | Website : www.apolloclinic.com

Online appointments: www.askapollo.com | Online reports: https://phr.apolloclinic.com

+91 96918 26363

0771 4033341/42

EXAMINATION OF EYES :- (BY OPHTHALMOLOGIST)

Patient Name Ms. Sandesh K. Pandey

Date 25/03/23

Sex/Age 46y/m

MR No

Employee Id

| | | | | |
|----------------------------------|------------|--------|------------|-------|
| EXTERNAL EXAMINATION | | NAD | | |
| SQUINT | | NO | | |
| NYSTAGMUS | | | | |
| COLOUR VISION | | NORMAL | | |
| FUNDUS:(RE):- | WNL | (LE):- | WNL | |
| INDIVIDUAL COLOUR IDENTIFICATION | | Good | | |
| DISTANT VISION:(RE):- | 6/6 | (LE):- | 6/9 & 6/6 | |
| NEAR VISION:(RE):- | M18 @ 4 N6 | (LE):- | M18 @ 6 N6 | |
| NIGHT BLINDNESS | | NAD | | |
| | SPH | CYL | AXIS | ADD |
| RIGHT | -0.25 | | | +1.50 |
| LEFT | | | | +1.50 |
| REMARKS :- | | | | |



Dr. Vikas Mishra
MBBS, MS(Ophthalmologist)
Reg. No. CGMC 621/2006

310 / MR SANTOSH / 46 Yrs / M / 165 Cms / 67 Kg Date: 25-Mar-2023

| Stage | Time | Duration | Belt Speed (Kmph) | Elevation | NETs | Rate | % THR Achieved | BP | RPP | PVC | Comments |
|---------------|-------|----------|-------------------|-----------|------|------|----------------|--------|-----|-----|----------|
| Standing | 00:13 | 0:02 | 02.7 | 10.0 | 01.0 | 64 | 37 % | 130/80 | 083 | 00 | |
| ExStart | 00:17 | 0:06 | 02.7 | 10.0 | 01.1 | 66 | 38 % | 130/80 | 085 | 00 | |
| BRUCE Stage 1 | 03:17 | 3:00 | 02.7 | 10.0 | 04.7 | 120 | 69 % | 130/90 | 156 | 00 | |
| BRUCE Stage 2 | 06:17 | 3:00 | 04.0 | 12.0 | 07.1 | 140 | 80 % | 140/90 | 196 | 00 | |
| PeakEX | 07:10 | 0:53 | 05.5 | 14.0 | 08.0 | 155 | 89 % | 140/90 | 217 | 00 | |
| Recovery | 07:39 | 0:29 | 00.8 | 00.0 | 04.2 | 150 | 86 % | 140/90 | 210 | 00 | |
| Recovery | 08:22 | 1:12 | 00.0 | 00.0 | 01.0 | 122 | 70 % | 130/90 | 158 | 00 | |

Findings :

Exercise Time : 06:54
 Max HR Attained : 169 bpm 97% of Target 174
 Max BP Attained : (Sys) 140/90
 Max Workload Attained : 8 Fair response to induced stress
 Test End Reasons : Test Complete, Heart Rate Achieved

Report :

Report: Stress test is Negative for Reversible Myocardial Ischemia with fair function capacity.



Doctor : DR DEEPAN DAS MBBS DIP.CARDIO

(GEM213180726(N)Allengas




310 / MR SANTOSH / 46 Yrs / M / 165 Cms / 67 Kg / HR : 64

Date: 25-Mar-2023 11:55:00 AM METS: 1.0/ 64 bpm 36% of THR BP: 130/80 mmHg Raw ECG/ BLC On/ Natch On/ HF 0.05 Hz/LF 20 Hz

4X

80 ms Post J

ExTime: 00:02 2.7 Km/h, 10.0%
25 mm/Sec. 1.0 Cm/mV



I
STL 0.7
STS 0.6

II
0.6
0.7

III
-0.1
0.1

avR
-0.6
-0.6

avL
0.4
0.2

avF
0.3
0.4

V1
0.3
0.1


V2
1.4
1.2

V3
0.9
0.9

V4
0.7
0.8

V5
0.4
0.6

V6
0.2
0.4



REMARKS:



Date: 25-Mar-2023 11:55:00 AM


METS: 1.1 / 66 bpm 37% of THR BP- 130/80 mmHg

Raw ECG/ BLC On/ Notch On/ HF 0.05 Hz/LF 20 Hz

EXTime: 00:06 2.7 Kmph, 10.0%

4X 80 ms Post J

25 mm/Sec. 1.0 Cm/mV



I
STL 0.7
STS 0.6

II
0.6
0.7

III
-0.1
0.1

avR
-0.6
-0.6

avL
0.4
0.2

avF
0.3
0.4

V1
0.3
0.1


V2
1.4
1.2

V3
0.9
0.9

V4
0.7
0.8

V5
0.4
0.6

V6
0.2
0.4



REMARKS:



310 / MR SANTOSH / 46 Yrs / M / 165 Cms / 67 Kg / HR : 120

Date: 25-Mar-2023 11:55:00 AM

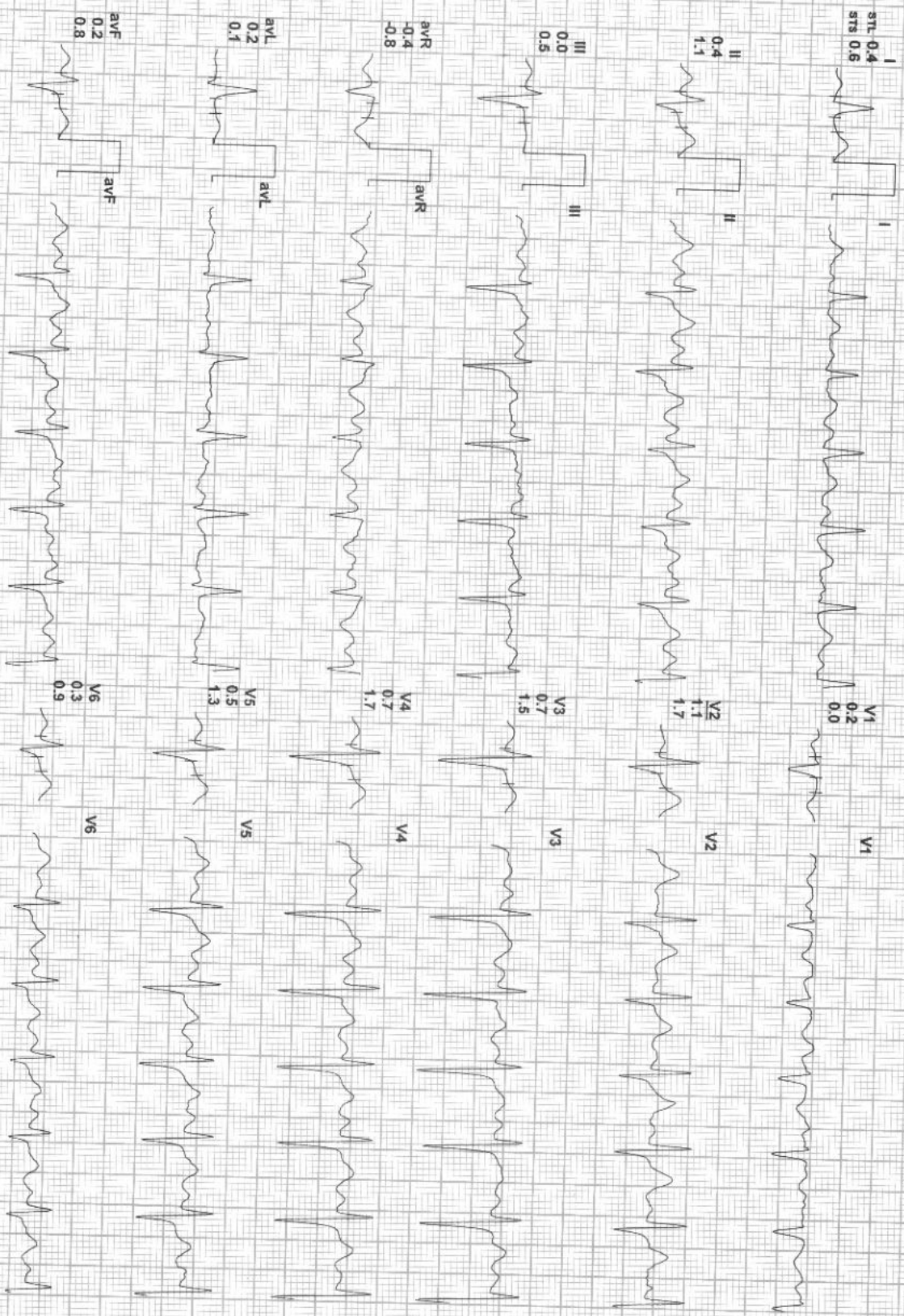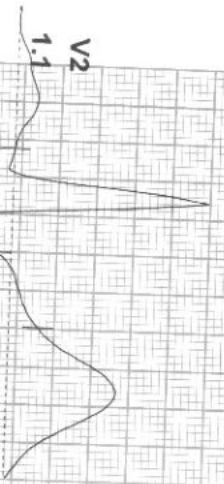METS: 4.7/ 120 bpm 68% of THR BP: 130/90 mmHg

Raw ECG/ BLC On/ Notch On/ HF 0.05 Hz/LF 20 Hz

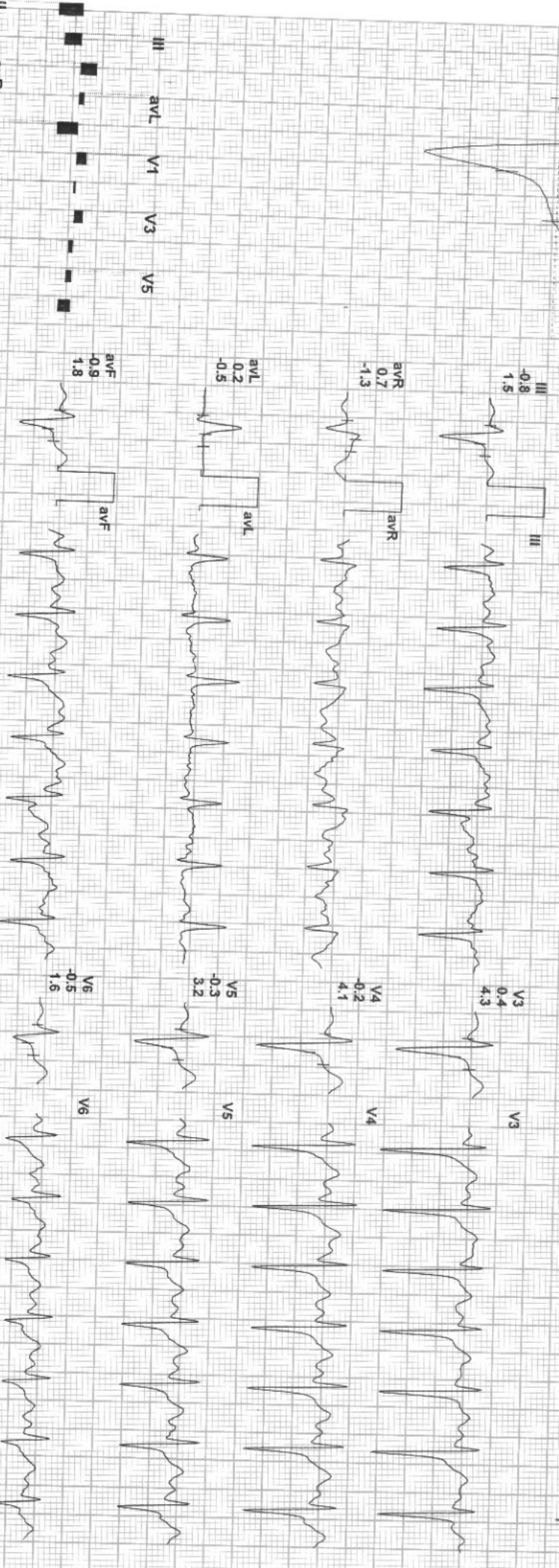
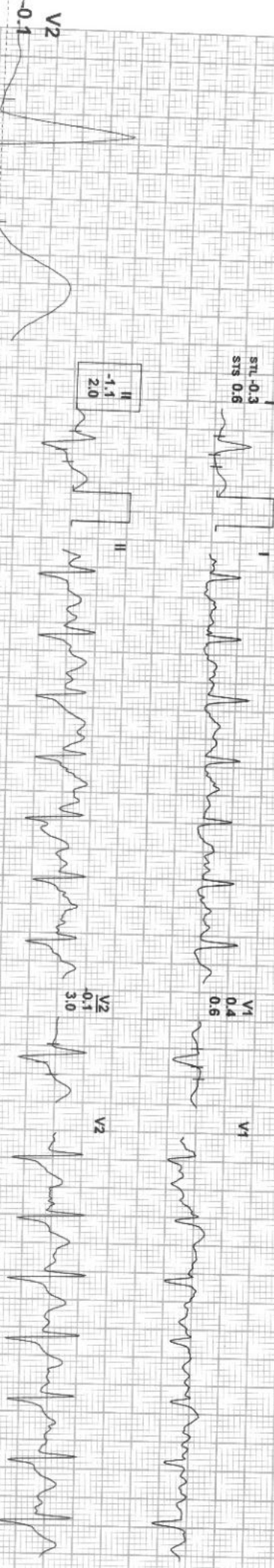
EXTime: 03:00 2.7 Kmph, 10.0%

25 mm/Sec. 1.0 Cm/mV

4X 80 mS Post J



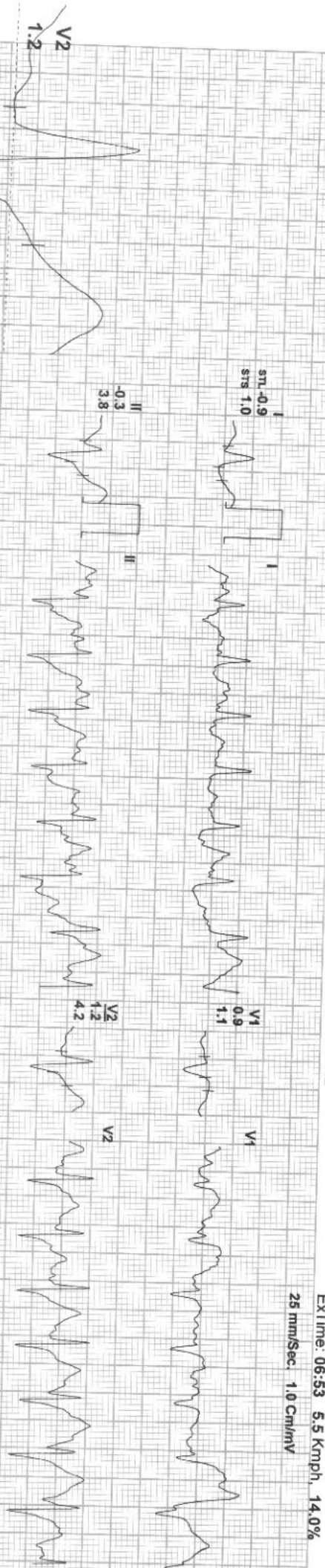
REMARKS: I II III aVR aVL aVF V1 V2 V3 V4 V5 V6



REMARKS:



4X 60 m/s Post J



REMARKS:



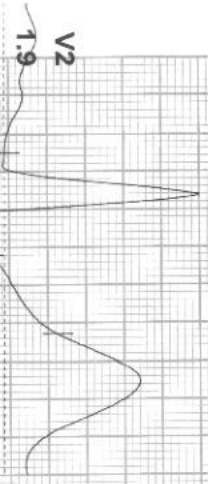
310 / MR SANTOSH / 46 Yrs / M / 165 Cms / 67 Kg / HR : 122

Date: 25-Mar-2023 11:55:00 AM METS: 1.0/ 122 bpm 70% of THR BP: 130/90 mmHg Raw ECG/ BLC On/ Notch On/ HF 0.05 Hz/ LE 20 Hz

EXTIME: 06:54 0.0 Km/h, 0.0%

4X 80 mS Post J

25 mm/Sec. 1.0 Cm/mV



I
STL 0.3
STR 0.7

II
1.3
2.1

III
0.9
1.4

aVR
-0.8
-1.4

aVL
-0.3
-0.4

aVF
1.1
1.8

V4
0.3
-0.1


V2
1.9
2.9

V3
2.0
2.8

V4
1.8
2.8

V5
1.2
2.1

V6
0.9
1.6



REMARKS:

(GEM2131B0726)(R)Allengers