



ABI SCANS & LABS

A unit of Aarthi Scans and Labs

Name	MRS. SREELEKHA	Patient ID	89332
Accession No	93078	Age/Gender	49Y / Female
Referred By	MEDIWHEEL	Date	26-Mar-2022

USG REPORT - ABDOMEN AND PELVIS

LIVER:

Is normal in size ~ 15.4 cm and shows increased echo texture.

No obvious focal lesion seen. No Intra - Hepatic biliary radical dilatation seen.

GALL BLADDER:

Is adequately distended. No calculus or internal echoes are seen. Wall thickness is normal.

PANCREAS:

Appears normal in size and it shows uniform echo texture.

SPLEEN:

Is normal in size ~ 9.1 cm and shows uniform echogenicity.

RIGHT KIDNEY:

Right kidney measures ~ 10.6 x 3.6 cms.

The shape, size and contour of the right kidney appear normal.

Cortico medullary differentiation is within normal. No evidence of pelvicalyceal dilatation.

No calculi seen.

LEFT KIDNEY:

Left kidney measures ~ 9.3 x 4.2 cms.

The shape, size and contour of the left kidney appear normal.

Cortico medullary differentiation is within normal. No evidence of pelvicalyceal dilatation.

No calculi seen.



ABI SCANS & LABS

A unit of Aarthi Scans and Labs

Name	MRS. SREELEKHA	Patient ID	89332
Accession No	93078	Age/Gender	49Y / Female
Referred By	MEDIWHEEL	Date	26-Mar-2022

USG REPORT - ABDOMEN AND PELVIS

BLADDER:

Is normal contour. No intra luminal echoes are seen.

UTERUS:

Measures ~ 9.3 x 4.8 x 5.8 cms.

Endometrium is regular and normal (1.4cm).

Uterus appears bulky and heterogenous with multiple subcentimetric myometrial cysts and altered endo myometrial junction.

Anterior myometrial fibroids measuring ~ 10 x 10 mm and 11 x 7 mm seen.

Calcified Posterior myometrial fibroid measuring ~ 1.2 x 1.2 cm seen.

Subserosal fibroid measuring ~ 12.9 x 2.9 cm seen arising from the posterior myometrium.

Cervix appears normal.

OVARIES:

Right ovary measures ~ 2.3 x 1.3 cms.


Left ovary measures ~ 2.4 x 1.5 cms.

IMPRESSION:

- ❖ Grade I fatty liver.
- ❖ Uterine adenomyosis.
- ❖ Uterine fibroids as described.

- Suggested clinical correlation.

Dr. Abinaya Rajasekaran, MD.,RD.,
Reg. No: 119338.


Dr. Abinaya Rajasekaran., MDRD.,
Radiologist

Thank you for the courtesy of this referral

Foot Note: Patient's identity is not verified. Report is not valid for medico legal purpose.



ABI SCANS & LABS

A unit of Aarthi Scans and Labs

Name	MRS. SREELEKHA	Patient ID	89332
Accession No	93078	Age/Gender	49Y / Female
Referred By	MEDIWHEEL	Date	26-Mar-2022

X - RAY - MAMMOGRAM BOTH SIDES

TECHNIQUE:

Full field digital mammography of both breasts was performed in cranio-caudal and medio-lateral oblique views

OBSERVATION:

The fibroglandular density is normal for age in both breasts.

Nipple and subareolar tissue are normal.

No retraction or skin thickening is seen.

Subcutaneous tissue and cooper's ligaments are normal.

No evidence of any distortion of the tissues seen.

The pectoralis and retro mammary space appears normal.

No abnormal macrocalcification / microcalcification seen.

Axillary tail is normal.

USG SCREENING

No evidence of any lesions seen in bilateral breasts.

Few subcentimetric axillary lymphnodes with preserved fatty hilum seen.

IMPRESSION:

- **BIRADS I - No significant abnormality seen.**
- **Radiologically benign appearing bilateral axillary lymph nodes.**

NOTE: BI - RADS SCORING KEY

0 - Needs additional evaluation; I - Negative II - Benign findings; III - Probably benign

IV - Suspicious abnormality - Biopsy to be considered

V - Highly suggestive of malignancy; VI - Known biopsy proven malignancy

**Dr. Abinaya Rajasekaran., MDRD.,
Radiologist**

Thank you for the courtesy of this referral

Foot Note: Patient's identity is not verified. Report is not valid for medico legal purpose.

**Dr. Abinaya Rajasekaran, MD.,RD.,
Reg. No: 119338.**



ABI SCANS & LABS

A unit of Aarthi Scans and Labs

Patient Name	MRS.SREELEKHA 49Y	Age	49Yr
Patient ID	93078	Sex	Female
Referral Dr	MEDIWHEEL	Study Date	26 Mar 2022

X-RAY - CHEST PA VIEW

OBSERVATION:

The trachea is central.

The mediastinal and cardiac silhouette are normal.

Cardiothoracic ratio is normal.

Cardiophrenic and costophrenic angles are normal.

Both hila are normal.

Lung zones are clear.

Bones of the thoracic cage are normal.

Soft tissues of the chest wall are normal.

IMPRESSION:

No significant abnormality seen.

Dr. Abinaya., MD., (RD)
Consultant Radiologist

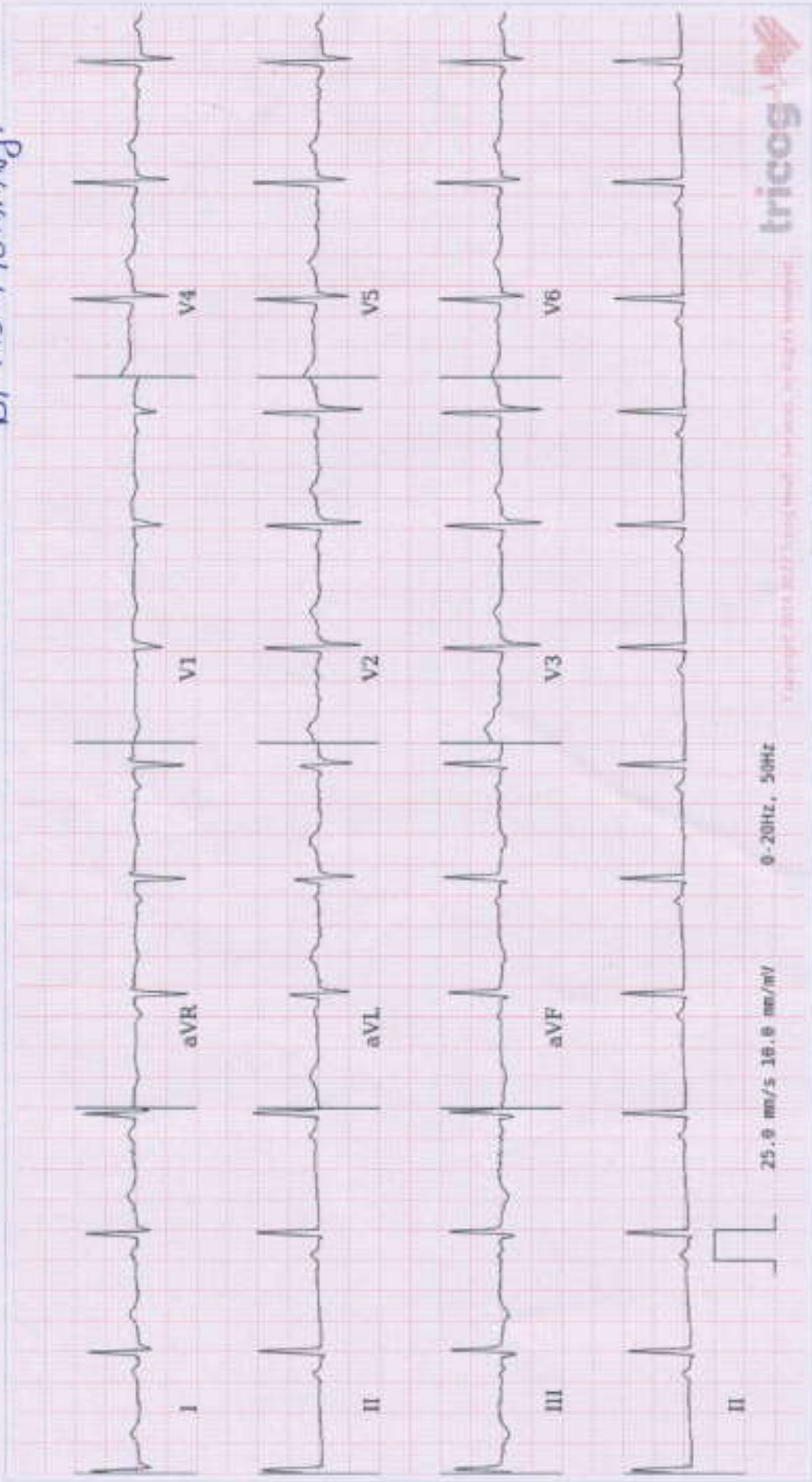


Aarhi CT and MRI Scans, R S Puram West

Age / Gender: 49/Female
Patient ID: 0000089332
Patient Name: MRS. SREELEKHA

Date and Time: 26th Mar 22 10:43 AM

BP: 150/90 mmHg.



Within Normal Limits: Sinus Rhythm, Normal Axis. Please correlate clinically.





ABI SCANS & LABS

A unit of Aarthi Scans and Labs

NAME	MRS. SREELEKHA	PATIENT ID	89332
ACCESSION NO	93078	AGE/GENDER	49Y/FEMALE
REFERRED BY	MEDIWHEEL	DATE	26.03.2022

ECHOCARDIOGRAPHIC EVALUATION

MEASUREMENTS: ACOUSTIC WINDOW: OPTIMAL

2D/ M MODE PARAMETERS:

Parameters	Patient Values	Normal Adult Value
LA	3.42	(2.0 - 4.0 cm)
AO	2.98	(2.0 - 4.0 cm)
LVIDD	4.67	(3.5 - 5.5 cm)
LVIDS	2.85	(2.5 - 4.3 cm)
IVSd	0.89	(0.6 - 1.2 cm)
LVPWd	0.98	(0.6 - 1.2 cm)
EF	69	(50% - 70%)

IMPRESSION:

- ✚ No regional wall motion abnormality at rest.
- ✚ Normal valves and chambers.
- ✚ No pulmonary hypertension.
- ✚ No pericardial effusion.
- ✚ Normal LV systolic function.

**Dr. KARTHIK C.S.MD.,PGD(CARDIOLOGY,UKR)
CONSULTANT CARDIOLOGIST.**



ABI SCANS & LABS

A unit of Aarthi Scans and Labs

NAME	MRS. SREELEKHA	PATIENT ID	89332
ACCESSION NO	93078	AGE/GENDER	49Y/FEMALE
REFERRED BY	MEDIWHEEL	DATE	26 -MARC-2022

VISION TEST

VISUAL ACUITY (VA)

If The Acuity Can Be Measures, Complete This Box Using Snellen acuities or snellen equivalents or NLP,LP,HM, or distance at which the patient sees the 20/100 letter.

WITH BEST CORRECTION

DISTANCE VISION	
Right	09/11
Left	09/11
Both	10/11

NEAR VISION	
Right	N6
Left	N6
Both	N6

COLOUR VISION	
BOTH	Normal



भारत सरकार
GOVERNMENT OF INDIA



சரண்யா அ.பு
Saranya.A.P

பிறந்த நாள்/ DOB: 18/02/1988
பெண் / FEMALE



9437 6815 3685

எனது ஆதார். எனது அடையாளம்



भारतीय विशिष्ट पहचान प्राधिकरण
UNIQUE IDENTIFICATION AUTHORITY OF INDIA™

முதுவரி:

W/O: முரளிதரன், எண் 45,
லால் பகதூர் சாஸ்திரி வீதி,
வேளாண்டிபாளையம்,
செயம்புத்தூர் வடக்கு,
செயம்புத்தூர்,
தமிழ் நாடு - 641025

Address

W/O: Muralidharan, NO 45, LAL
BAGADHUR SASTHRI NAGAR,
VELANDIPALAYAM, Coimbatore
North, Coimbatore,
Tamil Nadu - 641025



1947
1800 300 1947



help@uidai.gov.in



www.uidai.gov.in

P.O. Box No. 1947,
Bangalore-560 001

Saranyalluvalli



बैंक ऑफ बड़ौदा
Bank of Baroda

नाम : सरन्या ए पी
Name : SARANYA A P

क.कू.सं
E.C. No. : 161588

जारीकर्ता प्राधिकारी
Issuing Authority



धारक के हस्ताक्षर
Signature of Holder

Saranyapallurathali