




भारतीय विशिष्ट पहचान प्राधिकरण


Unique Identification Authority of India


पता: संबोधित: आदित्य नारायण
पटेल, छिन्नपुर, वाराणसी, हिंदू विश्व
विद्यालय, उत्तर प्रदेश, 221005

Address: D/O: Aditya Narayan Patel,
Chinnpur, Varanasi, Hindu Vishwa
Vidhyalaya, Uttar Pradesh, 221005

3974 1904 5520


1947
1800 300 1947


help@uidai.gov.in


www.uidai.gov.in



GPS Map Camera

Varanasi, Uttar Pradesh, India

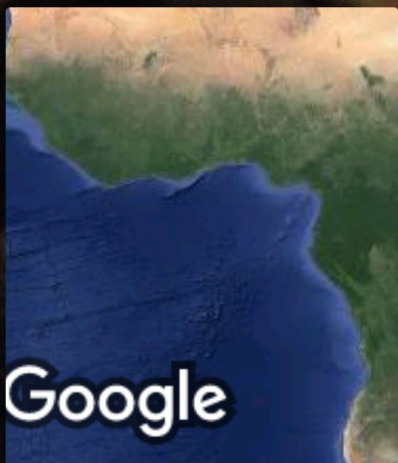
B36/44B-3, Padampuri Colony, Durgakund, Nagwa,

Varanasi, Uttar Pradesh 221005, India

Lat 25.289204°

Long 82.993374°

08/07/23 08:34 AM GMT +05:30






भारत सरकार

Government of India



आराधना पटेल
Aradhana Patel

जन्म तिथि / DOB : 13/03/1996
महिला / Female



3974 1904 5520

आधार - आम आदमी का अधिकार



GPS Map Camera

Varanasi, Uttar Pradesh, India

B36/44B-3, Padampuri Colony, Durgakund, Nagwa,
Varanasi, Uttar Pradesh 221005, India

Lat 25.289204°

Long 82.993374°

08/07/23 08:34 AM GMT +05:30

Google

Facilities:
 All clinical Biomedical & Hematology Investigations
 including Bone Marrow Examination
 VPT, Podiascan & Complete Foot Care (First Time in Purvanchal)
 All Hormonal Investigation by Chemiluminescent Method
 Visceral Fat by (AB-140) Ambulatory BP Monitoring
 CGMS & Insulin Pump Available
 PFT, 2D-ECHO (Color Doppler), Holter, TMT, Cardiac-3 available
 VIA, VILI, Colposcopy available
 Special Endocrinological Investigation Protocols.

ISO 9001:2008 Certified
 Mobile: 9389994334, 9554572190, 9453837595



Panacea Pathology

Clinical Reference Lab

Persistence, Preparedness and Precision
 EQAS (CMC Vellore Attached) & IQAS System
 पूर्वांचल की सर्वोत्तम गुणवत्ता वाली पैथोलॉजी

PATIENT NAME : ARADHANA PATEL	AGE/GENDER : 27YRS/FEMALE
REFD BY DR. : ARCO FEMI HEALTHCARE LTD.	RECEIVED DATE : 08-07-2023 (09:00AM)
SAMPLE : BLOOD & URINE	REPORT DATE : 08-07-2023 (07:00PM)

PATHOLOGY REPORT

COMPLETE BLOOD COUNT (CBC)

TEST	LAB TEST VALUES	NORMAL RANGE
HEMOGRAM		
HEMOGLOBIN (FLOW CYTOMETRY)	10.0	13 – 16 gm/dl
TOTAL LEUCOCYTE COUNT (TLC)	6,400	4000 – 11000
RBC COUNT	3.68	3.5 – 5.5
PCV (HCT)	33.7	37 – 47
MCV	89.8	80 – 95
MCH	27.2	28 – 34
MCHC	30.3	30 – 36
PLATELET COUNT	1,71,000	1,50,000 – 4,00,000
E.S.R. (WINTROBE FIRST HOURS)	10.0	20 mm/1 st hr
DIFFERENTIAL LEUCOCYTE		
NEUTROPHILS	52	40 – 75%
LYMPHOCYTES	43	20 – 45%
EOSINOPHILS	03	1 – 6%
MONOCYTES	02	2 – 8%
BASOPHILS	00	< 2%

RANDOM/FASTING BLOOD SUGAR

TEST	LAB TEST VALUES	NORMAL RANGE
RBS/FBS		
FASTING BLOOD SUGAR	104.7	70-125 mg/dl
RANDOM BLOOD SUGAR		125-140 mg/dl

GLYCOSYLATED HEMOGLOBIN (HBA1C)

TEST	LAB TEST VALUES	NORMAL RANGE
HBA1C	5.3	Normal : <5.97 % Good Control : 5.97 – 6.81% Fair Control : 6.81 – 7.65% Poor Control : >7.65%

PAGE 1

Lab Technician

(Signature)
PANACEA HOSPITAL
 (A UNIT OF ARCO FEMI HEALTHCARE PVT. LTD.)
 M.D., Pathology
 REG NO. AL-1500
 DURGAKUND, VARANASI - 221005

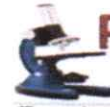Timing : 8.00 a.m. to 9.00 p.m. (Sunday 8.00 a.m. to 3.00 p.m.)

This Report is not valid for medical legal purpose

Note: These tests have technical limitations. Clinico-pathological interpretation is necessary. In case of any disparity test

Facilities:
 All clinical Biomedical & Hematology Investigations
 including Bone Marrow Examination
 VPT, Podiascan & Complete Foot Care (First Time in Purvanchal)
 All Hormonal Investigation by Chemiluminescent Method
 Visceral Fat by (AB-140) Ambulatory BP Monitoring
 CGMS & Insulin Pump Available
 PFT, 2D-ECHO (Color Doppler), Holter, TMT, Cardiac-3 available
 VIA, VILI, Colposcopy available
 Special Endocrinological Investigation Protocols.

ISO 9001:2008 Certified
 Mobile: 9389994334, 9554572190, 9453837595



Panacea Pathology

Clinical Reference Lab

Persistence, Preparedness and Precision
 EQAS (CMC Vellore Attached) & IQAS System
 पूर्वांचल की सर्वोत्तम गुणवत्ता वाली पैथोलॉजी

PATIENT NAME : ARADHANA PATEL

AGE/GENDER : 27YRS/FEMALE

REFD BY DR. : ARCO FEMI HEALTHCARE LTD.

RECEIVED DATE : 08-07-2023 (09:00AM)

SAMPLE : BLOOD & URINE

REPORT DATE : 08-07-2023 (07:00PM)

PATHOLOGY REPORT

LIPID PROFILE, SERUM

TEST	LAB TEST VALUES	NORMAL RANGE
BLOOD CHEMISTRY		
TOTAL CHOLESTEROL (SERUM)	164.0	Desirable:- < 200 mg/dl Borderline:- 200 – 239 mg/dl High:- > 240 mg/dl
TRIGLYCERIDES (SERUM)	148.0	35 – 170 mg/dl
HDL CHOLESTEROL (SERUM)	41.0	35.30 – 79.50 mg/dl
LDL CHOLESTEROL (SERUM)	93.4	< 130 mg/dl
VLDL	29.6	< 40 mg/dl
CHOLESTROL/HDL RATIO	4.0	< 3.0 Low Risk Ratio 3.0 – 5.0 Avg Risk < 5.0 High Risk
LDL/HDL RATIO	2.27	< 3 Ratio

BLOOD GROUP

TEST	LAB TEST VALUES
BLOOD GROUP ABO & RH FACTOR	
BLOOD GROUP	"A"
RH FACTOR	POSITIVE

LIVER PROFILE TEST, SERUM

TEST	LAB TEST VALUES	NORMAL RANGE
BIO CHEMISTRY		
TOTAL BILIRUBIN	0.72	0.0 – 1.1 mg/dl
DIRECT BILIRUBIN	0.28	0.0 – 0.2 mg/dl
INDIRECT BILIRUBIN	0.44	< 0.90 mg/dl
SGOT (AST)	26.0	0 – 52 mg/dl
SGPT (ALT)	23.0	0 – 39 mg/dl
GGT (GYT)	19.0	< 55 U/L

THYROID PROFILE (T3, T4, TSH)

TEST	LAB TEST VALUES	NORMAL RANGE
THYROID FUNCTION TEST		
T3	0.83	0.60 – 1.81 ng/ml
T4	5.16	4.50 – 10.90 ug/dl
TSH	7.58	0.39 – 6.10 uIU/mL

PAGE 2

Lab Technician

PANACEA HOSPITAL

(A UNIT OF ARCO FEMI HEALTHCARE PVT. LTD.)

REG NO. AL-1500

Timing : 8.00 a.m. to 9.00 p.m. (Sunday 8.00 a.m. to 3.00 p.m.)

This Report is not valid for medico legal purpose

Note: These tests have technical limitations. Clinico-pathological interpretation is necessary in case of any disparity test

OUR GAKIND, VARANASI, 221006

Facilities:

All clinical Biomedical & Hematology Investigations including Bone Marrow Examination
 VPT, Podiascan & Complete Foot Care (First Time in Purvanchal)
 All Hormonal Investigation by Chemiluminescent Method
 Visceral Fat by (AB-140) Ambulatory BP Monitoring
 CGMS & Insulin Pump Available
 PFT, 2D-ECHO (Color Doppler), Holter, TMT, Cardiac-3 available
 VIA, VILI, Colposcopy available
 Special Endocrinological Investigation Protocols.

ISO 9001:2008 Certified
 Mobile: 9389994334, 9554572190, 9453837595



Panacea Pathology

Clinical Reference Lab

Persistence, Preparedness and Precision
 EQAS (CMC Vellore Attached) & IQAS System
 पूर्वीचल की सर्वोत्तम गुणवत्ता वाली पैथोलॉजी

PATIENT NAME : ARADHANA PATEL

AGE/GENDER : 27YRS/FEMALE

REFD BY DR. : ARCO FEMI HEALTHCARE LTD.

RECEIVED DATE : 08-07-2023 (09:00AM)

SAMPLE : BLOOD & URINE

REPORT DATE : 08-07-2023 (07:00PM)

PATHOLOGY REPORT

RENAL & KIDNEY PROFILE, SERUM

TEST	LAB TEST VALUES	NORMAL RANGE
RENAL FUNCTION TESTS		
BLOOD UREA NITROGEN (BUN)	10.2	10 – 50 mg/dl
SERUM CREATININE	0.77	0.60 – 1.60 mg/dl
URIC ACID	3.98	3.60 – 7.70 mg/dl
ALKALINE PHOSPHATASE (ALP)	72.0	142 – 353 mg/dl
TOTAL PROTIENS	7.42	0 – 39 mg/dl
ALBUMIN	4.12	3.8 – 5.4 mg/dl
SERUM GLOBULIN	3.32	2.1 – 3.5 mg/dl
AG RATIO	1.24	-

URINE ROUTINE EXAMINATION

TEST	LAB TEST VALUES	NORMAL RANGE
PHYSICAL EXAMINATION		
QUANTITY	30	ML
COLOUR	STRAW	PALE YELLOW
APPEARANCE	CLEAR	CLEAR
SPECIFIC GRAVITY	1.025	1.01 – 1.03
PH	6.5	4.7 – 7.5
CHEMICAL EXAMINATION		
GLUCOSE	Not Detected	Not Detected
PROTEIN	NIL	Not Detected
MICROSCOPIC EXAMINATION		
PUS CELLS	01-02	0-5
RBC	Not Detected	Not Detected
EPITHELIAL CELLS	01-02	0-5
CASTS	Not Detected	Not Detected
CRYSTALS	Not Detected	Not Detected
BACTERIA	Not Detected	Not Detected

----- End of Report -----

Lab Technician

Timing : 8.00 a.m. to 9.00 p.m. (Sunday 8.00 a.m. to 3.00 p.m.)

This Report is not valid for medico legal purpose

Note: These tests have technical limitations. Clinico-pathological interpretation is necessary in case of any disparity test

(Signature)
 PANACEA HOSPITAL
 M.D. Pathology
 A UNIT OF ARCO FEMI HEALTHCARE PVT. LTD.)
 REG. NO. AL-1500
 344, B-4, KABIR NAGAR
 KUNDA, VARANASI - 221005



6

PANACEA HOSPITAL

B 36/44 F.K KABIR NAGAR, DURGAKUND
TOLLFREE NO-18001233070.
Whatsapp No - 8795832852
www.piire.org



OP Slip

Print Date : 08-Jul-2023 08:40AM



UHID No :- UD-23240001413	OP No :- OP-23240004933	OP Date :- 08 Jul 2023 8:39AM
Patient Name :- Mrs Aradhana patel	Age/Sex :- 27 Y/Female	Mobile No :- 9889120070
Husband :- Ashok kumar singh	Department :- OBST. & GYNAECOLOGY	
Pay Type :- Cash	Consultant :- Dr VANDANA SINGH (MBBS,MS)	
Token No :- NOR. - 1	Paid/Bal :- 0.00 /30.00	
Patient Type :- Normal		
Address :- 1/18 Golaghat Ramnagar bhatti ,varanasi		

BP :- 110/70
 height :- 154
 Weight (kg) :- 86.4
 BMI :- 36.4
 SpO₂ - 95
 PR - 107
 NL - 35
 WL - 124
 RBS - NO
 PEFR - 160

Rx for Routine check up.

LMP - 6/7/2023 - Regular. on Tab thyron 50ug. [Irregular intake].

P3 to L3 ← 6y
 4y
 6m] USS.

TL done.
Breastfeeding

adv No gynae. complaints.
 Tab calcium 1 x OD x 30d.

Printed By : Ms. ANJALI

Created By : Ms. ANJALI

Madans

BPL - 02

AUTO 10mm/mV

10mm/mV

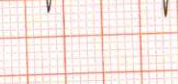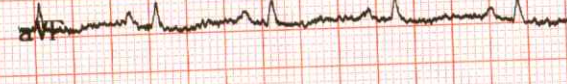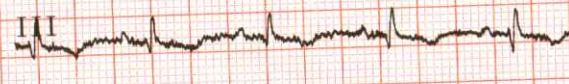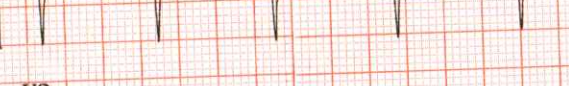
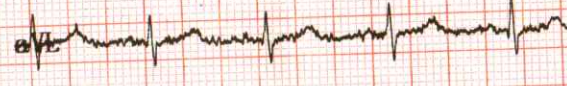
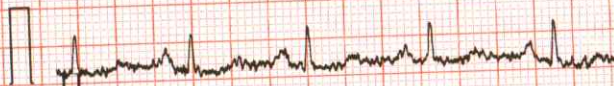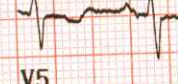
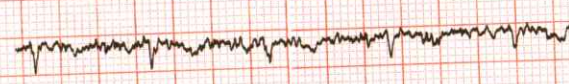
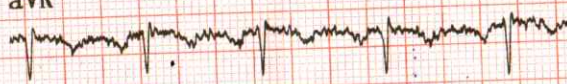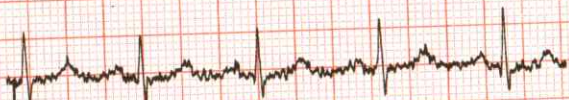
10mm/mV

10mm/mV

aVR

V1

V4

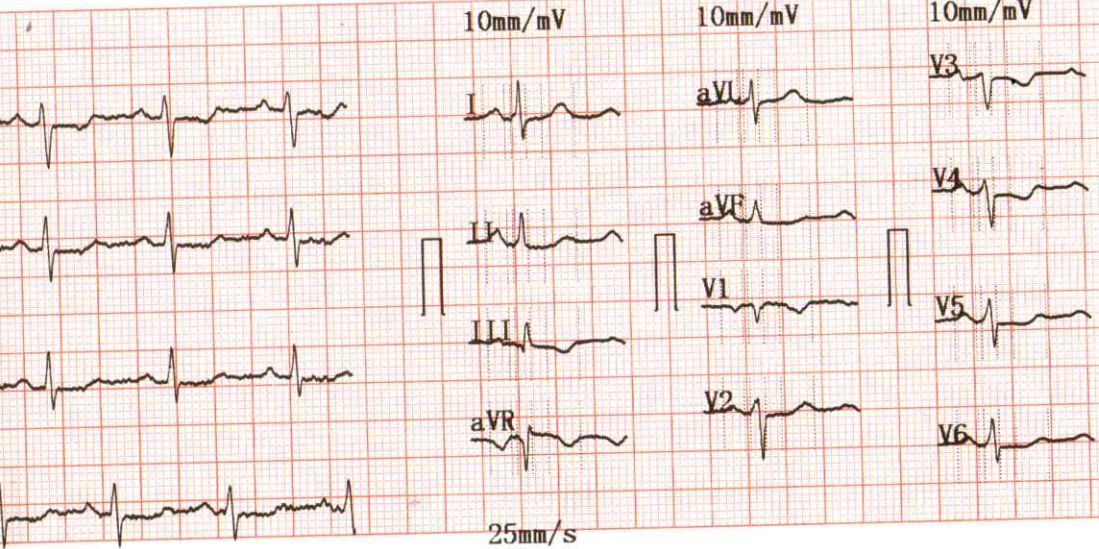


V5 10mm/mV

25mm/s AC 50HZ

CARDIART

BPL - 02



25mm/s

2023-07-08 09:33

<< Conclusions >>

ID :
 Name : **ARADHANA PATEL**
 Sex : **FEMALE** Age : **27**
 Height : _____ Weight : _____ kg
 SYS : _____
 DIA : _____

Normal Sinus Rhythm;
 Cardiac electric axis normal;
 III aVF V4 V5 Abnormal T wave;
 Report need physician confirm

HR [bpm] : 94
 PR Interval [ms] : 149
 P Duration [ms] : 116
 QRS Duration [ms] : 84
 T Duration [ms] : 178
 QT/QTc [ms] : 350/438
 P/QRS/T Axis [deg] : 43.8/51.6/-11.9
 R(V5)/S(V1) [mV] : 0.29/0.22
 R(V5)+S(V1) [mV] : 0.51

DR. PALLAB MISHRA
 MBBS, MD (GENERAL MEDICINE)
 MCI Reg. No. 52033

CARDIART Physician _____



Call Now - 1800-123-3070

PANACEA HOSPITAL

A shelter for many hearts A Home for many lives

(An ISO 9001:2008 Certified Organisation)

Lab Attached with CMC Vellore Under EQAS Scheme

PATIENT'S NAME : MRS.ARADHANA PATEL

AGE/SEX: 27 Y/F

REF. BY : Dr. ASHUTOSH MISHRA (MD)

Saturday, July 08, 2023

Echo - Cardiography

MITRAL VALVE Doppler	AML - normal morphology MV Flow - E - 0.7 A-0.6 E/A=1.21	PML - normal morphology MVA - 3.0 cm ² Mitral Regurgitation - No
TRICUSPID VALVE Doppler	Normal TV Flow -No	Tricuspid Regurgitation -No
PULMONARY VALVE Doppler	Normal PV Flow -No	Pulmonary Regurgitation - No
AORTIC VALVE Doppler	Trileaflet-No AV Flow - no	Aortic Regurgitation - no
MEASUREMENT	Aorta - 20.6 (20-38) mm IVS ed - 8.0 (6-12) mm LVID ed - 45.1 (35-55) mm LVPW ed - 8.0 (6-12) mm OA - 7 (> 5) mm	LA - 29.1 (24-32) mm IVS es -12.0 (6-12) mm LVID es - 30.3 (24-40) mm LVPW es - 12.0 (6-12) mm EPSS - 6 (< 9) mm


CONCLUSION

All cardiac chamber dimensions are WNL
No valvular abnormalities
Good LV systolic function present Modified Simpson's method (4C, 2C) (LVEF-62%)
No diastolic dysfunction present (E/A = 1.21)
No RWMA
No pericardial effusion
Intact IAS / IV
No PAH
No intra cardiac mass /thrombus /vegetation

IMPRESSION

Normal Echocardiogram

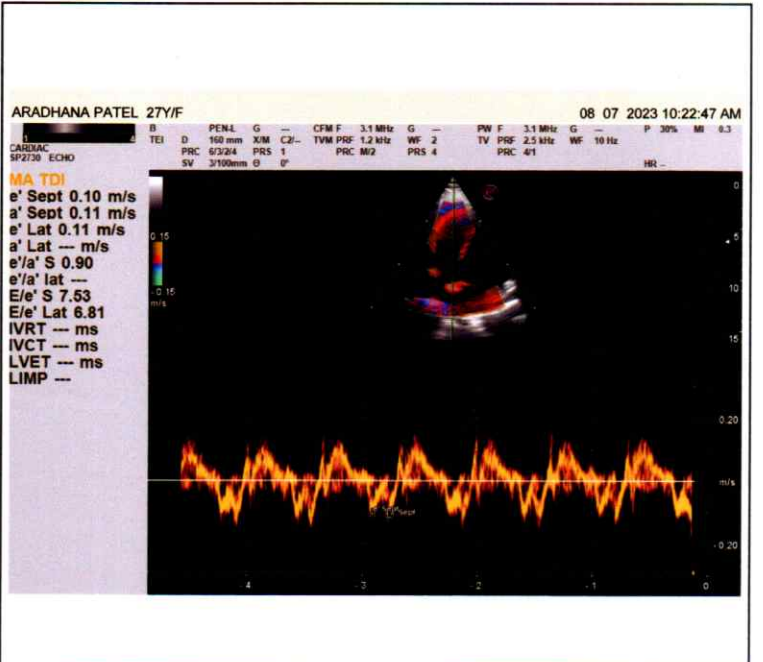
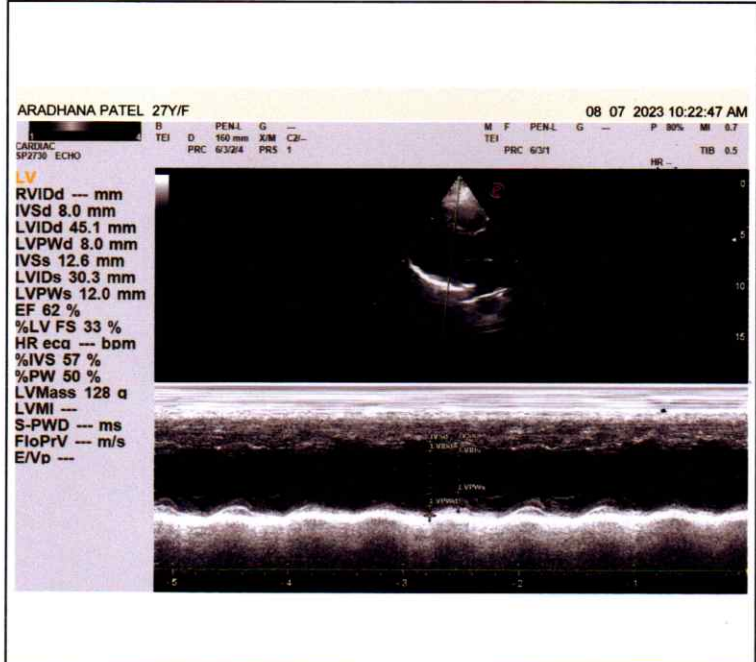
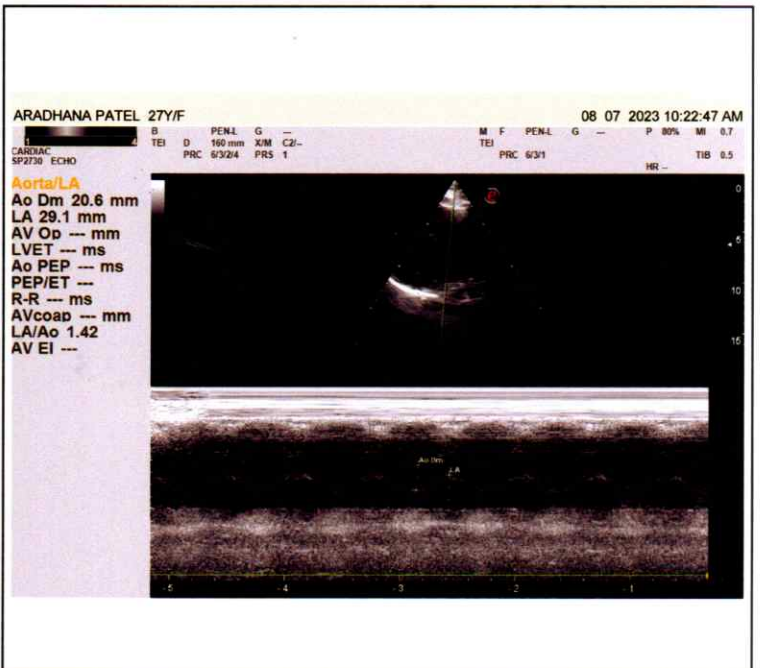
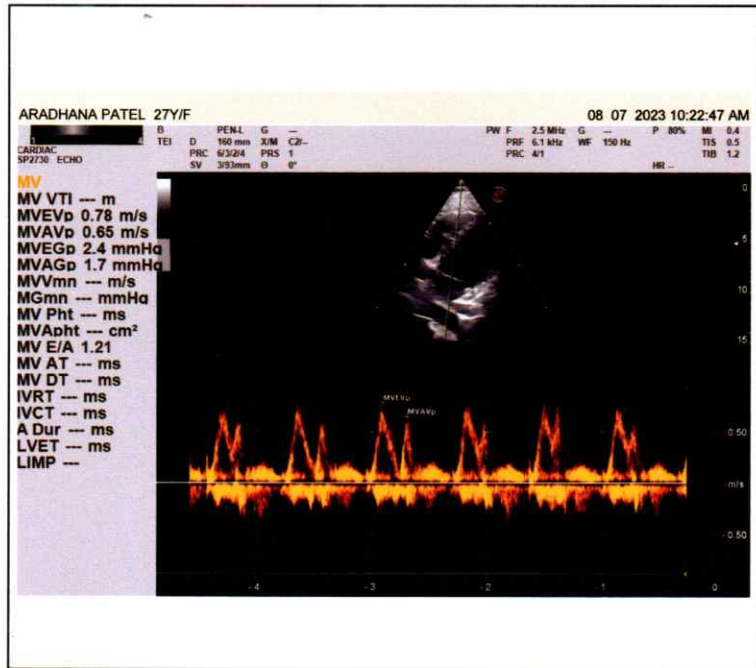

Niraj Mishra
Physician Assistant
(PIIRE)

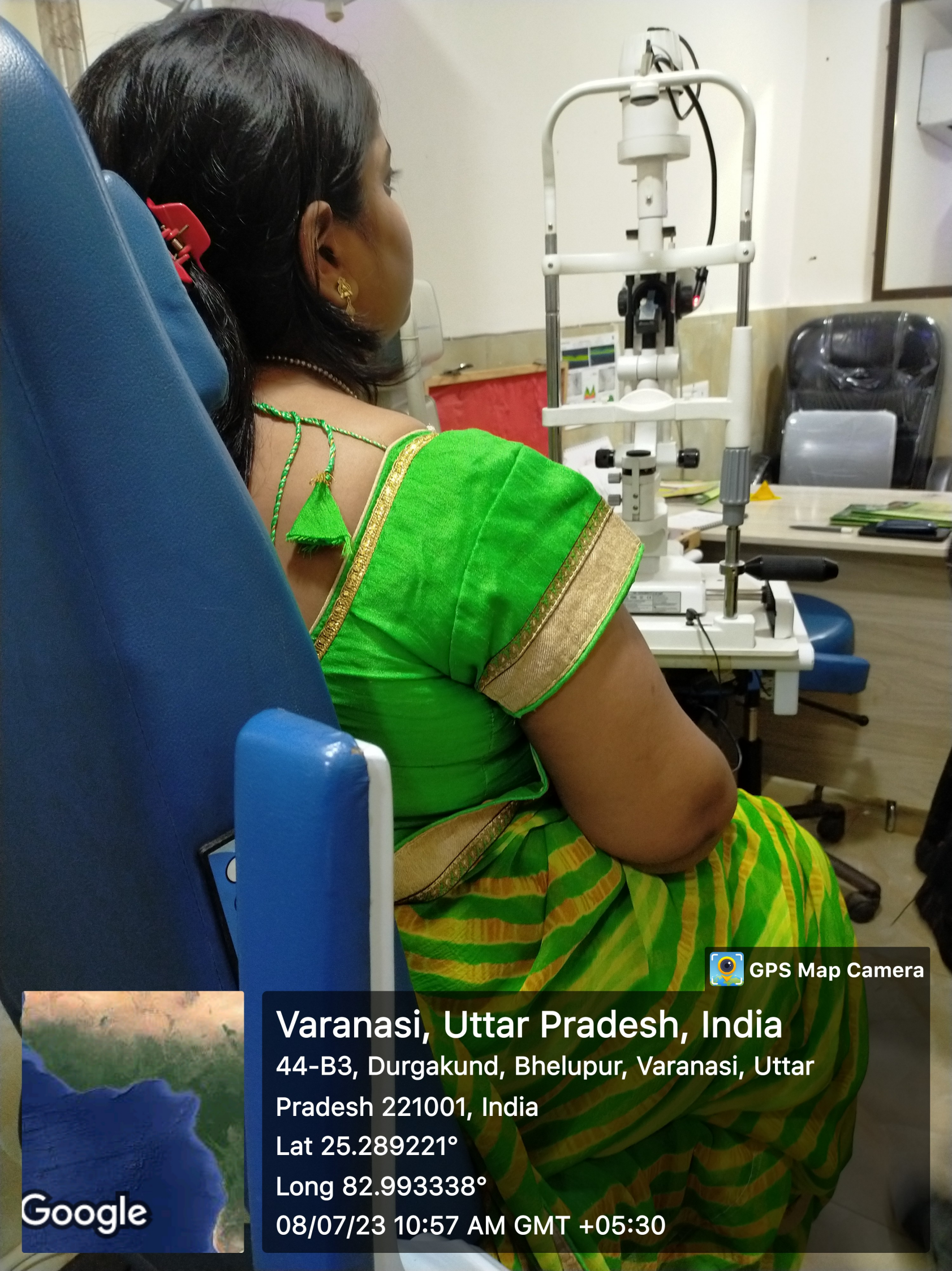
Dr. Pallavi Mishra
MBBS, MD (MED) Lucknow
Echocardiography Specialist, MIAE
Non-invasive cardiologist
Women Cardiologist
Diabetocardiologist

Address : Kabir Nagar (Near Sanjay Shiksha Niketan), Durgakund, Varanasi

Mobile : 9554572190 / 9453837595 / Recpn. 9389994334

E-mail : dramishra@gmail.com, drpallaviojha@gmail.com, Website: www.piire.org





GPS Map Camera

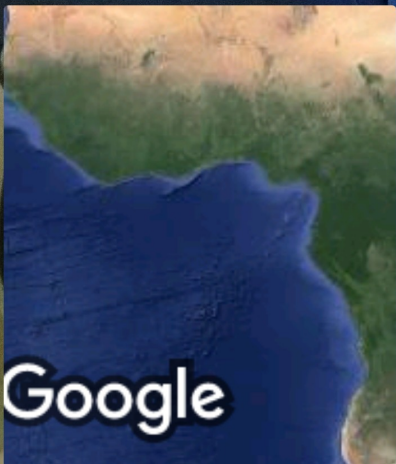Varanasi, Uttar Pradesh, India

44-B3, Durgakund, Bhelupur, Varanasi, Uttar Pradesh 221001, India

Lat 25.289221°

Long 82.993338°

08/07/23 10:57 AM GMT +05:30



Google

08.07.2023

171 Aradhama Singh CBC HB 10.0
= 24.0 TC 6.400
BOB CYOFA CAT T 0.72 ABO "A" P 52
= BUN 10.2 D 0.28 R4 Positive L 43
U/A 3.98 20.44 RBS 104.7 E 03
HBADL 5.3 OF 26.0 PPBS W 02
T3 0.83 PT 23.0 CHO 164.0 ALT 1.71
T4 5.16 GGT 19.0 TG 148.0 PCV 33.1
TSH 7.58 ALK 72.0 UOL 41.0 RBC 3.68
SU - Nil TP 7.42 ZOL 93.4 MW 89.8
PRO - Nil ALB 4.12 UOL 29.6 MW 27.2
PY - Not 6.0 GIB 3.32 MCHC 30.3
SMA 1.010
PC - 02-03
BP - 02-02

CBC HB 15.3



GPS Map Camera



Varanasi, Uttar Pradesh, India

44-B3, Durgakund, Bhelupur, Varanasi, Uttar Pradesh 221001, India

Lat 25.289218°

Long 82.993345°

08/07/23 08:46 AM GMT +05:30

Panacea Hospital

A Shelter For Many Heart
Home For Many Lives

Diabetes Care Organisation



ओ. पी. डी. पंजीकरण
O.P.D. REGISTRATION

IPD BILLING

GPS Map Camera



Varanasi, Uttar Pradesh, India
44-B3, Durgakund, Bhelupur, Varanasi, Uttar Pradesh 221001, India
Lat 25.289216°
Long 82.993353°
08/07/23 09:05 AM GMT +05:30



Call Now - 1800-123-3070

PANACEA HOSPITAL

A shelter for many hearts A Home for many lives

(An ISO 9001:2008 Certified Organisation)

Lab Attached with CMC Vellore Under EQAS Scheme

PATIENT'S NAME : MRS.ARADHANA PATEL	AGE/SEX: 27 Y/F
REF. BY : Dr. ASHUTOSH MISHRA (MD)	Saturday, July 08, 2023

U/S. WHOLE ABDOMEN

- LIVER** : Liver is normal in size 132mm, **Diffuse increased echogenicity of liver parenchyma - Grade I fatty liver.** Intra hepatic biliary radicals are normal. Portal venous channels are normal.
- G. B.** : Gall bladder is normal in size, lumen is clear. Wall thickness normal.
- C.B.D.** : C.B.D. is normal in caliber.
- PANCREAS** : Pancreas is normal in size, shape and echotexture. No evidence of any inflammatory disease or mass.
- SPLEEN** : Spleen is normal in size, shape and echotexture.
- Rt. KIDNEY** : Normal in size, shape and echotexture. Renal sinus is normal
Cortico medullary differentiation is normal. P. C. system is normal.
- Lt. KIDNEY** : Normal in size, shape and echotexture. Renal sinus is normal
Cortico medullary differentiation is normal. P. C. system is normal.
- URI. BLADDER** : Urinary bladder is normal in size, position. Wall thickness normal.
No evidence of calculus or mass.
- UTERUS** : Normal in size. shape & echotexture. Endometrial echo is normal(5.4mm).
- OVARIES** : Rt. Ovary:- Normal in size.
Lt. Ovary:-Normal in size.
No free fluid seen in P. O. D.

IMPRESSION :

- **GRADE I FATTY LIVER.**

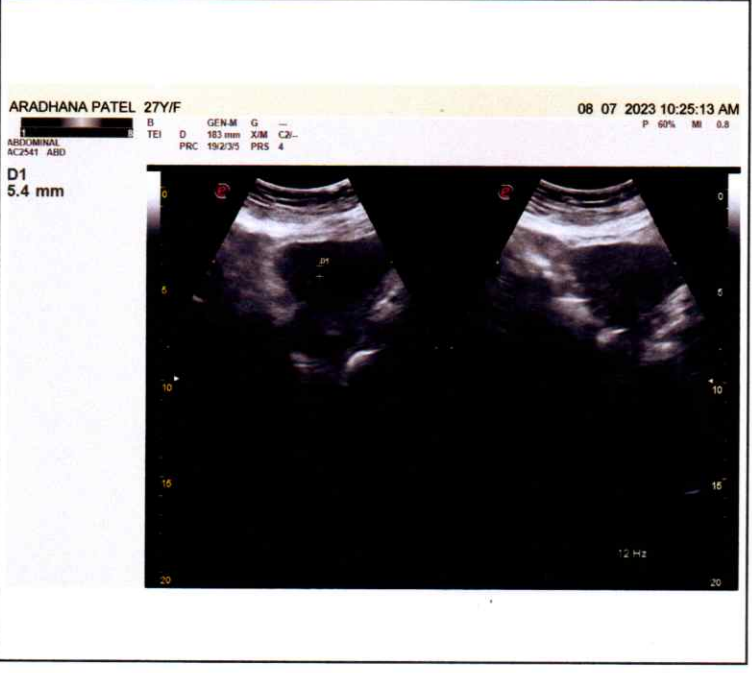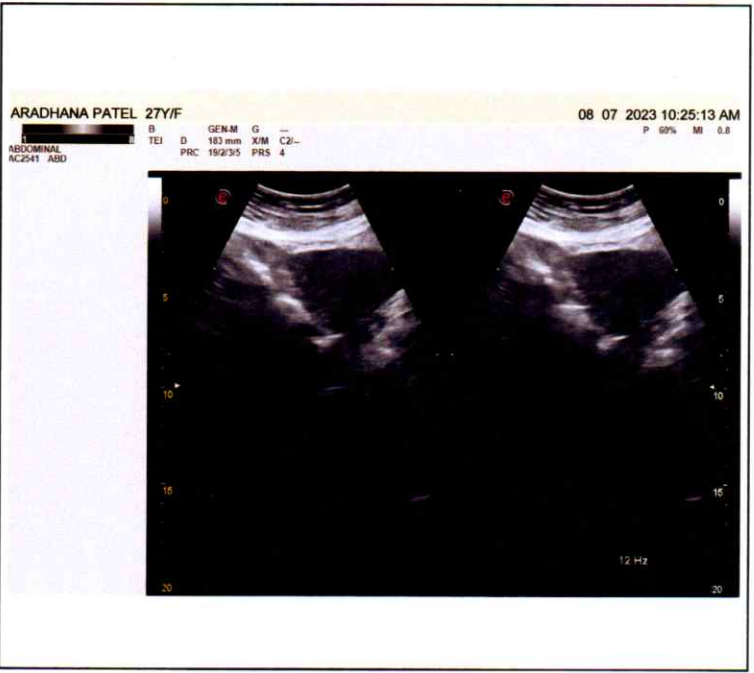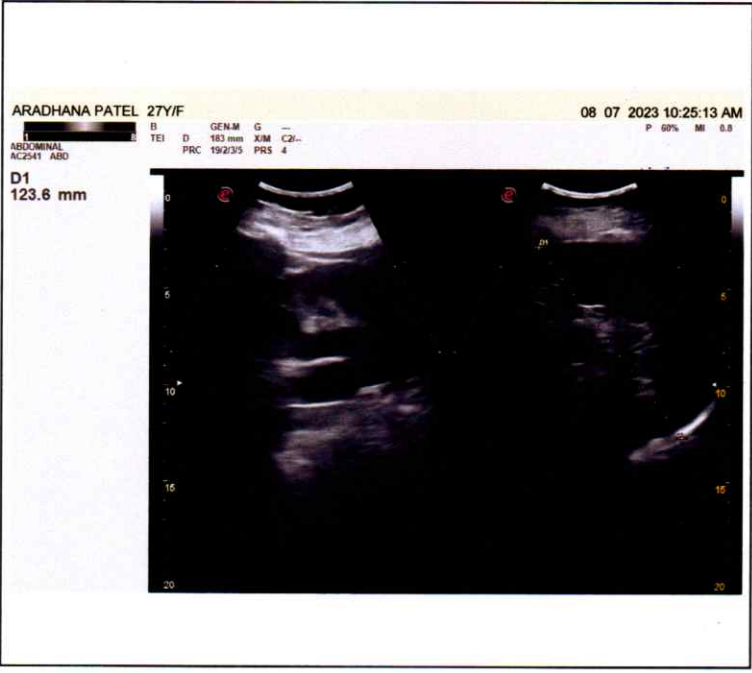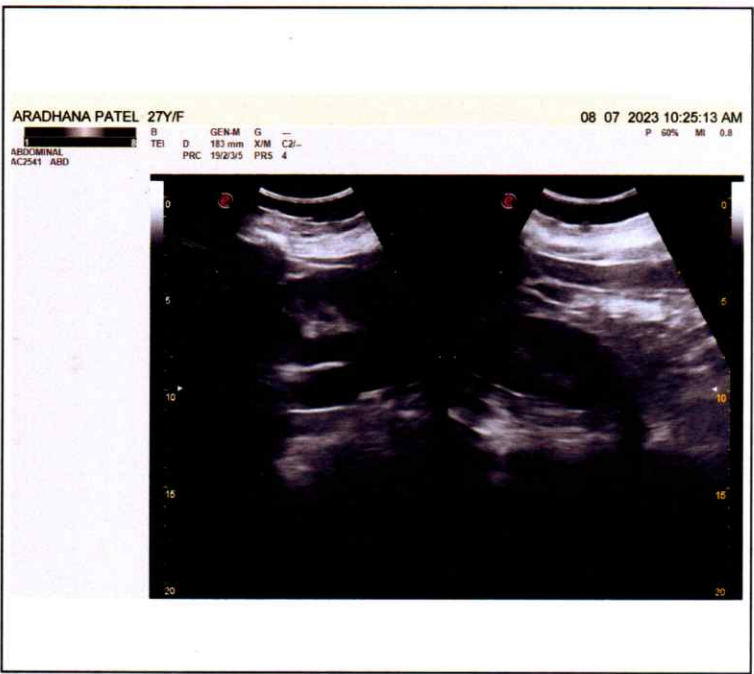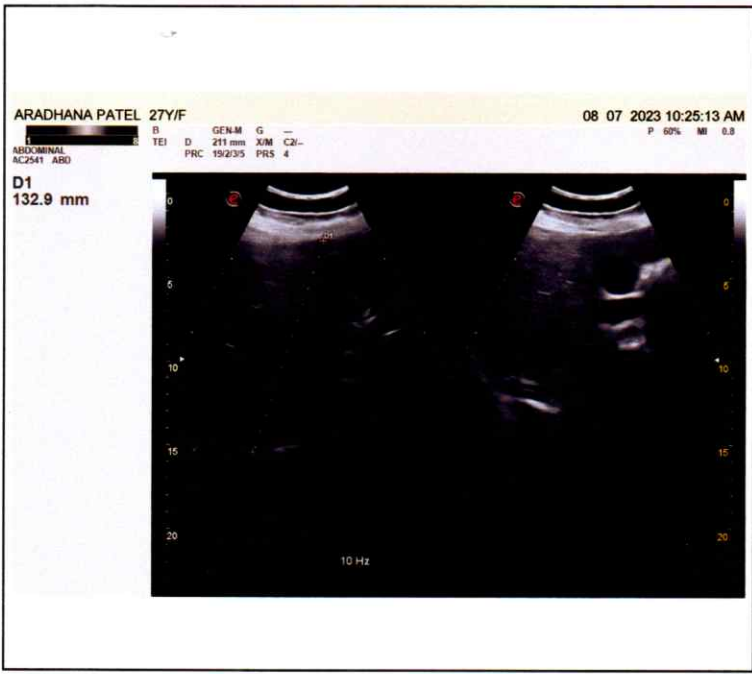
Thanks for reference.

Radiologist

Address : Kabir Nagar (Near Sanjay Shiksha Niketan), Durgakund, Varanasi

Mobile : 9554572190 / 9453837595 / Recpn. 9389994334

E-mail : dramishra@gmail.com, drpallaviojha@gmail.com, Website: www.piire.org





Call Now - 1800-123-3070

PANACEA HOSPITAL

A shelter for many hearts A Home for many lives

(An ISO 9001:2008 Certified Organisation)

Lab Attached with CMC Vellore Under EQAS Scheme

PATIENT'S NAME : MRS.ARADHANA PATEL
REF. BY : Dr. ASHUTOSH MISHRA (MD)

AGE/SEX: 27 Y/F
Saturday, July 08, 2023

X-RAY CHEST PA

BOTH LUNG FIELDS AND PLEURAE:

Both lungs show normal bronchovascular pattern.

Right & left hila are normal

No focal mass or calcification is seen

There is no evidence of any fluid in the both the pleural cavities.

Both domes of diaphragms are normal in position.

MEDIASTINUM:

Trachea is central in position.

Cardiac silhouette is of normal size and configuration.

No evidence of pericardial effusion.

No significant lymphadenopathy is seen.

Visualized skeleton is normal.

NO SIGNIFICANT RADIOGRAPHIC ABNORMALITY.

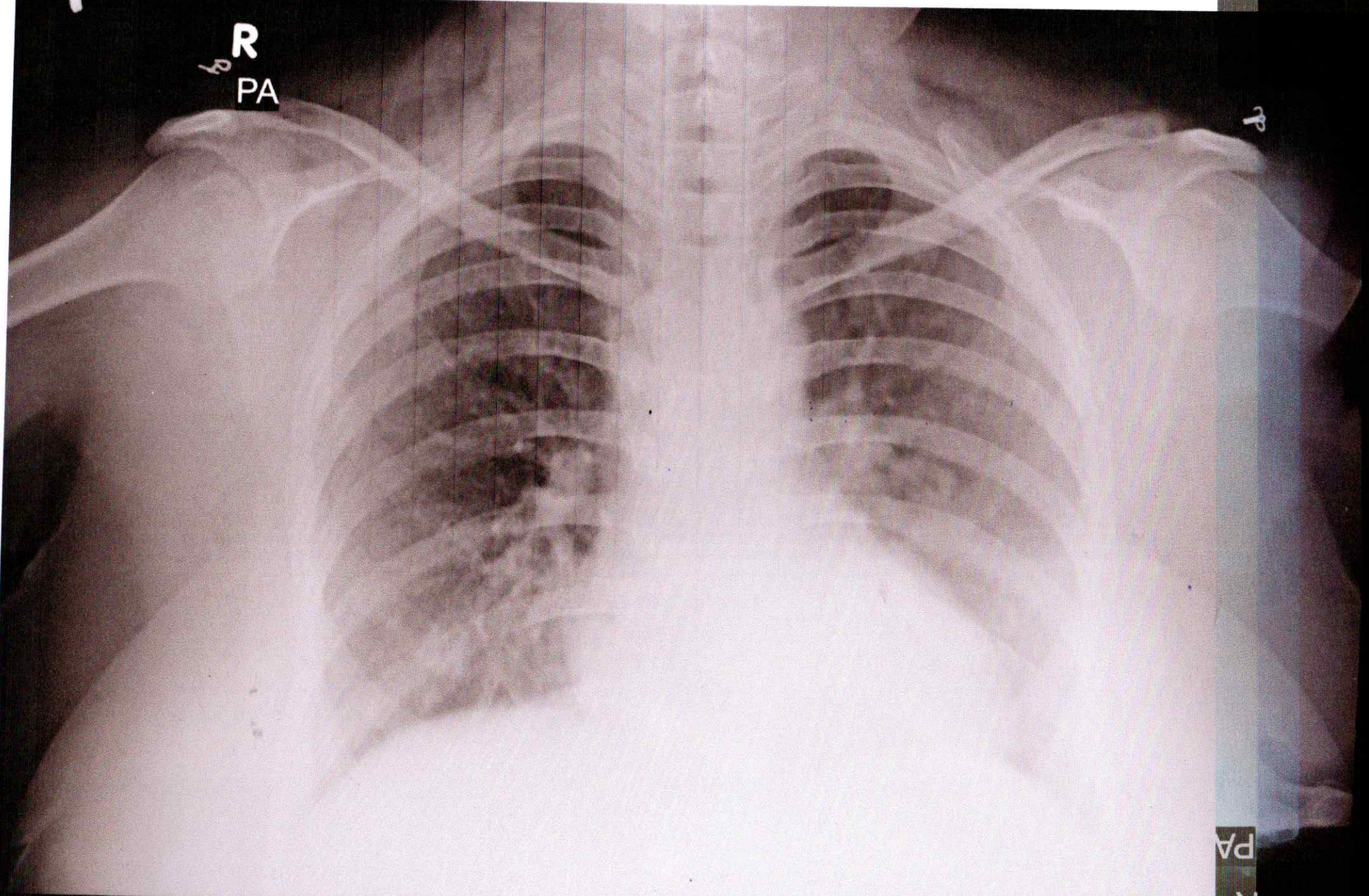

Radiologist

Address : Kabir Nagar (Near Sanjay Shiksha Niketan), Durgakund, Varanasi

Mobile : 9554572190 / 9453837595 / Recpn. 9389994334

E-mail : dramishra@gmail.com, drpallaviojha@gmail.com, Website: www.piire.org

R
PA



PA
R

ARADHANA PATEL 27Y/F 1413 O CHEST P.A. 08-Jul-23 10:48 AM

PANACEA HOSPITAL, KABIR NAGAR, DURGAKUND, VARANASI