

Health Check up Booking Request(bobS9772),Package Code(PKG10000243),Beneficiary Code(21506)

1 message

Mediwheel <santosh@policywheel.com>

10 March 2022 at 12:18

To: "vidhidiagnostics@gmail.com" <vidhidiagnostics@gmail.com>

Cc: Mediwheel CC <customercare@mediwheel.in>, Mediwheel CC <mediwheelwellness@gmail.com>

**Mediwheel**
...Your wellness partner**011-41195959****Email:wellness@mediwheel.in**

Dear Vidhi Diagnostics,
City : Ahmedabad . Location : .New Wadaj,

We have received the following request for Health Check up from

Name : Meenakshi nagpal
Age : 42
Gender : Female
Member Relations : Spouse
Package Name : Metro Full Body Health Checkup Female Above 40
Package Code : PKG10000243
User Location : Gujarat,AHMEDABAD,380001
Contact Details : 8905905955
Booking Date : 10-03-2022
Appointment Date : 14-03-2022

Member Information			
Booked Member Name	Age	Gender	Cost(In INR)
Meenakshi nagpal	42	Female	Cashless
Total amount to be paid			Cashless

Please login to your account to confirm the same. Also you mail us for confirmation

Package Name : Metro Full Body Health Checkup Female Above 40 - Includes (41)Tests

Tests included in this Package : Ecg, TSH, X-ray Chest, Stress Test (tmt)/ 2d Echo, GyneC Consultation, Blood Sugar Postprandial, Dental Consultation, A:g Ratio, Blood Group, Total Cholesterol, Triglycerides, Pap Smear, Fasting Blood Sugar, Ultrasound Whole Abdomen , Glycosylated Haemoglobin (hba1c), Mammography, Hdl, Vldl, Urine Analysis, LDL, Total Protine, General Consultation, HDL/ LDL ratio, GGT(Gamma-glutamyl Transferase), Eye Check-up consultation, ALP (ALKALINE PHOSPHATASE), Uric Acid, AST/ALT Ratio, Serum Protein, CBC with ESR, Stool Analysis, Urine Sugar Fasting, Urine Sugar PP, T3, T4, Cholesterol Total / HDL Ratio, BUN, BUN/Creatinine Ratio, Bilirubin Total & Direct and Indirect, Albumin, Globulin

PRE EMPLOYMENT HEALTH SCREENING

Date : 12/3/2022

1. Personal Particulars

Name : Maanalkshi Nagpal NRIC No : _____

Age : 42 years Gender : Male / Female

Marital Status : married

Past & Present Medical History : yes Hb thyroid since 948
taking tab thyronorm od

Family Medical History : no

Allergy : no

2. Clinical Medical Examination

Height : 159 cm Weight : 83 kg kg

Blood Pressure : 122/82 mmHg Pulse : 100 p/min

Vision : Uncorrected : (R) normal (L) normal with spectacles Corrected : (R) _____ (L) _____

Colour Vision : Normal / Colour Blind

General Condition : _____ Skin : _____

Central Nervous System : normal Head & Neck : normal

Cardiovascular System : _____ Chest : _____

Abdomen : _____ Limbs : _____

Last menstrual period : 28-2-2022

3. Investigations

Chest X-Ray : As per Attached report

I, the undersigned hereby authorize the doctor to release my medical check-up

Maanalkshi

Signature of applicant

Remarks : Fit / Unfit for employment

Dr. Vidhi D. Modh
MBBS
Reg. No. 6-74540

Dr's name, signature & chop

<< Analysis Result >>

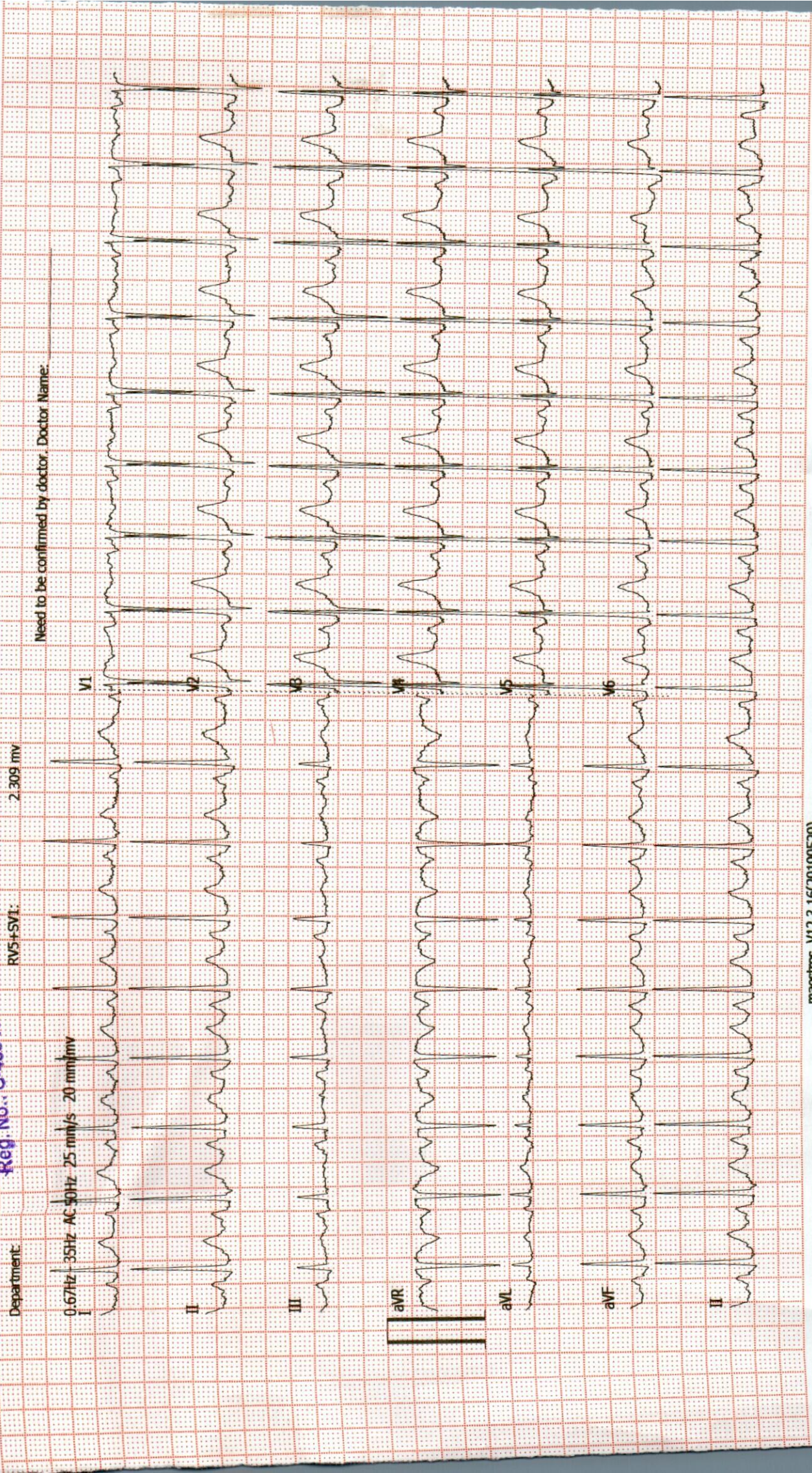
** abnormal ECG **
Sinus tachycardia

HR : 101 bpm
PR : 154 ms
QRS : 74 ms
QT/QTc : 328/424 ms
P/QRS/T : 56/47/65 deg.
RV5/SV1 : 1.529/-0.780 mv
RV5+SV1 : 2.309 mv

Need to be confirmed by doctor. Doctor Name:

ID: 4142
Name: meenakshi nagpal
Age: 42yrs
Sex: Female
Hospital: **Dr. Avinash Bhaskar**
MBBS, D Cardio

Reg. No.: G-45946



Dr. Dinesh S. Modh

M.D., D.M.R.E. (Radiodiagnosis)

Consultant Radiologist & Sonologist

Ex. Junior Lecturer, B.J. Medical College, Civil Hospital, A'bad.

Panel Doctor of L.I.C.



Patient's name : MEENAKSHI NAGPAL

Reg. ID : R-12292-21

Referred by : Dr. MEDIWHEEL

Age/Sex : 42 Years/Female

Accession : 9837

Date : 12/03/2022

Report of ECG

Conclusion

- Sinus tachycardia.
- HR - 100/per minute.
- Normal PR interval.
- Normal QRS interval.
- Normal QT interval.

Dr. Avinash Bhaskar

MBBS, D Cardiol

Reg. No.: G-45946

DR.AVINASH BHASKAR

ISO 9001:2015 Certified Diagnostics Center

Vidhi Imaging Center

L-86, Swatantra Senani Nagar, Opp. Akhbarnagar Petrol Pump, Nr. Akhbarnagar Circle, Nava-Vadaj, Ahmedabad - 380 013.

Phone : 079-2762 1406, Mobile : 98799 29406, 98250 09406, E-mail : vidhidiagnostics@gmail.com, Website : www.vidhidiagnostics.com

Time : Mon. to Sat. 9.00 am to 2.00 pm, 5.00 pm to 9.00 pm, Sunday 9.00 am to 12.00 Noon

FACILITIES : Live 3D-4D Sonography | Colour Doppler | Echo Cardiography | Interventional Radiology | Fetal Medicine | Digital X-Ray
Digital Mammography | Digital OPG/TMJ | ECG/TMT/PFT/EEG/EMG | Pathology Laboratory | Health Check Up Plans | Pre Employment Check Up

Dr. Dinesh S. Modh

M.D., D.M.R.E. (Radiodiagnosis)

Consultant Radiologist & Sonologist

Ex. Junior Lecturer, B.J. Medical College, Civil Hospital, A'bad.

Panel Doctor of L.I.C.



Patient's name: MEENAKSHI NAGPAL
Reg. ID : R-12292-21
Referred by : Dr. MEDIWHEEL

Age/Sex : 42 Years/Female
Accession : 9837
Date : 12/03/2022

X-RAY CHEST (PA VIEW)

Both lung fields appear normal.
No e/o consolidation or cavitations is seen.
Both costo-phrenic angles appear clear.
Cardiac size is within normal limits.
Both domes of diaphragm appear normal.
Bony thoracic cage appears normal.

Thanks for reference.

Dr. Dinesh S. Modh
MD DMRE (Radiodiagnosis)
DR DINESH S. MODH
M.D. DMRE(RADIODIAGNOSIS)

ISO 9001:2015 Certified Diagnostics Center

Vidhi Imaging Center

L-86, Swatantra Senani Nagar, Opp. Akhbarnagar Petrol Pump, Nr. Akhbarnagar Circle, Nava-Vadaj, Ahmedabad - 380 013.

Phone : 079-2762 1406, Mobile : 98799 29406, 98250 09406, E-mail : vidhidiagnostics@gmail.com, Website : www.vidhidiagnostics.com

Time : Mon. to Sat. 9.00 am to 2.00 pm, 5.00 pm to 9.00 pm, Sunday 9.00 am to 12.00 Noon

FACILITIES : Live 3D-4D Sonography | Colour Doppler | Echo Cardiography | Interventional Radiology | Fetal Medicine | Digital X-Ray
Digital Mammography | Digital OPG/TMJ | ECG/TMT/PFT/EEG/EMG | Pathology Laboratory | Health Check Up Plans | Pre Employment Check Up

Dr. Dinesh S. Modh

M.D., D.M.R.E. (Radiodiagnosis)

Consultant Radiologist & Sonologist

Ex. Junior Lecturer, B.J. Medical College, Civil Hospital, A'bad.

Panel Doctor of L.I.C.



Patient's name: MEENAKSHI NAGPAL

Reg. ID : R-12292-21

Referred by : Dr. MEDIWHEEL

Age/Sex : 42 Years/Female

Accession : 9837

Date : 12/03/2022

DIGITAL MAMMOGRAPHY

Digital mammography was done on Siemens mammomat-3000.

Reason for exam: - Screening.

Bilateral digital cranio-caudal and medio-lateral oblique views were taken.
The breast tissue is homogeneously dense with fibro-fatty tissue on both sides.
No masses, no architectural distortion, no suspicious calcifications, no asymmetries or other abnormalities are seen.
No e/o radio-opaque or radiolucent mass lesion is seen.
No e/o skin thickening is seen.
Nipple and sub-areolar tissue appear normal.
Axillary tail appears normal.

USG:-Normal.

Assessment:-Negative (BI-RADS category-1)

BI-RADS category

- 0- incomplete
- 1- Negative
- 2- Benign
- 3- Probably benign
- 4- Suspicious abnormality.
- 5- Highly suggestive of malignancy
- 6- Known biopsy-proven malignancy.

The false negative mammography is approximately 10%. Management of palpable abnormality must be based upon clinical grounds.

Thanks for reference.

Dr. Dinesh S. Modh

MD DMRE (Radiodiagnosis)

DR DINESH S. MODH

M.D. DMRE(RADIODIAGNOSIS)

ISO 9001:2015 Certified Diagnostics Center

Vidhi Imaging Center

L-86, Swatantra Senani Nagar, Opp. Akhbarnagar Petrol Pump, Nr. Akhbarnagar Circle, Nava-Vadaj, Ahmedabad - 380 013.

Phone : 079-2762 1406, Mobile : 98799 29406, 98250 09406, E-mail : vidhidiagnostics@gmail.com, Website : www.vidhidiagnostics.com

Time : Mon. to Sat. 9.00 am to 2.00 pm, 5.00 pm to 9.00 pm, Sunday 9.00 am to 12.00 Noon

FACILITIES : Live 3D-4D Sonography | Colour Doppler | Echo Cardiography | Interventional Radiology | Fetal Medicine | Digital X-Ray
Digital Mammography | Digital OPG/TMJ | ECG/TMT/PFT/EEG/EMG | Pathology Laboratory | Health Check Up Plans | Pre Employment Check Up

Dr. Dinesh S. Modh

M.D., D.M.R.E. (Radiodiagnosis)

Consultant Radiologist & Sonologist

Ex. Junior Lecturer, B.J. Medical College, Civil Hospital, A'bad.

Panel Doctor of L.I.C.



Patient's name : MEENAKSHI NAGPAL
Reg. ID : R-12292-21
Referred by : Dr. MEDIWHEEL

Age/Sex : 42 Years/Female
Accession : 9837
Date : 12/03/2022

USG ABDOMEN

LIVER:- Liver shows normal in size & normal echotexture. No e/o diffuse or focal lesion is seen. IHBR appear normal. PV & CBD (4mm) appears normal. No e/o calculus is seen in bile duct.

GALL BLADDER:- Gall bladder is distended and shows single mobile calculus measures 15mm. GB wall thickness appears normal.

SPLEEN:- Spleen appears normal in size & shows normal echotexture. No evidence of diffuse or focal lesion is seen.

PANCREAS:- Pancreas appears normal size and echopattern. No e/o diffuse or focal lesion is seen. Main pancreatic duct appears normal.

KIDNEY:- Both Kidneys appear normal in size & echotexture. No e/o calculus or hydronephrosis or hydroureter is seen in both sides. Cortico-medullary differentiation is maintained on either side.

Both suprarenal regions appear normal. No evidence of pre & para aortic lymphadenopathy is seen.

No evidence of free fluid is seen in abdomen. No evidence of dilated or thickened bowel loops is seen.

Urinary bladder:- appear normal. No e/o calculus or mass lesion is seen in bladder.

Uterus is bulky and shows 55x60mm sub-serous fibroid in body of uterus.

Both adenexal regions appear normal.

No e/o free fluid is seen in pouch of Douglas.

-
Thanks for reference.

Dr. Dinesh S. Modh
MD DMRE (Radiodiagnosis)
G-23825

DR DINESH S. MODH

M.D. DMRE(RADIODIAGNOSIS)

ISO 9001:2015 Certified Diagnostics Center

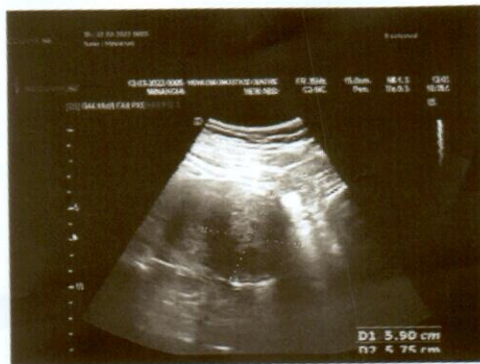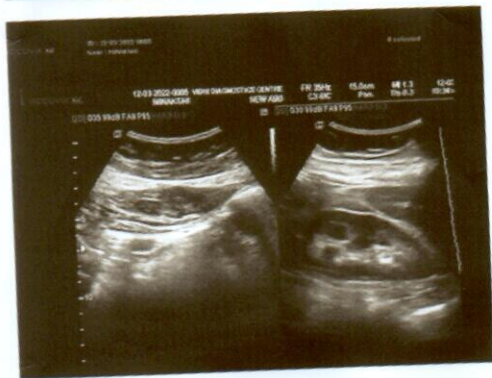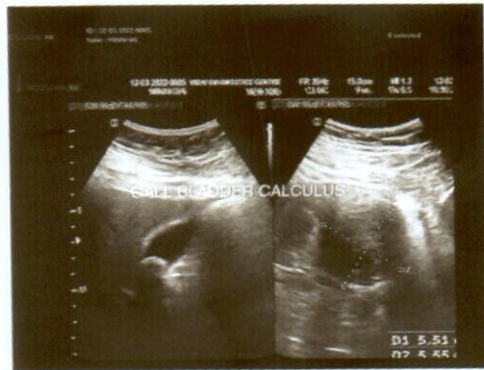
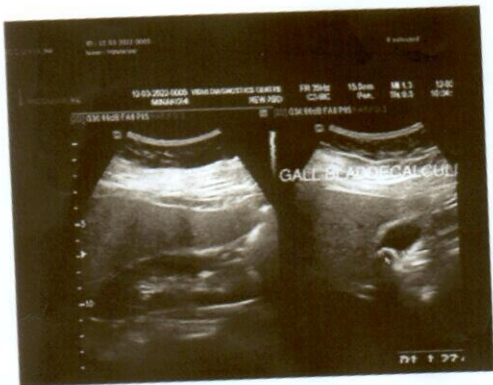Vidhi Imaging Center

L-86, Swatantra Senani Nagar, Opp. Akhbarnagar Petrol Pump, Nr. Akhbarnagar Circle, Nava-Vadaj, Ahmedabad - 380 013.

Phone : 079-2762 1406, Mobile : 98799 29406, 98250 09406, E-mail : vidhidiagnostics@gmail.com, Website : www.vidhidiagnostics.com

Time : Mon. to Sat. 9.00 am to 2.00 pm, 5.00 pm to 9.00 pm, Sunday 9.00 am to 12.00 Noon

FACILITIES : Live 3D-4D Sonography | Colour Doppler | Echo Cardiography | Interventional Radiology | Fetal Medicine | Digital X-Ray
Digital Mammography | Digital OPG/TMJ | ECG/TMT/PFT/EEG/EMG | Pathology Laboratory | Health Check Up Plans | Pre Employment Check Up



Dr. Dinesh S. Modh

M.D., D.M.R.E. (Radiodiagnosis)
Consultant Radiologist & Sonologist
Ex. Junior Lecturer, B.J. Medical College, Civil Hospital, A'bad.
Panel Doctor of L.I.C.



Patient's name : MEENAKSHI NAGPAL
Reg. ID : R-12292-21
Referred by : Dr. MEDIWHEEL

Age/Sex : 42 Years/Female
Accession : 9837
Date : 12/03/2022

2D- ECHO REPORT

FINAL CONCLUSION:

LV IS NORMAL SIZE. GOOD LV SYSTOLIC FUNCTION NO RWMA.
LVEF - 60%. NO CONCENTRIC LVH.
NORMAL LV COMPLIANCE.
LA IS NORMAL SIZE. NO LA CLOT.
RV IS NORMAL SIZE. GOOD RV SYSTOLIC FUNCTION.
RA IS NORMAL SIZE.
MITRAL VALVE IS NORMAL. NO MS. NO MR. NO MVP.
AORTIC VALVE IS NORMAL. NO AS. NO AR.
TRICUSPID VALVE IS NORMAL. NO TR. RVSP-26 mmHg. NO PAH.

NO CLOT, NO VEGETATION, NO PERICARDIAL EFFUSION.

DIMENSIONS:

AORTA	2.6 C.M
LEFT ATRIUM	2.7 C.M
LVDD	4.1 C.M.
IVSD	1.0 C.M
PWD	1.0 C.M
LVDS	2.6 C.M.

COLOUR DOPPLER FINDING:

STRUCTURE	VELOCITY m/sec
	Max
PULMONARY VALVE	0.7
MITRAL VALVE	E : 0.7 A: 0.4
AORTIC VALVE	1.0

Dr. Avinash Bhaskar
MBBS, D Cardio
Reg. No.: G-45946
DR AVINASH BHASKAR

ISO 9001:2015 Certified Diagnostics Center

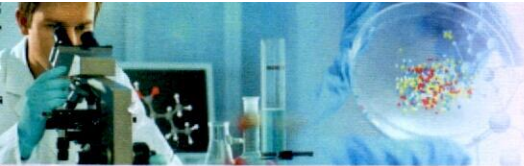Vidhi Imaging Center

L-86, Swatantra Senani Nagar, Opp. Akhbarnagar Petrol Pump, Nr. Akhbarnagar Circle, Nava-Vadaj, Ahmedabad - 380 013.

Phone : 079-2762 1406, Mobile : 98799 29406, 98250 09406, E-mail : vidhidiagnostics@gmail.com, Website : www.vidhidiagnostics.com

Time : Mon. to Sat. 9.00 am to 2.00 pm, 5.00 pm to 9.00 pm, Sunday 9.00 am to 12.00 Noon

FACILITIES : Live 3D-4D Sonography | Colour Doppler | Echo Cardiography | Interventional Radiology | Fetal Medicine | Digital X-Ray
Digital Mammography | Digital OPG / TMJ | ECG / TMT / PFT / EEG / EMG | Pathology Laboratory | Health Check Up Plans | Pre Employment Check Up



Patient's name : MEENAKSHI NAGPAL
 Age/Sex : 42 Years/Female
 Referred by : -
 Collection Time : 09:31

Reg. ID : P-8412-21
 Accession : 9827
 Order Dt/time : 12/03/2022 09:31

Complete Blood Count

Sample Type: EDTA

Test Name	Result	Units	Biological Reference Interval
<u>Blood Counts</u>			
Haemoglobin :	12.0	Gms%	12.5 - 16.0
Total R.B.C. :	4.28	mill/c.mm	4.2 - 5.4
Total W. B. C. :	6,990	/cu mm	4000 - 10500
Platelet Count :	3,94,000	/cu.mm	1,50,000 - 4,50,000
<u>Differential Count</u>			
Neutrophils :	65	%	40 - 70
Lymphocytes :	30	%	20 - 40
Eosinophils :	03	%	1 - 4
Monocytes :	02	%	2 - 6
Basophils :	00	%	0 - 01
<u>Blood Indices</u>			
P. C. V :	36.6	%	37 - 47
M. C. V. :	85.4	fl	78 - 100
M.C.H :	28.1	pg	27 - 31
M. C. H. C. :	32.9	%	32 - 36
R.D.W :	15.7	%	11.5 - 14.0
<u>E.S.R.(Westergren Method)</u>			
After one hour :	06	mm/hr	3 - 12

TESTS DONE ON FULLY AUTOMATED HEMATOLOGY ANALYZER.

Dr. Gayatri M. Mehta

M. D. (Patho)

Reg. No. G-32215

DR GAYATRI MEHTA
 MD(PATHOLOGY)

DR. ANAND D. PARIKH
 MD(PATHOLOGY)

LAB USE ONLY (Entered by :GM Enter Date/Time:12/03/2022 12:26:00) (Verify by :GM Verify Date/Time:12/03/2022 12:26:00)

ISO 9001:2015 Certified Diagnostics Center

Vidhi Imaging Center | Pathology Department

L-86, Swatantra Senani Nagar, Opp. Akhbarnagar Petrol Pump, Nr. Akhbarnagar Circle, Nava-Vadaj, Ahmedabad - 380 013.

Ph. (Pathology) : 079-2764 5405, 8849893954 M. 98799 29406, 98250 09406, E-mail : vidhidiagnostics@gmail.com, Web. : www.vidhidiagnostics.com

Time (Pathology) : Mon. to Sat. 8.30 am to 8.00 pm, Sunday 9 am to 12 Noon

Pathology means science behind medicine

CT SCAN & CBCT FACILITY NOW AVAILABLE



Pathology Department



Patient's name : MEENAKSHI NAGPAL
Age/Sex : 42 Years/Female
Referred by : -
Collection Time : 09:31

Reg. ID : P-8412-21
Accession : 9827
Order Dt/time : 12/03/2022 09:31

Blood Group

Sample Type: ~~EDTA~~ sample.

Test Name	Result
BG :	" O "
RH :	POSITIVE
Remarks	Done by forward grouping method.

Dr. Gayatri M. Mehta
M. D. (Patho)

Reg. No. G-32215
DR GAYATRI MEHTA
MD(PATHOLOGY)

DR. ANAND D. PARIKH
MD(PATHOLOGY)

LAB USE ONLY (Entered by :GM Enter Date/Time:12/03/2022 16:39:00) (Verify by :GM Verify Date/Time:12/03/2022 16:39:00)

ISO 9001:2015 Certified Diagnostics Center

Vidhi Imaging Center | Pathology Department

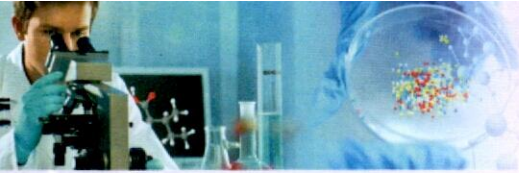L-86, Swatantra Senani Nagar, Opp. Akhbarnagar Petrol Pump, Nr. Akhbarnagar Circle, Nava-Vadaj, Ahmedabad - 380 013.

Ph. (Pathology) : 079-2764 5405, 8849893954 M. 98799 29406, 98250 09406, E-mail : vidhidiagnostics@gmail.com, Web. : www.vidhidiagnostics.com

Time (Pathology) : Mon. to Sat. 8.30 am to 8.00 pm, Sunday 9 am to 12 Noon

Pathology means science behind medicine

CT SCAN & CBCT FACILITY NOW AVAILABLE



Patient's name : MEENAKSHI NAGPAL
 Age/Sex : 42 Years/Female
 Referred by : -
 Collection Time : 09:31

Reg. ID : P-8412-21
 Accession : 9827
 Order Dt/time : 12/03/2022 09:31

Blood Glucose

Sample Type: Serum

Test Name	Result	Units	Biological Reference Interval
Fasting Blood Glucose :	107.9	mg/dl	70 - 110
<i>GOD-POD Method.</i>			

Blood Glucose

Sample Type: Serum

Test Name	Result	Units	Biological Reference Interval
Post Prandial Blood Glucose After 2hr. :	<u>124.4</u>	mg/dl	80 - 140
<i>GOD-POD Method.</i>			

Dr. Gayatri M. Mehta

M. D. (Patho)

Reg. No. G-32215

DR GAYATRI MEHTA
MD(PATHOLOGY)

DR. ANAND D. PARIKH
MD(PATHOLOGY)

LAB USE ONLY (Entered by :GM Enter Date/Time:12/03/2022 16:39:00) (Verify by :GM Verify Date/Time:12/03/2022 16:39:00)

ISO 9001:2015 Certified Diagnostics Center

Vidhi Imaging Center | Pathology Department

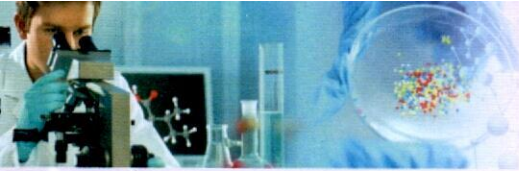L-86, Swatantra Senani Nagar, Opp. Akhbarnagar Petrol Pump, Nr. Akhbarnagar Circle, Nava-Vadaj, Ahmedabad - 380 013.

Ph. (Pathology) : 079-2764 5405, 8849893954 M. 98799 29406, 98250 09406, E-mail : vidhidiagnostics@gmail.com, Web. : www.vidhidiagnostics.com

Time (Pathology) : Mon. to Sat. 8.30 am to 8.00 pm, Sunday 9 am to 12 Noon

Pathology means science behind medicine

CT SCAN & CBCT FACILITY NOW AVAILABLE



Pathology Department

Patient's name : MEENAKSHI NAGPAL
Age/Sex : 42 Years/Female
Referred by : -
Collection Time : 09:31

Reg. ID : P-8412-21
Accession : 9827
Order Dt/time : 12/03/2022 09:31

HbA1C

Sample Type: Serum

Test Name	Result	Units	Biological Reference Interval
HbA1C :	5.4	%	Non-diabetic: 4.2-6.2 Pre-diabetic : 6.3-7.2 Diabetic : 7.3-8.2
Mean Blood Glucose of Last 03 months.	108.28	mg/dl	

Comment

*As per the new 2009 update of American Diabetes Association regarding HbA1C & Mean Blood Glucose relationship.

NOTE:

This test is used to monitor diabetic patients compliance with the therapeutic regimen and logo It's level is proportional to both the average blood glucose concentration and the life span of the red blood cells (RBC) in circulation. HbA1c values are free of day to day glucose fluctuations and are unaffected by exercise or recent food intake.

Dr. Gayatri M. Mehta
M. D. (Patho)

Reg. No. G-32215

DR GAYATRI MEHTA
MD(PATHOLOGY)

DR. ANAND D. PARIKH
MD(PATHOLOGY)

LAB USE ONLY (Entered by :GM Enter Date/Time:12/03/2022 16:12:00) (Verify by :GM Verify Date/Time:12/03/2022 16:12:00)

ISO 9001:2015 Certified Diagnostics Center

Vidhi Imaging Center | Pathology Department

L-86, Swatantra Senani Nagar, Opp. Akhbarnagar Petrol Pump, Nr. Akhbarnagar Circle, Nava-Vadaj, Ahmedabad - 380 013.

Ph. (Pathology) : 079-2764 5405, 8849893954 M. 98799 29406, 98250 09406, E-mail : vidhidiagnostics@gmail.com, Web. : www.vidhidiagnostics.com

Time (Pathology) : Mon. to Sat. 8.30 am to 8.00 pm, Sunday 9 am to 12 Noon

Pathology means science behind medicine

CT SCAN & CBCT FACILITY NOW AVAILABLE



Patient's name : MEENAKSHI NAGPAL
Age/Sex : 42 Years/Female
Referred by : -
Collection Time : 09:31

Reg. ID : P-8412-21
Accession : 9827
Order Dt/time : 12/03/2022 09:31

Lipid Profile

Sample Type: Serum

Test Name	Result	Units	Biological Reference Interval
S. Cholesterol : Oxidase-esterase method.	184.0	mg/dl	0 - 200
S. Triglyceride : Enzymatic Colorimetry method	98.6	mg/dL	0 - 200
S. HDL - Cholesterol : Serum by Enzymatic method.	58.2	mg/dL	35 - 65
S. LDL - Cholesterol : Serum by Enzymatic method	106.08	mg/dL	0 - 130
S. VLDL - Cholesterol :	19.72	mg/dL	0 - 30
S. Chole/HDL.Ratio :	3.16		1 - 6
S. LDL / HDL Cholesterol Ratio :	1.82		0 - 3.5

Dr. Gayatri M. Mehta

M. D. (Patho)

Reg. No. G-32215

DR GAYATRI MEHTA
MD(PATHOLOGY)

DR. ANAND D. PARIKH
MD(PATHOLOGY)

LAB USE ONLY (Entered by :GM Enter Date/Time:12/03/2022 16:12:00) (Verify by :GM Verify Date/Time:12/03/2022 16:12:00)

ISO 9001:2015 Certified Diagnostics Center

Vidhi Imaging Center | Pathology Department

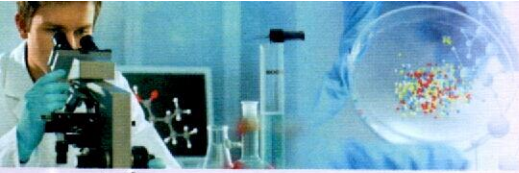L-86, Swatantra Senani Nagar, Opp. Akhbarnagar Petrol Pump, Nr. Akhbarnagar Circle, Nava-Vadaj, Ahmedabad - 380 013.

Ph. (Pathology) : 079-27615405, 8849893954 M. 98799 29406, 98250 09406, E-mail : vidhidiagnostics@gmail.com, Web. : www.vidhidiagnostics.com

Time (Pathology) : Mon. to Sat. 8.30 am to 8.00 pm, Sunday 9 am to 12 Noon

Pathology means science behind medicine

CT SCAN & CBCT FACILITY NOW AVAILABLE



Creating Life in Samples

Patient's name : MEENAKSHI NAGPAL
Age/Sex : 42 Years/Female
Referred by : -
Collection Time : 09:31

Reg. ID : P-8412-21
Accession : 9827
Order Dt/time : 12/03/2022 09:31

BIOCHEMISTRY

Sample type : Serum

Test Name	Result	Units	Biological Reference Interval
Urea, (Serum by GLDH method) :	15.7	mg/dl	10 - 50
S.Uric acid, (Serum by Uricase method) :	3.0	mg/dl	2.4-5.7
Bun :	7.3	mg/dl	6-20
Creatinine, (Serum by Enzymatic reaction) :	0.60	mg/dl	0.5-1.2
S.G.P.T (ALT) : (Serum by IFCC method)	16.6	U/L	0 - 40
S.G.O.T (AST) : (Serum by IFCC method)	21.3	U/L	0 - 37
ALK.PHOSPHATASE : (Serum by PNP method)	75.0	U/L	35-104
G.G.T :	12.3	U/L	8 - 78
<u>BILIRUBIN</u>			
Total :	0.48	mg/dl	Up to 1.2
Direct :	0.22	mg/dl	0-0.7
Indirect :	0.26	mg/dl	0 - 0.5
<u>SERUM PROTEINS</u>			
Total Protein (Serum by Biuret method) :	7.42	gms/dl	
Albumin (Serum by BCG method) :	4.33	gms/dl	3.97-4.94
Globulins :	3.09	gms/dl	2.3 - 3.5
A/G Ratio :	1.401		0.9 - 2.9

Dr. Gayatri M. Mehta

M. D. (Patho)

Reg. No. G-32215

DR GAYATRI MEHTA
MD(PATHOLOGY)

DR. ANAND D. PARIKH
MD(PATHOLOGY)

LAB USE ONLY (Entered by : GM Enter Date/Time: 12/03/2022 16:11:00) (Verify by : GM Verify Date/Time: 12/03/2022 16:11:00)

ISO 9001:2015 Certified Diagnostics Center

Vidhi Imaging Center | Pathology Department

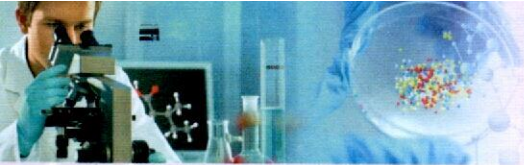486, Swatantra Senani Nagar, Opp. Akhbarnagar Petrol Pump, Nr. Akhbarnagar Circle, Nava-Vadaj, Ahmedabad - 380 013.

Ph. (Pathology) : 079-2764 5405, 8849893954 M. 98799 29406, 98250 09406, E-mail : vidhidiagnostics@gmail.com, Web. : www.vidhidiagnostics.com

Time (Pathology) : Mon. to Sat. 8.30 am to 8.00 pm, Sunday 9 am to 12 Noon

Pathology means science behind medicine

CT SCAN & CBCT FACILITY NOW AVAILABLE



Pathology Department

Patient's name : MEENAKSHI NAGPAL
Age/Sex : 42 Years/Female
Referred by : -
Collection Time : 09:31

Reg. ID : P-8412-21
Accession : 9827
Order Dt/time : 12/03/2022 09:31

Thyroid Function Test

Sample Type: Serum

Test Name	Result	Units	Biological Reference Interval
TOTAL T3 :	1.07	ng/ml	0.84 - 2.0
TOTAL T4 :	8.5	ug/dl	5.1 - 14.0
TSH(Ultra sensitive) :	3.172	mIU/L	0.27 - 4.2
Method	Electrochemiluminescence Immunoassay "ECLIA"		

Test done on Roche Cobas e411 Immunoassay Analyser

Dr. Gayatri M. Mehta

M. D. (Patho)

Reg. No. G-32215

DR GAYATRI MEHTA
MD(PATHOLOGY)

DR. ANAND D. PARIKH
MD(PATHOLOGY)

LAB USE ONLY (Entered by :GM Enter Date/Time:12/03/2022 16:12:00) (Verify by :GM Verify Date/Time:12/03/2022 16:12:00)

ISO 9001:2015 Certified Diagnostics Center

Vidhi Imaging Center | Pathology Department

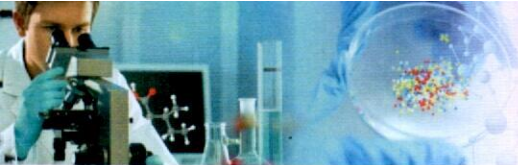L-86, Swatantra Senani Nagar, Opp. Akhbarnagar Petrol Pump, Nr. Akhbarnagar Circle, Nava-Vadaj, Ahmedabad - 380 013.

Ph. (Pathology) : 079-2764 5405, 8849893954 M. 98799 29406, 98250 09406, E-mail : vidhidiagnostics@gmail.com, Web. : www.vidhidiagnostics.com

Time (Pathology) : Mon. to Sat. 8.30 am to 8.00 pm, Sunday 9 am to 12 Noon

Pathology means science behind medicine

CT SCAN & CBCT FACILITY NOW AVAILABLE



Patient's name : MEENAKSHI NAGPAL
Age/Sex : 42 Years/Female
Referred by : -
Collection Time : 09:31

Reg. ID : P-8412-21
Accession : 9827
Order Dt/time : 12/03/2022 09:31

Urine Analysis

Sample Type: Urine

Test Name	Result	Units	Biological Reference Interval
<u>Physical Examination</u>			
Quantity :	10	ml	0 - 500 ml
Colour :	Yellowish		Pale Yellow
Transparency :	Slight Turbid.		Clear
Reaction :	Acidic		4.6 - 8.0
Specific Gravity :	1.015		1.016 - 1.022
Sediment :	Present		
<u>Chemical Examination</u>			
Albumin :	Present (Faint Trace)		Absent
Sugar :	NIL		Absent
Acetone :	Absent		Absent
Bile Salts :	Absent		Absent
Bile Pigments :	Absent		Absent
Urobilogen :	Absent		Absent
Nitrites :	Absent		Absent
<u>Microscopic Examination</u>			
Red blood Cells :	2-3	/h.p.f	Absent
Pus Cells :	1-2	/h.p.f	Absent
Epithelial Cells :	2-3	/h.p.f	< 10.0
Amorphous :	Absent	/h.p.f	Absent
Bacteria :	Absent	/h.p.f	Absent
Crystals :	Absent	/h.p.f	Absent
Casts :	Absent	/h.p.f	Absent
Fungus :	Not seen	/h.p.f	Absent

Dr. Gayatri M. Mehta

M. D. (Patho)

Reg. No. G-82215

DR. GAYATRI MEHTA
MD(PATHOLOGY)

DR. ANAND D. PARIKH
MD(PATHOLOGY)

ISO 9001:2015 Certified Diagnostics Center

Vidhi Imaging Center, Pathology Department

LAB USE ONLY (Entered by: GM Enter Date/Time: 12/03/2022 16:12:00) (Verify by: GM Verify Date/Time: 12/03/2022 16:12:00)
L-86, Swatantra Senani Nagar, Opp. Akhbarnagar Petrol Pump, Nr. Akhbarnagar Circle, Nava-Vadaj, Ahmedabad - 380 013.

Ph. (Pathology) : 079-2764 5405, 8849893954 M. 98799 29406, 98250 09406, E-mail : vidhidiagnostics@gmail.com, Web. : www.vidhidiagnostics.com

Time (Pathology) : Mon. to Sat. 8.30 am to 8.00 pm, Sunday 9 am to 12 Noon

Pathology means science behind medicine

CT SCAN & CBCT FACILITY NOW AVAILABLE



भारत सरकार
GOVERNMENT OF INDIA

मिनाक्षी नागपाल
Meenakshi Nagpal

जन्म तिथि/ DOB: 05/09/1979
महिला / FEMALE

3206 7339 8639

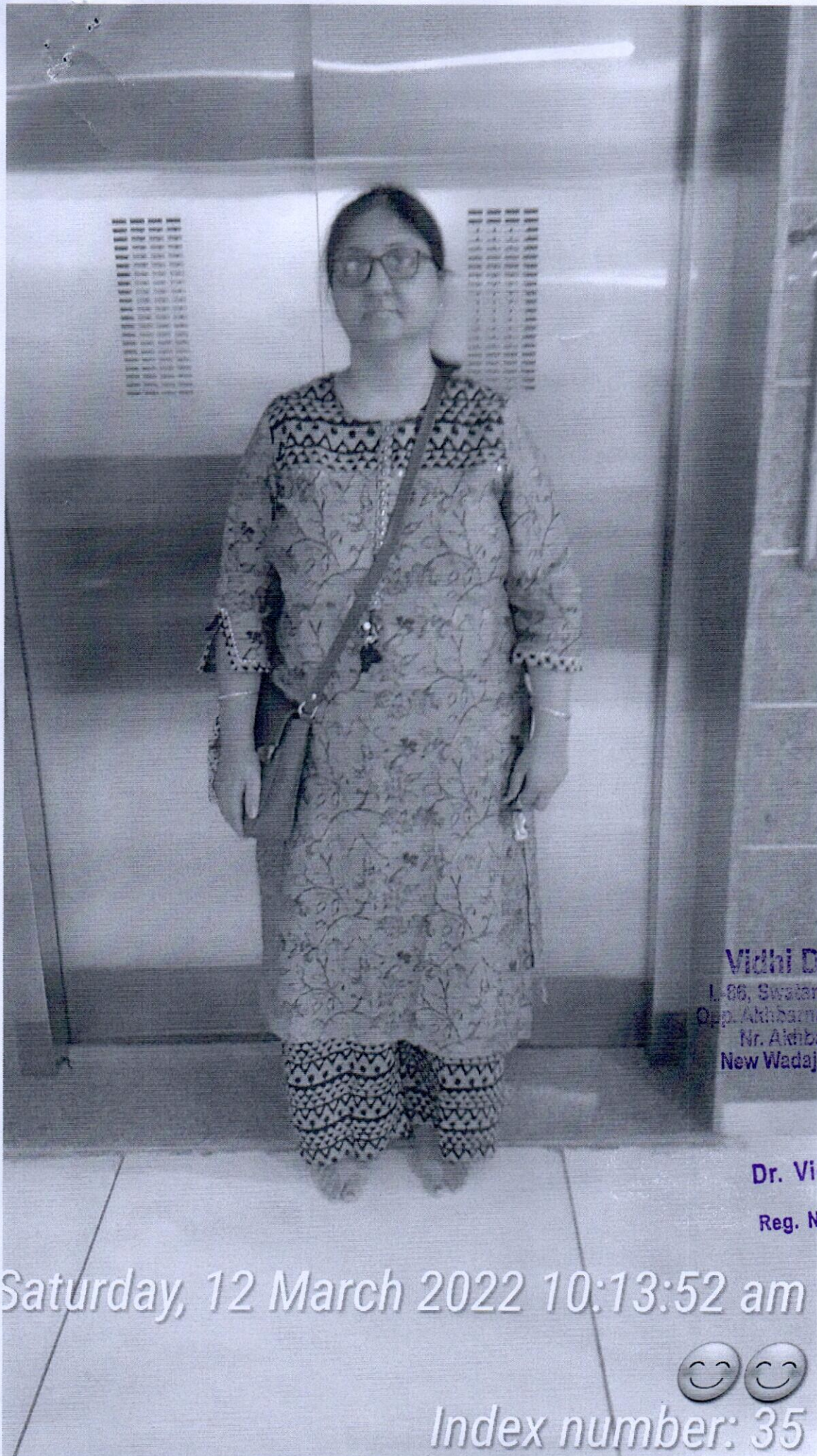आधार-आम आदमी का अधिकार



Dr. Vidhi D. Modh
MBBS
Reg. No. G-74540

Vidhi Diagnostics
L-86, Swatantra-Senani Nagar,
Opp. Akhbarnagar Bus Terminals,
Nr. Akhbarnagar Circle,
New Wadaj, Ahmedabad-13.

~~Dr. Vidhi D. Modh~~



Vidhi Diagnostics

L-86, Swatantra-Senani Nagar,
Opp. Akhbarnagar Bus Terminals,
Nr. Akhbarnagar Circle,
New Wadaj, Ahmedabad-13.

Dr. Vidhi D. Modh
MBBS
Reg. No. G-74540

Saturday, 12 March 2022 10:13:52 am



Index number: 35