



ABI SCANS & LABS

A unit of Aarthi Scans and Labs

Patient Name	MR.ANUGRAH 29Y	Age	29Yr
Patient ID	131377	Sex	Male
Referral Dr	MEDIWHEEL	Study Date	11 Mar 2023

X-RAY - CHEST PA VIEW

OBSERVATION:

The trachea is central.
The mediastinal and cardiac silhouette are normal.
Cardiothoracic ratio is normal.
Cardiophrenic and costophrenic angles are normal.
Both hila are normal.
Lung zones are clear.
Bones of the thoracic cage are normal.
Soft tissues of the chest wall are normal.

IMPRESSION:

No significant abnormality seen.

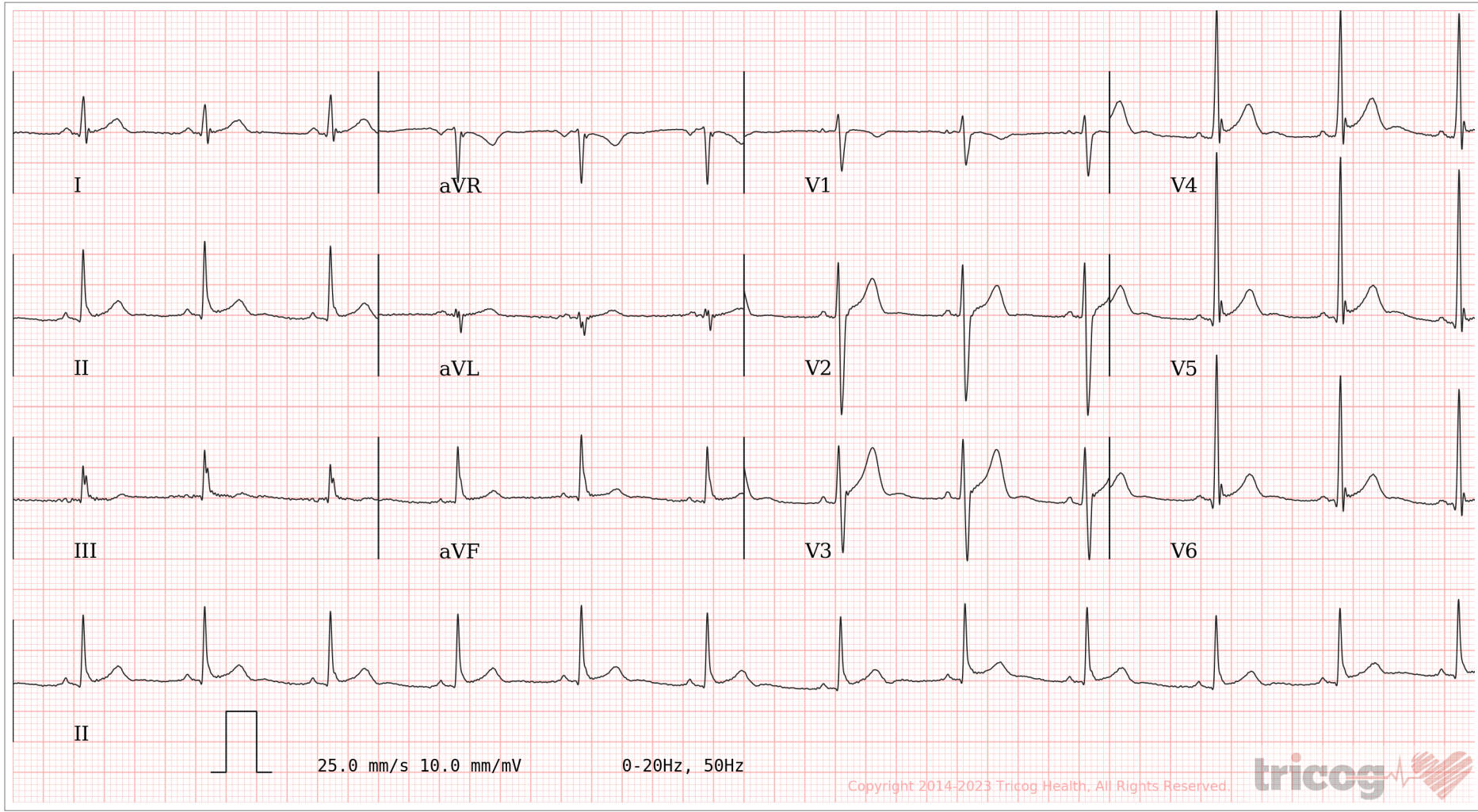

Dr. Abinaya., MD., (RD)
Consultant Radiologist

Aarthi CT and MRI Scans, R S Puram West



Age / Gender: 29/Male
Patient ID: 0000124312
Patient Name: MR. ANUGRAH M

Date and Time: 11th Mar 23 3:43 PM



AR: 73bpm VR: 73bpm QRSD: 88ms QT: 356ms QTc: 392ms PRI: 122ms P-R-T: 26° 70° 37°

ECG Within Normal Limits: Sinus Rhythm. Please correlate clinically.



Disclaimer: Analysis in this report is based on ECG alone and should only be used as an adjunct to clinical history, symptoms and results of other invasive and non-invasive tests and must be interpreted by a qualified physician.



ABI SCANS & LABS

A unit of Aarthi Scans and Labs

Patient Name	MR.ANUGRAH M	Age	29Yr
Patient ID	124312	Sex	Male
Referral Dr	MEDIWHEEL	Study Date	11 Mar 2023

USG REPORT - ABDOMEN AND PELVIS

LIVER:

Is normal in size ~ 13.2 cm and shows normal echo texture.

No obvious focal lesion seen. No intra – Hepatic biliary radical dilatation seen.

GALL BLADDER:

Is adequately distended. No calculus or internal echoes are seen. Wall thickness is normal.

PANCREAS:

Appears normal in size and it shows uniform echo texture.

SPLEEN:

Is normal in size ~9.9 cm and shows uniform echogenicity.

RIGHT KIDNEY:

Right kidney measures ~ 9.4 x 3.8 cms.

The shape, size and contour of the right kidney appear normal.

Cortico medullary differentiation is within normal. No evidence of pelvicalyceal dilatation.

No calculi seen.

LEFT KIDNEY:

Left kidney measures ~ 10.6 x 4.5 cms.

The shape, size and contour of the left kidney appear normal.

Cortico medullary differentiation is within normal. No evidence of pelvicalyceal dilatation.

No calculi seen.

URINARY BLADDER:

Is normal contour. No intra luminal echoes are seen.

PROSTATE:

Prostate appears normal, Measures ~3.3 x 3.1 x 2.6 cms (Vol – 14 cc).



ABI SCANS & LABS

A unit of Aarthi Scans and Labs

Patient Name	MR.ANUGRAH M	Age	29Yr
Patient ID	20230311-155335-5E25	Sex	Male
Referral Dr		Study Date	11 Mar 2023

RIGHT ILIAC FOSSA:

No focal fluid collections seen.

No evidence of hernia seen in anterior abdominal wall.

IMPRESSION:

- **No significant abnormality seen in the present study.**
- **Suggested clinical correlation.**

Dr. Lokesh Babu., MD., (RD)
Consultant Radiologist