



Transport Department Government of Delhi
Licence to Drive Vehicles Throughout India

Licence No. : DI-0820130203147
 Name : PALLAVI PALIWAL (P) N
 S/W/D : RAJESH KUMAR PALIWAL BG: U
 DOB : 10/11/1993
 Address : 3430 GALI NO 248 HANSA PURI TRI
 NAGAR, DELHI 110035

Authorisation to Drive : LMV-NT
 M.CYL

Issue Date : 19/01/2013
 Validity : 18/01/2033
 Inv Carr No : NA

Date of Issue : 19/01/2013
 19/01/2013

(Holder's Signature)
 Issuing Authority (NWZ-1)

[Handwritten Signature]

Dr. NITIN AGARWAL
 MBBS, MD
 Regn. No. DMC-R-1436

[Handwritten Signature]

ONEPLUS ULTRASOUND LAB
 47, Harsh Vihar, Piram Pura,
 Delhi-110034
 Ph. 011-42480101, 9599913051
 E-mail: oneplusul@gmail.com



Transport Department Government of Delhi
Licence to Drive Vehicles Throughout India

Licence No.	: DL-0820130203147	(P) N
Name	: PALLAVI PALIWAL	BG: U
S/W/D	: RAJESH KUMAR PALIWAL	
	DOB: 10/11/1993	
	Address: 3430 GALI NO 248 HANSA PURI TRI	
	NAGAR, DELHI 110035	

Authorisation to Drive
LMV-NT
M,CYL

Issue Date: 19/01/2013
Validity: 18/01/2033
Inv Carr No: NA

Date of Issue: 19/01/2013



(Holder's Signature)
Issuing Authority (NWZ-1)


[Handwritten Signature]

Dr. NITIN AGARWAL
MBBS, MD
Regn. No. DMC-R-1436

[Handwritten Signature]

ONEPLUS ULTRASOUND LAB
47, Harsh Vihar, Pitam Pura,
Delhi-110034
Ph. 011-42480101, 9599913051
E-mail: oneplusul@gmail.com

Handwritten scribbles and marks at the bottom left corner of the page.



Dr. NITIN AGARWAL
MBBS, MD
Regn. No. DMC-R-1436

ONEPLUS ULTRASOUND LAB
47, Harsh Vihar, Pitam Pura,
Delhi-110034
Ph. 011-42480101, 9599913051
E-mail: oneplusul@gmail.com





OnePLUS
Ultrasound Lab
— QUALITY FIRST... ALWAYS! —

Dr. Nitin Agarwal
Pathologist & Director
Ex. Sr. Res. MAMC
& Lok Nayak Hospital
Ex. Chief of Lab Dr. Lal Path Labs.

Dr. Pooja (Garg) Agarwal
Radiologist & Director
MAMC & Lok Nayak Hospital

Name	: Miss. PALLAVI PALIWAL	Age/Sex	: 28 YRS/Female
Ref. By	: Dr. MEDIWHEEL	Lab No	: 012202060010
Date	: 06-Feb-2022	Patient ID	: LSHHI90831

X-ray-Chest PA view

Lung fields are clear. No parenchymal lesion seen.

Cardiothoracic ratio is normal.

Mediastinum is normal.

Both hila are normal.

Both costophrenic angles are clear.

Both domes of diaphragm are normal.

Bony cage and soft tissues are normal.

IMPRESSION: Normal Study.

Dr. Shubham K
MD RADIODIAGNOSIS
REG NO - DMC/R/99162

Dr SHUBHAM KHATOD
MBBS, MD
Reg. No. DMC/R/99162
Radiologist

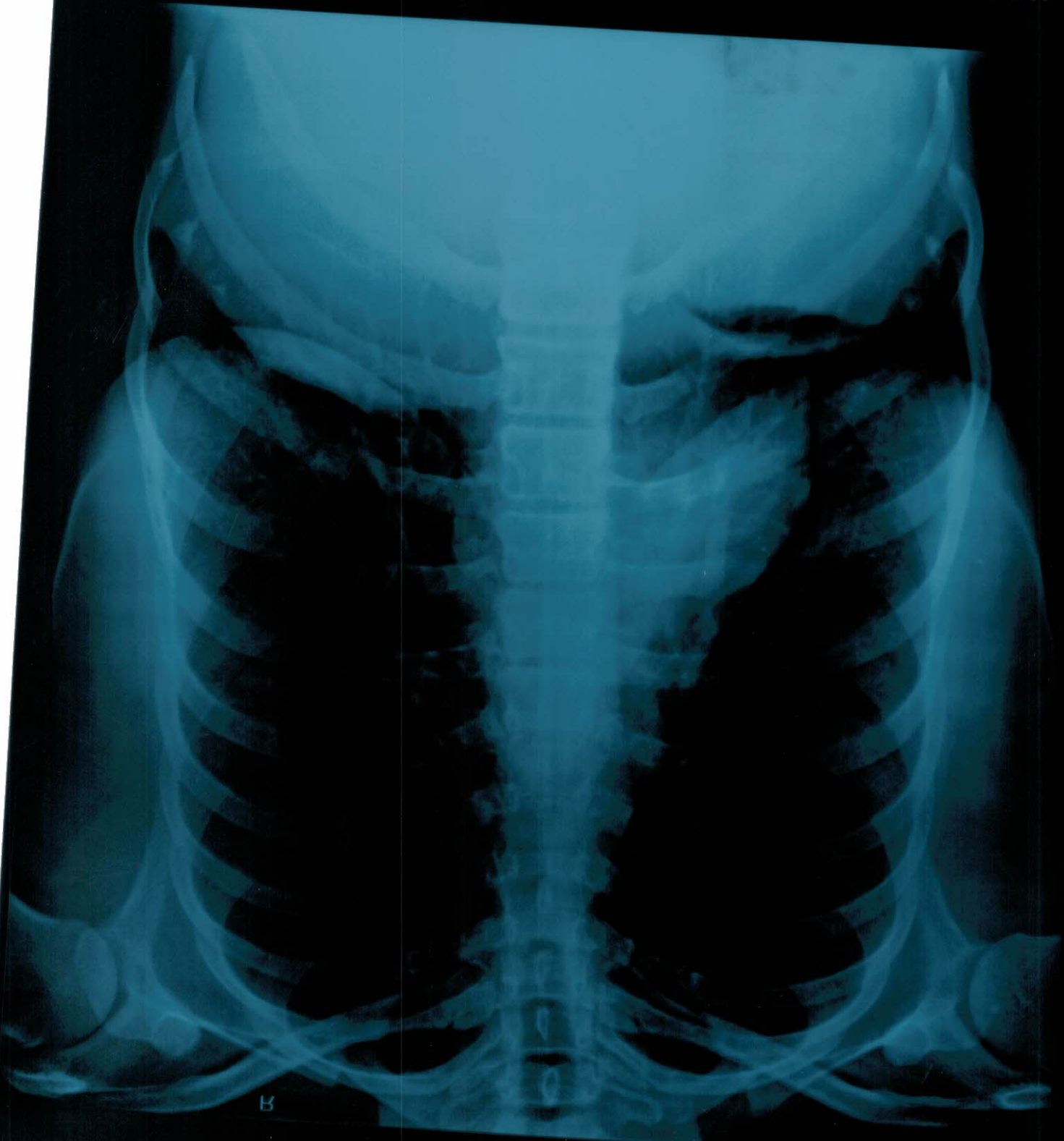47, Harsh Vihar, Pitampura, New Delhi-110034 | Ph.: 011-42480101, 9599913051

E-mail: oneplusul@gmail.com | Web.: www.oneplusul.in

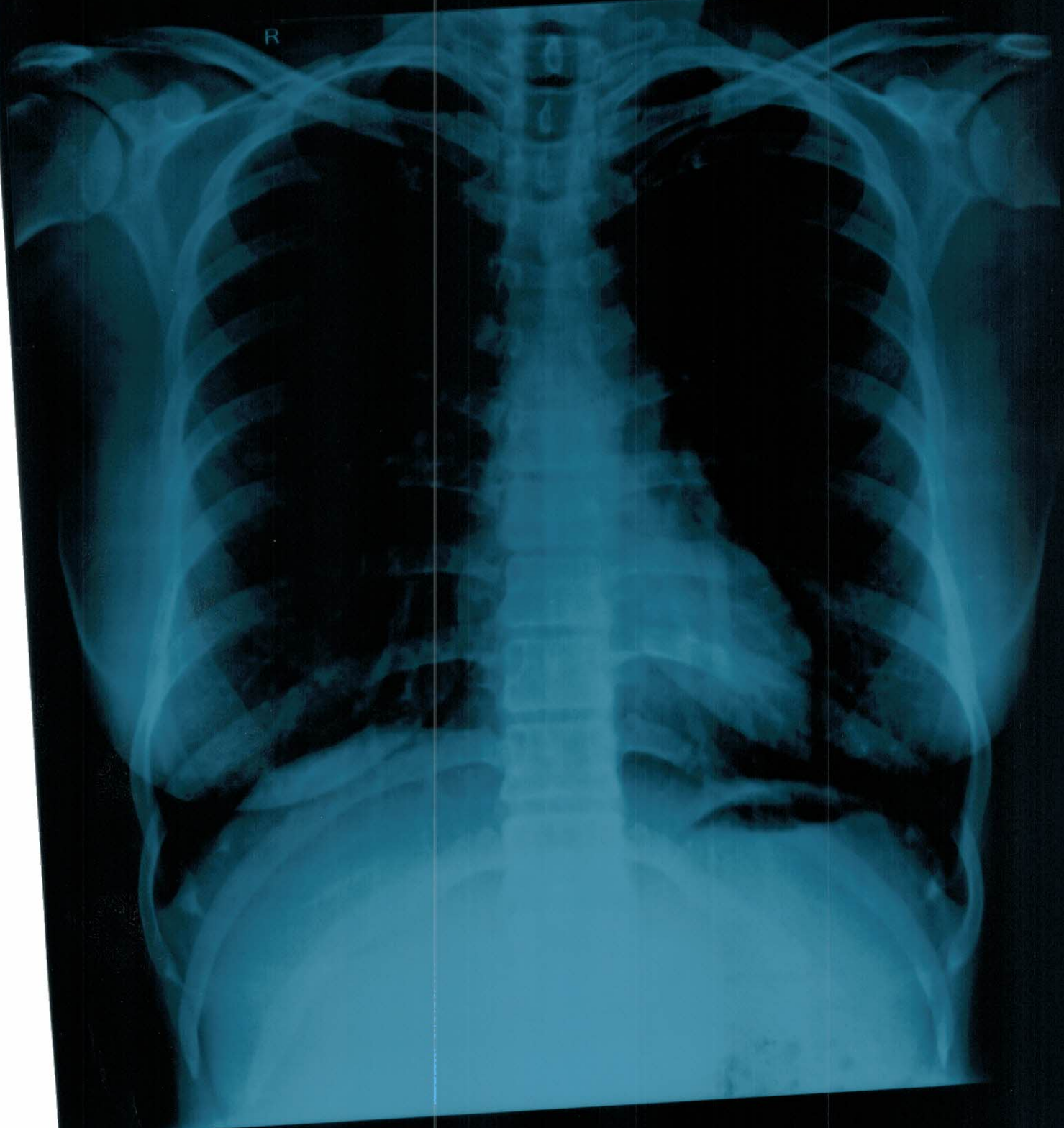
Consent is essential for final diagnosis. • If test results are unsatisfactory please contact personally or on phone. • This report is for perusal of doctors only.
Delhi Jurisdiction only. • Not for medicolegal purposes. • All congenital anomalies in a foetus may not be diagnosed in routine obstetric ultrasound.

Handwritten text, possibly a signature or date, located in the upper right quadrant of the page.

ОИЕБГУС ПГ ТРАСОИИД ГАВ'47-НАР2Н ВІНАВ'РІТАМЬУВА
MISS PAГГVI PAГІWAG 38 YP2 0E10Z1Z0Z3 E CHECT PA VIEW



В



MISS PALLVI PALIWAL 28 YRS 06/02/2022 F CHEST PA VIEW
ONEPLUS ULTRASOUND LAB, 47-HARSH VIHAR, PITAMPURA



OnePLUS
Ultrasound Lab
— QUALITY FIRST... ALWAYS! —

Dr. Nitin Agarwal
Pathologist & Director
Ex. Sr. Res. MAMC
& Lok Nayak Hospital
Ex. Chief of Lab Dr. Lal Path Labs.

Dr. Pooja (Garg) Agarwal
Radiologist & Director
MAMC & Lok Nayak Hospital

Name	: Miss. PALLAVI PALIWAL	Age/Sex	: 28 YRS/Female
Ref. By	: Dr. MEDIWHEEL	Lab No	: 012202060010
Date	: 06-Feb-2022	Patient ID	: LSHHI90831

ULTRASOUND EXAMINATION----WHOLE ABDOMEN

Liver is normal in size (12.5 cm) and outline with normal echopattern. Intrahepatic biliary radicles are not dilated. No abscess or mass lesion seen. Hepatic veins, portal vein, IVC and aorta are normal. CBD is normal in caliber.

Gall bladder is well distended with anechoic lumen. Wall thickness is normal.

Both kidneys are normal in size, shape, position, outline and echopattern. Corticomedullary differentiation is maintained. No pelvicalyceal dilation or mass lesion is seen.

Renal measurements are --

Rt. Kidney - 9.5 x 3.7 cm.

Lt. kidney - 9.1 x 4.3 cm

Spleen is normal in size (8.8 cm) and echotexture. No mass lesion seen.

Pancreas is normal in size, outline and echotexture.

Urinary bladder is normal in shape and position. No evidence of intravesical stone or mass seen.

Uterus is normal in size, shape, position and echopattern. No mass seen

Uterine cavity is empty. Endometrial thickness is 3.0 mm

Both ovaries appear normal in size, shape and echopattern. No tubo-ovarian mass seen.

Ovarian measurements are --

Rt. Ovary--- 2.3 x 3.2 x 1.7 cm. Vol – 6.7 cc.


Lt. Ovary--- 3.5 x 2.4 x 1.9 cm. Vol – 8.9 cc

No abnormal bowel wall thickening seen in right iliac fossa.

No free fluid seen anywhere in abdomen.

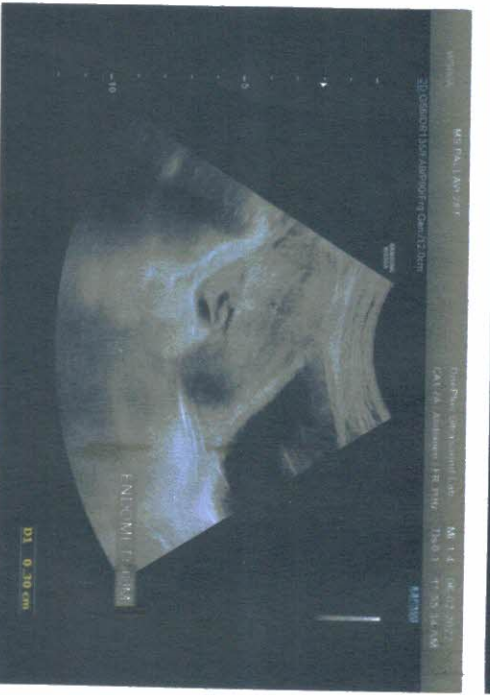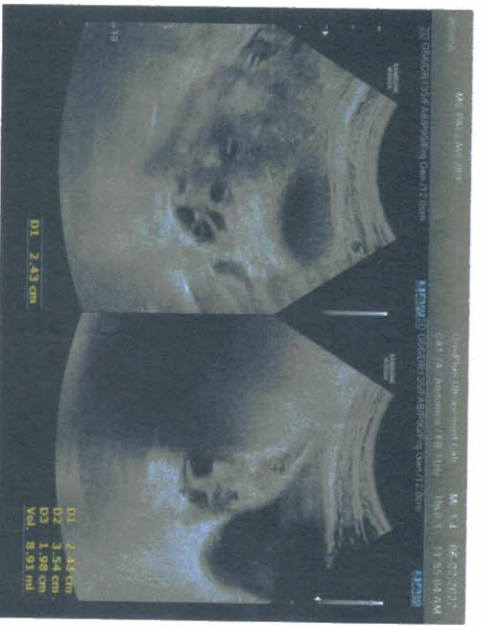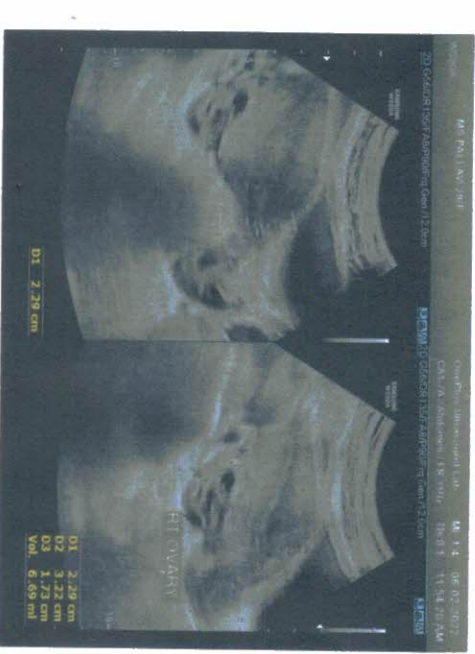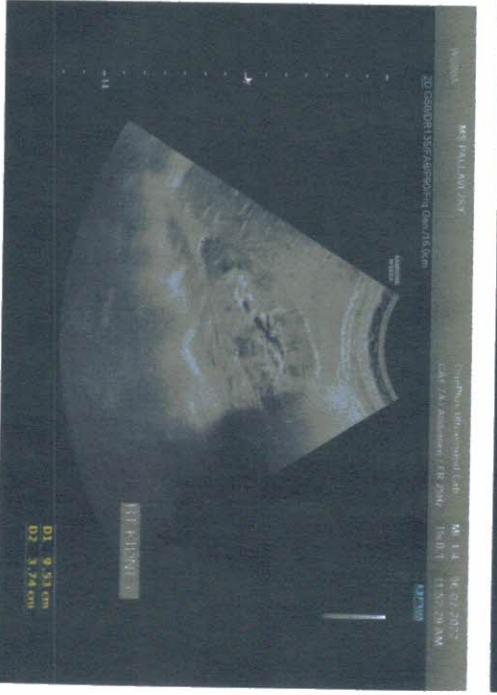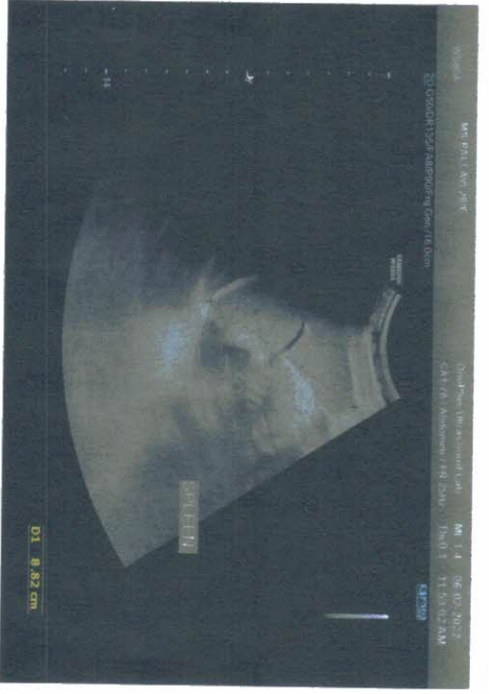
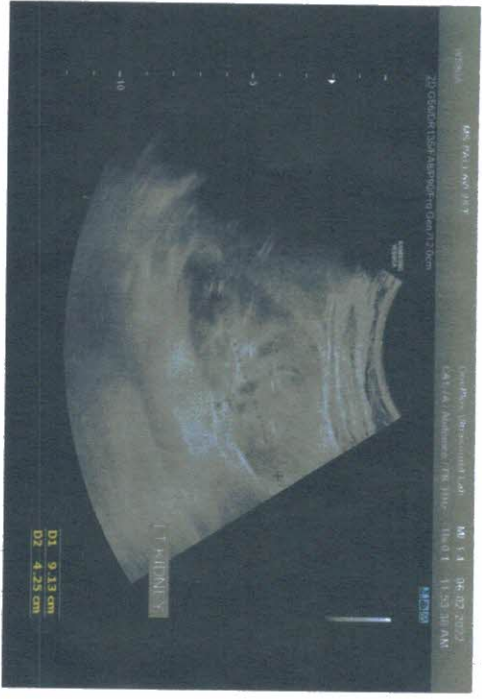
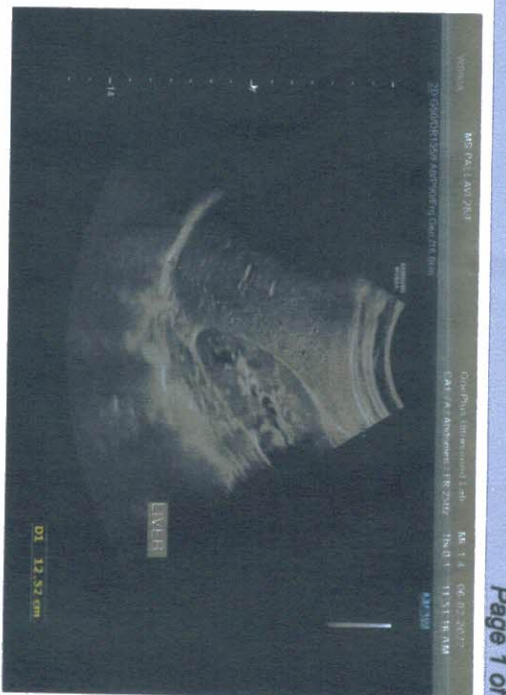
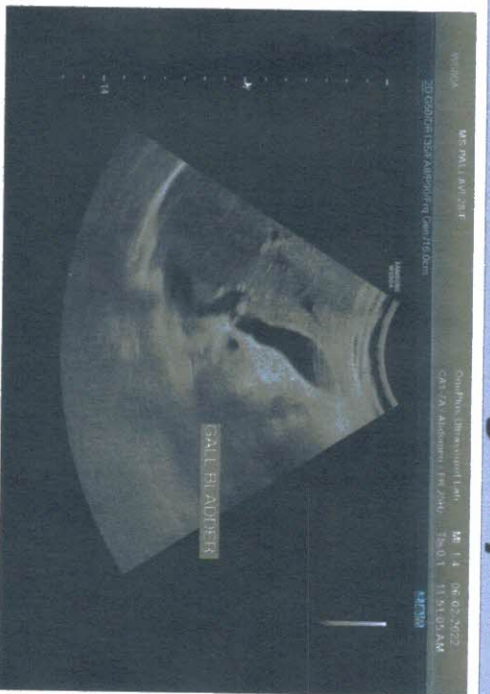
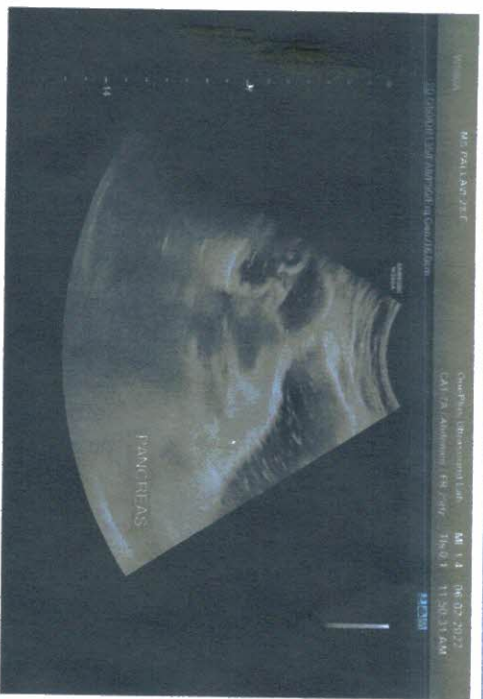
IMPRESSION:

- Normal study.


Dr. Shubham K
MD RADIODIAGNOSIS
REG NO – DMC/R/99162

Dr SHUBHAM KHATOD
MBBS, MD
Reg. No. DMC/R/99162
Radiologist

47, Harsh Vihar, Pitampura, New Delhi-110034 | Ph.: 011-42480101, 9599913051
E-mail: oneplusul@gmail.com | Web.: www.oneplusul.in





OnePLUS

Ultrasound Lab

Dr. Nitin Agarwal
Pathologist & Director
Ex. Sr. Res. MAMC
& Lok Nayak Hospital
Ex. Chief of Lab Dr. Lal Path Labs.

Dr. Pooja (Garg) Agarwal
Radiologist & Director
MAMC & Lok Nayak Hospital



QUALITY FIRST... ALWAYS!			
NAME	: Miss. PALLAVI PALIWAL	Barcode No	: 10113047
AGE/GENDER	: 28 YRS/Female	SPECIMEN DATE	: 06/Feb/2022 10:26AM
PATIENT ID	: 90831	SPECIMEN RECEIVED	: 06/Feb/2022 01:30PM
REFERRED BY	: Dr. MEDIWHEEL	REPORT DATE	: 06/Feb/2022 05:41PM
CENTRE NAME	: ONEPLUS ULTRASOUND LAB	LAB NO.	: 012202060010

Test Name	Result	Unit	Ref. Range
-----------	--------	------	------------

HAEMATOLOGY

Health checkup 2 Female

Glycosylated Hemoglobin (HbA1c)	4.8	%	Non Diabetic adults <5.7 Prediabetic (at risk) 5.7-6.4 Diabetes >6.4
Estimated average blood glucose (eag)	91		

Reference range (mg/dl):

90 - 120:Excellent control, 121 - 150:Good Control, 151 - 180:Average Control, 181 - 210:Action Suggested

>211:Panic value

BLOOD GROUP (ABO)

AB

Rh typing

POSITIVE

NOTE :

- * Apart from major A,B,H antigens which are used for ABO grouping and Rh typing, many minor blood group antigens exist. Agglutination may also vary according to titre of antigen and antibody.
- * So before transfusion, reconfirmation of blood group as well as cross-matching is needed.
- * Presence of maternal antibodies in newborns, may interfere with blood grouping.
- * Auto agglutination (due to cold antibody, falciparum malaria, sepsis, internal malignancy etc.) may also cause erroneous result.

CBC

Haemoglobin	12.1	g/dl	11.5-15.0
Total Leucocyte Count	7490	/cumm	4000-10000
Differential leucocyte count			
Neutrophils	62.9	%	40-80
Lymphocyte	22.40	%	20-40
Monocytes	6.60	%	2-10
Eosinophils	7.8	%	1-6
Basophils	0.3	%	0-2
RBC Count	4.44	million/cumm	3.8-4.8

Checked By.

DR. NITIN AGARWAL
MBBS,MD(PATHOLOGIST)

Dr NITIN AGARWAL
M B B S , MD (Path)
DMC/R/01436

47, Harsh Vihar, Pitampura, New Delhi-110034 | Ph.: 011-42480101, 9599913051

E-mail: oneplusul@gmail.com | Web.: www.oneplusul.in

Page 1 of 5



OnePLUS

Ultrasound Lab

QUALITY FIRST... ALWAYS!

Dr. Nitin Agarwal
Pathologist & Director
Ex. Sr. Res. MAMC
& Lok Nayak Hospital
Ex. Chief of Lab Dr. Lal Path Labs.

Dr. Pooja (Garg) Agarwal
Radiologist & Director
MAMC & Lok Nayak Hospital



NAME	:Miss. PALLAVI PALIWAL	Barcode No	:10113047
AGE/GENDER	:28 YRS/Female	SPECIMEN DATE	:06/Feb/2022 10:26AM
PATIENT ID	:90831	SPECIMEN RECEIVED	:06/Feb/2022 01:30PM
REFERRED BY	:Dr. MEDIWHEEL	REPORT DATE	:06/Feb/2022 05:41PM
CENTRE NAME	:ONEPLUS ULTRASOUND LAB	LAB NO.	:012202060010

Test Name	Result	Unit	Ref. Range
PCV(Hematocrit)	38.2	%	36-46
MCV	86	fL	83-101
MCH	27.3	Pg	27-32
MCHC	31.7	G/dL	32-35
Platelet count	214000	/cumm	150000-450000
RDW-CV	13.1	%	11.4-14.0
ESR(WESTEGRENs METHOD)	12	mm/1hr	<20

BIOCHEMISTRY

<u>Blood sugar fasting</u>	86	mg/dL	70-110
<u>Blood sugar pp</u>	123	mg/dL	70.0-140.0
<u>Bun (blood urea nitrogen)</u>	13.50	mg/dl	7-18.7
<u>Uric acid, serum</u>	4.2	mg/dl	2.4-5.7
<u>Creatinine, serum</u>	0.52	mg/dl	0.50-0.9

LFT(LIVER FUNCTION TEST)

Bilirubin Total	0.65	mg/dl	0.1-1.2
Bilirubin Conjugated	0.25	mg/dl	0-0.4
Bilirubin Unconjugated	0.4	mg/dl	up to 0.7
SGOT (AST)	21	U/L	0-31
SGPT (ALT)	15	U/L	<34
Alkaline phosphatase	102	U/L	35-104
Gamma glutamyl transpeptidase	26	U/L	<39
Total Protein	6.9	gm/dl	6.60 - 8.70
Albumin	3.9	g/dL	3.8-5.1
Globulin	3.00	gm/dl	1.8-3.4
Albumin/Globulin Ratio	1.30		1.10 - 2.50

LIPID PROFILE

Cholesterol	172	mg/dl	50-200
Triglycerides	59	mg/dL	25-150

Checked By.

Dr. NITIN AGARWAL
MBBS, MD (Pathology)
DMC/R/01436

47, Harsh Vihar, Pitampura, New Delhi-110034 | Ph.: 011-42480101, 9599913051

E-mail: oneplusul@gmail.com | Web.: www.oneplusul.in

Page 2 of 5

Clinical correlation is essential for final diagnosis. • If test results are unsatisfactory please contact personally or on phone. • This report is for perusal of doctors only. • All disputes Subject to Delhi Jurisdiction only. • Not for medicolegal purposes. • All congenital anomalies in a foetus may not be diagnosed in routine obstetric ultrasound.



OnePLUS Ultrasound Lab

QUALITY FIRST... ALWAYS!

*** End Of Report ***

Dr. Nitin Agarwal
Pathologist & Director
Ex. Sr. Res. MAMC
& Lok Nayak Hospital
Ex. Chief of Lab Dr. Lal Path Labs.

Dr. Pooja (Garg) Agarwal
Radiologist & Director
MAMC & Lok Nayak Hospital



NAME	:Miss. PALLAVI PALIWAL	Barcode No	:10113047
AGE GENDER	:28 YRS/Female	SPECIMEN DATE	:06/Feb/2022 10:26AM
PATIENT ID	:90831	SPECIMEN RECEIVED	:06/Feb/2022 01:30PM
REFERRED BY	:Dr. MEDIWHEEL	REPORT DATE	:06/Feb/2022 05:41PM
CENTRE NAME	:ONEPLUS ULTRASOUND LAB	LAB NO.	:012202060010

Test Name	Result	Unit	Ref. Range
HDL Cholesterol	45	mg/dL	30 - 70
LDL cholesterol	115	mg/dL	< 130
VLDL cholesterol	11.8	mg/dL	5-40
Cholesterol/HDL Ratio	3.8		Low Risk 3.3-4.97 Average Risk 4.4-7.1 Moderate Risk 7.1-11.0 High Risk >11.0
LDL/HDL Ratio	2.6		0 - 3.55

According to ATP III and NCEP guidelines

Parameter	Normal	Desirable	Borderline	High
Total cholesterol	<200	200-239		240
Triglycerides	<150	150-199	200-499	500
LDL	Optimal <100 Near Optimal 100-129	130-159	160-180	190
HDL	<40 : LOW 60 : HIGH			

ENDOCRINOLOGY

THYROID PROFILE(T3,T4,TSH)

Triiodothyronine total [t3]	0.72	ng/dl	0.52-1.9
Thyroxine total [t4]	6.50	µg/dl	4.8-11.6
TSH (Thyroid Stimulating Hormone)	6.00	µIU/ml	0.25-5.0

AGE WISE VARIATION IN TSH

AGE	TSH(µIU/ml)	AGE	TSH(µIU/ml)
1-4 weeks	1.00 - 19.0	16-20 yrs	0.25 - 5.0
1-12 mths	1.70 - 9.1	21 - 80 yrs	0.25 - 5.0
1-5 yrs	0.80 - 8.2	I st trimester	0.25 - 5.0
6-10 yrs	0.25 - 5.0	II nd trimester	0.50 - 5.0
11-15 yrs	0.25 - 5.0	III rd trimester	0.4 - 6.0

Checked By.

Dr. NITIN AGARWAL
MBBS, MD (Path), MD (PATHOLOGIST)
DMC/R/01436

47, Harsh Vihar, Pitampura, New Delhi-110034 | Ph.: 011-42480101, 9599913051
E-mail: oneplusul@gmail.com | Web.: www.oneplusul.in

Page 2 of 2
Page 3 of 5



OnePLUS Ultrasound Lab

QUALITY FIRST... ALWAYS!

Dr. Nitin Agarwal
Pathologist & Director
Ex. Sr. Res. MAMC
& Lok Nayak Hospital
Ex. Chief of Lab Dr. Lal Path Labs.

Dr. Pooja (Garg) Agarwal
Radiologist & Director
MAMC & Lok Nayak Hospital



NAME	:Miss. PALLAVI PALIWAL	Barcode No	:10113047
AGE/GENDER	:28 YRS/Female	SPECIMEN DATE	:06/Feb/2022 10:26AM
PATIENT ID	:90831	SPECIMEN RECEIVED	:06/Feb/2022 01:30PM
REFERRED BY	:Dr. MEDIWHEEL	REPORT DATE	:06/Feb/2022 05:41PM
CENTRE NAME	:ONEPLUS ULTRASOUND LAB	LAB NO.	:012202060010

Test Name	Result	Unit	Ref. Range
-----------	--------	------	------------

Reference ranges - Interpretation of Diagnostic tests - (Jacques Wallach)

1. Primary hypothyroidism is accompanied by depressed serum T3 and T4 values and elevated serum TSH level.
2. Primary hyperthyroidism is accompanied by elevated serum T3 and T4 levels along with depressed TSH values.
3. Slightly elevated T3 levels may be found in pregnancy and estrogen therapy, while depressed levels may be encountered in severe illness, renal failure and during therapy with drugs like propranolol and propyl thiouracil.
4. Although elevated TSH levels are nearly always indicative of primary hypothyroidism, and may be seen in secondary thyrotoxicosis

CLINICAL PATHOLOGY

URINE ROUTINE

Physical examination

Quantity	30	ML
Colour	PALE YELLOW	
Transparency	CLEAR	CLEAR
Sp.gravity	1.010	1.010-1.030
pH	6.50	
Reaction	ACIDIC	ACIDIC


Chemical examination

Urine protein	NIL	NIL
Urine sugar	NIL	NIL
Bilirubin, urine	NEGATIVE	NEGATIVE
Urobilinogen	NORMAL	NORMAL
Ketones	NEGATIVE	NEGATIVE

Microscopic examination

Pus cells.	1-2	/HPF	1-2
Epithelial cells	1-2	/HPF	0-5
R.B.C.	NIL	/HPF	NIL
Casts	NIL	/HPF	NIL
Crystals	NIL	/HPF	NIL
Bacteria	NIL	/HPF	NIL

Checked By.


Dr. NITIN AGARWAL
MBBS, MD (Path)
DMC/R/01436
DR. NITIN AGARWAL
MBBS, MD (PATHOLOGIST)

47, Harsh Vihar, Pitampura, New Delhi-110034 | Ph.: 011-42480101, 9599913051

E-mail: oneplusul@gmail.com | Web.: www.oneplusul.in

Page 4 of 5



OnePLUS Ultrasound Lab

QUALITY FIRST... ALWAYS!

Dr. Nitin Agarwal
Pathologist & Director
Ex. Sr. Res. MAMC
& Lok Nayak Hospital
Ex. Chief of Lab Dr. Lal Path Labs.

Dr. Pooja (Garg) Agarwal
Radiologist & Director
MAMC & Lok Nayak Hospital



NAME	:Miss. PALLAVI PALIWAL	Barcode No	:10113047
AGE/GENDER	:28 YRS/Female	SPECIMEN DATE	:06/Feb/2022 10:26AM
PATIENT ID	:90831	SPECIMEN RECEIVED	:06/Feb/2022 01:30PM
REFERRED BY	:Dr. MEDIWHEEL	REPORT DATE	:06/Feb/2022 05:41PM
CENTRE NAME	:ONEPLUS ULTRASOUND LAB	LAB NO.	:012202060010

Test Name	Result	Unit	Ref. Range
Others.	NIL		NIL
STOOL ROUTINE			
<u>Physical examination</u>			
Colour	BROWNISH		Brownish
Consistency	SEMI FORMED		Semi Formed
Blood	ABSENT		Absent
Mucus	ABSENT		Absent
<u>Chemical examination, stool</u>			
pH	5.50		
<u>Microscopic examination</u>			
Pus cells	0 - 1	/HPF	10-11
Red blood cells	NIL	NIL	
Ova	ABSENT		NIL
Cysts	NIL		NIL
Bacteria	PRESENT	/HPF	NIL
Others	NIL		

*** End Of Report ***

Checked By.

DR. NITIN AGARWAL
MBBS,MD(PATHOLOGIST)

47, Harsh Vihar, Pitampura, New Delhi-110034 | Ph.: 011-42480101, 9599913051
E-mail: oneplusul@gmail.com | Web.: www.oneplusul.in

Page 5 of 5

Clinical correlation is essential for final diagnosis. • If test results are unsatisfactory please contact personally or on phone. • This report is for perusal of doctors only.
• All disputes Subject to Delhi Jurisdiction only. • Not for medicolegal purposes. • All congenital anomalies in a foetus may not be diagnosed in routine obstetric ultrasound.

ONEPLUS ULTRASOUND LAB

47, HARSH VIHAR, PITAMPURA, DELHI- 110034

Handwritten signature

Ms. PALLAVI PALIWAL
Age : 28/F
Ref. by : MEDIWHEEL
Indication1 :
Indication2 :
Indication3 :
COMMENTS : Normal ECG.

ID : 1868
H/Wt : 160/55
Recorded : 6-2-2022 10:59
Medication1 :
Medication2 :
Medication3 :

BPM : 84
BP : 120/80
P Axis : 67 deg
QRS Axis : 88 deg
T Axis : 38 deg

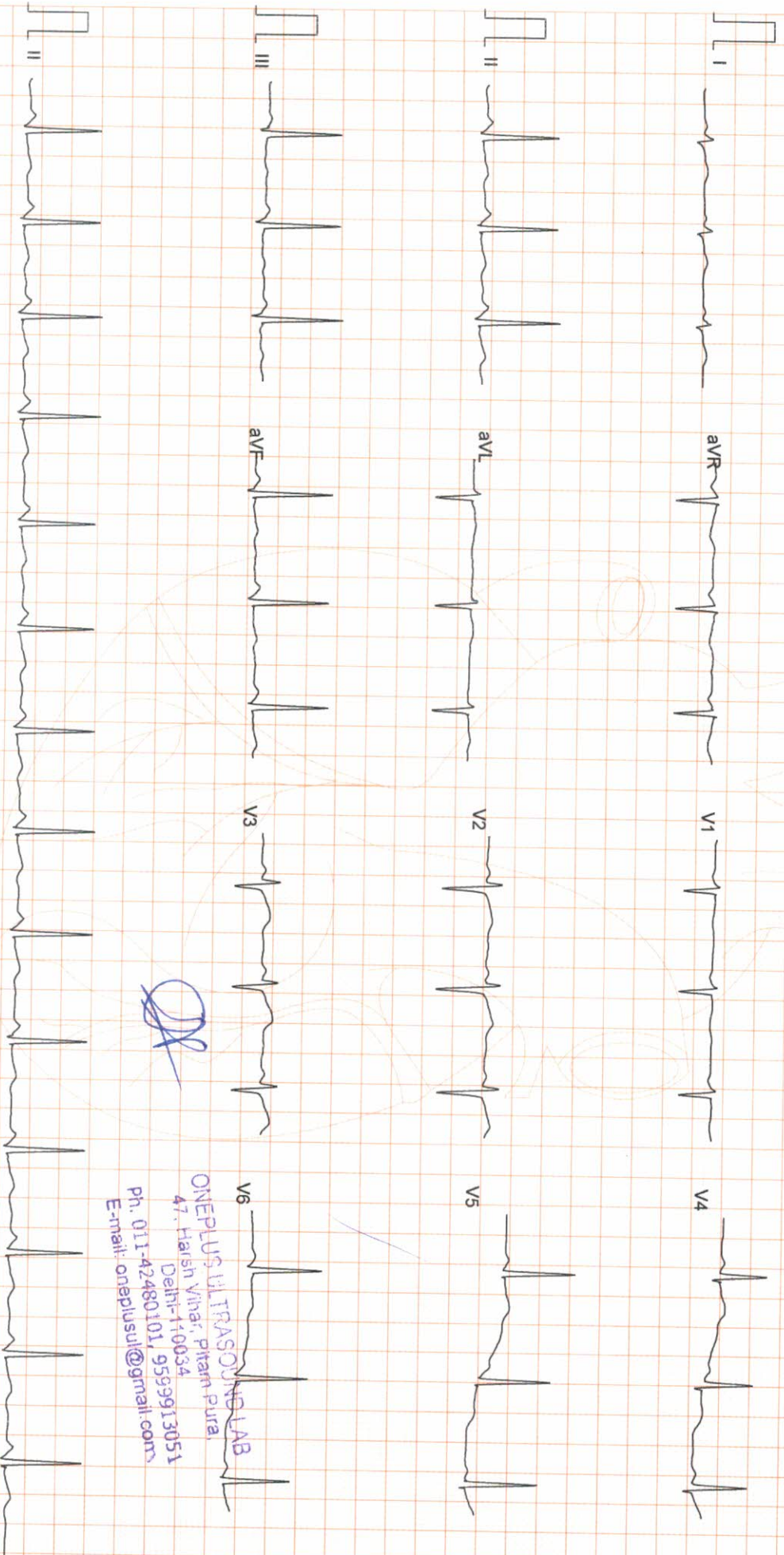
P duration : 83 msec
PR duration : 110 msec
QRS duration : 100 msec
QT interval : 320 msec
QTc interval : 362 msec

Raw E.C.G.(Seq)

Reg. No. 57007

Unconfirmed Report Reviewed By:
Cardiologist

Handwritten signature
Dr. B.S. SINGLA
MBBS MD



Handwritten signature

ONEPLUS ULTRASOUND LAB
47, Harsh Vihar, Pitampura
Delhi-110034
Ph. 011-42480101, 9559913051
E-mail: oneplusul@gmail.com

Filtered

25mm/sec 10mm/mV

AVR aV

CardiCom, INDIA

ONEPLUS ULTRASOUND LAB

47, HARSH VIHAR PITAMPURA DELHI 110034

ID : 998
 HWWT : 160/55
 Recorded : 6-2-2022 11:03
 TREADMILL TEST SUMMARY REPORT
 Protocol: BRUCE

Ms. PALLAVI PALIWAL
 Age : 28/F
 Ref. by : MEDIWHEEL
 Indication 1 :
 Indication 2 :
 Indication 3 :

History :
 Medication 1 :
 Medication 2 :
 Medication 3 :

PHASE	PHASE TIME	STAGE TIME	SPEED (Km./Hr.)	GRADE (%)	H.R. (BPM)	B.P. (mmHg)	RPP X100	II	ST LEVEL (mm) V2	V5	METS
STANDING											
SUPINE					82	120/80	98	0.1	0.6	0.3	
					82	120/80	98	0.1	0.6	0.2	
STAGE 1	2:59	2:59	2.70	10.00	112	120/80	134	-0.6	0.3	-0.2	4.80
STAGE 2	5:59	2:59	4.00	12.00	136	134/82	182	-1.1	0.7	-0.4	7.10
STAGE 3	8:59	2:59	5.40	14.00	165	146/86	240	-0.9	0.6	-2.3	10.00
STAGE 4	9:14	0:14	6.70	16.00	177	160/90	283	-1.8	0.7	-1.5	10.31
PEAK EXER	9:25	0:25			179	160/90	286	-1.0	0.9	-2.1	10.56
RECOVERY	2:59	2:59	0.00	0.00	108	126/82	136	-1.0	0.3	-0.5	

Negative for inducible ST changes

RESULTS
 Exercise Duration : 9:25 Minutes
 Max Heart Rate : 179 bpm 93 % of target heart rate 192 bpm
 Max Blood Pressure : 160/90 mmHg
 Max Work Load : 10.56 METS
 Reason of Termination :
 IMPRESSIONS :

Pass

ONEPLUS ULTRASOUND LAB
 47, Harsh Vihar, Pitam Pura,
 Delhi-110034
 Ph. 011-42480101, 9599913051
 E-mail: onepiusul@gmail.com

Cardiologist
Dr. B.S. GISTLA
 MBBS MD
 Reg. No. 57807

[Signature]

ONEPLUS ULTRASOUND LAB

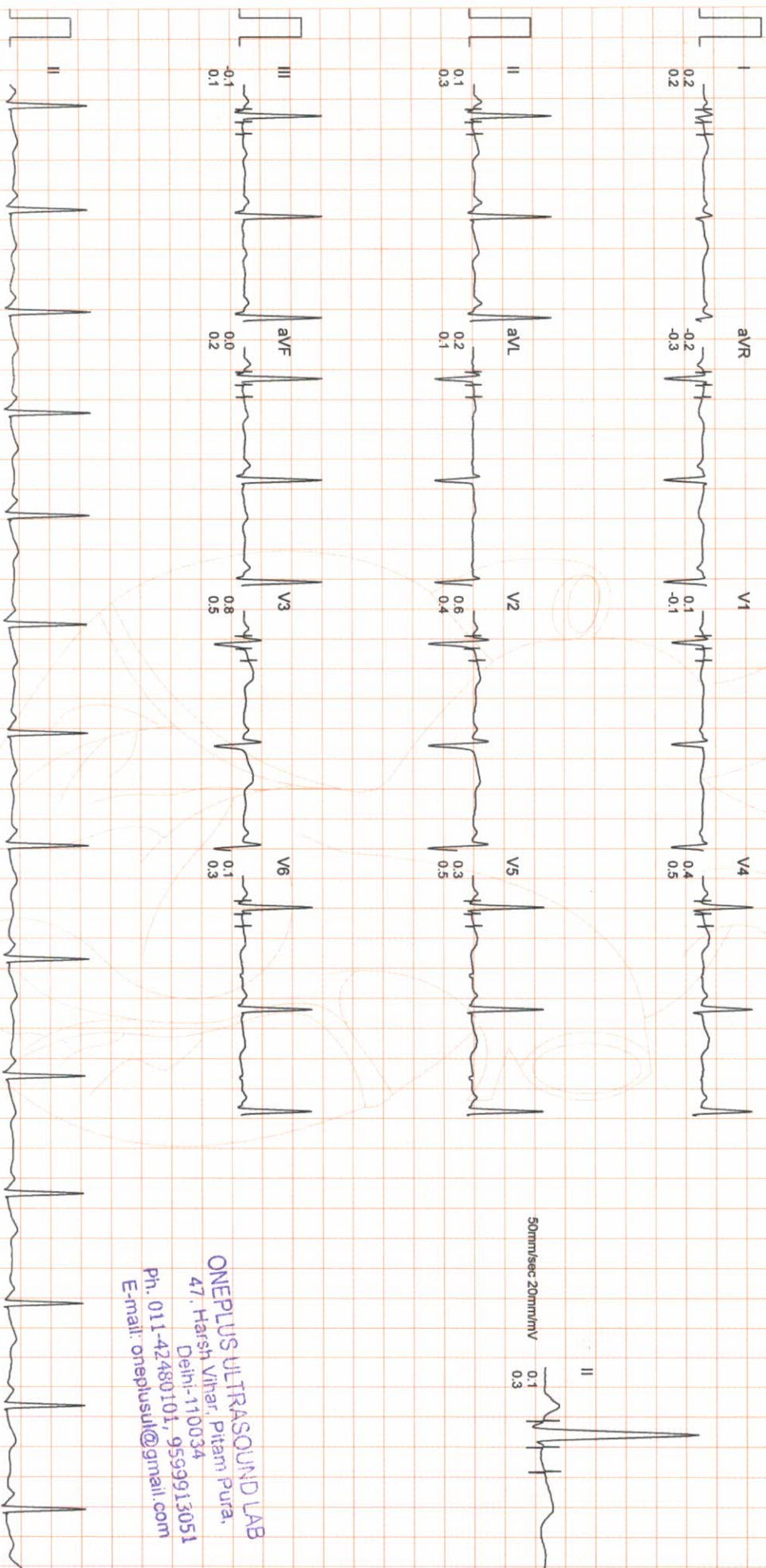
STANDING
PRETEST

ST @ 10mm/mV
80ms PostJ

Ms. PALLAVI PALIWAL
I.D. : 998
AGE/SEX : 28/F
RECORDED : 6-2-2022 11:03

RATE : 82 BPM
B.P. : 120/80 mmHg

LINKED MEDIAN



ONEPLUS ULTRASOUND LAB
47, Harsh Vihar, Pitam Pura,
Delhi-110034
Ph. 011-42480101, 9599913051
E-mail: oneplusul@gmail.com

ONEPLUS ULTRASOUND LAB

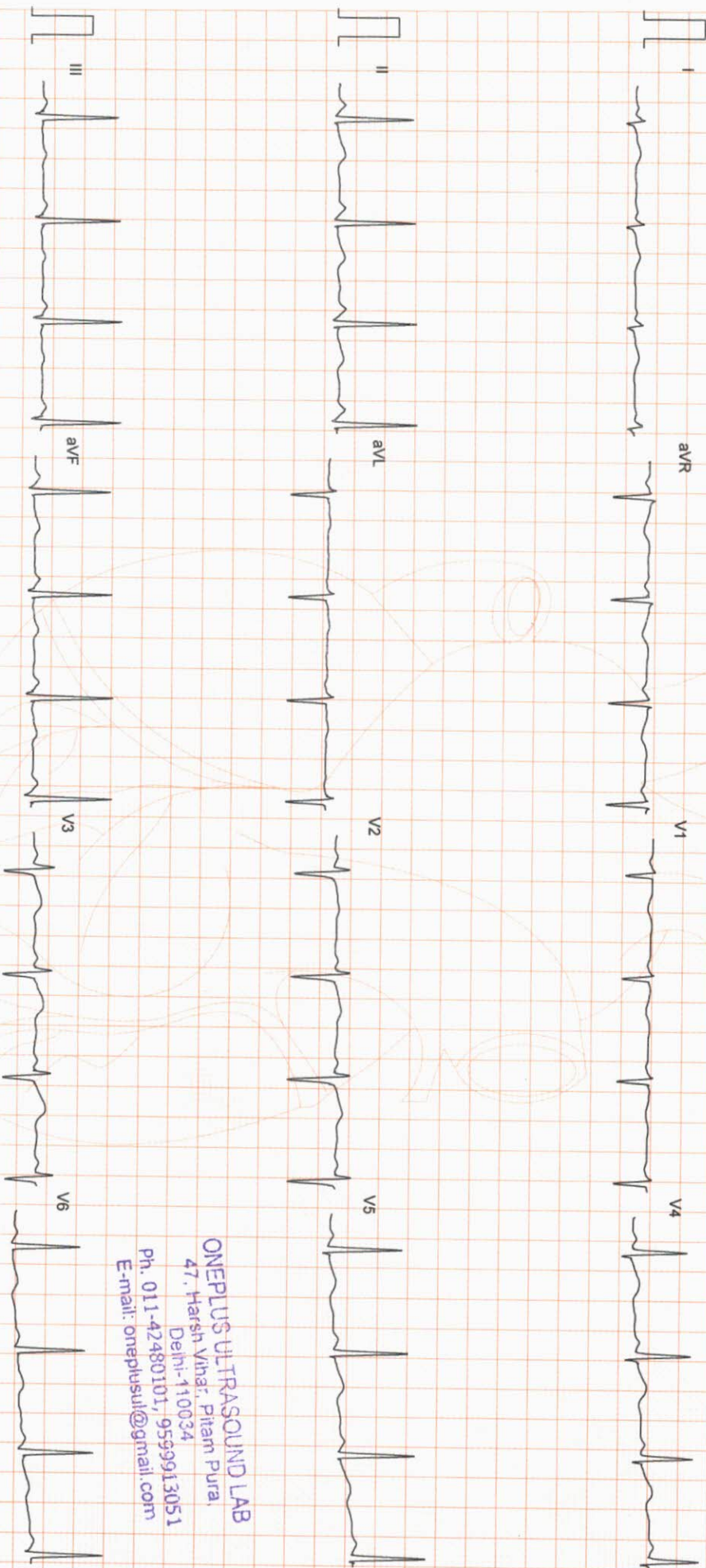
SUPINE
PRETEST

ST @ 10mm/mV
80ms PostJ

Ms. PALLAVI PALIWAL
I.D. : 998
AGE/SEX : 28/F
RECORDED : 6-2-2022 11:03

RATE : 82 BPM
B.P. : 120/80 mmHg

RAW E.C.G.



ONEPLUS ULTRASOUND LAB
47, Harsh Vihar, Pitam Pura,
Delhi-110034
Ph. 011-42480101, 9599913051
E-mail: oneplusul@gmail.com

Filtered

25mm/sec 10mm/mV

ARROW

CardiCom, INDIA Ph.:091-731-2620740, TeleFax:091-731-2431214

ONEPLUS ULTRASOUND LAB

Ms. PALLAVI PALIWAL

I.D. : 998

AGE/SEX : 28/F

RECORDED : 6-2-2022 11:03

RATE : 112 BPM

B.P. : 120/80 mmHg

BRUCE

EXERCISE 1

PHASE TIME : 2:59

STAGE TIME : 2:59

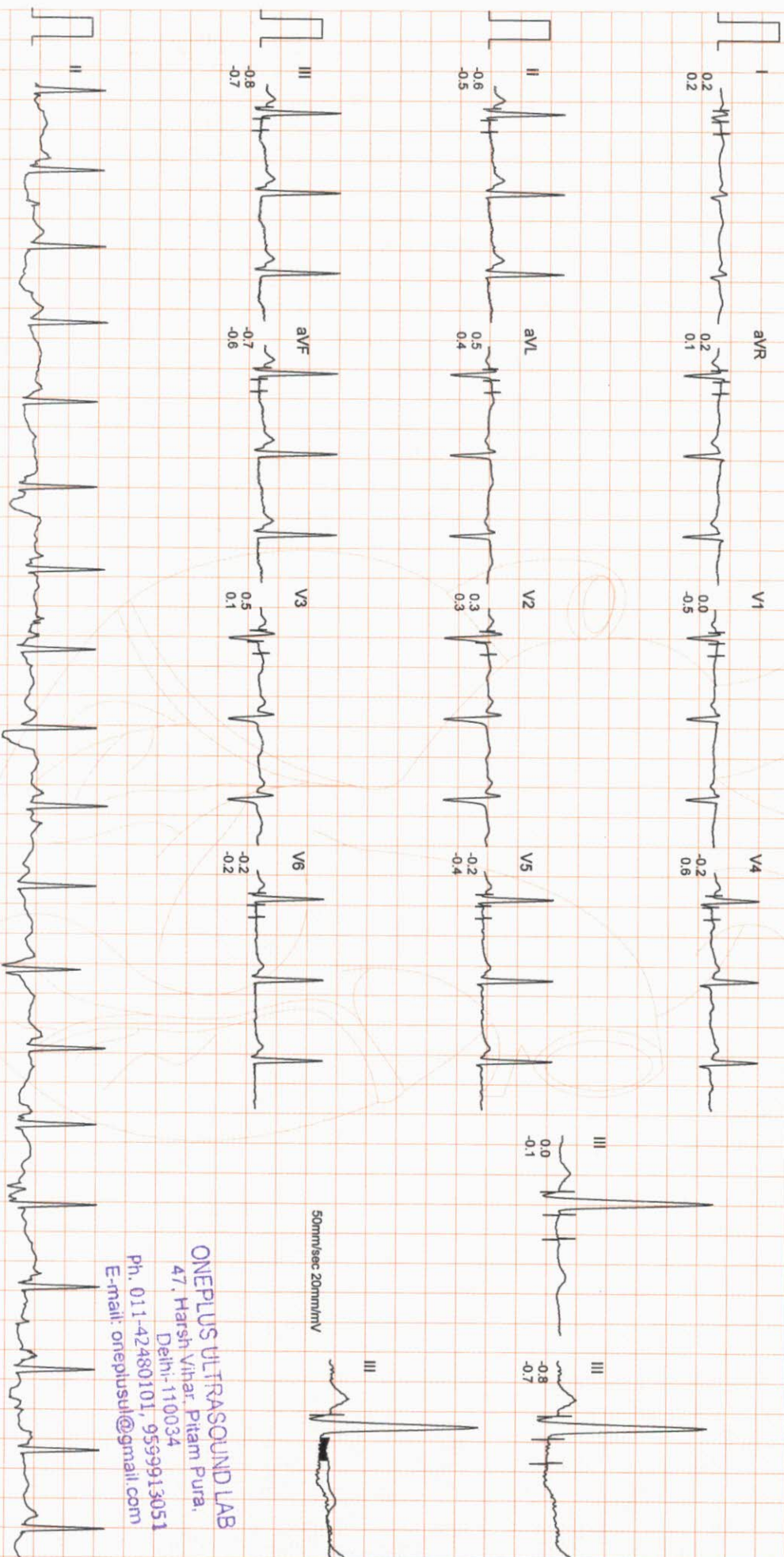
ST @ 10mm/mV

80ms PostI

SPEED : 2.7 Km./Hr.

GRADE : 10.0 %

LINKED MEDIAN



ONEPLUS ULTRASOUND LAB
47, Harsh Vihar, Pitam Pura,
Delhi-110034
Ph. 011-42480101, 9599913051
E-mail: oneplusul@gmail.com

ONEPLUS ULTRASOUND LAB

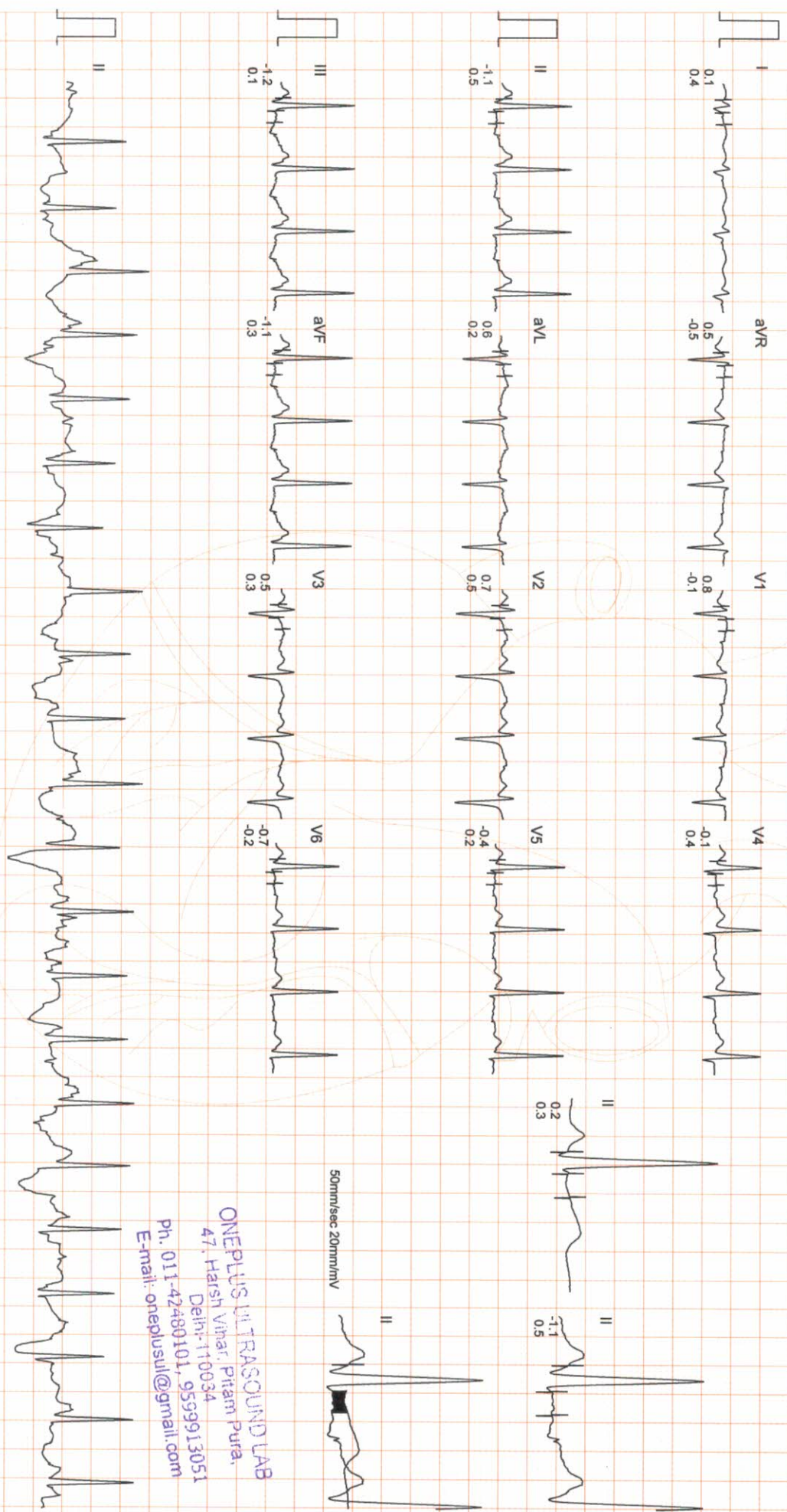
Ms. PALLAVI PALIWAL
I.D. : 998
AGE/SEX : 28/F
RECORDED : 6-2-2022 11:03

RATE : 136 BPM
B.P. : 134/82 mmHg

BRUCE
EXERCISE 2
PHASE TIME : 5:59
STAGE TIME : 2:59

ST @ 10mm/mV
80ms PostJ
SPEED : 4.0 Km./Hr.
GRADE : 12.0 %

LINKED MEDIAN



ONEPLUS ULTRASOUND LAB
47, Haish Vihar, Pitam Pura,
Delhi-110034
Ph. 011-42480101, 9539913051
E-mail: oneplusul@gmail.com

ONEPLUS ULTRASOUND LAB

Ms. PALLAVI PALIWAL

I.D. : 998

AGE/SEX : 28/F

RECORDED : 6-2-2022 11:03

RATE : 165 BPM
B.P. : 146/86 mmHg

BRUCE

EXERCISE 3

PHASE TIME : 8:59

STAGE TIME : 2:59

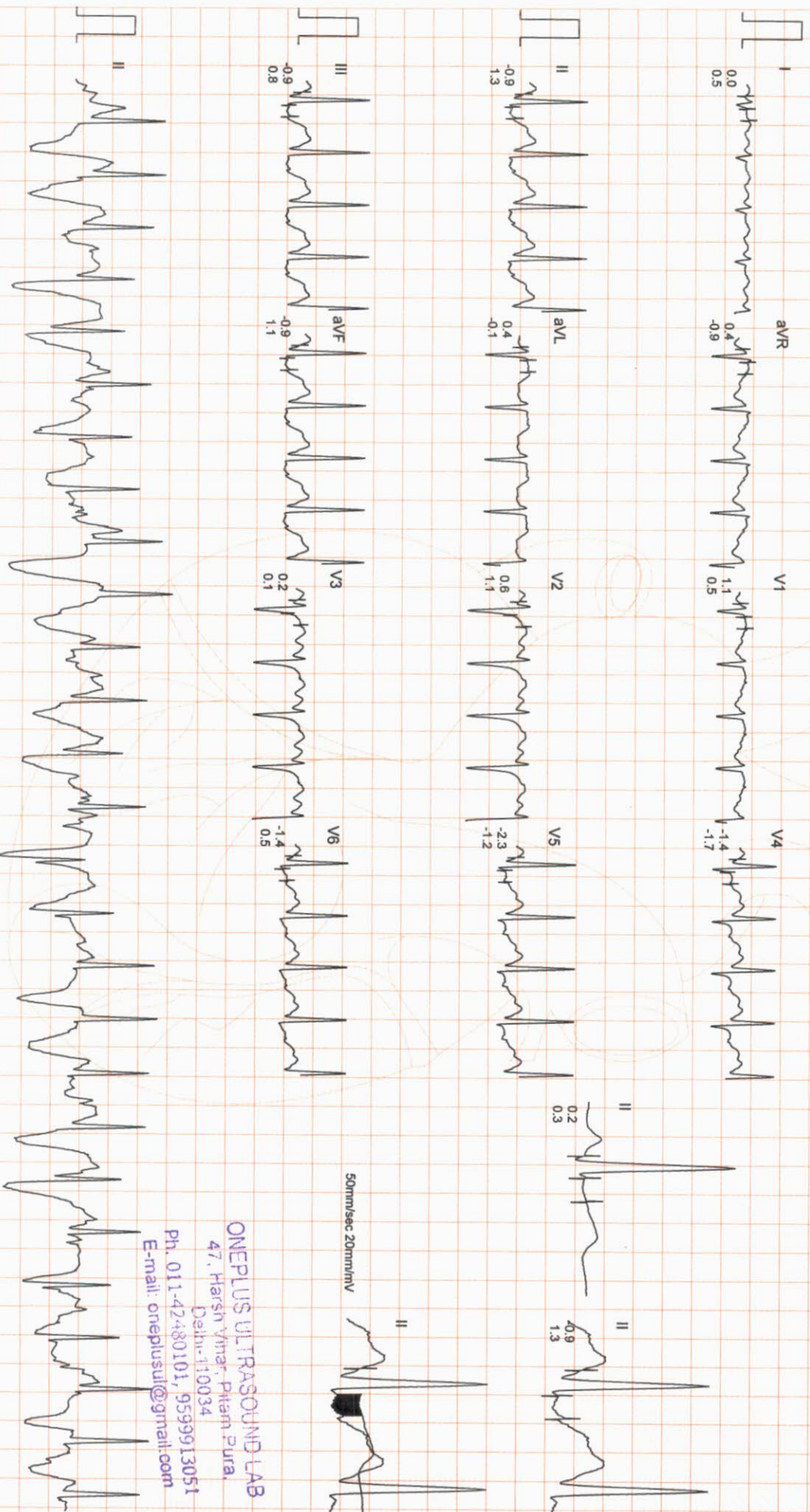
ST @ 10mm/mV

80ms PostJ

SPEED : 5.4 Km./Hr.

GRADE : 14.0 %

LINKED MEDIAN



ONEPLUS ULTRASOUND LAB
47, Harsn Ymar, Pitam Pura,
Delhi-110034
Ph. 011-42480101, 9539913051
E-mail: oneplusul@gmail.com

ONEPLUS ULTRASOUND LAB

Ms. PALLAVI PALIWAL

ID : 998

AGE/SEX : 28/F

RECORDED : 6-2-2022 11:03

RATE : 177 BPM

B.P. : 160/90 mmHg

BRUCE

EXERCISE 4

PHASE TIME : 9:14

STAGE TIME : 0:14

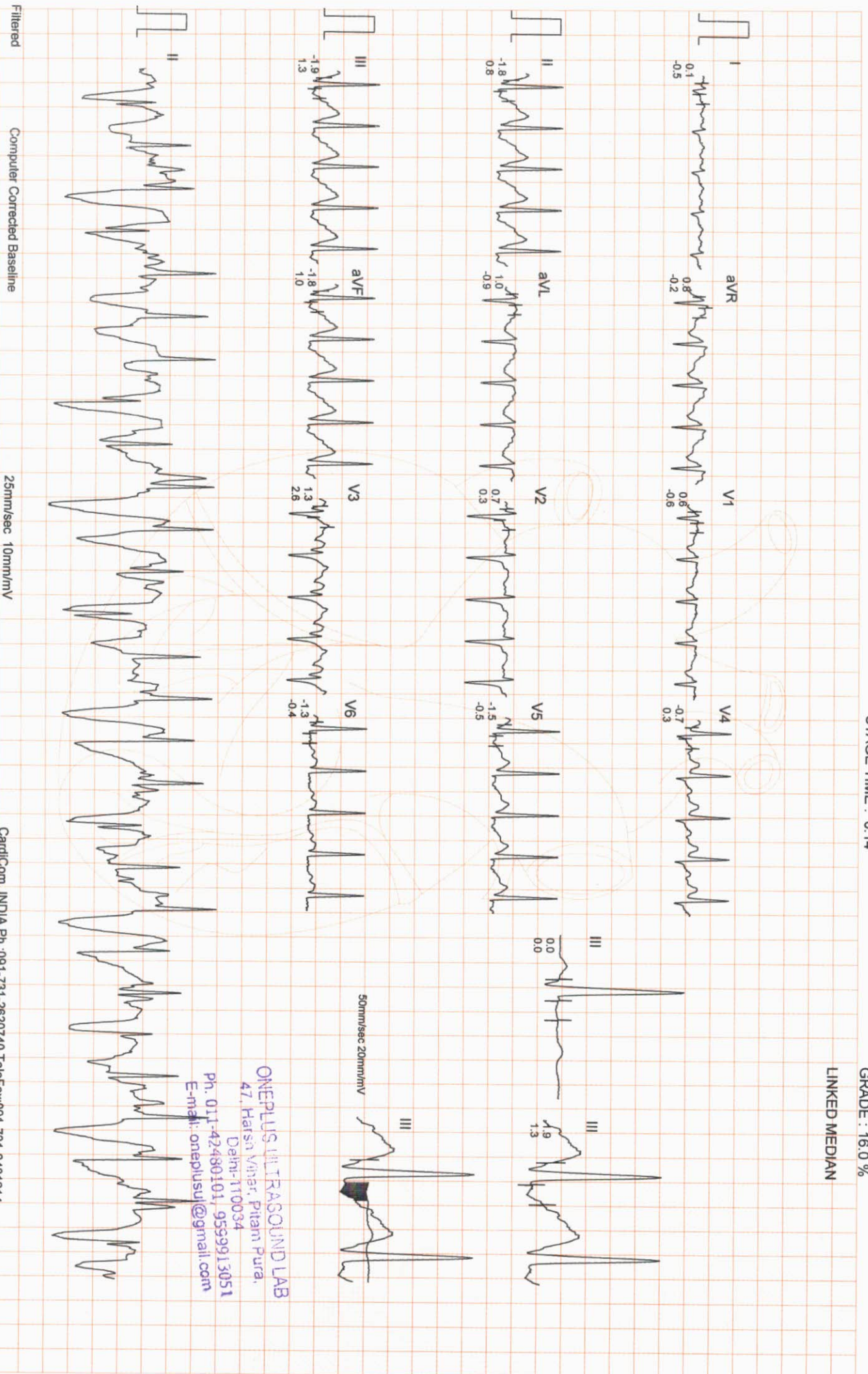
ST @ 10mm/mV

80ms PostJ

SPEED : 6.7 Km./Hr.

GRADE : 16.0 %

LINKED MEDIAN



ONEPLUS ULTRASOUND LAB
47, Harsn Vihar, Pitam Pura,
Delhi-110034
Ph. 011-42480101, 9559913051
E-mail: onepiusul@gmail.com

Filtered

Computer Corrected Baseline

25mm/sec 10mm/mV

CardiCom, INDIA Ph.:091-731-2620740, TeleFax:091-731-2431214

ONEPLUS ULTRASOUND LAB

Ms. PALLAVI PALIWAL

ID : 998

AGE/SEX : 28/F

RECORDED : 6-2-2022 11:03

RATE : 108 BPM

B.P. : 126/82 mmHg

BRUCE

RECOVERY

PHASE TIME : 2:59

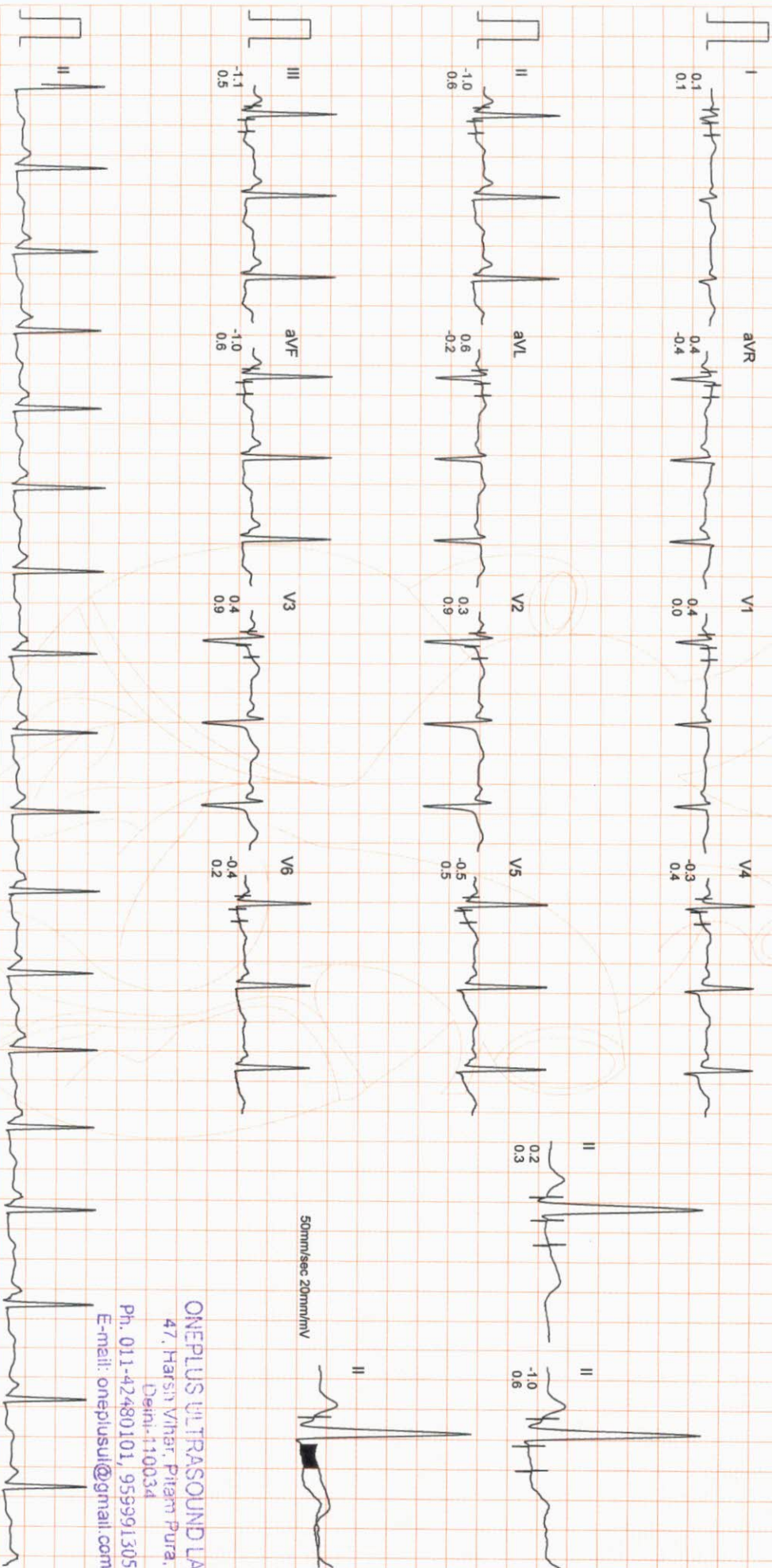
ST @ 10mm/mV

80ms PostJ

SPEED : 0.0 Km./Hr.

GRADE : 0.0 %

LINKED MEDIAN



ONEPLUS ULTRASOUND LAB

47, Harsih Vihar, Pitam Pura,

Delhi-110034

Ph. 011-42480101, 9599913051

E-mail: oneplusul@gmail.com

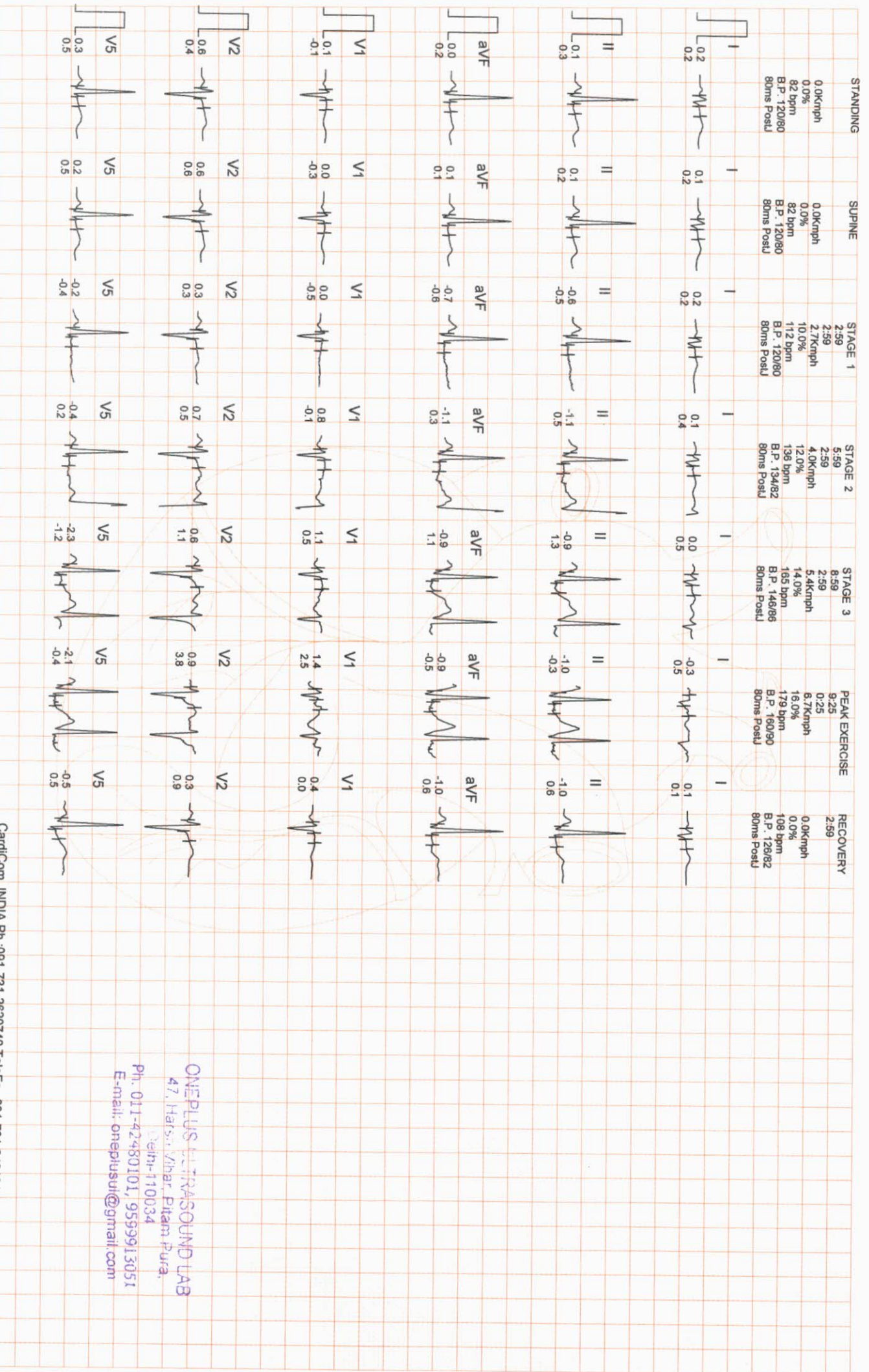Filtered

Computer Corrected Baseline

25mm/sec 10mm/mV

CardiCom, INDIA Ph.:091-731-2620740, TeleFax:091-731-2431214

ARROW






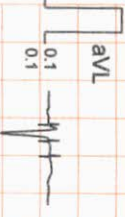






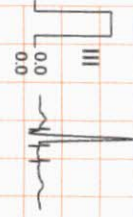

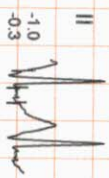
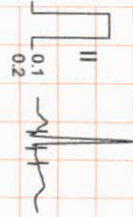




ONEPLUS ULTRASOUND LAB
 47, Harsha Vihar, Pitam Pura,
 Delhi-110034
 Ph. 011-42480101, 9559913051
 E-mail: oneplusul@gmail.com

SUPINE
 0.0kmph
 0.0%
 82 bpm
 B.P. 120/80
 80ms PostJ

PEAK EXERCISE
 9:25
 0.25
 6.7kmph
 16.0%
 179 bpm
 B.P. 160/90
 80ms PostJ

SUPINE
 0.0kmph
 0.0%
 82 bpm
 B.P. 120/80
 80ms PostJ

PEAK EXERCISE
 9:25
 0.25
 6.7kmph
 16.0%
 179 bpm
 B.P. 160/90
 80ms PostJ



ONEPLUS ULTRASOUND LAB
 47, Hars'i Vihar, Pitam Pura,
 Delhi-110034
 Ph. 011-42480101, 9539913051
 E-mail: oneplusul@gmail.com