

ECHO Report

Date: 14/5/2022

Patient Details

Patient ID – 20993
Name- MR CHANDRA SEKHAR
Age- 39 YEARS
Gender- MALE
Referral By - MEDIWHEEL

Doctor Incharge DR MAHESH PADSALGE

Clinical Status of Patient -

- Finding description -**
- 1. Normal cardiac chambers dimensions.**
 - 2. Normal LV systolic function.**
 - 3. No RWMA.**
 - 4. All cardiac valves are structurally normal.**
 - 5. Trivial MR, Trivial PR, NO AR.**
 - 6. No PAH.**
 - 7. Normal RV systolic function.**
 - 8. No clot/vegetation/pericardial effusion.**
 - 9. No coarctation of aorta.**

Chs chandra Sekhar

Chamber Dimensions-M mode Findings

LVID (Diastole) 35-56(mm)	- 41.00	LVID (Systole) 24-42(mm)	- 26.00
IVS (Diastole) 8-12(mm)	- 9.00	IVS (Systole) 14-42(mm)	- 14.00
LVPWT (Diastole) 6-11(mm)	- 9.00	EPSS	- 5.00
LVEF (%)	- 65%	LVFS (%)	- 35.00

LV Volume (Diastolic)(mm³)
Meridional Wall Stress in System

LV Volume (Systolic)(mm³)
Cubed LV Volume in Diastole (mm³)

Cubed LV+ myocardial volume (mm³)

Velocity of circumferential Shortening (mm)

Aortic root 22-37(mm)	- 28.00
Left Atrium Length (mm)	- 26.00
Left Atrium Volume (mm ³)	
RV size	Normal
Normal	
RV volume (mm ³)	
Normal	
Pericardium	Normal
Effusion	None
Resp Variation	Present
Predicted RV Systolic Pressure	

Left Atrium Width (mm)
Left Atrium Area (mm²)
RV Function

RA Size

IVC Size (mm) – 16 mm Collapsible

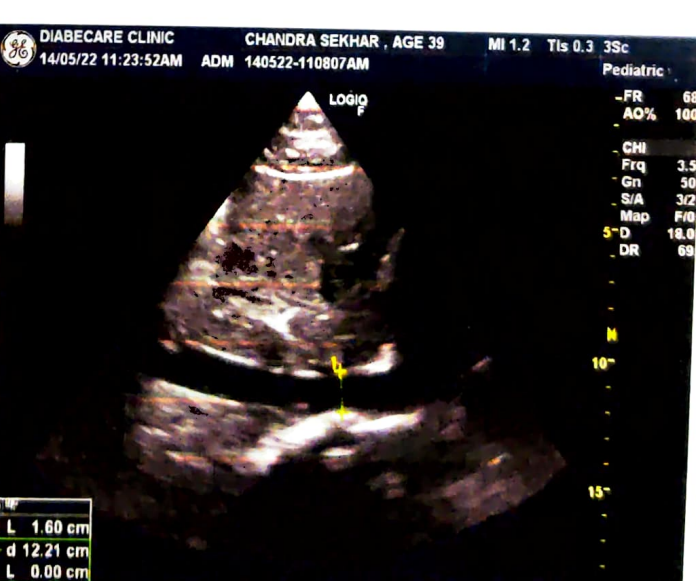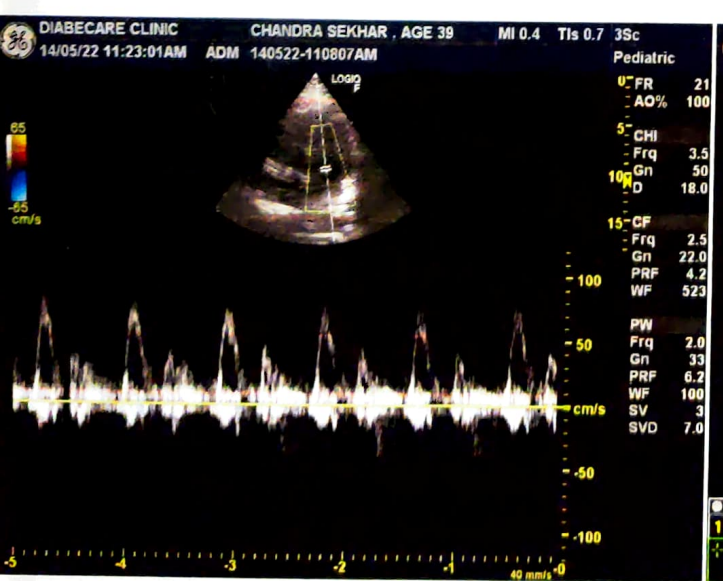
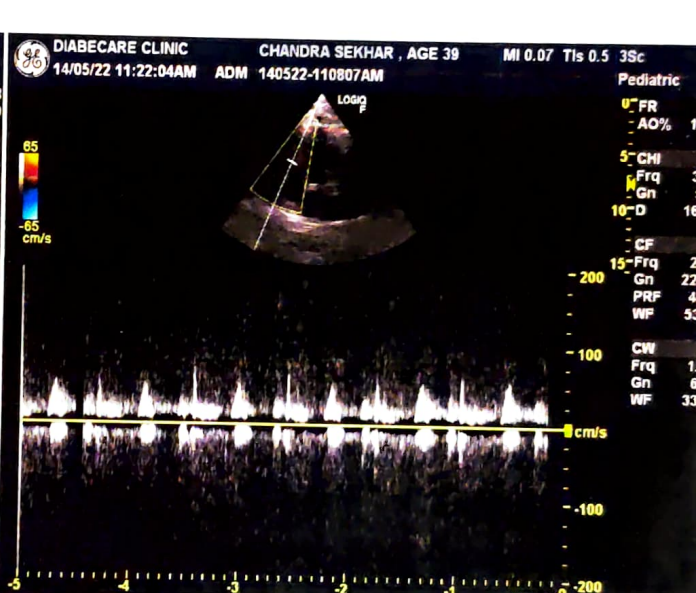
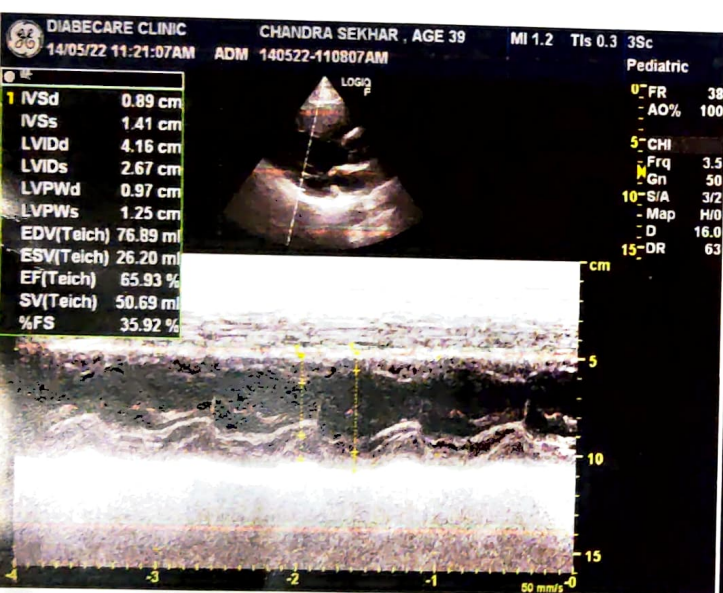
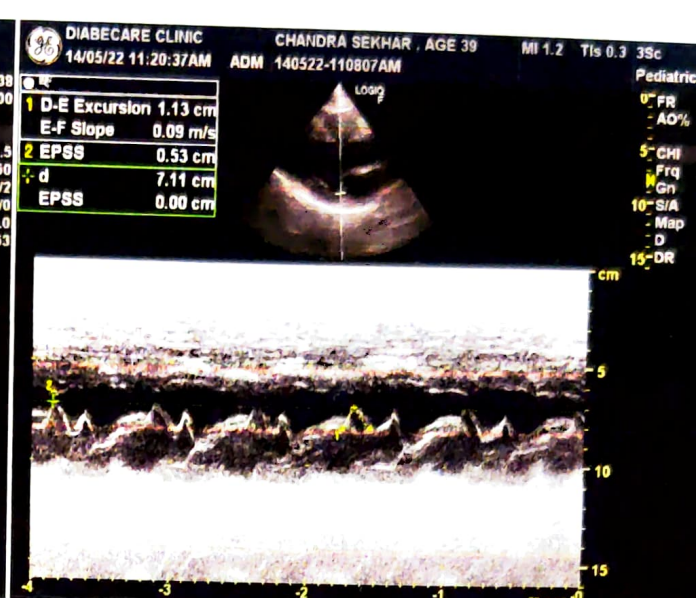
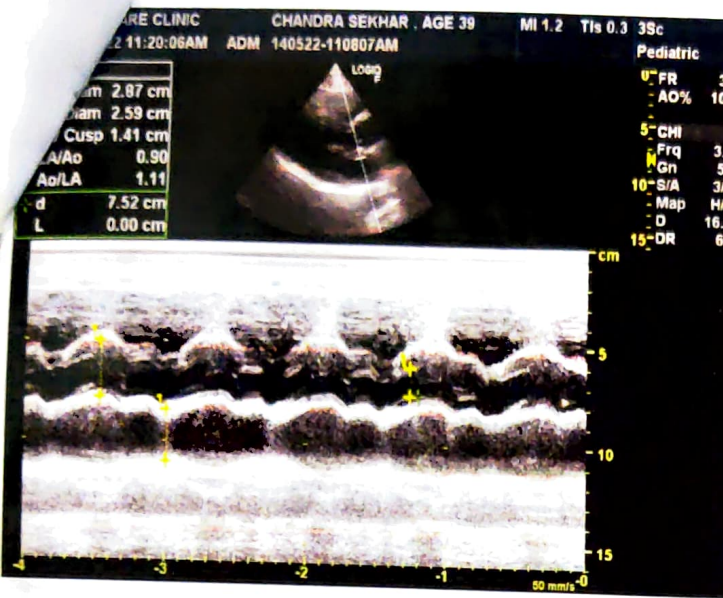
Doppler Findings- I



Dr. Mahesh Padsalge

Dr. Mahesh V. Padsalge
MD. (Medicine)
Consultant Physician
Reg. No. 91424 (MMC)

Arus chandra Setchan



14/05/2022



Diabecare
DIABETES & ENDOCRINE CLINIC

Mr. Chandra Sekhar
33/M

Eye check up

	Right Eye	Left Eye
VA	6/6	6/6
	N6	N6
		(N)
Ant Eye	(N)	NMD
Fundus	NMD	

Imp: Both Eyes (N6) WNL

ly

Vital Signs™ 226 166 05

Chandra, Shekhar
ID: 0

Male

QRS : 80 ms
QT / QTcBaz : 400 / 406 ms
PR : 134 ms
P : 92 ms
RR / PP : 964 / 967 ms
P / QRS / T : 54 / 43 / 41 degrees

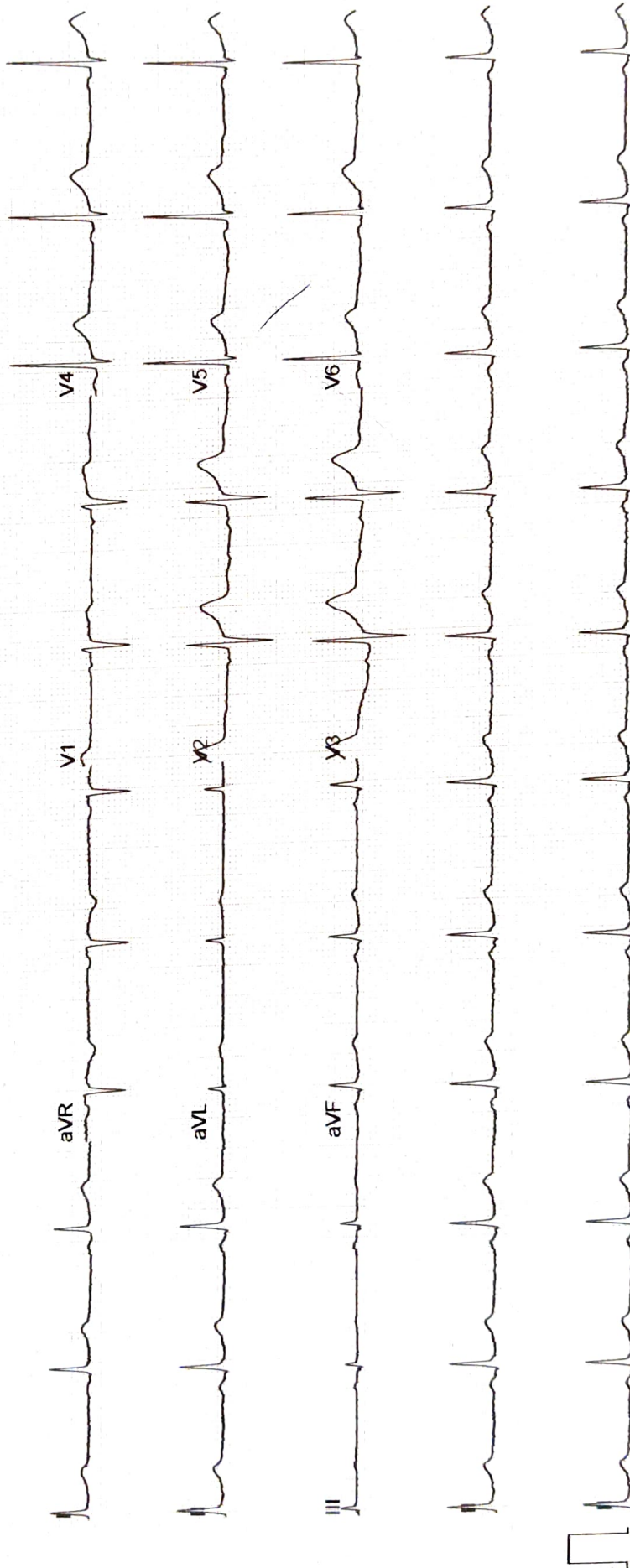
Normal sinus rhythm
Normal ECG

ECG in sin normal

Chandra Shekhar

[Signature]
Dr. Malieshi V. Padsalge
MD. (Medicine)
Consultant Physician
Reg. No. 91424 (MMC)

6Z
-- / -- mmHg



INDIAN UNION DRIVING LICENCE
TELANGANA STATE

TS00820150005338

G CHANDRA SEKHAR
GV RAJA GOPAL RAO
FLAT NO 201 PLOT NO 15
SRI RAM NAGAR COLONY
PEERZADIGUDA
GHATKESAR
MEDCHAL - 600092

DUPLICATE

Signature
Issued On: 27/04/2017

Licencing Authority
RTA UPPAL

Gvs chandra Sekhar

Dr. Mahesh V. Padsalge
 MD. (Medicine)
 Consultant Physician
 Reg. No. 91424 (MMC)

Non Transport Light Motor Vehicle Non Transport, Motor Cycle With Gear

Date of Validity Transport 18/08/2032

Date of Validity Badge No.

Reference No. DLDT5108672817

Original LA. RTA MEDCHAL

Date of First Issue 30/01/2015

Date of Birth 18/08/1982

Blood Group

DL1621160/15

NAME – CHANDRASHEKHAR**DATE- 14/05/2022****AGE- 39/M****X-RAY CHEST PA**

The Soft Tissues And Bony Thorax Are Normal.

Both The Costophrenic And Cardiophrenic Angles Are Clear.


The Lung Field Are Normal.

Cardiac Shape And Size Appears Normal.

Both The Hila Are Normal In Density And Position.

Both The Domes Of Diaphragm And Mediastinum Are Normal.

Impression: Normal Chest X-Ray.

For, 

**DR SIDRAM JADHAV
CONSULTANT RADIOLOGIST**

Dr. Sidram D. Jadhav
MBBS, DMRE (Radiologist)
Reg. No.: 2004 / 09 / 3526