

Name : Mrs. MITAL PATEL (32 /F)

Date : 09/03/2023

Address : MAHESANA, MAHESANA, MAHESANA, GUJARAT, INDIA

Examined by : Dr .BHAWANA DAGA

UHID : AHCC.0000127424

Package : MEDIWHEEL-FULL BODY CHK-BELOW40-FEMALE

AHC No : AHCCA4670



### CHIEF COMPLAINTS

For Annual health checkup  
No specific complaints

### PRESENT KNOWN ILLNESS

No history of - Diabetes mellitus,  
Hypertension,  
Dyslipidemia, Thyroid  
disorder, Heart disease,  
Stroke, Asthma, COPD,  
Cancer, Impaired Glycemia

### DRUG ALLERGY

NO KNOWN ALLERGY :09/03/2023

### SYSTEMIC REVIEW

#### Cardiovascular system

- Nil Significant

#### Past medical history

Do you have any - No

allergies?

Covid 19 - No

#### Surgical history

Surgical history - Nil

#### Immunization history

- Covid Dose1, Covid Dose2

#### Personal history

Marital status - Married

No. of children - 2

Diet - Eggs

Alcohol - does not consume alcohol

Smoking - No

Chews tobacco - No

Physical activity - Moderate

### Family history

Hypertension - father, mother

Coronary artery disease - none

Cancer - None

### PHYSICAL EXAMINATION

#### General

General appearance - normal

Height - 150

Weight - 49.1

BMI - 21.82

Pallor - No

Oedema - no

#### Cardiovascular system

Heart rate (Per minute) - 99

Rhythm - Regular

Systolic(mm of Hg) - 127

Diastolic(mm of Hg) - 84

Heart sounds - S1S2+

#### Respiratory system

Breath sounds - Normal vesicular breath sounds

#### Abdomen

Organomegaly - No

Tenderness - No

Printed By : BHAWANA DAGA



Name : Mrs. MITAL PATEL (32 /F)

UHID : AHCC.0000127424

Date 09/03/2023

Package : MEDIWHEEL-FULL BODY CHK-BELOW40-FEMALE

AHC No AHCCA4670



### URINE FOR ROUTINE EXAMINATION

Test Name	Result	Unit	Level	Range
Specific Gravity	1.015			
Colour:	Pale-Yellow			
Transparency:	Clear			
pH	5.5			
Protein :	Nil			
Sugar:	Nil			
Blood:	Negative			
Ketone	Absent			
Bile Pigments:	Absent			
Urobilinogen	Normal	E.U./d L		
Nitrite	Negative			
Pus Cells	Occasional			0-5
RBC	Nil	/hpf		0-5/hpf
Epithelial Cells	Occasional			
Casts:	Absent			
Crystals:	Absent			

Basophils	00	%	●	0-1
Platelet Count (Impedance)	353000	/cu mm	●	150000-450000
MPV (Calculated)	6.9 *	fl	●	7-11
ERYTHROCYTE SEDIMENTATION RATE (ESR) (Automated/ optic-electronic)	36 *	mm/1st hr	●	0-20

### BLOOD GROUPING AND TYPING (ABO and Rh)

Test Name	Result	Unit	Level	Range
BLOOD GROUP:	B Positive			

### LFT (LIVER FUNCTION TEST)

Test Name	Result	Unit	Level	Range
ALT(SGPT) - SERUM / PLASMA	10	U/L	●	0-35
ALKALINE PHOSPHATASE - SERUM/PLASMA	53	U/L	●	Adult(Female): 35 - 104
AST (SGOT) - SERUM	16	U/L	●	>1 year Female : <32
Total Bilirubin	0.44	mg/dL	●	0.300-1.200
Direct Bilirubin	0.175	mg/dL	●	Upto 0.3 mg/dl

### COMPLETE BLOOD COUNT WITH ESR

Test Name	Result	Unit	Level	Range
Hemoglobin (Photometric Measurement)	12.4	gm%	●	12-16
Packed cell volume(Calculated)	36.6	%	●	36-46
RBC COUNT (Impedance)	4.14	Million/ ul	●	3.8-5.2
MCV (From RBC Histogram)	88.4	fl	●	80-100
MCH(Calculated)	29.9	pg	●	27-32
MCHC(Calculated)	33.9	%	●	31-36
RDW(Calculated)	12.3	%	●	11.5-14.5
WBC Count (Impedance)	5300	/cu mm	●	4000-11000
Neutrophils	51	%	●	40-75
Lymphocytes	35	%	●	20-40
Monocytes	08	%	●	2-10
Eosinophils	06	%	●	01-06

● Within Normal Range      ● Borderline High/Low      ● Out of Range





Name : Mrs. MITAL PATEL (32 /F)

UHID : AHCC.0000127424

Date : 09/03/2023

Package : MEDIWHEEL-FULL BODY CHK-BELOW40-FEMALE

AHC No : AHCCA4670



Indirect Bilirubin  
by Joint Commission International

0.26

mg/dL ●

1 Day ≤5.1 mg/dL  
2 Days ≤7.2 mg/dL  
3-5 Days ≤10.3 mg/dL  
6-7 Days ≤8.4 mg/dL  
8-9 Days ≤6.5 mg/dL  
10-11 Days ≤4.6 mg/dL  
12-13 Days ≤2.7 mg/dL  
14 Days - 9 Years 0.2-0.8 mg/dL  
10-19 Years 0.2-1.1 mg/dL  
≥20 Years 0.2-1.2 mg/dL

Urine Glucose (Post Prandial)

Nil

### GLYCOSYLATED HEMOGLOBIN (HBA1C) - WHOLE BLOOD

Test Name	Result	Unit	Level	Range
Glycosylated Hemoglobin (HbA1c)	5.46	%	●	Normal < 5.7
				%Increased risk for Diabetes 5.7 - 6.4%
				Diabetes >= 6.5%
				Monitoring criteria for Diabetes Mellitus
				<7.0 : Well Controlled Diabetes
				7.1 – 8.0 : Unsatisfactory Control
				> 8.0 : Poor Control & Needs Immediate Treatment

### CREATININE - SERUM / PLASMA

Test Name	Result	Unit	Level	Range
CREATININE - SERUM / PLASMA	0.64	mg/dL	●	Adult Female: 0.5 - 1.2

### LFT (LIVER FUNCTION TEST)

Test Name	Result	Unit	Level	Range
GGTP: GAMMA GLUTAMYL TRANSPEPTIDASE - SERUM	8	U/L	●	Male : 10 - 71 Female : 6 - 42

### GLUCOSE - SERUM / PLASMA (FASTING)

Test Name	Result	Unit	Level	Range
Glucose - Plasma (Fasting)	98	mg/dL	●	70 - 100 : Normal 100 - 125 : Impaired Glucose Tolerance ≥ 126 : Diabetes Mellitus

### GLUCOSE - SERUM / PLASMA (POST PRANDIAL) - PPBS

Test Name	Result	Unit	Level	Range
Glucose - Plasma (Post Prandial)	157 *	mg/dL	●	70-140

● Within Normal Range    ● Borderline High/Low    ● Out of Range



Glycosylated Hemoglobin (HbA1c)	5.46	%	●	Normal < 5.7  %Increased risk for Diabetes 5.7 - 6.4%  Diabetes >= 6.5%  Monitoring criteria for Diabetes Mellitus <7.0 : Well Controlled Diabetes 7.1 – 8.0 : Unsatisfactory Control > 8.0 : Poor Control & Needs Immediate Treatment
Mean Blood Sugar	110			

Test Name	Result	Unit	Level	Range
URIC ACID - SERUM	3.6	mg/dL	●	Male : 3.4-7.0 Female : 2.4-5.7

**BUN (BLOOD UREA NITROGEN)**

Test Name	Result	Unit	Level	Range
BUN (BLOOD UREA NITROGEN)	10	mg/dL	●	6-20
UREA - SERUM / PLASMA	20	mg/dL	●	15 - 50

**LIPID PROFILE - SERUM**

Test Name	Result	Unit	Level	Range
Total Cholesterol	165	mg/dl	●	0 - 200 : Desirable 200 - 240 : Borderline High 240 - 280 : High > 280 : Very High
Triglycerides - Serum	54	mg/dL	●	0-150

Test Name	Result	Unit	Level	Range
HDL CHOLESTEROL - SERUM / PLASMA (Direct Enzymatic Colorimetric)	59 *	mg/dL	●	< 40 : Major risk factor for heart disease 40 - 59 : The higher The better. >=60 : Considered protective against heart disease

**LFT (LIVER FUNCTION TEST)**

Test Name	Result	Unit	Level	Range
PROTEIN TOTAL - SERUM / PLASMA	8.08 *	g/dL	●	6.00-8.00
ALBUMIN - SERUM	5.01	g/dL	●	Adult(18 - 60 Yr): 3.5 - 5.2
Globulin-Serum/Plasma	3.1		●	2.20-4.20
A/G ratio	1.6		●	1.00-2.00

**THYROID PROFILE (T3,T4 AND TSH)**

Test Name	Result	Unit	Level	Range
TOTAL T3: TRI IODOTHYRONINE - SERUM	0.923	ng/mL	●	0.8 - 2.0
TOTAL T4: THYROXINE - SERUM	7.18 *	ug/dL	●	5.1 - 14.1
TSH: THYROID STIMULATING HORMONE - SERUM	2.25	µIU/mL	●	14-120 years : 0.27 - 4.20

Test Name	Result	Unit	Level	Range
LDL Cholesterol (Direct LDL)	107	mg/dL	●	100 : Optimal 100-129 : Near Optimal 130-159 : Borderline High 160-189 : High >=190 : Very High
VLDL CHOLESTEROL	11		●	< 40 mg/dl
C/H RATIO	2.8		●	0-4.5

**ECHO/TMT**

**URIC ACID - SERUM**

● Within Normal Range    ● Borderline High/Low    ● Out of Range





Name : Mrs. MITAL PATEL (32 /F)

UHID : AHCC.0000127424

Date : 09/03/2023

Package : MEDIWHEEL-FULL BODY CHK-BELOW40-FEMALE

AHC No : AHCCA4670



Normal LV systolic function, LVEF: 60%.

Normal LV compliance.

No PAH.

### USG WHOLE ABDOMEN

Liver appears normal in size and shows uniform normal echotexture. No evidence of focal or diffuse pathology seen. Intra and extra hepatic biliary radicles are not dilated. Portal vein is normal in caliber. Intrahepatic portal radicles appear normal.

Gall bladder appears normal with no evidence of calculus. Wall thickness appears normal. No evidence of pericholecystic collection.

Visualized pancreas appear normal in size and echotexture. No focal lesions identified. Visualize pancreatic duct appears normal in caliber.

Spleen is normal in size and shows uniform echotexture.

Both kidneys are normal in size and show normal echopattern with good corticomedullary differentiation. Cortical outlines appear smooth. No evidence of calculi. Pelviccalyceal system on both sides appear normal.

No evidence of ascites or significant lymphadenopathy. Visualized bowel loops appear normal and shows normal peristalsis.

Urinary bladder is normal in contour and outline. Wall thickness appears normal. No evidence of any intraluminal pathology seen.

On transabdominal scan;

Uterus measures 7.5 x 3.6 x 4.3 cm. ET measures 7 mm.

Uterus is anteverted and appears normal in size and echotexture. No focal lesion noted. Myometrial and endometrial echotexture appears normal.

Both ovaries appears normal in size and echotexture. No definite evidence of adnexal/pelvic mass is seen.

### IMPRESSION :

No significant abnormality detected.

### X-RAY CHEST PA

NORMAL STUDY.

### INVESTIGATIONS NOT DONE / NOT YET REPORTED / NOT PART OF PACKAGE(LAB,RADIOLOGY & CARDIOLOGY)

#### Haematology

STOOL ROUTINE

URINE GLUCOSE(FASTING)

URINE GLUCOSE(POST PRANDIAL)

#### Histopathology

CONVENTIONAL PAP SMEAR /CERVICAL SMEAR

#### CARDIOLOGY

ECG

● Within Normal Range    ● Borderline High/Low    ● Out of Range



Name : Mrs. MITAL PATEL (32 /F)

UHID : AHCC.0000127424


Date : 09/03/2023

Package : MEDIWHEEL-FULL BODY CHK-BELOW40-FEMALE

AHC No : AHCCA4670




### Executive Summary


 ALL PHYSICAL FINDINGS ARE WNL.

### Wellness Prescription

#### Advice On Diet :-

 BALANCED DIET.

#### Advice On Physical Activity :-

 REGULAR EXERCISE.

Printed By : BHAWANA DAGA



AHC Physician / Consultant Internal Medicine

**Note :-** The Health Check-up examinations and routine investigations have certain limitations and may not be able to detect all the diseases. Any new or persisting symptoms should be brought to the attention of the Consulting Physician. Additional tests, consultations and follow up may be required in some cases.






Organization is Accredited  
by Joint Commission International



DEPARTMENT OF HAEMATOLOGY

Name : Mrs. MITAL PATEL Age : 32Yr 6Mth 15Days Gender : Female  
 UHID : AHCC.0000127424 / AHCCAH4670 W/BNo/RefNo : AHC  
 SIN \LRN : 3815887 \ 1635228  
 Specimen : Whole Blood ( EDTA )  
 Ref Doctor : DR. BHAWANA DAGA



Collected on : 09-MAR-2023 09:25:54 AM Received on : 09-MAR-2023 10:23:29 AM Reported on : 09-MAR-2023 11:34:09 AM

MEDIWHEEL-FULL BODY CHK-BELOW40-FEMALE

TEST NAME	RESULT	BIOLOGICAL REFERENCE INTERVALS	UNITS
<b>COMPLETE BLOOD COUNT WITH ESR</b>			
Hemoglobin (Photometric Measurement)	12.4	12 - 16	gm%
Packed cell volume(Calculated)	36.6	36 - 46	%
RBC COUNT (Impedance)	4.14	3.8 - 5.2	Million/ul
MCV (From RBC Histogram)	88.4	80 - 100	fl
MCH(Calculated)	29.9	27 - 32	pg
MCHC(Calculated)	33.9	31 - 36	%
RDW(Calculated)	12.3	11.5 - 14.5	%
WBC Count (Impedance)	5300	4000 - 11000	/cu mm
<b>Differential Count (VCS Technology and Microscopy)</b>			
Neutrophils	51	40 - 75	%
Lymphocytes	35	20 - 40	%
Monocytes	08	2 - 10	%
Eosinophils	06	01 - 06	%
Basophils	00	0 - 1	%
Platelet Count (Impedance)	353000	150000 - 450000	/cu mm
MPV (Calculated)	6.9 *	7 - 11	fl
<b>PERIPHERAL SMEAR(Microscopy)</b>			
ERYTHROCYTE SEDIMENTATION RATE (ESR) (Automated/ optic-electronic)	36 *	0 - 20	mm/1st hr

For Enquiry/Appointments Contact +91 76988 15003 / +91 79 66701880

**Apollo Hospitals International Limited**  
 Plot No. -1A, Bhat, GIDC, Gandhinagar, Gujarat - 382428, India.  
 Phone : +91 79 66701800 | Fax No. : +91 79 66701843  
 E-mail : info@apolloahd.com | www.ahmedabad.apollohospitals.com

**Apollo Hospitals - City Centre (NON NASH-JCI)**  
 1, TulsiBaag Society, Nr. Parimal Garden, Ahmedabad.  
 Phone : +91 79 66305800 / 01 or +91 76988 15148  
 E-mail : infoahcc@apolloahd.com

**Regd. Office**  
 19, Bishop Gardens, R.A. Puram, Chennai - 600 028  
 CIN No. : U85110TN1997PLC039016 | GSTin : 24AABCA4150H225  
 For online appointment : www.askapollo.com



For online appointment : www.askapollo.com  
 Keep the records carefully and bring them along during your next visit to our Hospital



Organization is Accredited  
by Joint Commission International



DEPARTMENT OF HAEMATOLOGY

Name : Mrs. MITAL PATEL Age : 32Yr 6Mth 15Days Gender : Female  
 UHID : AHCC.0000127424 / AHCCAH4670 W/BNo/RefNo : AHC  
 SIN \LRN : 3815887 \ 1635228  
 Specimen : Whole Blood ( EDTA )  
 Ref Doctor : DR. BHAWANA DAGA



Collected on : 09-MAR-2023 09:25:54 AM Received on : 09-MAR-2023 10:23:29 AM Reported on : 09-MAR-2023 11:34:09 AM

'09/03/2023  
Report Status:Final

\* END OF REPORT \*

CHECKED BY : 1217739  
723343

Printed On : 09-MAR-2023 04:28:18 PM

DR. JAYDEEP BARIYA,  
MD PATHOLOGY,  
CONSULTANT

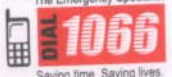For Enquiry/Appointments Contact +91 76988 15003 / +91 79 66701880

**Apollo Hospitals International Limited**  
Plot No.-1A, Bhat, GIDC, Gandhinagar, Gujarat - 382428, India.  
Phone : +91 79 66701800 | Fax No. : +91 79 66701843  
E-mail : info@apolloahd.com | www.ahmedabad.apollohospitals.com

**Apollo Hospitals - City Centre** (NON NABH-JCI)  
1, Tulsiabaug Society, Nr. Panimal Garden, Ahmedabad.  
Phone : +91 79 66305800 / 01 or +91 76988 15148  
E-mail : infoahcc@apolloahd.com

**Regd. Office**  
19, Bishop Gardens, R.A. Puram, Chennai - 600 028  
CIN No. : U85110TN1997PLC039016 | GSTin : 24AABCA4150H225  
For online appointment : www.askapollo.com

The Emergency Specialist



Saving time. Saving lives.

For online appointment : www.askapollo.com  
Keep the records carefully and bring them along during your next visit to our Hospital






Organization is Accredited  
by Joint Commission International



DEPARTMENT OF CLINICAL PATHOLOGY

Name : Mrs. MITAL PATEL Age : 32Yr 6Mth 15Days Gender : Female  
 UHID : AHCC.0000127424 / AHCCAH4670 W/BNo/RefNo : AHC  
 SIN \LRN : 3815884 \ 1635228  
 Specimen : Urine  
 Ref Doctor : DR. BHAWANA DAGA



Collected on : 09-MAR-2023 09:25:54 AM Received on : 09-MAR-2023 10:23:16 AM Reported on : 09-MAR-2023 12:23:52 PM

MEDIWHEEL-FULL BODY CHK-BELOW40-FEMALE

TEST NAME	RESULT	BIOLOGICAL REFERENCE INTERVALS	UNITS
<b>URINE FOR ROUTINE EXAMINATION : (Solubility Method)</b>			
<b>PHYSICAL EXAMINATION</b>			
Specific Gravity	1.015		
Colour:	Pale-Yellow		
Transparency:	Clear		
<b>CHEMICAL EXAMINATION</b>			
pH	5.5		
Protein :	Nil		
Sugar:	Nil		
Blood:	Negative		
Ketone	Absent		
Bile Pigments:	Absent		
Urobilinogen	Normal		E.U./dL
Nitrite	Negative		
<b>Cells:</b>			
Pus Cells	Occasional	0-5/hpf	
RBC	Nil	0-5/hpf	/hpf
Epithelial Cells	Occasional		
Casts:	Absent		
Crystals:	Absent		

For Enquiry/Appointments Contact +91 76988 15003 / +91 79 66701880

**Apollo Hospitals International Limited**  
 Plot No. -1A, Bhat, GIDC, Gandhinagar, Gujarat - 382428, India.  
 Phone : +91 79 66701800 | Fax No. : +91 79 66701843  
 E-mail : info@apolloahd.com | www.ahmedabad.apollohospitals.com

**Apollo Hospitals - City Centre (NON NABH-JCI)**  
 1, TulsiBaag Society, Nr. Parimal Garden, Ahmedabad.  
 Phone : +91 79 66305800 / 01 or +91 76988 15148  
 E-mail : infoahcc@apolloahd.com

**Regd. Office**  
 19, Bishop Gardens, R.A. Puram, Chennai - 600 028  
 CIN No. : U85110TN1997PLC039016 | GSTIn : 24AABCA4150H2Z5  
 For online appointment : www.askapollo.com



For online appointment : www.askapollo.com  
 Keep the records carefully and bring them along during your next visit to our Hospital



Organization is Accredited by Joint Commission International



DEPARTMENT OF CLINICAL PATHOLOGY

Name : Mrs. MITAL PATEL      Age : 32Yr 6Mth 15Days      Gender : Female  
 UHID : AHCC.0000127424 / AHCCA4670      W/BNo/RefNo : AHC  
 SIN \LRN : 3815884 \ 1635228  
 Specimen : Urine  
 Ref Doctor : DR. BHAWANA DAGA



Collected on : 09-MAR-2023 09:25:54 AM    Received on : 09-MAR-2023 10:23:16 AM    Reported on : 09-MAR-2023 12:23:52 PM

09/03/2023  
Report Status:Final

\* END OF REPORT \*

CHECKED BY : 1058662  
717880

Printed On : 09-MAR-2023 04:28:38 PM

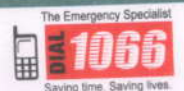Dr.HARDIK KOSHTI  
MD PATHOLOGY,  
CONSULTANT

For Enquiry/Appointments Contact +91 76988 15003 / +91 79 66701880

**Apollo Hospitals International Limited**  
Plot No.-1A, Bhat, GIDC, Gandhinagar, Gujarat - 382428, India.  
Phone : +91 79 66701800 | Fax No. : +91 79 66701843  
E-mail : info@apolloahd.com | www.ahmedabad.apollohospitals.com

**Apollo Hospitals - City Centre** (NOR NASH-JCI)  
1, Tulsibaug Society, Nr. Parimal Garden, Ahmedabad.  
Phone : +91 79 66305800 / 01 or +91 76988 15148  
E-mail : infoahcc@apolloahd.com

**Regd. Office**  
19, Bishop Gardens, R.A. Puram, Chennai - 600 028  
CIN No. : U85110TN1997PLC039016 | GSTIn : 24AABCA4150H2Z5  
For online appointment : www.askapollo.com



For online appointment : www.askapollo.com  
Keep the records carefully and bring them along during your next visit to our Hospital





Organization is Accredited  
by Joint Commission International



DEPARTMENT OF CLINICAL PATHOLOGY

Name : Mrs. MITAL PATEL Age : 32Yr 6Mth 15Days Gender : Female  
 UHID : AHCC.0000127424 / AHCCA4670 W/BNo/RefNo : AHC  
 SIN \LRN : 3815884 \ 1635228  
 Specimen : Urine  
 Ref Doctor : DR. BHAWANA DAGA



Collected on : 09-MAR-2023 09:25:54 AM Received on : 09-MAR-2023 10:23:16 AM Reported on : 09-MAR-2023 12:23:52 PM

MEDIWHEEL-FULL BODY CHK-BELOW40-FEMALE

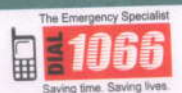TEST NAME	RESULT	BIOLOGICAL REFERENCE INTERVALS	UNITS
<b>URINE FOR ROUTINE EXAMINATION : (Solubility Method)</b>			
<b>PHYSICAL EXAMINATION</b>			
Specific Gravity	1.015		
Colour:	Pale-Yellow		
Transparency:	Clear		
<b>CHEMICAL EXAMINATION</b>			
pH	5.5		
Protein :	Nil		
Sugar:	Nil		
Blood:	Negative		
Ketone	Absent		
Bile Pigments:	Absent		
Urobilinogen	Normal		E.U./dL
Nitrite	Negative		
<b>Cells:</b>			
Pus Cells	Occassional	0-5/hpf	
RBC	Nil	0-5/hpf	/hpf
Epithelial Cells	Occassional		
Casts:	Absent		
Crystals:	Absent		

For Enquiry/Appointments Contact: +91 76988 15003 / +91 79 66701880

**Apollo Hospitals International Limited**  
 Plot No.-1A, Bhat, GIDC, Gandhinagar, Gujarat - 382428, India.  
 Phone : +91 79 66701800 | Fax No. : +91 79 66701843  
 E-mail : info@apolloahd.com | www.ahmedabad.apollohospitals.com

**Apollo Hospitals - City Centre (NON HARB-JC)**  
 1, Tulsibaug Society, Nr. Parimal Garden, Ahmedabad.  
 Phone : +91 79 66305800 / 01 or +91 76988 15148  
 E-mail : infoahcc@apolloahd.com

**Regd. Office**  
 19, Bishop Gardens, R.A. Puram, Chennai - 600 028  
 CIN No. : U85110TN1997PLC039016 | GSTIN : 24AA8CA4150H2Z5  
 For online appointment : www.askapollo.com



For online appointment : www.askapollo.com  
 Keep the records carefully and bring them along during your next visit to our Hospital



Organization is Accredited  
by Joint Commission International



DEPARTMENT OF CLINICAL PATHOLOGY

Name : Mrs. MITAL PATEL      Age : 32Yr 6Mth 15Days      Gender : Female  
 UHID : AHCC.0000127424 / AHCCAH4670      W/BNo/RefNo : AHC  
 SIN \LRN : 3815884 \ 1635228  
 Specimen : Urine  
 Ref Doctor : DR. BHAWANA DAGA



Collected on : 09-MAR-2023 09:25:54 AM    Received on : 09-MAR-2023 10:23:16 AM    Reported on : 09-MAR-2023 12:23:52 PM

\*09/03/2023

Report Status:Final

\* END OF REPORT \*

CHECKED BY : 1058662  
717880

First Report Printed On : 09-MAR-2023 04:28:41 PM  
Printed On : 09-MAR-2023 04:29:37 PM

Dr.HARDIK KOSHTI  
MD PATHOLOGY,  
CONSULTANT

For Enquiry/Appointments Contact +91 76988 15003 / +91 79 66701880

**Apollo Hospitals International Limited**  
Plot No.-1A, Bhat, GIDC, Gandhinagar, Gujarat - 382428, India.  
Phone : +91 79 66701800 | Fax No. : +91 79 66701843  
E-mail : info@apolloahd.com | www.ahmedabad.apollohospitals.com

**Apollo Hospitals - City Centre** (NON NABH-JCI)  
1, Tulsibaug Society, Nr. Parimal Garden, Ahmedabad.  
Phone : +91 79 66305800 / 01 or +91 76988 15148  
E-mail : infoahcc@apolloahd.com

**Regd. Office**  
19, Bishop Gardens, R.A. Puram, Chennai - 600 028  
CIN No. : U85110TN1997PLC039016 | GSTIn : 24AABCA4150H225  
For online appointment : www.askapollo.com



For online appointment : www.askapollo.com  
Keep the records carefully and bring them along during your next visit to our Hospital

Saving time. Saving lives.





Organization is Accredited  
by Joint Commission International



DEPARTMENT OF BIOCHEMISTRY AND IMMUNOLOGY

Name : Mrs. MITAL PATEL Age : 32Yr 6Mth 15Days Gender : Female  
 UHID : AHCC.0000127424 / AHCCAH4670 W/BNo/RefNo : AHC  
 SIN \ LRN : 3815881 \ 3815880 \ 3815883 \ 3815885 \  
 Specimen : 1635228 Serum  
 Ref Doctor : DR. BHAWANA DAGA



Collected on : 09-MAR-2023 09:25:54 AM Received on : 09-MAR-2023 10:22:58 AM Reported on : 09-MAR-2023 12:34:37 PM

MEDIWHEEL-FULL BODY CHK-BELOW40-FEMALE

TEST NAME	RESULT	BIOLOGICAL REFERENCE INTERVALS	UNITS
GLYCOSYLATED HEMOGLOBIN (HBA1C) - WHOLE BLOOD (Immunoturbidimetric)	5.46	Normal < 5.7%  Increased risk for Diabetes 5.7 - 6.4%  Diabetes >= 6.5%  Monitoring criteria for Diabetes Mellitus <7.0 : Well Controlled Diabetes 7.1 – 8.0 : Unsatisfactory Control > 8.0 : Poor Control & Needs Immediate Treatment	%
Mean Blood Sugar GLUCOSE - SERUM / PLASMA (FASTING) (Hexokinase)	110 98	70 - 100 : Normal 100 - 125 : Impaired Glucose Tolerance >= 126 : Diabetes Mellitus	mg/dL
ALT(SGPT) - SERUM / PLASMA (UV without P5P)	10	Adult Female : <34	U/L
ALKALINE PHOSPHATASE - SERUM/PLASMA (PNP AMP BUFFER)	53	Adult(Female): 35 - 104	U/L
AST (SGOT) - SERUM	16	>1 year Female : <32	U/L

For Enquiry/Appointments Contact +91 76988 15003 / +91 79 66701880

**Apollo Hospitals International Limited**  
 Plot No. -1A, Bhat, GIDC, Gandhinagar, Gujarat - 382428, India.  
 Phone : +91 79 66701800 | Fax No. : +91 79 66701843  
 E-mail : info@apolloahd.com | www.ahmedabad.apollohospitals.com

**Apollo Hospitals - City Centre** (NON NABH-JCI)  
 1, Tulsibaug Society, Nr. Panimal Garden, Ahmedabad.  
 Phone : +91 79 66305800 / 01 or +91 76988 15148  
 E-mail : infoahcc@apolloahd.com

**Regd. Office**  
 19, Bishop Gardens, R.A. Puram, Chennai - 600 028  
 CIN No. : U85110TN1997PLC039016 | GSTin : 24AABCA4150H225  
 For online appointment : www.askapollo.com



For online appointment : www.askapollo.com  
 Keep the records carefully and bring them along during your next visit to our Hospital



Organization is Accredited  
by Joint Commission International



DEPARTMENT OF BIOCHEMISTRY AND IMMUNOLOGY

--

Name : Mrs. MITAL PATEL Age : 32Yr 6Mth 15Days Gender : Female  
 UHID : AHCC.0000127424 / AHCCA4670 W/BN/RefNo : AHC  
 SIN \ LRN : 3815881 \ 3815880 \ 3815883 \ 3815885 \  
 Specimen : 1635228 Serum  
 Ref Doctor : DR. BHAWANA DAGA



Collected on : 09-MAR-2023 09:25:54 AM Received on : 09-MAR-2023 10:22:58 AM Reported on : 09-MAR-2023 12:34:37 PM

(UV without P5P)

**BILIRUBIN (DIRECT/INDIRECT/TOTAL) - SERUM**

(Diazotization)

<b>Bilirubin Total</b>	<b>0.44</b>	0-1 days : 0 - 6mg/dl 1-2 days : 0 - 8mg/dl 2-5 days : 0 - 12mg/dl 5days - 4 months : 0.3 - 1.2mg/dl >4 months : 0.3-1.2 mg/dl	mg/dL
<b>Direct Bilirubin</b>	<b>0.175</b>	Upto 0.3 mg/dl	mg/dL
<b>Indirect Bilirubin</b>	<b>0.26</b>	1 Day ≤5.1 mg/dL 2 Days ≤7.2 mg/dL 3-5 Days ≤10.3 mg/dL 6-7 Days ≤8.4 mg/dL 8-9 Days ≤6.5 mg/dL 10-11 Days ≤4.6 mg/dL 12-13 Days ≤2.7 mg/dL 14 Days - 9 Years 0.2-0.8 mg/dL 10-19 Years 0.2-1.1 mg/dL ≥20 Years 0.2-1.2 mg/dL	mg/dL
<b>CREATININE - SERUM / PLASMA</b>	<b>0.64</b>	Adult Female: 0.5 - 1.2	mg/dL
(Alkaline picrate - kinetic rate blanked)			
<b>GGTP: GAMMA GLUTAMYL TRANSPEPTIDASE - SERUM</b>	<b>8</b>	Male : 10 - 71 Female : 6 - 42	U/L
(IFCC)			
<b>PROTEIN TOTAL - SERUM / PLASMA</b>	<b>8.08 *</b>	>2 Year: 6.0 - 8.0	g/dL
(Biuret)			
<b>ALBUMIN - SERUM</b>	<b>5.01</b>	Adult(18 - 60 Yr): 3.5 - 5.2	g/dL

For Enquiry/Appointments Contact +91 76988 15003 / +91 79 66701880

**Apollo Hospitals International Limited**  
 Plot No.-1A, Bhat, GIDC, Gandhinagar, Gujarat - 382428, India.  
 Phone : +91 79 66701800 | Fax No. : +91 79 66701843  
 E-mail : info@apolloahd.com | www.ahmedabad.apollohospitals.com

**Apollo Hospitals - City Centre (NON NABH-JCI)**  
 1, TulsiBaag Society, Nr. Parimal Garden, Ahmedabad.  
 Phone : +91 79 66305800 / 01 or +91 79988 15148  
 E-mail : infoahcc@apolloahd.com

**Regd. Office**  
 19, Bishop Gardens, R.A. Puram, Chennai - 600 028  
 CIN No. : U85110TN1997PLC039016 | GSTin : 24AABCA4150HZZ5  
 For online appointment : www.askapollo.com



For online appointment : www.askapollo.com  
 Keep the records carefully and bring them along during your next visit to our Hospital

The Emergency Specialist  
 Saving time. Saving lives.











Name : Mrs. MITAL PATEL

Age : 32Yr 6Mth 15Days

Gender : Female

Organization is Accredited  
by Joint Commission International

UHID : AHCC.0000127424 / AHCCA4670

W/BNo/RefNo : AHC

SIN \LRN : 3815886 \ 1635228

Specimen : Blood

Ref Doctor : DR. BHAWANA DAGA



Collected on : 09-MAR-2023 09:25:54 AM Received on : 09-MAR-2023 04:32:54 PM Reported on : 09-MAR-2023 07:44:47 PM

**MEDIWHEEL-FULL BODY CHK-BELOW40-FEMALE****TEST NAME****RESULT****BLOOD GROUPING AND TYPING (ABO and Rh)**

BLOOD GROUP: B Positive


Report Status:Final

\* END OF REPORT \*

CHECKED BY : 1235263

717844

Printed On : 10-MAR-2023 11:16:24 AM

  
 Dr. SANJAY GUPTA  
 MBBS, DIHBT,  
 CONSULTANT, BLOOD BANK

Page 1 of 1

For Enquiry/Appointments Contact +91 76988 15003 / +91 79 66701880

**Apollo Hospitals International Limited**  
 Plot No.-1A, Bhat, GIDC, Gandhinagar, Gujarat - 382428, India.  
 Phone : +91 79 66701800 | Fax No. : +91 79 66701843  
 E-mail : info@apolloahd.com | www.ahmedabad.apollohospitals.com

**Apollo Hospitals - City Centre** (NON NABH-JCI)  
 1, Tulsibaug Society, Nr. Parimal Garden, Ahmedabad.  
 Phone : +91 79 66305800 / 01 or +91 76988 15148  
 E-mail : infoahcc@apolloahd.com

**Regd. Office**  
 19, Bishop Gardens, R.A. Puram, Chennai - 600 028  
 CIN No. : U85110TN1997PLC039016 | GSTin : 24AABCA4150H2Z5  
 For online appointment : www.askapollo.com

The Emergency Specialist



Saving time. Saving lives.


For online appointment : www.askapollo.com  
 Keep the records carefully and bring them along during your next visit to our Hospital



Organization is Accredited  
by Joint Commission International



## DEPARTMENT OF RADIOLOGY AND IMAGING SCIENCES

**Patient Details** : Mrs. MITAL PATEL | Female | 32Yr 6Mth 15Days  
**UHID** : AHCC.0000127424 **Patient Location:** AHC  
**Patient Identifier:** AHCCA4670   
**DRN** : 123030847 **Completed on :** 09-MAR-2023 09:01  
**Ref Doctor** : DR. BHAWANA DAGA

### X-RAY CHEST PA


#### FINDINGS :

Both lung fields appear normal. No evidence of consolidation or collapse.  
 Bilateral hilar shadows appear normal. Trachea and major bronchi appear normal.  
 Cardiothoracic ratio is normal.  
 Both costophrenic angles are clear. Domes of diaphragm are well delineated.  
 Visualized bony thorax appear normal.

#### IMPRESSION

NORMAL STUDY.

— END OF THE REPORT —



TIRTH VINAYKUMAR PARIKH

Printed on : 09-Mar-2023 12:13

Printed By : 1010896

Reported By : 717876

Page 1 of 1

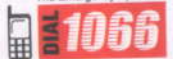For Enquiry/Appointments Contact +91 76988 15003 / +91 79 66701880

**Apollo Hospitals International Limited**  
 Plot No.-1A, Bhat, GIDC, Gandhinagar, Gujarat - 382428, India.  
 Phone : +91 79 66701800 | Fax No. : +91 79 66701843  
 E-mail : info@apolloahd.com | www.ahmedabad.apollohospitals.com

**Apollo Hospitals - City Centre** (NON NABH-JCI)  
 1, Tulsibaug Society, Nr. Parimal Garden, Ahmedabad.  
 Phone : +91 79 66305800 / 01 or +91 76988 15148  
 E-mail : infoahcc@apolloahd.com

**Regd. Office**  
 19, Bishop Gardens, R.A. Puram, Chennai - 600 028  
 CIN No. : U85110TN1997PLC039016 | GSTin : 24AABCA4150H225  
 For online appointment : www.askapollo.com

The Emergency Specialist



Saving time. Saving lives.

For online appointment : [www.askapollo.com](http://www.askapollo.com)  
 Keep the records carefully and bring them along during your next visit to our Hospital





Organization is Accredited  
by Joint Commission International



## DEPARTMENT OF RADIOLOGY AND IMAGING SCIENCES

**Patient Details** : Mrs. MITAL PATEL | Female | 32Yr 6Mth 15Days  
**UHID** : AHCC.0000127424 **Patient Location:** AHC  
**Patient Identifier:** AHCCA4670   
**DRN** : 223013148 **Completed on :** 09-MAR-2023 09:20  
**Ref Doctor** : DR. BHAWANA DAGA

### USG WHOLE ABDOMEN

#### IMPRESSION

Liver appears normal in size and shows uniform normal echotexture. No evidence of focal or diffuse pathology seen. Intra and extra hepatic biliary radicles are not dilated. Portal vein is normal in caliber. Intrahepatic portal radicles appear normal.

Gall bladder appears normal with no evidence of calculus. Wall thickness appears normal. No evidence of pericholecystic collection.

Visualized pancreas appear normal in size and echotexture. No focal lesions identified.

Visualize pancreatic duct appears normal in caliber.

Spleen is normal in size and shows uniform echotexture.

Both kidneys are normal in size and show normal echopattern with good corticomedullary differentiation. Cortical outlines appear smooth. No evidence of calculi. Pelvicalyceal system on both sides appear normal.

No evidence of ascites or significant lymphadenopathy. Visualized bowel loops appear normal and shows normal peristalsis.

Urinary bladder is normal in contour and outline. Wall thickness appears normal. No evidence of any intraluminal pathology seen.

On transabdominal scan;

Uterus measures 7.5 x 3.6 x 4.3 cm. ET measures 7 mm.

Uterus is anteverted and appears normal in size and echotexture. No focal lesion noted. Myometrial and endometrial echotexture appears normal.

Both ovaries appears normal in size and echotexture. No definite evidence of adnexal/pelvic mass is seen.

#### IMPRESSION :

No significant abnormality detected.

Printed on : 09-Mar-2023 12:13

Printed By : 1010896

Reported By : 717876

Page 1 of 2

For Enquiry/Appointments Contact +91 76988 15003 / +91 79 66701880

**Apollo Hospitals International Limited**  
Plot No.-1A, Bhat, GIDC, Gandhinagar, Gujarat - 382428, India.  
Phone : +91 79 66701800 | Fax No. : +91 79 66701843  
E-mail : info@apolloahd.com | www.ahmedabad.apollohospitals.com

**Apollo Hospitals - City Centre (NON NABH-IC)**  
1, Tulsibaug Society, Nr. Parimal Garden, Ahmedabad.  
Phone : +91 79 66305800 / 01 or +91 79 66305800  
E-mail : infoahcc@apolloahd.com

**Regd. Office**  
19, Bishop Gardens, R.A. Puram, Chennai - 600 028  
CIN No. : U85110TN1997PLC039016 | GSTIn : 24AABCA4150H225  
For online appointment : www.askapollo.com



For online appointment : www.askapollo.com  
Keep the records carefully and bring them along during your next visit to our Hospital



Organization is Accredited  
by Joint Commission International



Mrs. MITAL PATEL

AHCC.0000127424

AHCCA4670

USG WHOLE ABDOMEN

--- END OF THE REPORT ---

T.V. Parikh

TIRTH VINAYKUMAR PARIKH

Printed on : 09-Mar-2023 12:13

Printed By : 1010896

Reported By : 717876

Page 2 of 2

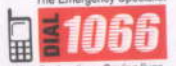For Enquiry/Appointments Contact +91 76988 15003 / +91 79 66701880

**Apollo Hospitals International Limited**  
Plot No.-1A, Bhat, GIDC, Gandhinagar, Gujarat - 382428, India.  
Phone : +91 79 66701800 | Fax No. : +91 79 66701843  
E-mail : info@apolloahd.com | www.ahmedabad.apollohospitals.com

**Apollo Hospitals - City Centre** (NON NASH-JCI)  
1, Tulsibaug Society, Nr. Parimal Garden, Ahmedabad.  
Phone : +91 79 66305800 / 01 or +91 76988 15148  
E-mail : infoahcc@apolloahd.com

**Regd. Office**  
19, Bishop Gardens, R.A. Puram, Chennai - 600 028  
CIN No. : U85110TN1997PLC039016 | GSTin : 24AABCA4150H2Z5  
For online appointment : www.askapollo.com

The Emergency Specialist



Saving time. Saving lives.

For online appointment : [www.askapollo.com](http://www.askapollo.com)  
Keep the records carefully and bring them along during your next visit to our Hospital





**OBSTETRICS & GYNAECOLOGY - AHC**

Name : .....

Date : ..... Unit No. : .....

Occupation : .....

Ref. Physician : .....

Age : ..... Sex :  Male  Female

Copies to : .....

**GYNAEC CHECK UP**

Chief Complaint:

Nil

Children: 2 FTND (♂ 6 YD, ♀ 2 YD)

Weight:

Deliveries: 2

BP:

Last Child: 2 YD

Abortions: 1

Breasts: NAD

Periods: Regular

PAP Smear: Done

LMP: 1/03/23

Previous Medical H/O:

Menopause: -

Nil

G. Condition: Good

Previous Surgical H/O:

P/A: soft

Nil

S/E: Cervical erosion +

P/V: w/AV-NS, fx clear

P/R:

Impression:

J C Desai

Doctor Signature  
Date & Time



**ELECTROCARDIOGRAM REPORT**

AHCC.0000127424  
MRS. MITAL PATEL  
Age: 32 Year(s) Year(s)/Female  
9 Mar 2023 8:32:59 AM



Name: \_\_\_\_\_ Age/Sex: \_\_\_\_\_ Date: \_\_\_\_\_  
Ref. By: \_\_\_\_\_ ECG No. \_\_\_\_\_ UHID/IP: \_\_\_\_\_

Referral Diagnosis:

Atria - Rate:

Rhythm:

Axis:

PR Interval:

P Wave:

Voltage:

Q Wave:

S-T Changes:

Final Impression:

Reported By:

*NSK/wm*

Ventricular Rate:

Q R S:

QTc:

	V <sub>4R</sub>	V <sub>1</sub>	V <sub>2</sub>	V <sub>5</sub>	V <sub>6</sub>
R/S					



\*Caution: Please get the ECG photocopied for future reference.



Copy ID:

Name:

Birth date: /

Sex: cm kg

mmHg

years

1100 Sinus rhythm  
9110 xx normal ECG \*\*

AHCC.0000127424  
MRS. MITAL PATEL  
Age: 32 Year(s) Female  
9 Mar 2023 8:32:58 AM



Medication:

Symptoms:

History:

Vent. rate

PR int

QRS dur

QT/QTc(E) int

P/QRS/T axis

RV5/SV1 amp

RV5+SV1 amp

96 bpm

144 ms

80 ms

344/ 398 ms

61/ 41/ 32 °

1.62/ 1.10 mV

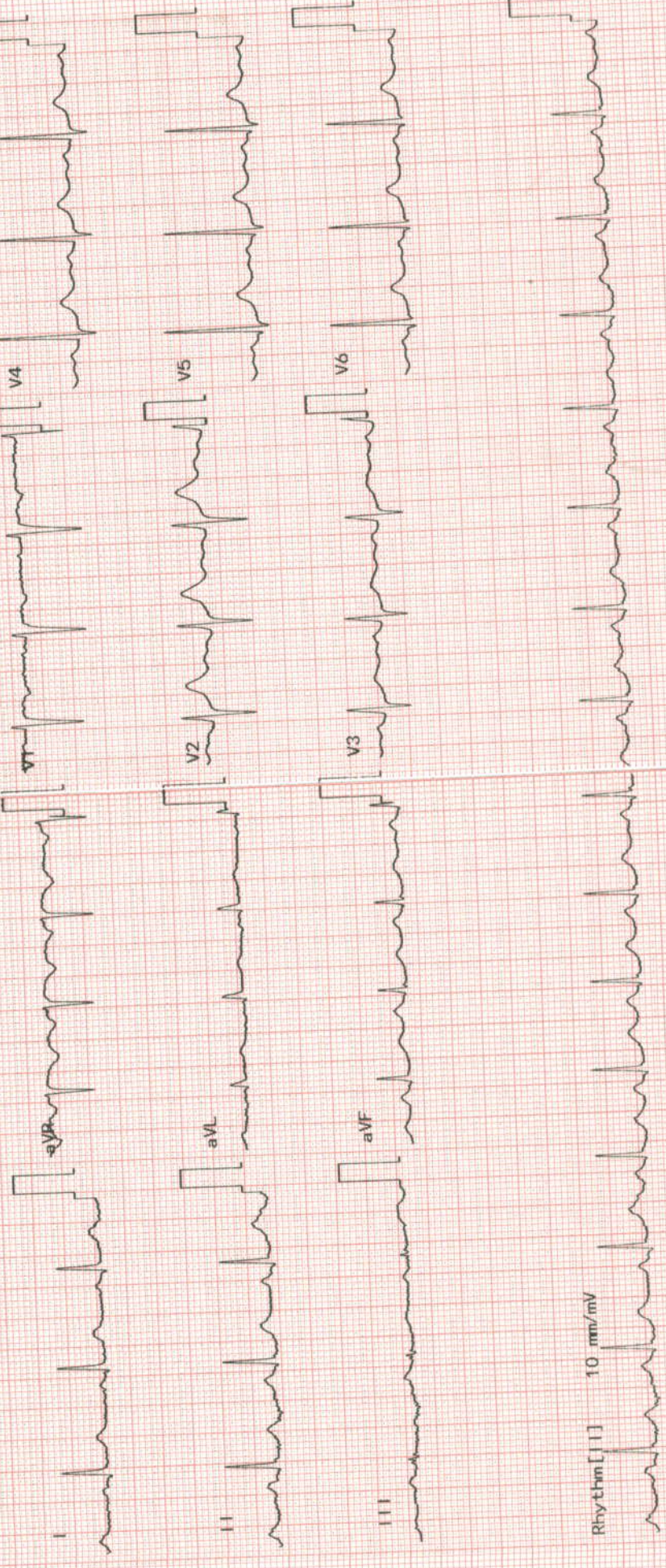
2.73 mV

Filter: H50 D 35 Hz 10 mm/mV

10 mm/mV 25 mm/s

10 mm/mV

10 mm/mV



Unconfirmed Report  
Reviewed by:

Exam:



EYE CHECK UP

NAME Mas Mital Patel

Date 09/03/23

VA 6/6

32/2

flor

BCVA(Distance & Near)

RE plus 6/6  
LE plus 6/6

Colour Vision Normal

Advice:

Anterior Segment

Fundus

Advice:



Diagnosis

Checked By





Organization is Accredited  
by Joint Commission International



### CARDIOLOGY

**Patient Details** : Mrs. MITAL PATEL | Female | 32Yr 6Mth 15Days  
**UHID** : AHCC.0000127424 **Patient Location:** AHC  
**Patient Identifier:** AHCCA4670   
**DRN** : 5623022749 **Completed on :** 09-MAR-2023 13:12  
**Ref Doctor** : DR. BHAWANA DAGA

### ECHO

Normal cardiac chamber dimensions.  
 Normal LV systolic function, LVEF: 60%. No RWMA at rest.  
 Normal LV compliance.  
 All cardiac valves are structurally normal.  
 IAS/ IVS intact.  
 Trivial MR, No AR, No PR, Trivial TR. No PAH, RVSP: 22 mm Hg.  
 No clots/ vegetation/ effusion.  
**Impression**  
 Normal LV systolic function, LVEF: 60%.  
 Normal LV compliance.  
 No PAH.

— END OF THE REPORT —



DR SAMEER DANI MD.DM  
 Interventional Cardiologist

Printed on : 09-Mar-2023 13:19

Printed By : 717723

Reported By : 1010793

Page 1 of 1

