



# METRO

## HOSPITAL & HEART INSTITUTE

(A unit of Sunhill Hospitals Private Limited)  
(NABH & ISO 5001: 2003 Certified)

WE BRING...HE CURES

### Health Check-up Certificate

Company Name:- Mediwheel HR Date:- 23/5/22

Name:- Mr Davendra Singh Rawat Age/Sex:- 49y M

Personal, Family & Occupational History	No	
General Appearance	Av	
Height in cm		
Weight in kg	N	
Pulse Rate/minute	84/1	
BP in mmhg	130/80	
Eye Examination	}	
ENT Examination or Audiometry		
Respiratory System		
Cardio Vascular System		
Gastro Intestinal System		
Genito Urinary System		
Central Nervous System		
Pathological Test		Hb 12.7, RBC 4.3 + 1% - NAD - - TG ↑, PLT - 0.90
Radiologic and other studies		-
CXR-PA View		Done NAD
ECG	Done NAD	
Spirometry	-	

Doctor's Remark:-  
fit

Doctor Signature & Stamp  
Dr. Krishna Kumar Caroli  
MBBS, PMHS (EX.)

NOT FOR MEDICOLEGAL PURPOSE  
Consultant Health Checkup & CMO I/C  
Reg.No. - UP/MCI-4570  
Metro Hospital & Heart Institute  
SIDCUL, Haridwar, U.K., Pin No. 249403

# METRO HOSPITAL & HEART INSTITUTE

(A unit of Sunhill Hospitals Private Ltd.), CIN No. U33201DL2006PTC156918

Reg. Off : 21, Community Centre, Preet Vihar, Delhi - 92

GST No.: 05AAKCS5409G1ZD

Plot No. F-1, Sector-6A, SIDCUL, Ranipur, Haridwar (UK) - 249403, www.metrohospitals.com

Phone No.: 01334-239040, 239042, 239053

## BILL OF SUPPLY (OUTPATIENT CREDIT BILL) (DUPLICATE)

Bill No	MHWOP/202204536	Date/Time	28/05/2022 09:02
Name	Mr. Devender Singh Rawat	UHID	MHWID/2022009666
Age/Sex	49 Y /Male	Category	CASH
Address	Mediwheel, Haridwar Uttarakhand India	Req. Dr.	Dr. Krishna Kumar Caroli
Tel	9690720942		
Comp Name	MEDIWHEEL#ARCOFEMI HEALTH LTD. (MEDIWHEEL_HARIDWAR)		

HEALTH CARE SERVICES	Req. No.	AMOUNT(Rs.)
<b>Package - MediWheel Full Body Health Checkup Male Above 40(Rs 2100)FEB 2022</b>		2100.00
✓ CBC (COMPLETE BLOOD COUNT/HAEMOGRAM)	10302372	
✓ ESR	10302372	
✓ URINE ROUTINE ANALYSIS	10302372	
✓ STOOL ROUTINE EXAMINATION	10302372	
✓ BLOOD GROUP	10302372	
✓ BLOOD SUGAR -FASTING	10302372	
✓ URINE SUGAR	10302372	
✓ BLOOD SUGAR -PP	10302372	
✓ HB1AC	10302372	
✓ THYROID PROFILE	10302372	
✓ LIPID PROFILE	10302372	
✓ KFT (KIDNEY FUNCTION TEST)	10302372	
✓ LFT (LIVER FUNCTION TEST)	10302372	
ECG	80088827	
TMT/ECHO	80088827	
✓ X-RAY CHEST PA View	70195830	
✓ USG WHOLE ABDOMEN	70195830	
✓ PSA TOTAL	10302372	
Dr. Physician Consultation {First Visit}	Patient No 1	
Dr. Eye Consultation {Second Visit}	Patient No 1	
Dr. Dental Consultation {First Visit}	Patient No 1	

Bill Amount:2100.00  
Net Bill Amt Credit:2100.00

Credit Bill Towards **MEDIWHEEL#ARCOFEMI HEALTH LTD.** an Amount of  
Rupees Two Thousand One Hundred Only

Signature of Patient/Attendant .....  
Relation with patient .....  
Contact No .....  
Run Date : 28/05/2022 09:13

CASHIER  
User : Vinod



Measurement Results:

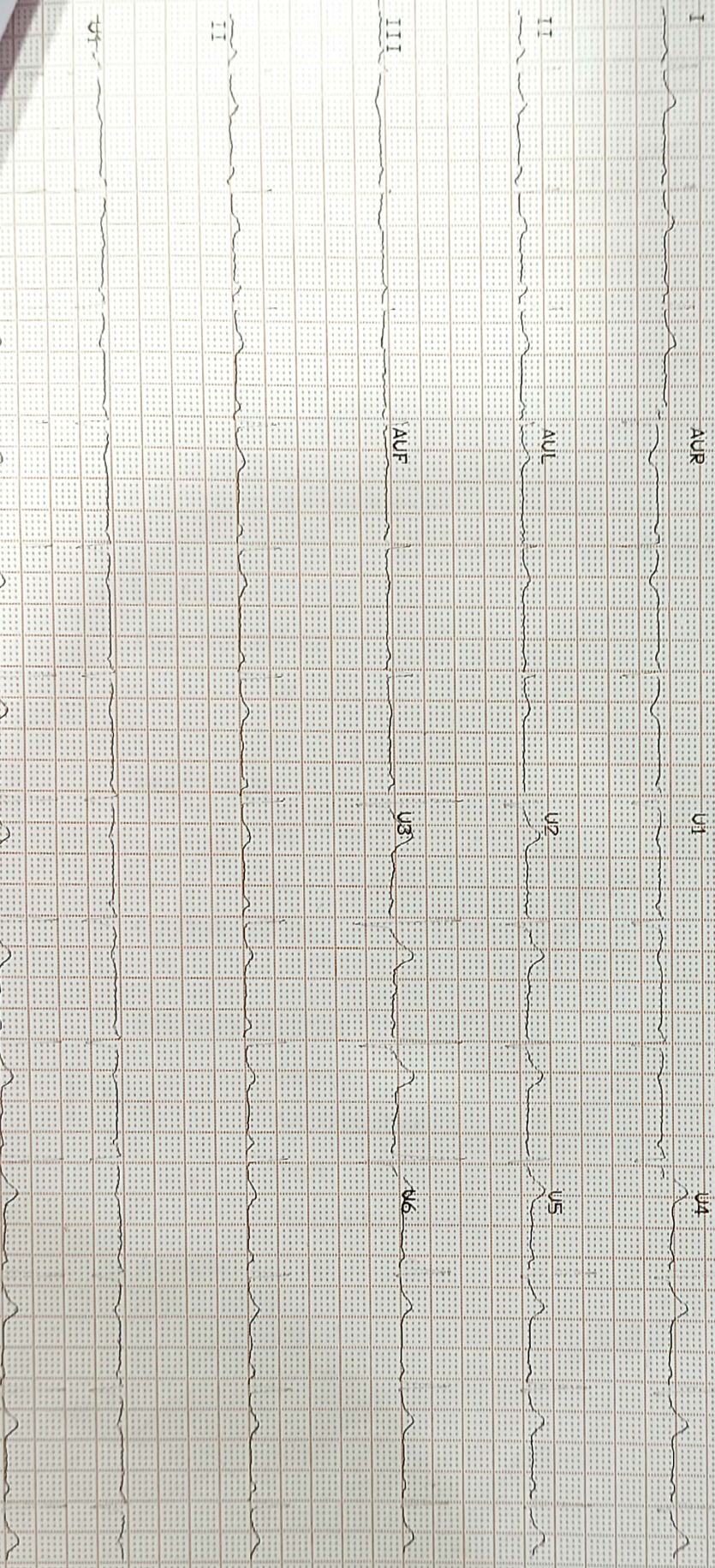
QRS	84 ms	< P	Interpretation:
QT/QTcB	407 ms	< T	normal ECG
PR	122 ms	< QRS	
P	100 ms	aVR	
RR/PP	772 / 780 ms	avL	0 I
P/QRS/T	40 / 40 / 20 degrees	III	+90
QTd/QTcBd	54 / 61 ms	II	
Sokolow	1.5 mV	aVF	
Rx	11		

Mr. Deveshwar Singh Rawat - 77  
 49 yrs | Mo

20/05/22  
 11:00 Am



Unlimited report



21mm/5 10mm/mV AVS 30Hz 0.08 - 20Hz 4x2 5PR Automatic V6 R 12L 11



**METRO**  
HOSPITAL & HEART INSTITUTE  
(A unit of Sunhill Hospitals Private Limited)  
(NABH & ISO 9001: 2008 Certified)



we treat...HE CURES

**Metro Hospital & Heart Institute**

(A unit of Sunhill Hospital Private Limited)

OPD CONSULTATION

Patient Name Mr. Devender Singh Rawal Age/Sex 49/M Reg. No. \_\_\_\_\_

Doctor's Name Dr. Sushil

Date 27/05/22 Time \_\_\_\_\_

OPHTHALMIC EXAMINATION

VISION

DISTANCE VISION-

Rt 6/6

Lt 6/6

NEAR VISION-

Rt N16

Lt N16

COLOUR VISION - Normal

EYE EXAMINATION

Cornea

Ant Chamber

Pupil

Fundus Examination

ADVICE-

Signature 

Plot No. F-1, Sector-6A, SIDCUL, Haridwar - 249 403

Emergency : +91 8191902600, Phone : 01334 - 239040 / 42 / 43, Fax : 01334 - 239043

E-mail : metroharidwar@metrohospitals.com, Website: www.metrohospitals.com





# METRO PATH LABS

(A unit of Sunhill Hospitals Private Limited)

(ISO & NABH Certified)

CIN No.: U33201DL2006PTC156918

## Pathology Report

Name : Mr. Devender Singh Rawat  
Ref. By : Dr. Krishna Kumar Caroli  
IP/OP : OP/202204536  
Sample Date : 28/05/2022  
Reporting Date: 28/05/2022

Age/Sex : 49 Y/M  
UHID : 2022009666  
Request No. : 10302372  
Sample Time : 10:44  
Reporting Time : 20:44

Test	Result	Unit	Bio. Ref. Inter. Test Method
<b>Biochemistry</b>			
LIPID PROFILE			
TOTAL CHOLESTEROL	185.0	mg/dl	00-250.0
HDL-CHOLESTEROL	37.0	mg/dl	00-50.0
LDL	98.0	mg/dl	00-150.0
TRIGLYCERIDES	252.0	md/dl	30-150
VLDL	50.0	mg/dl	0-50
CHOL/HDL Ratio	4.9		-<4.5
<b>Hematology</b>			
CBC (COMPLETE BLOOD COUNT/HAEMOGRAM)			
HB	12.7	gm/dl	M - 13-18
TLC	6000	/cumm	4000-11000
DLC (WBC DIFFERENTIAL)			
NEUTROPHILS	61	%	45-75
LYMPHOCYTES	31	%	25-45
EOSINOPHILS	04	%	1-6
MONOCYTES	04	%	2-8
BASOPHILS	00	%	--<2
RBC	4.76	million	3.5-5.5
PCV	42.6	%	36-52
MCV	89.5	fL	80-100
MCH	26.7	PG	27-32
MCHC	29.8	gm/dl	31-37
PLATELET COUNT	0.90	lakh/cumm	1.5-4.5
RDW	12.8	%	11.5-15
BLOOD GROUP			
ABO	AB		-
Rh	POSITIVE		-
ESR	17	mm/hr	20

\*\*\* End of Reports \*\*\*

Dr. Vishal Arora  
MBBS, DCP  
(Consultant Pathologist)

Checked By

**Note:**

1. These reports are mere estimation of values at that particular time and are liable to vary/change in different conditions in different laboratories.
2. The values are to be collaborated with clinical findings by qualified doctor and any alarming and unexpected results should be reported to Lab urgently for recheck and manual typing errors.
3. These reports are not valid for medicolegal purposes and all doctor unsigned reports should be considered provisional only.

Plot No. F-1, Sector-6A, SIDCUL, Haridwar - 249 403

Emergency : +91 8191902600, Phone : 01334 - 239040 / 42 / 43, Fax : 01334 - 239043

E-mail : metroharidwar@metrohospitals.com Website: www.metrohospitals.com

5/28/2022 11:03 PM





# METRO PATH LABS

(A unit of Sunhill Hospitals Private Limited)

(ISO & NABH Certified)

CIN No.: U33201DL2006PTC156918

## Pathology Report

Name : Mr. Devender Singh Rawat  
Ref. By : Dr. Krishna Kumar Caroli  
IP/OP : OP/202204536  
Sample Date : 28/05/2022  
Reporting Date: 28/05/2022


Age/Sex : 49 Y/M  
UHID : 2022009666  
Request No. : 10302372  
Sample Time : 10:44  
Reporting Time: 20:44


Test	Result	Unit	Bio. Ref.	Inter. Test Method
------	--------	------	-----------	--------------------

### Biochemistry

HBIAC	6.2	%	4.5-6.3	
BLOOD SUGAR -PP	<b>142.0</b>	mg/dl	70.0-140.0	
BLOOD SUGAR -FASTING	86.0	mg/dl	70.0-110.0	
LFT (LIVER FUNCTION TEST)				
BILIRUBIN INDIRECT	0.50	mg/dl	0.2-0.8	
SGOT	28.0	U/L	10-42	
SGPT	<b>46.0</b>	U/L	10-42	
BIILIRUBIN TOTAL	1.00	mg/dl	0.2-1.0	
ALKALINE PHOSPHATASE	73.0	IU/L	28-111	
BILIRUBIN DIRECT	<b>0.50</b>	mg/dl	0.1-0.4	
TOTAL PROTEIN	7.1	gm/dl	6.4-8.2	
ALBUMIN	4.0	g/dl	3.5-5.0	
GLOBULIN	3.1	gm/dl	2.0-4.0	
AG RATIO	1.3	-	-	
KFT (KIDNEY FUNCTION TEST)				
UREA	21.9	mg/dl	15-45	
SODIUM	135.0	mmol/L	135-155	
CREATININE	1.06	mg/dl	0.6-1.3	
URIC ACID	6.9	mg/dl	3.0-7.6	
BUN	10.1	mg/dl	05-20	
POTTASSIUM	4.4	mmol/L	3.5-5.5	
CALCIUM	9.8	mg/dl	8.5-10.5	

\*\*\* End of Reports \*\*\*

  
**Dr. Vishal Arora**  
 MBBS, DCP  
 (Consultant Pathologist)

Checked By 

#### Note:

1. These reports are mere estimation of values at that particular time and are liable to vary/change in different conditions in different laboratories.
2. The values are to be collaborated with clinical findings by qualified doctor and any alarming and unexpected results should be reported to Lab urgently for recheck and manual typing errors.
3. These reports are not valid for medicolegal purposes and all doctor unsigned reports should be considered provisional only.
4. All card based tests are screening test therefore need confirmation by other alternative test like (PCR, ELISA).

Plot No. F-1, Sector-6A, SIDCUL, Haridwar - 249 403

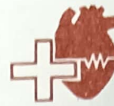Emergency : +91 8191902600, Phone : 01334 - 239040 / 42 / 43, Fax : 01334 - 239043

E-mail : metroharidwar@metrohospitals.com, Website: www.metrohospitals.com

5/28/2022 11:03 PM

Regd. Office : 21, Community Center, Preet Vihar, New Delhi-110092





## Radiology Investigation Report

Name : Mr. Devender Singh Rawat  
Ref. By : Dr. Krishna Kumar Caroli  
IP/OP : OP/202204536  
Date : 28/05/2022

Age/Sex : 49 Y/M  
UHID NO : 2022009666  
Request No : 70195830

### X-RAY CHEST PA View

Trachea is central.

Bilateral hila are normal in size & density.

Cardiac silhouette is normal.

Bilateral lung fields are clear.

Bilateral Costophrenic angles are normal.

Bilateral domes of diaphragm are normal in position & contour.

Bones and soft tissues are normal.

**IMPRESSION : Normal skiagram**



DR. PRAKASH CHANDRA PANDEY  
MBBS, DMRD  
CONSULTANT RADIOLOGIST

**Note:**

- (1) Not Valid for medical-legal purposes.
- (2) This is a professional opinion based on imaging finding and not the diagnosis.
- (3) In case of any discrepancy due to machine error or typing error, please get it rectified immediately.

Plot No. F-1, Sector-6A, SIDCUL, Haridwar - 249 403

Emergency : +91 8191902600, Phone : 01334 - 239040 / 42 / 43, Fax : 01334 - 239043

E-mail : metroharidwar@metrohospitals.com, Website: www.metrohospitals.com

Regd. Office : 21, Community Center, Preet Vihar, New Delhi-110092

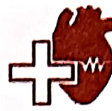CIN No.: U33201DL2006PTC156918

30-May-22 11:52 AM

MHHI/CL/0115/Rev. No. 01







**Radiology Investigation Report ( Provisional )**

<b>Name</b> : Mr. Devender Singh Rawat	<b>Age/Sex</b> : 49 Y/M
<b>Ref. By</b> : Dr. Krishna Kumar Caroli	<b>UHID NO</b> : 2022009666
<b>IP/OP</b> : OP/202204536	<b>Request No</b> : 70195830
<b>Date</b> : 28/05/2022	

**USG WHOLE ABDOMEN**

The diaphragm is normal in contour & respiratory excursion. There is no ascitis or lymph node mass.

Liver is normal in size, shape, outline & echotexture. No focal area of abnormal echogenicity is seen in liver. Intrahepatic biliary radicles are not dilated. Portal vein & portal venous radicles are normal.

**Gall bladder is not visualized H/O cholecystectomy.** Common bile duct is normal in course & caliber. No calculus is seen in its lumen.

Spleen & pancreas appears normal in shape, size, outline & echotexture.


Both the kidneys are normal in shape, size, outline & echotexture. Renal parenchymal thickness is normal. Corticomedullary junction is defined & is normal. There is no hydronephrosis. No echogenic renal calculus is seen.

Urinary bladder is normal in contour & capacity. Bladder wall is not thick. No pathological filling defect / vesical calculus is seen in bladder. Ureterovesical junctions appear normal.

Prostate is normal in shape, outline & echotexture. Prostatic capsule & periprostatic facial planes appear normal.

**IMPRESSION : NORMAL STUDY**

DR. PRAKASH CHANDRA PANDEY  
MBBS, DMRD  
CONSULTANT RADIOLOGIST



**Notes:**

- (1) Not Valid for medical-legal purposes.
- (2) This is a professional opinion based on imaging finding and not the diagnosis.
- (3) In case of any discrepancy due to machine error or typing error, please get it rectified immediately.

Plot No. F-1, Sector-6A, SIDCUL, Haridwar - 249 403  
Emergency : +91 8191902600, Phone : 01334 - 239040 / 42 / 43, Fax : 01334 - 239043  
E-mail : metroharidwar@metrohospitals.com, Website: www.metrohospitals.com

Regd. Office : 21, Community Center, Preet Vihar, New Delhi-110092  
CIN No. : U33201DL2006PTC156918

28-May-22 9:26 AM

MHHI/CL/0115/Rev. No. 01

