

## HEALTH CHECKUP REPORT

Patient Name: HRASHA AHIRRAO  
Age/Gender: 29/F  
Reg. No: 277068  
Package: MEDIWHEEL

DATE: 12/11/2022

### COMPLAINTS (IF ANY):

- headache after walking and forced activity

### HISTORY OF HEALTH STATUS:

- arthritis

PRESENT MEDICATIONS: No

HYPERSENSITIVITY TO ANY DRUG: No

### PERSONAL HISTORY:

- |               |   |              |                             |   |     |
|---------------|---|--------------|-----------------------------|---|-----|
| - Bowel       | : | constipation | Diet                        | : | Veg |
| - Micturition | : | Normal       | Habits                      | : | No  |
| - Sleep       | : | Adequate     | Physical Activity/Exercise: | : | no  |
| - Appetite    | : | Adequate     |                             |   |     |

### HISTORY OF ILLNESS (WITH PAST MEDICATIONS):

- Lmp :- 29/10/2022

### FAMILY HISTORY:

- Mother :- hypothyroidism

### VITAL SIGNS:

- |            |          |         |            |
|------------|----------|---------|------------|
| - Height : | 164 cms  | Pulse : | 76/min.    |
| - Weight : | 76.3 Kgs | B.P:    | 118/64mmHg |



**CIMS Hospital Private Limited**

Plot No 67/1, Opposite Panchmrut Bungalows Near Shakun Mall, Off Science City Road, Sola, Ahmedabad, Gujarat 380060

CIMS HOSP/2021/

1800 309 9999 CIN No. U85110GJ2001PTC039962

At CIMS...We Care

**PHYSICIAN CONSULTATION:**

- 1) **Clinical Impression**
- Mild Aenemia
- 2) **Recommendations**
- Healthy life style

(Dr. Rashmi chovatia)

**OPHTHALMO CONSULTATION:**

Best corrected visual acuity

RE

6/6

LE

6/6

(Dr. Jignesh Shah)

**DENTAL CONSULTATION:**

Adv:

- Cleaning, filing, cleaning

(Dr. Parvin Chandarana)

**GYNEC CONSULTATION:**

M/H: PMP- regular

LMP: 15<sup>th</sup> days

O/H: - AML -

1 FTLSCS

H/O: TL

P/H : Any other surgeries - nill

O/E: P/A - Soft

P/S - Cx. NAD

P/V - UT, RV, NS, FMR, Fx. Clear

Adv: USG Pelvis/TVS

Mammography

Pap Smear

} Follow up with reports

(Dr. Deavng patel )

**Please take regular medicine as prescribed by the Doctor. (If given)**



Patient ID 259083  
Patient Name Mrs. HARSHA RAHUL AHIRRAO  
Gender/Age Female/29  
Ref Doctor

Dt: 12/11/2022

Rx	Drug Name	Generic Name	Morning	Afternoon	Evening	Night	Duration
Tab.	LIVOGEN-Z oral	FERROUSFUMARATE+F OLICACID+ZINC	0	1	0	0	2 Month(s)

Dr. Rashmi Chovatia



**CIMS Hospital Private Limited**

Plot No 67/1, Opposite Panchmrut Bungalows Near Shakun Mall, Off Science City Road, Sola, Ahmedabad, Gujarat 380060

© 1800 309 9999 CIN No. U85110GJ2001PTC039962

**DR. JIGNESH SHAH**

MS (Ophthalmology), D.O.

**Phacosurgeon & LASIK**

Reg. No. : G-9414

Mobile: +91-98252 98258

Email : jignesh.shah@cimshospital.org

12/11/22.

Harshan

R

• Teardrop exchm

①





FOR OPD CONSULTATION ONLY



OUR ACCREDITATIONS

**CIMS Hospital Private Limited**

Plot No 67/1, Opp. Panchamrut Bungalows, Near Shukan Mall, Off Science City Road, Sola, Ahmedabad - 380060, Gujarat

© 1800 309 9999 CIN No. U85110GJ2001PTC039962

Reg. No : CIMS/A/2019/277068	VisitNo : HC/121122/13 [HCV]
Patient Name : Mrs. HARSHA RAHUL AHIRRAO	Age(Y-M-D)/Sex : 29 Y 10 M 3 D. / Female
Referring Doctor : Dr. CIMS DOCTOR	Doctor :
Ward/Room :	Bed :
ORD/121122/350 Lab No : 2022167537 LSN : 933339 ( Whole Blood )	Sample Quality : Normal
Collection Time : 12/11/2022 9:12:28	Arrival : 12/11/2022 9:52:28 Validation Time: 12/11/2022 12:43:00PM

	<u>Result</u>	<u>Unit</u>	<u>Reference Range</u>
<b>CBC With ESR</b>			
<b>TOTAL COUNT</b>			
Hemoglobin <i>(SLS Hemoglobin Detection method)</i>	11.7	g/dl	12.5 - 16.0 g/dl
Total RBC Count <i>(Hydro Dynamic Focusing Method)</i>	4.8	mill/Cmm	4.2 - 5.4 mill/Cmm
HCT <i>(Hydro Dynamic Focusing Method)</i>	37.2	%	37 - 47 %
Total WBC Count <i>(Flow Cytometry)</i>	8690	/Cmm	4000 - 10500 /Cmm
Platelet Count <i>(Hydro Dynamic Focusing Method)</i>	214000	/Cmm	150000 - 450000 /Cmm
<b>DIFFERENTIAL COUNT (by Flow Cytometry)</b>			
Polymorphs	60	%	40 - 70 %
Lymphocytes	32	%	22 - 45 %
Eosinophils	03	%	01 - 04 %
Monocytes	05	%	01 - 06 %
Basophils	00	%	00 - 01 %
Immature Granulocytes	00	%	0 - 2 %
Smear Study	RBCs shows Anisocytosis(+), Microcytosis(+), Hypochromia(+). Platelets are adequate in number. Malarial Parasites are not seen. No Premature cells are seen.		
<b>BLOOD INDICES (by Calculated Method)</b>			
M.C.V	77.5	fl	78 - 100 fl
M.C.H	24.4	pg	27 - 31 pg
M.C.H.C.	31.5	gm/dl	32 - 36 gm/dl
RDW-CV	13.7	%	11.5 - 14.0 %
<b>ESR (Red Cell Aggregation)</b>			
After One Hour	35	mm	0 - 12 mm
<b>Blood Group Rh</b>			
ABO	"B"		



**Dr. Kazumi Gondalia  
M.D. (Path)  
Consultant Pathologist  
Reg. No. : G-21729**

Dr. Manisha Shah  
MD (Path & Bact)  
Consultant Pathologist  
Reg. No. : G-15496

Dr. Jitendra Nayak  
MD (Path)  
Consultant Pathologist  
Reg. No. : G-14786



**CIMS Hospital Private Limited**

Plot No 67/1, Opp. Panchamrut Bungalows, Near Shukan Mall, Off Science City Road, Sola, Ahmedabad - 380060, Gujarat

© 1800 309 9999 CIN No. U85110GJ2001PTC039962

Print By : ankita.rajput

Print Date/Time : 12/11/2022 13:57:56

Page 1 of 4



Reg. No : CIMS/A/2019/277068	VisitNo : HC/121122/13 [HCV]
Patient Name : Mrs. HARSHA RAHUL AHIRRAO	Age(Y-M-D)/Sex : 29 Y 10 M 3 D. / Female
Referring Doctor : Dr. CIMS DOCTOR	Doctor :
Ward/Room :	Bed :

ORD/121122/350 Lab No : 2022167537 LSN : 933339 ( Whole Blood ) Sample Quality : Normal  
Collection Time : 12/11/2022 9:12:28 Arrival : 12/11/2022 9:52:28 Validation Time: 12/11/2022 12:43:00PM


Rh

POSITIVE

\*\*\* END OF REPORT \*\*\*

Dr. Manisha Shah  
MD (Path & Bact)  
Consultant Pathologist  
Reg. No. : G-15496

Dr. Jitendra Nayak  
MD (Path)  
Consultant Pathologist  
Reg. No. : G-14786

  
**Dr. Kazumi Gondalia**  
M.D. (Path)  
Consultant Pathologist  
Reg. No. : G-21729



OUR ACCREDITATIONS

**CIMS Hospital Private Limited**

Plot No 67/1, Opp. Panchamrut Bungalows, Near Shukan Mall, Off Science City Road, Sola, Ahmedabad - 380060, Gujarat

© 1800 309 9999 CIN No. U85110GJ2001PTC039962

Print By : ankita.rajput

Print Date/Time : 12/11/2022 13:57:56

Page 2 of 4

Reg. No : CIMS/A/2019/277068	VisitNo : HC/121122/13 [HCV]
Patient Name : Mrs. HARSHA RAHUL AHIRRAO	Age(Y-M-D)/Sex : 29 Y 10 M 3 D. / Female
Referring Doctor : Dr. CIMS DOCTOR	Doctor :
Ward/Room :	Bed :

ORD/121122/350 Lab No : 2022167537 LSN : 933339 ( Whole Blood ) Sample Quality : Normal  
 Collection Time : 12/11/2022 9:12:28 Arrival : 12/11/2022 9:52:28 Validation Time : 12/11/2022 12:59:36PM

	<u>Result</u>	<u>Unit</u>	<u>Reference Range</u>
HbA1c (Glycosylated Haemoglobin )			
TEST			
HbA1c (Glyoco Hb) (Immuno Turbidimetric)	<u>6.05</u>	%	4.8-5.9% Normal 5.9-7.0% Good diabetic control 7.0-10.0% Fair diabetic control >10.0% Poor diabetic control
Mean Plasma Glucose	137.9	mg/dL	80 - 140 mg/dL

*Jan*

Dr. Manisha Shah  
MD (Path & Bact)  
Consultant Pathologist  
Reg. No. : G-15496

Dr. Jitendra Nayak  
MD (Path)  
Consultant Pathologist  
Reg. No. : G-14786



Reg. No : CIMS/A/2019/277068	VisitNo : HC/121122/13 [HCV]
Patient Name : Mrs. HARSHA RAHUL AHIRRAO	Age(Y-M-D)/Sex : 29 Y 10 M 3 D. / Female
Referring Doctor : Dr. CIMS DOCTOR	Doctor :
Ward/Room :	Bed :
ORD/121122/350 Lab No : 2022167538 LSN :933339 ( SERUM )	Sample Quality : Normal
Collection Time :12/11/2022 9:12:28 Arrival : 12/11/2022 9:52:28	Validation Time: 12/11/2022 12:59:58PM

**Liver Function Test**

	<u>Result</u>	<u>Unit</u>	<u>Reference Range</u>
Alkaline Phosphatase <i>(PNPP,AMP Buffer Method,Colorimetric)</i>	73.5	U/L	35 - 104 U/L
<b>Billirubin</b>			
Total Billirubin <i>(Diazospecial Iazonium Iron with Blank)</i>	0.24	mg/dL	0.0 - 1.0 mg/dL
Direct Billirubin <i>(Dialzo,(Evelyn Malloy) with Blank )</i>	0.12	mg/dL	0.0 - 0.2 mg/dL
Indirect Billirubin <i>(Calculated from Total and Direct Billirubin)</i>	0.12	mg/dL	0.0 - 0.8 mg/dL
SGPT (ALT) <i>(IFCC without pyridoxal phosphate)</i>	10.4	U/L	0 - 33 U/L
SGOT (AST) <i>(IFCC without pyridoxal 5 phosphate)</i>	21.1	U/L	0 - 32 U/L
<b>Total Protein</b>			
Total Proteins <i>(Biuret Method)</i>	7.58	gm/dl	6.4 - 8.3 gm/dl
Albumin <i>(Bromocresol Green Colorimetric)</i>	4.33	gm/dl	3.97 - 4.95 gm/dl
Globulin	3.25	gm/dl	2.2 - 3.5 gm/dl
A/G Ratio	1.33		0.9 - 2.1

*Jan*

Dr. Manisha Shah  
MD (Path & Bact)  
Consultant Pathologist  
Reg. No. : G-15496

Dr. Jitendra Nayak  
MD (Path)  
Consultant Pathologist  
Reg. No. : G-14786



**CIMS Hospital Private Limited**

Plot No 67/1, Opp. Panchamrut Bungalows, Near Shukan Mall, Off Science City Road, Sola, Ahmedabad - 380060, Gujarat

© 1800 309 9999 CIN No. U85110GJ2001PTC039962

Print By : ankita.rajput

Print Date/Time : 12/11/2022 13:58:17

Page 1 of 2



Reg. No : CIMS/A/2019/277068	VisitNo : HC/121122/13 [HCV]
Patient Name : Mrs. HARSHA RAHUL AHIRRAO	Age(Y-M-D)/Sex : 29 Y 10 M 3 D. / Female
Referring Doctor : Dr. CIMS DOCTOR	Doctor :
Ward/Room :	Bed :

ORD/121122/350 Lab No : 2022167538 LSN :933339 ( SERUM ) Sample Quality : Normal  
 Collection Time :12/11/2022 9:12:28 Arrival : 12/11/2022 9:52:28 Validation Time: 12/11/2022 12:59:57PM

	<u>Result</u>	<u>Unit</u>	<u>Reference Range</u>
Creatinine <i>(Buffered Jaffe Reaction Kinetic Compensated)</i>	0.53	mg/dL	0.5 - 0.9 mg/dL
Estimated GFR	187.91	mL/min/1.73m2	72 - 110 mL/min/1.73m2
Fasting Glucose <i>(Hexokinase)</i>	90.5	mg/dL	70 - 100 mg/dL
<b>Thyroid Function Test</b>			
TOTAL T3 (T3) * <i>(Electrochemiluminescence Assay)</i>	1.23	ng/ml	0.846 - 2.02 ng/ml
TOTAL T4 (T4) * <i>(Electrochemiluminescence Assay)</i>	9.67	µgm/dl	5.13 - 14.06 µgm/dl
TSH <i>(Electrochemiluminescence Assay)</i>	3.69	µIU/ml	0.27- 4.20 µIU/ml
Uric Acid <i>(Uricase Colorimetric Enzymatic)</i>	4.3	mg/dL	2.4 - 5.7 mg/dL

\*\*\* END OF REPORT \*\*\*



Dr. Manisha Shah  
MD (Path & Bact)  
Consultant Pathologist  
Reg. No. : G-15496

Dr. Jitendra Nayak  
MD (Path)  
Consultant Pathologist  
Reg. No. : G-14786



**CIMS Hospital Private Limited**

Plot No 67/1, Opp. Panchamrut Bunglows, Near Shukan Mall, Off Science City Road, Sola, Ahmedabad - 380060, Gujarat

© 1800 309 9999 CIN No. U85110GJ2001PTC039962

Print By : ankita.rajput

Reg. No : CIMS/A/2019/277068	VisitNo : HC/121122/13 [HCV]
Patient Name : Mrs. HARSHA RAHUL AHIRRAO	Age(Y-M-D)/Sex : 29 Y 10 M 3 D. / Female
Referring Doctor : Dr. CIMS DOCTOR	Doctor :
Ward/Room :	Bed :

ORD/121122/350 Lab No : 2022167540 LSN : 933339 ( SERUM ) Sample Quality : Normal  
Collection Time : 12/11/2022 9:12:28 Arrival : 12/11/2022 9:52:28 Validation Time : 12/11/2022 12:59:45PM

	<u>Result</u>	<u>Unit</u>	<u>Reference Range</u>
BUN * (Ureas with UV)	8.0	mg/dL	6 - 20 mg/dL

\*\*\* END OF REPORT \*\*\*



Dr. Manisha Shah  
MD (Path & Bact)  
Consultant Pathologist  
Reg. No. : G-15496

Dr. Jitendra Nayak  
MD (Path)  
Consultant Pathologist  
Reg. No. : G-14786



**CIMS Hospital Private Limited**

Plot No 67/1, Opp. Panchamrut Bunglows, Near Shukan Mall, Off Science City Road, Sola, Ahmedabad - 380060, Gujarat  
1800 309 9999 CIN No. U85110GJ2001PTC039962

Reg. No : CIMS/A/2019/277068	VisitNo : HC/121122/13 [HCV]
Patient Name : Mrs. HARSHA RAHUL AHIRRAO	Age(Y-M-D)/Sex : 29 Y 10 M 3 D. / Female
Referring Doctor : Dr. CIMS DOCTOR	Doctor :
Ward/Room :	Bed :

ORD/121122/350 Lab No : 2022167538 LSN : 933339 ( SERUM ) Sample Quality : Normal  
 Collection : 12/11/2022 9:12:28AM Arrival: 12/11/2022 9:53:48 Validation Time 12/11/2022 11:58:40

<u>Lipid Profile (With Direct LDL)</u>	<u>Result</u>	<u>Unit</u>	<u>Reference Range</u>
Type of Sample	: Fasting	.	
Cholesterol <i>(Enzymatic/Colorimetric, Cholesterol Oxidase, Esterase, Peroxidase Gen.2)</i>	: 129.3	mg/dL	Less than 160 mg/dl Excellent Less than 200 mg/dl Desirable 200-239 mg/dl Borderline High 240 mg/dl & over High
Triglyceride <i>(Enzymatic Colorimetric without Glycerol Blank without Serum Blank)</i>	: 61.5	mg/dL	Less than 150 mg/dl Normal 150 - 199 mg/dl Borderline High 200-499 mg/dl High 500 mg/dl or greater Very High
HDL Cholesterol <i>(Direct Measured Homogenous Technique Modified Enzymatic Colorimetric Gen. 3)</i>	: 45.2	mg/dL	Less than 40 mg/dl Low 60 mg/dl or above Excellent
L D L Cholesterol (DIRECT) <i>(Homogenous Enzymatic colorimetric Assay)</i>	: 75.5	mg/dL	Less than 80 mg/dl Excellent Less than 100 mg/dl Optimal 100 - 129 mg/dl Near or above optimal 130 - 159 mg/dl Borderline High 160 - 189 mg/dl High 190 mg/dl & above Very High
VLDL Cholesterol <i>(Calculated)</i>	: 12.3	mg/dL	15 - 30 mg%
Cholesterol/HDL Ratio <i>(Calculated)</i>	: 2.86		Normal upto 4.5
LDL/HDL Ratio <i>(Calculated)</i>	: 1.67		Less than 3.5

Remarks :



Dr. Manisha Shah  
MD (Path & Bact)  
Consultant Pathologist  
Reg. No. : G-15496

Dr. Jitendra Nayak  
MD (Path)  
Consultant Pathologist  
Reg. No. : G-14786



**CIMS Hospital Private Limited**

Reg. No : CIMS/A/2019/277068	VisitNo : HC/121122/13 [HCV]
Patient Name : Mrs. HARSHA RAHUL AHIRRAO	Age(Y-M-D)/Sex : 29 Y 10 M 3 D. / Female
Referring Doctor : Dr. CIMS DOCTOR	Doctor :
Ward/Room :	Bed :

ORD/121122/350 Lab No : 2022167539 LSN :933339 ( Urine ) Sample Quality : Normal  
 Collection Time :12/11/2022 9:12:28 Arrival : 12/11/2022 9:52:28 Validation Time: 12/11/2022 12:43:12PM

	<u>Result</u>	<u>Unit</u>	<u>Reference Range</u>
<b>Urine R &amp; M</b>			
<b>PHYSICAL EXAMINATION</b>			
Quantity	20 cc		
Colour	Pale Yellow		
Transperancy	Clear		
Reaction (QDS-10 Strip)	6.0		
Sp. Gravity (QDS-10 Strip)	1.010		1.005 - 1.035 .
<b>CHEMICAL EXAMINATION</b>			
U. Albumin (QDS-10 Strip/Manual)	Nil		
U. Glucose (QDS-10 Strip/Manual)	Nil		
U. Acetone (QDS-10 Strip/Manual)	Absent		
BS/BP (QDS-10 Strip/Manual)	Absent		
<b>MICROSCOPIC EXAMINATION</b>			
Pus Cell	Occasional	/H.P.F.	/H.P.F.
Red Blood Cell	Nil	/H.P.F.	/H.P.F.
Epithelial Cell	1-2	/H.P.F.	/H.P.F.
Cast	Not Seen		
Crystals	Not Seen		
Amorphous	Absent		
Monilia	Absent		

\*\*\* END OF REPORT \*\*\*

Dr. Manisha Shah  
MD (Path & Bact)  
Consultant Pathologist  
Reg. No. : G-15496

Dr. Jitendra Nayak  
MD (Path)  
Consultant Pathologist  
Reg. No. : G-14786

  
**Dr. Kazumi Gondalia**  
**M.D. (Path)**  
**Consultant Pathologist**  
**Reg. No. : G-21729**

JCI (USA) NABH MC-3049  
OUR ACCREDITATIONS

**CIMS Hospital Private Limited**

Plot No 67/1, Opp. Panchamrut Bungalows, Near Shukan Mall, Off Science City Road, Sola, Ahmedabad - 380060, Gujarat  
 @ 1800 309 9999 CIN No. U85110GJ2001PTC039962



Name : Mrs. HARSHA RAHUL AHIRRAO  
Reg No : CIMS/A/2019/277068  
DoB/Sex: 09/01/1993 / Female

Dt : 12/11/2022

### ECHO Report

#### Patient Details

Patient ID 259083  
Name Mrs. HARSHA RAHUL AHIRRAO  
Age 29 Years  
Gender Female  
Blood Group  
Referral Doctor

#### ECHO Identification Detail

Doctor Incharge Dr. VIPUL KAPOOR  
Clinical Status Of Patient RP  
ECHO Code  
Finding Description  
1. Normal cardiac chambers dimensions.  
2. Normal LV systolic function, LVEF: 60%.  
3. No RWMA.  
4. Normal LV diastolic function.  
5. All cardiac valves are structurally normal.  
6. Trivial MR, Trivial TR, Trivial PR, No AR.  
7. No PAH.  
8. IAS/IVS: Intact.  
9. No clot/vegetation/pericardial effusion.  
10. No coarctation of aorta.

Dr. VIPUL KAPOOR



**CIMS Hospital Private Limited**

Plot No 67/1, Opposite Panchmrut Bungalows Near Shakun Mall, Off Science City Road, Sola, Ahmedabad, Gujarat 380060  
© 1800 309 9999 CIN No. U85110GJ2001PTC039962

12/11/2022



12-11-2022 10:13:15

ID: 891

Years

HR

64 bpm

P

98 ms

PR

153 ms

QRS

73 ms

QT/QTc

397/412 ms

P/QRS/T

45/62/38 °

RV5/SV1

1.362/0.476 mV

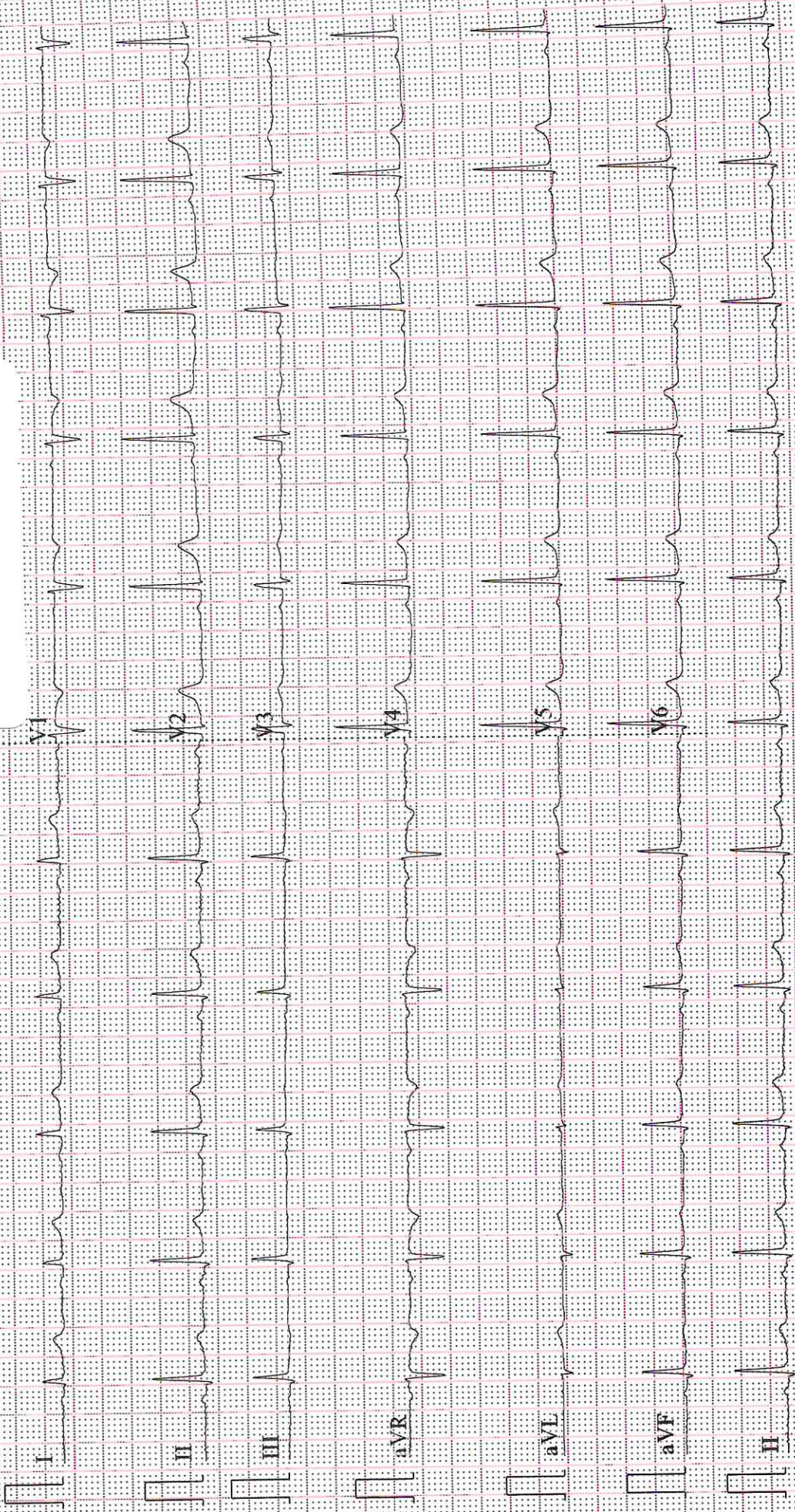
Diagnosis Information

Name : Mrs. HARSHA RAHUL AHIRRAO

Reg No : CIMS/A/2019/277068

DoB / Sex : 09/01/1993 / Female

NSR WOMAN





Patient's Name :HARSHA RAHUL AHIRRAO  
Reg. No. (IP/OP):HC-277068  
Referred By Dr. :CIMS

Age, Sex :26Y/M  
Date :12/11/2022

**Plain Skiagram of Chest PA standing view:**  
(Serial No-6838)

Both lung fields appear normal.

No evidence of collapse or consolidation in either lung field.  
No evidence of pleural effusion or pneumothorax is seen on either side.

Mediastinal shadow appears normal.

Heart and aorta appear normal.

Domes of diaphragm appear normal.

Bones under view appears normal.

Kindly correlate clinically



DR KIRTAN SHAH M.D. RADIOLOG. CONS. RADIOLOGIST  
DR DEEPA SHAH M.D., D.M.R.E CONS. RADIOLOGIST  
DR UMA MEHTA D.M.R.D. F.R.C.R CONS. RADIOLOGIST  
DR NIMISH SHARMA D.M.R.D. (D.N.B.) CONS. RADIOLOGIST  
DR RAVINA CHAUHAN M.D. RADIOLOG. CONS. RADIOLOGIST  
DR YASH PATEL M.D., D.N.B. CONS. RADIOLOGIST  
DR SUNALI DESAI MD, DNB, DM, FRCC CONS. RADIOLOGIST NEURORADIOLOGIST

Note: This is only a radiological impression and not the final diagnosis. All diagnostic modalities have their own limitations.  
Therefore radiological modality report should be interpreted in correlation with clinical and pathological findings.

FOR RADIOLOGY REPORTS ONLY

Patient's Name : HARSHA RAHUL AHIRRAO	Age, Sex : 26Y/F
Reg. No. (IP/OP): HC-277068	Date : 12/11/2022
Referred By Dr. : CIMS	

**USG OF ABDOMEN & PELVIS**

**LIVER:** Liver shows bright echotexture and is normal in size. S/O Fatty liver (Grade-I). No evidence of focal SOL or dilatation of IHBR seen. Porta hepatis appear normal.

**GALLBLADDER:** Gallbladder appeared normal. No calculus or mass lesion seen.

**PANCREAS:** Visualised Pancreas appeared normal in size and echotexture. No focal lesion, mass or pancreatitis.

**SPLEEN:** Spleen appears normal in size and echotexture.

**PARAAORTIC REGION:** Aorta grossly appeared normal. No paraaortic lymphnodes seen.

**KIDNEYS:** Both kidneys appear normal in size, shape and in position. Cortex and collecting system of both kidneys appeared normal. No evidence of calculus or obstructive uropathy on either side. Right kidney: 113x37mm. Left kidney: 111x43mm.

**URINARY BLADDER:** Bladder appeared normal. No calculus or mass lesion is seen.

**UTERUS:** Uterus appears normal in size and measures 81x49x29mm. Uterus shows homogenous endometrial and myometrial echotexture. Endometrial thickness appears normal and measures 8mm. No fibroid or GS seen.

**OVARIES:** Both ovaries appear normal. No adnexal mass lesion seen on either side.

No evidence of free fluid or collection is seen in peritoneal spaces. Normal small bowel peristalsis noted.

**COMMENTS:** Appearance suggests,

- Fatty liver (Grade-I).

Kindly correlate clinically.



DR KIRTAN SHAH M.D. RADIOLOGIST  
DR DEEPA SHAH M.D., D.M.R.E CONS. RADIOLOGIST  
DR UMA MEHTA D.M.R.D. F.R.C.R CONS. RADIOLOGIST  
DR NIMISH SHARMA D.M.R.D. (D.N.B.) CONS. RADIOLOGIST  
DR RAVINA CHAUHAN M.D. RADIOLOGIST CONS. RADIOLOGIST  
DR YASH PATEL M.D., D.N.B. CONS. RADIOLOGIST  
DR SUNALI DESAI MD, DNB, DM, FRCR CONS. RADIOLOGIST NEURORADIOLOGIST

Note: This is only a radiological impression and not the final diagnosis. All diagnostic modalities have their own limitations. Therefore radiological modality report should be interpreted in correlation with clinical and pathological findings.

