

Facilities:
 All clinical Biomedical & Hematology Investigations
 including Bone Marrow Examination
 VPT, Podiascan & Complete Foot Care (First Time in Purvanchal)
 All Hormonal Investigation by Chemiluminescent Method
 Visceral Fat by (AB-140) Ambulatory BP Monitoring
 CGMS & Insulin Pump Available
 PFT, 2D-ECHO (Color Doppler), Holter, TMT, Cardiac-3 available
 VIA, VILI, Colposcopy available
 Special Endocrinological Investigation Protocols.

ISO 9001:2008 Certified
 Mobile: 9389994334, 9554572190, 9453837595



Panacea Pathology Clinical Reference Lab

Persistence, Preparedness and Precision
 EQAS (CMC Vellore Attached) & IQAS System
 पूर्वांचल की सर्वोत्तम गुणवत्ता वाली पैथोलॉजी

PATIENT NAME : ASHA LATA TRIPATHI	AGE/GENDER : 41 YRS/FEMALE
REFD BY DR. : ARCO FEMI HEALTHCARE LTD.	RECEIVED DATE : 10-12-2022 (09:45 AM)
SAMPLE : BLOOD & URINE	REPORT DATE : 10-12-2022 (18:15 PM)

PATHOLOGY REPORT

COMPLETE BLOOD COUNT (CBC)

TEST	LAB TEST VALUES	NORMAL RANGE
HEMOGRAM		
HEMOGLOBIN (FLOW CYTOMETRY)	13.6	13 – 16 gm/dl
TOTAL LEUCOCYTE COUNT (TLC)	11,700	4000 – 11000
RBC COUNT	4.87	3.5 – 5.5
PCV (HCT)	41.9	37 – 47
MCV	86.1	80 – 95
MCH	28.5	28 – 34
MCHC	32.5	30 – 36
PLATELET COUNT	1,70,000	1,50,000 – 4,00,000
E.S.R. (WINTROBE FIRST HOURS)	18.0	20 mm/1 st hr
DIFFERENTIAL LEUCOCYTE		
NEUTROPHILS	76	40 – 75%
LYMPHOCYTES	16	20 – 45%
EOSINOPHILS	05	1 – 6%
MONOCYTES	03	2 – 8%
BASOPHILS	00	< 2 %

RENAL & KIDNEY PROFILE, SERUM

TEST	LAB TEST VALUES	NORMAL RANGE
RENAL FUNCTION TESTS		
BLOOD UREA NITROGEN (BUN)	12.0	10 – 50 mg/dl
SERUM CREATININE	0.80	0.60 – 1.60 mg/dl
URIC ACID	3.96	3.60 – 7.70 mg/dl
ALKALINE PHOSPHATASE (ALP)	76.0	142 – 353 mg/dl
TOTAL PROTIENS	7.06	0 – 39 mg/dl
ALBUMIN	4.00	3.8 – 5.4 mg/dl
SERUM GLOBULIN	3.12	2.1 – 3.5 mg/dl
CALCIUM	9.6	8.80 – 10.20
PHOSPHORUS	3.94	2.50 – 5.00
SERUM SODIUM NA+	145.0	135.00 – 155.00 mEq/Ltr
SERUM POTASIUM K+	4.18	3.60 – 5.50 mEq/Ltr
ICALCIUM	1.25	1.10 – 1.35 mmol/L
SERUM CHLORIDE CL+	103.3	98.00 – 110.00 mEq/Ltr

PAGE 1

Lab Technician

M.D., Pathology

Timing : 8.00 a.m. to 9.00 p.m. (Sunday 8.00 a.m. to 3.00 p.m.)

This Report is not valid for medico legal purpose

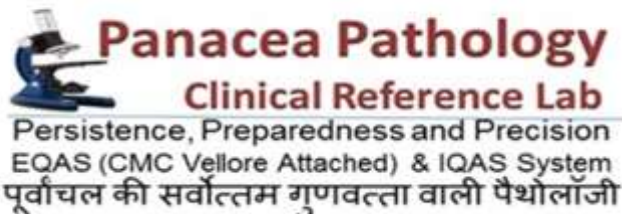
Note: These tests have technical limitations. Clinico-pathological interpretation is necessary. In case of any disparity test may be repeated immediately.

Address : 36/44 FK Kabir Nagar, Durgakund, Varanasi – 221005

Email: dramishra@gmail.com, drpallaviojha@gmail.com Website: panaceahospital.org

Facilities:
 All clinical Biomedical & Hematology Investigations
 including Bone Marrow Examination
 VPT, Podiascan & Complete Foot Care (First Time in Purvanchal)
 All Hormonal Investigation by Chemiluminescent Method
 Visceral Fat by (AB-140) Ambulatory BP Monitoring
 CGMS & Insulin Pump Available
 PFT, 2D-ECHO (Color Doppler), Holter, TMT, Cardiac-3 available
 VIA, VILI, Colposcopy available
 Special Endocrinological Investigation Protocols.

ISO 9001:2008 Certified
 Mobile: 9389994334, 9554572190, 9453837595



PATIENT NAME : ASHA LATA TRIPATHI	AGE/GENDER : 41 YRS/FEMALE
REFD BY DR. : ARCO FEMI HEALTHCARE LTD.	RECEIVED DATE : 10-12-2022 (09:45 AM)
SAMPLE : BLOOD & URINE	REPORT DATE : 10-12-2022 (18:15 PM)

PATHOLOGY REPORT

LIPID PROFILE, SERUM

TEST	LAB TEST VALUES	NORMAL RANGE
BLOOD CHEMISTRY		
TOTAL CHOLESTEROL (SERUM)	172.0	Desirable:- < 200 mg/dl Borderline:- 200 – 239 mg/dl High:- > 240 mg/dl
TRIGLYCERIDES (SERUM)	152.0	35 – 170 mg/dl
HDL CHOLESTEROL (SERUM)	42.0	35.30 – 79.50 mg/dl
LDL CHOLESTEROL (SERUM)	99.6	< 130 mg/dl
VLDL	30.4	< 40 mg/dl
NON HDL	72.0	0.00 – 100.00 mg/dl
CHOLESTROL/HDL RATIO	3.81	< 3.0 Low Risk Ratio 3.0 – 5.0 Avg Risk < 5.0 High Risk
LDL/HDL RATIO	2.11	< 3 Ratio

BLOOD GROUP

TEST	LAB TEST VALUES
BLOOD GROUP ABO & RH FACTOR	
BLOOD GROUP	“B”
RH FACTOR	POSITIVE

GLYCOSYLATED HEMOGLOBIN (HBA1C)

TEST	LAB TEST VALUES	NORMAL RANGE
HBA1C	5.3	Normal : <5.97 % Good Control : 5.97 – 6.81% Fair Control : 6.81 – 7.65% Poor Control : >7.65%

THYROID PROFILE (T3, T4, TSH)

TEST	LAB TEST VALUES	NORMAL RANGE
THYROID FUNCTION TEST		
T3	0.92	0.60 – 1.81 ng/ml
T4	8.10	4.50 – 10.90 ug/dl
TSH	2.16	0.39 – 6.10 uIU/mL

PAGE 2

Lab Technician

M.D., Pathology

Timing : 8.00 a.m. to 9.00 p.m. (Sunday 8.00 a.m. to 3.00 p.m.)

This Report is not valid for medico legal purpose


Note: These tests have technical limitations. Clinico-pathological interpretation is necessary. In case of any disparity test may be repeated immediately.

Address : 36/44 FK Kabir Nagar, Durgakund, Varanasi – 221005

Email: dramishra@gmail.com, drpallaviojha@gmail.com Website: panaceahospital.org

Facilities:
 All clinical Biomedical & Hematology Investigations
 including Bone Marrow Examination
 VPT, Podiascan & Complete Foot Care (First Time in Purvanchal)
 All Hormonal Investigation by Chemiluminescent Method
 Visceral Fat by (AB-140) Ambulatory BP Monitoring
 CGMS & Insulin Pump Available
 PFT, 2D-ECHO (Color Doppler), Holter, TMT, Cardiac-3 available
 VIA, VILI, Colposcopy available
 Special Endocrinological Investigation Protocols.

ISO 9001:2008 Certified
 Mobile: 9389994334, 9554572190, 9453837595



Panacea Pathology
Clinical Reference Lab
 Persistence, Preparedness and Precision
 EQAS (CMC Vellore Attached) & IQAS System
 पूर्वांचल की सर्वोत्तम गुणवत्ता वाली पैथोलॉजी

PATIENT NAME : ASHA LATA TRIPATHI	AGE/GENDER : 41 YRS/FEMALE
REFD BY DR. : ARCO FEMI HEALTHCARE LTD.	RECEIVED DATE : 10-12-2022 (09:45 AM)
SAMPLE : BLOOD & URINE	REPORT DATE : 10-12-2022 (18:15 PM)

PATHOLOGY REPORT

LIVER PROFILE TEST, SERUM

TEST	LAB TEST VALUES	NORMAL RANGE
BIO CHEMISTRY		
TOTAL BILIRUBIN	0.68	0.0 – 1.1 mg/dl
DIRECT BILIRUBIN	0.22	0.0 – 0.2 mg/dl
INDIRECT BILIRUBIN	0.46	< 0.90 mg/dl
SGOT (AST)	25.0	0 – 52 mg/dl
SGPT (ALT)	27.0	0 – 39 mg/dl
GGT (GYT)	21.0	< 55 U/L
AG RATIO	1.96	-

URINE ROUTINE EXAMINATION

TEST	LAB TEST VALUES	NORMAL RANGE
PHYSICAL EXAMINATION		
QUANTITY	29	ML
COLOUR	STRAW	PALE YELLOW
APPEARANCE	CLEAR	CLEAR
SPECIFIC GRAVITY	1.005	1.01 – 1.03
PH	5.0	4.7 – 7.5
CHEMICAL EXAMINATION		
GLUCOSE	Not Detected	Not Detected
PROTEIN	NIL	Not Detected
MICROSCOPIC EXAMINATION		
PUS CELLS	1-2	0-5
RBC	Not Detected	Not Detected
EPITHELIAL CELLS	1-2	0-5
CASTS	Not Detected	Not Detected
CRYSTALS	Not Detected	Not Detected
BACTERIA	Not Detected	Not Detected

FASTING/RANDOM BLOOD SUGER

TEST	LAB TEST VALUES	NORMAL RANGE
FBS/RBS		
FASTING BLOOD SUGER	82.5	110-125 mg/dl
RANDOM BLOOD SUGER	104.0	125-140 mg/dl

----- End of Report -----

Lab Technician

M.D., Pathology

Timing : 8.00 a.m. to 9.00 p.m. (Sunday 8.00 a.m. to 3.00 p.m.)

This Report is not valid for medico legal purpose

Note: These tests have technical limitations. Clinico-pathological interpretation is necessary. In case of any disparity test may be repeated immediately.

Address : 36/44 FK Kabir Nagar, Durgakund, Varanasi – 221005

Email: dramishra@gmail.com, drpallaviojha@gmail.com Website: panaceahospital.org



Shiv

PANACEA HOSPITAL

B 36/44 F.K KABIR NAGAR, DURGAKUND
TOLLFREE NO-18001233070.
Whatsapp No - 8795832852.
www.piire.org



OP Slip

Print Date : 10-Dec-2022 08:45AM



UHID No	:: UD-22230002871	OP No	:: OP-22230010792	OP Date	:: 10 Dec 2022 8:44AM
Patient Name	:: Mrs ASHA TRIPATHI	Age/Sex	:: 41 Y/Female	Mobile No	:: 9978286161
Husband	:: SANJAY DUBEY	Department	:: DIABETES, ENDOCRINOLOGY & METABOLIC PHYSICIAN		
Pay Type	:: Cash	Consultant	:: Dr ASHUTOSH MISHRA (MD(MEDICINE), IMS, BHU)		
Token No	:: NOR. - 5	Paid/Bal	:: 0.00 / 500.00		
Patient Type	:: Normal				
Address	:: D -503 , MAHABEER HEIGHTS , MANDUADIH, varanasi				

BP :- 130/80
height :- 153
Weight (kg) :- 64
BMI :- 27.3

NC - 34

WC - 92

SPO₂ - 98

PR - 93

Randoms - 116

Rx

duration of Hypothyroidism
x 4 years

Hypothyroidism
Obesity

clo

USMC - 5.5

• Knee Joint Pain

• all over H/O (-nt)

• Seasonal variation (-nt)

Medicine

Tab - Thyronorm 150 OD (8hr) ✓
(2hr)

Rx. Diet 1000kcal/d (SSP)

✓ Tab. Thyrox (150) OD

✓ Tab. Glumet-M2 OD (2hr) ✓

• Tab. Atrorip (4 OD)

• Tab. Montelukast 10 mg x 1 month

• A 2 month

Printed By : Mr NITIN YADAV

Created By : Mr NITIN YADAV

[Signature]

[Handwritten notes]

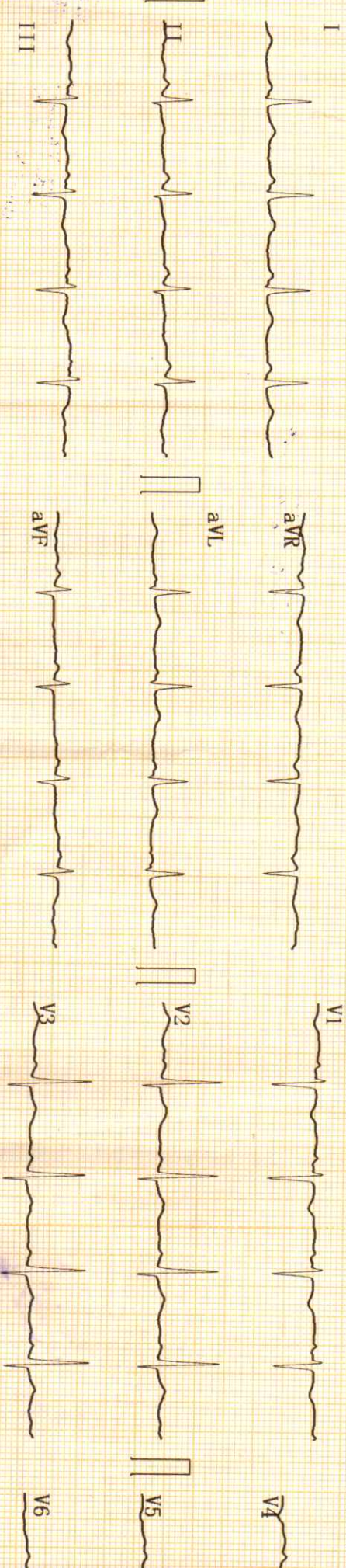
BpL

AUTO 10mm/mV

10mm/mV

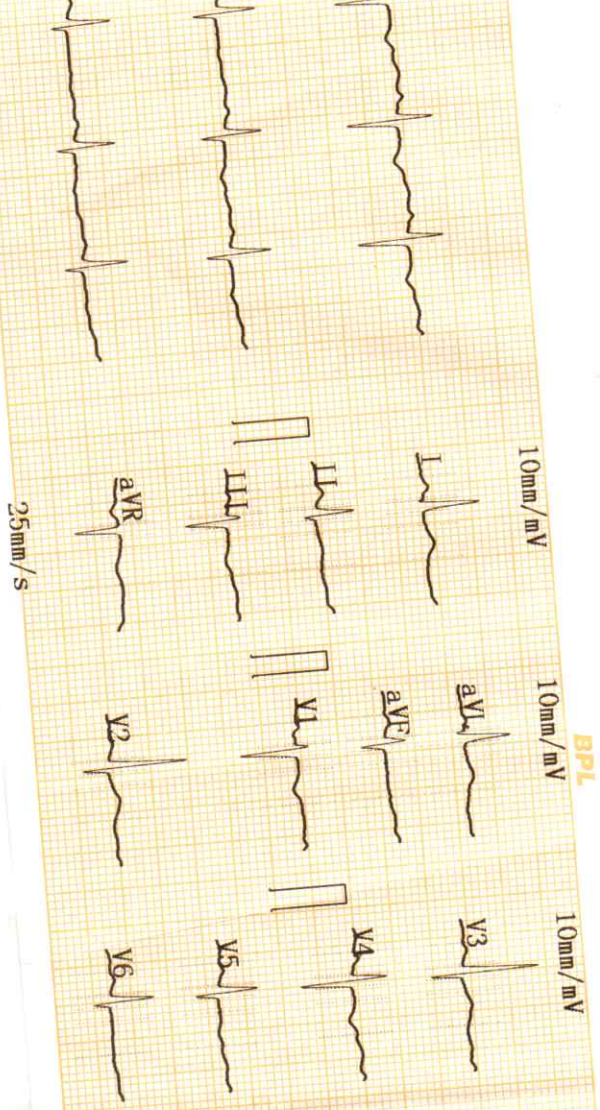
10mm/mV

10mm/mV



25mm/s AC50Hz+EMG35Hz

CARDIART



2022-12-10 11:01

ID : _____
 Name : Ashay Tripathi
 Sex : _____
 Height : _____
 SYS : _____
 DIA : _____
 HR : 93 bpm
 PR Interval : 130 ms
 P Duration : 115 ms
 QRS Duration : 61 ms
 T Duration : 181 ms
 QT/QTc : 319/396 ms
 P/QRS/T Axis : 55.9/-3.1/-2.3 deg
 R (V5) / S (V1) : 0.50/0.74 mV
 R (V5) + S (V1) : 1.24 mV

Age : 41
 Weight : _____ kg

<< Conclusions >>
 Normal Sinus Rhythm;
 Midingling left axis deviation;
 I I V2 V3 V4 V5 V6 Abnormal T wave;
 Report need physician confirm

Physician : DR. PALLAVI MISHRA
 MBBS,MD (GENERAL MEDICINE)
 MCI Reg.No. 52033



PANACEA HOSPITAL

A shelter for many hearts A Home for many lives

(An ISO 9001:2008 Certified Organisation)

Lab Attached with CMC Vellore Under EQAS Scheme

Name	MRS.ASHA TRIPATHI	Sex /Age	41/F	Date	10/12/2022
Ref. by	Dr.Pallavi Mishra(MD)	BSA - m ²		Echo window	fair

Echo - Cardiography


MITRAL VALVE Doppler	AML - normal morphology MV Flow - E - 0.9 A-0.6 E/A=1.51	PML - normal morphology MVA - 3.0 cm ² Mitral Regurgitation - No
TRICUSPID VALVE Doppler	Normal TV Flow -No	Tricuspid Regurgitation -No
PULMONARY VALVE Doppler	Normal PV Flow -No	Pulmonary Regurgitation - No
AORTIC VALVE Doppler	Trileaflet-No AV Flow - no	Aortic Regurgitation - no
MEASUREMENT	Aorta - 21.1 (20-38) mm IVS ed - 12.0 (6 -12) mm LVID ed - 31.4 (35 - 55) mm LVPW ed - 15.4 (6 -12) mm OA - 7 (> 5) mm	LA - 30.3 (24-32) mm IVS es -10.3 (6 - 12) mm LVID es - 22.3 (24 - 40) mm LVPW es - 14.8 (6 -12) mm EPSS - 5 (< 9) mm

CONCLUSION

All cardiac chamber dimensions are WNL
 No valvular abnormalities
 Good LV systolic function present Modified Simpson's method (4C, 2C) (LVEF-57%)
 No diastolic dysfunction present (E/A = 1.51) by tissue Doppler (E/e'=8.0)
 No RWMA
 No pericardial effusion
 Intact IAS / IV
 No PAH
 No intra cardiac mass /thrombus /vegetation

IMPRESSION **Normal Echocardiogram**

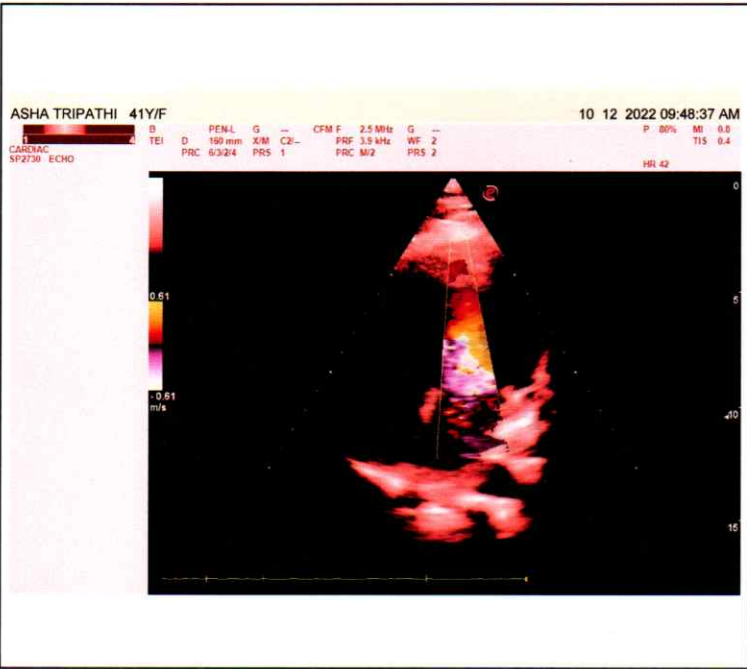
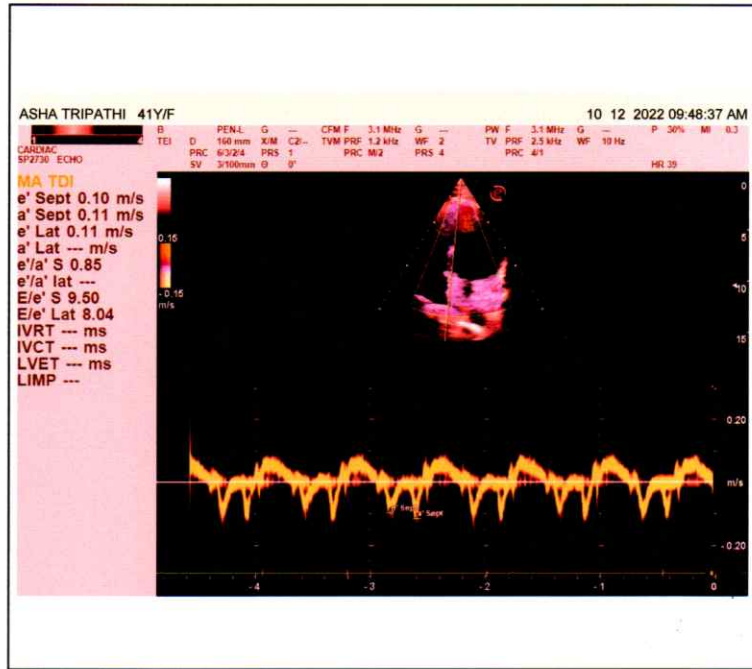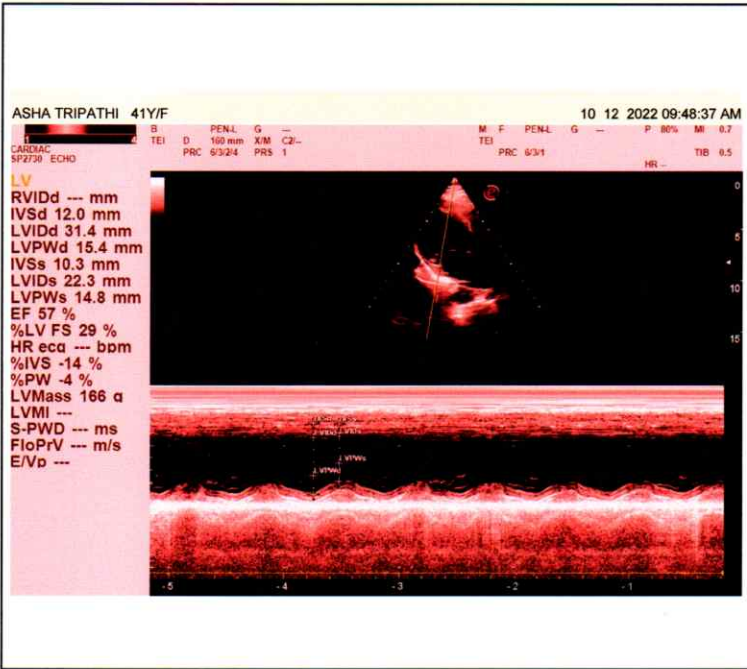
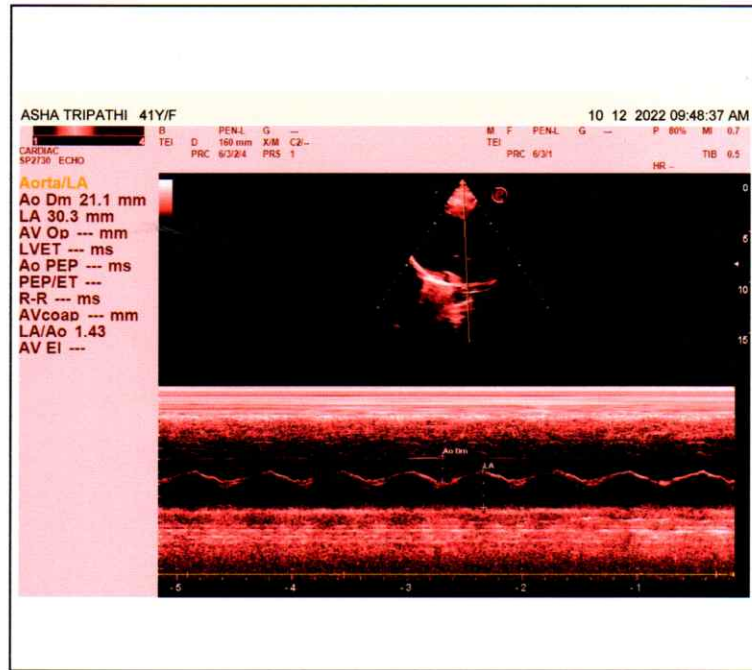
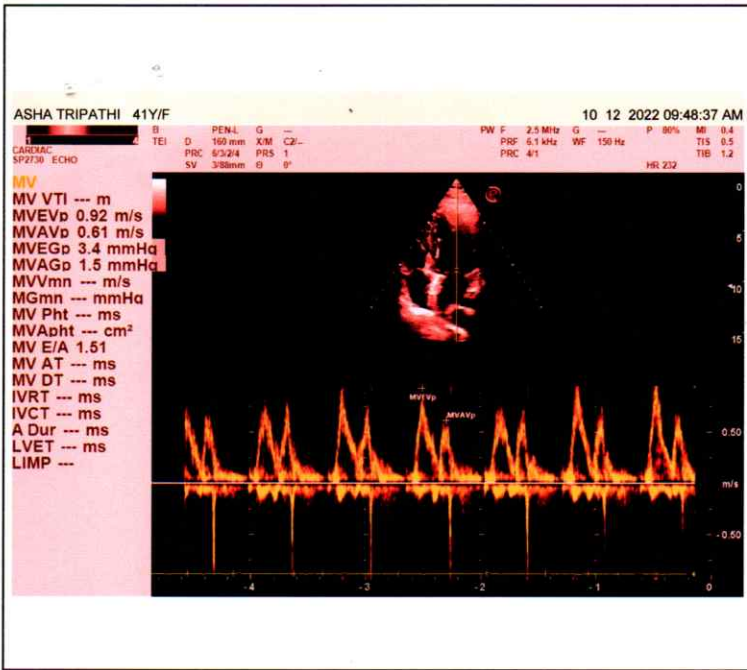

 Niraj Mishra
 Physician Assistant
 (PIIRE)


DR. PALLAVI MISHRA
 (BBS,MD (GENERAL MEDICINE))
 MCI Reg.No. 52033
 Dr. Pallavi Mishra
 MBBS, MD (MED) Lucknow
 Echocardiography Specialist, MIAE
 Non-invasive cardiologist
 Women Cardiologist
 Diabetocardiologist

Address : Kabir Nagar (Near Sanjay Shiksha Niketan), Durgakund, Varanasi

Mobile : 9554572190 / 9453837595 / Recpn. 9389994334

E-mail : dramishra@gmail.com, drpallaviojha@gmail.com, Website: www.piire.org





PANACEA HOSPITAL

A shelter for many hearts A Home for many lives

(An ISO 9001:2008 Certified Organisation)

Lab Attached with CMC Vellore Under EQAS Scheme

AME: MRS. ASHA TRIPATHI

AGE/SEX: 41 YRS / FEMALE

EF BY: DR. ASHUTOSH MISHRA (MD)

DATE: 10 /12/2022

ULTRA SOUND FOR ABDOMAN REPORT

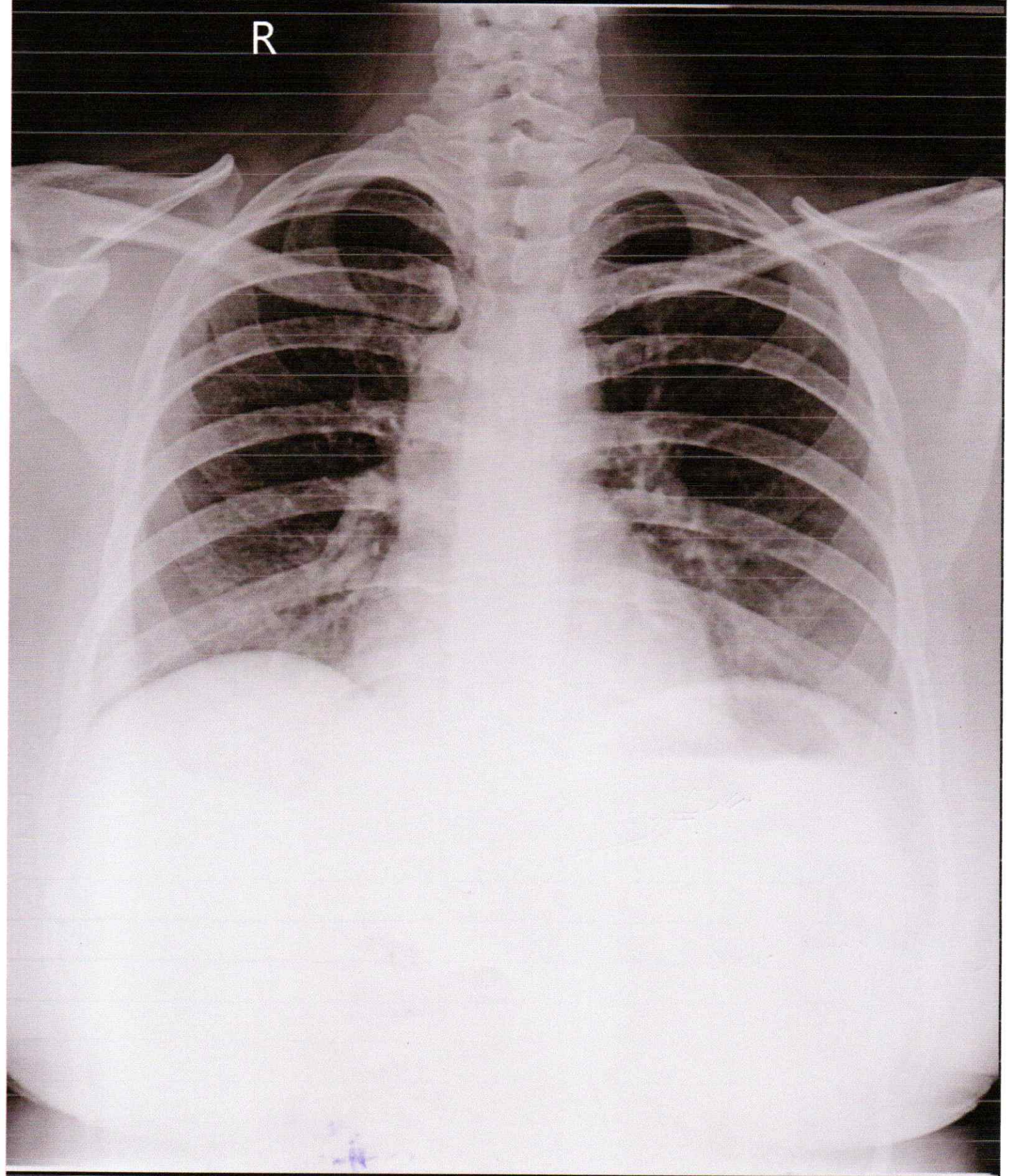
- Liver:** Normal in shape and size(11.1cm) and shows smooth and regular margin.
No diffuse/focal lesion seen.
- Gall bladder** Partially distended with normal wall thickness and echo-free lumen.
- CBD** Visualized part normal in course & caliber.
- Pancreas:** Normal in size, shape & echogenicity.
Margins are smooth & regular.
No diffuse/ focal lesion seen. Pancreatic tail obscured.
- Spleen:** Normal in size(11.1 cm) shape & echogenicity.
Margins are smooth & regular. No diffuse / focal lesion seen.
Splenic vessels at hilum is normal.
- Kidney:** Right kidney: 9.7 X 4.7cm
Left kidney: 9.8 X 5.0 cm
Normal cortical echogenicity with well maintained Cortical-medullary differentiation.
Pelvicalyceal system normal.
No calculus/mass lesion seen.
No hydronephrosis/ hydroureter seen.

Address : Kabir Nagar (Near Sanjay Shiksha Niketan), Durgakund, Varanasi .

Mobile : 9554572190 / 9453837595 / Recpn. 9389994334

E-mail : dramishra@gmail.com, drpallaviojha@gmail.com, **Website:** www.piire.org

R



ASHA TRIPATHI 41Y/F 2871 O CHEST P.A. 10-Dec-22 10:37 AM

PANACEA HOSPITAL, KABIR NAGAR, DURGAKUND, VARANASI



PANACEA HOSPITAL

A shelter for many hearts *A Home for many lives*

(An ISO 9001:2008 Certified Organisation)

Lab Attached with CMC Vellore Under EQAS Scheme

NAME: MRS.ASHA TRIPATHI

AGE/SEX: 41 YRS / FEMALE

REF BY: DR.ASHUTOSH MISHRA(MD)

DATE: 10/12/2022

X-RAY CHEST PA

BOTH LUNG FIELDS AND PLEURAE:

Both lungs show normal bronchovascular pattern.

Right & left hila are normal

No focal mass or calcification is seen

There is no evidence of any fluid in the both the pleural cavities.

Both domes of diaphragms are normal in position.

MEDIASTINUM:

Trachea is central in position.

Cardiac silhouette is of normal size and configuration.

No evidence of pericardial effusion.

No significant lymphadenopathy is seen.

Visualized skeleton is normal.

NO SIGNIFICANT RADIOGRAPHIC ABNORMALITY

DR. ALPANA PATHAK

MD, RADIOLOGY

REG. NO. 46455

REPORTED BY

DR. ALPANA PATHAK

**MBBS (HONS, GOLD MEDALIST) PMCH, PATNA
MD RADIODIAGNOSIS (GOLD MEDALIST) IMS BHU
EX-SR, IMS BHU, VARANASI**

Address : Kabir Nagar (Near Sanjay Shiksha Niketan), Durgakund, Varanasi

Mobile : 9554572190 / 9453837595 / Recpn. 9389994334

E-mail : dramishra@gmail.com, drpallaviojha@gmail.com, Website: www.piire.org