



# YASHFEEN CARDIAC HOSPITAL™

At. & Po. Viraval, Navsari. 396 445. Phone (H) (02637) 235725

Website : www.yashfeenhospital.in E-mail : info@yashfeenhospital.in

(For Laboratory Reports Only)



Patient Name : BIJALKUMARI ASHOKBHAI PATEL  
Ref By Dr. : -  
Sample Time : 30/03/2023 09:16 No : 16

Age : 34 Years Sex : F  
Area : Navsari Date : 30/03/2023  
Time : 12:03PM

## HAEMOGRAM

Test	Findings	UOM	Normal Range
------	----------	-----	--------------

HAEMOGLOBIN	12.3	gm/dl	M-13.5-17.0 F-11.5-15.5
-------------	------	-------	----------------------------

<b>HAEMOGRAM</b> RED BLOOD CELL	<b>6.09</b>	10 <sup>6</sup> /μL	3.76 - 5.70
------------------------------------	-------------	---------------------	-------------

TOTAL LEUCOCYTE COUNT	9500	cells/cumm	4,000-11,000
-----------------------	------	------------	--------------

### Differential Count

Neutrophil	55	%	40-75
Lymphocytes	36	%	20-40
Eosinophil	5	%	1-6
Monocytes	4	%	2-10
Basophils	0	%	0-0

PLATELET COUNT	354000	lacs/cumm	1.5-5.5 Lacs
----------------	--------	-----------	--------------

### RBC INDICES

P.C.V.	37.8	%	M-40-56% F-37-47%
M.C.V.	<b>62.1</b>	cu/microns	76-94
M.C.H.	<b>20.2</b>	pg	27-30
M.C.H.C.	32.5	-	30-35

BLOOD GROUP	" O "	-	-
RH FACTOR	POSITIVE	-	-

E.S.R.(1 hour)	12	mm/hr.	M-5-10, F-5-20
----------------	----	--------	----------------



*P. Chaudhari*  
Dr. PIYUSH B. CHAUDHARI

M. D. Medicine  
Reg. No. G-21518

### Remarks

Designed By : Sarita Infotech Pvt. Ltd., Navsari

Yashfeen Cardiac Hospital

Signature

Thanks for Reference

Technician



# YASHFEEN CARDIAC HOSPITAL™

At. & Po. Viraval, Navsari. 396 445. Phone (H) (02637) 235725

Website : www.yashfeenhospital.in E-mail : info@yashfeenhospital.in

(For Laboratory Reports Only)



Patient Name : BIJALKUMARI ASHOKBHAI PATEL  
Ref By Dr. : -  
Sample Time : 30/03/2023 09:17 No : 16

Age : 34 Years Sex : F  
Area : Navsari Date : 30/03/2023  
Time : 12:03PM

## RENAL FUNCTION TEST REPORT

Test	Findings	UOM	Normal Range
S.CREATININE	<b>0.6</b>	mg/dL	M .0.9-1.4 , F. 0.8-1.2
S.URIC ACID	5.4	mg/dL	Male:3.5-7.2, Female:2.6-6.0
BLOOD UREA NITROGEN	4.7	mg/dL	4.7-23.0



*P. Chaudhari*  
Dr. PIYUSH B. CHAUDHARI  
M.D. Medicine  
Reg. No. G-21518

### Remarks

Designed By : Sarita Infotech Pvt. Ltd., Navsari

Yashfeen Cardiac Hospital

*Dr. Chaudhari*  
signature

*Thanks for Reference*

Technician





# YASHFEEN CARDIAC HOSPITAL™

At. & Po. Viraval, Navsari. 396 445. Phone (H) (02637) 235725

Website : www.yashfeenhospital.in E-mail : info@yashfeenhospital.in

(For Laboratory Reports Only)



Patient Name : BIJALKUMARI ASHOKBHAI PATEL  
Ref By Dr. : -  
Sample Time : 30/03/2023 09:17 No : 16

Age : 34 Years Sex : F  
Area : Navsari Date : 30/03/2023  
Time : 12:04PM

## LIPID PROFILE TEST REPORT

Test	Findings	UOM	Normal Range
S.CHOLESTEROL	138.1	mg/dL	<200:Desirable, 200-239:Borderline High, >=240:High
HDL CHOLESTEROL	<b>34.3</b>	mg/dL	<40:Low(High Risk), >=60:High(Low Risk)
LDL CHOLESTEROL	96.6	mg/dL	<100: Optimal, 100-129: Nearoptimal/ Aboveoptimal, 130-159:BorderlineHigh,16 0-189:High,>=190:Very
VLDL CHOLESTEROL	21.3	mg/dL	UPTO 40
S.TRIGLYCERIDES	106.6	mg/dL	<150:Normal, 150-199:Borderline High,200-499:High, >=500:Very Hi
CHOL/ HDL RATIO	4.0	mg/dL	LESS THAN 5
LDL/ HDL RATIO	2.8	mg/dL	LESS THAN 5



*P. Chaudhari*  
Dr. PIYUSH B. CHAUDHARI  
M.D. Medicine  
Reg. No. G-21518

### Remarks

Designed By : Sarita Infotech Pvt. Ltd., Navsari

Yashfeen Cardiac Hospital

*Signature*  
signature

Thanks for Reference

Technician



# YASHFEEN CARDIAC HOSPITAL™

At. & Po. Viraval, Navsari. 396 445. Phone (H) (02637) 235725

Website : [www.yashfeenhospital.in](http://www.yashfeenhospital.in) E-mail : [info@yashfeenhospital.in](mailto:info@yashfeenhospital.in)  
(For Laboratory Reports Only)



Patient Name : BIJALKUMARI ASHOKBHAI PATEL Age : 34 Years Sex : F  
Ref By Dr. : - Area : Navsari Date : 30/03/2023  
Sample Time : 30/03/2023 09:17 No : 16 Time : 12:04PM

## LIVER FUNCTION TEST REPORT

Test	Findings	UOM	Normal Range
TOTAL BILIRUBIN	0.2	mg/dL	0-1.0
DIRECT BILIRUBIN	0.1	mg/dL	0-0.8
INDIRECT BILIRUBIN	0.1	mg/dL	0-0.2
SGPT	19.1	U/L	Below 40.0
S.ALKALINE PHOSPHATASE	89.9	U/L	CH . 170.0-515.0 A. 37.0-147.0
TOTAL PROTEIN	6.8	g/dl	6.0-8.0
ALBUMIN	4.5	g/dl	3.0-5.0
GLOBULIN	<b>2.3</b>	g/dl	3.0-3.5
A/G	1.9	g/dl	
SGOT	17.2	U/L	Below 40.0



*P. chaudhari*  
Dr. PIYUSH B. CHAUDHARI  
M.D. Medicine  
Reg. No. G-21518

### Remarks

Designed By : Sarita Infotech Pvt. Ltd., Navsari

Yashfeen Cardiac Hospital

*Signature*  
Signature

*Thanks for Reference*

Technician





# YASHFEEN CARDIAC HOSPITAL™

At. & Po. Viraval, Navsari. 396 445. Phone (H) (02637) 235725

Website : www.yashfeenhospital.in E-mail : info@yashfeenhospital.in

(For Laboratory Reports Only)



Patient Name : BIJALKUMARI ASHOKBHAI PATEL  
Ref By Dr. : -  
Sample Time : 30/03/2023 09:17 No : 16

Age : 34 Years Sex : F  
Area : Navsari Date : 30/03/2023  
Time : 12:04PM

## THYROID FUNCTION TEST REPORT

Test	Findings	UOM	Normal Range
T3 (TRIODOTHYRONINE)	1.44	ng/ml	NEWBORNS:0.73-2.88 6DAYS-3MONTHS:0.80-2.75 4-12MONTHS:0.86-2.65 1-6YEARS:0.92-2.48 7-11YEARS:0.93-2.31 12-20YEARS:0.91-2.18 ADULT:0.80-2.00
T4(THYROXINE)	8.38	µg/dl	NEWBORNS:5.04-18.5, 6DAYS-3MONTHS:5.41-17.0, 4-12 MONTHS:5.67-16.0, 1-6YEARS:5.95-14.7, 7-11 YEARS:5.99-13.8, 12-20 YEARS:5.91-13.2, ADULTS:5.10-14.1
TSH	2.33	µIU/ml	NEWBORNS:0.70-15.2, 6DAYS-3MONTHS:0.72-11.0, 4-12MONTHS:0.73-8.35, 1-6YEARS:0.70-5.97, 7-11YEARS:0.60-4.84, 12-20YEARS:0.51-4.30, ADULTS:0.27-4.20

**TECHNIQUE**  
ELECTROCHEMILUMINESCEN  
CE



*P. Chaudhari*  
**Dr. PIYUSH B. CHAUDHARI**  
M. D. Medicine  
Reg. No. G-21518

### Remarks

Designed By : Sarita Infotech Pvt. Ltd., Navsari

Yashfeen Cardiac Hospital

*Dr. Harbejee*  
**Signature**

*Thanks for Reference*

**Technician**



# YASHFEEN CARDIAC HOSPITAL™

At. & Po. Viraval, Navsari. 396 445. Phone (H) (02637) 235725

Website : [www.yashfeenhospital.in](http://www.yashfeenhospital.in) E-mail : [info@yashfeenhospital.in](mailto:info@yashfeenhospital.in)  
(For Laboratory Reports Only)



Patient Name : BIJALKUMARI ASHOKBHAI PATEL Age : 34 Years Sex : F  
Ref By Dr. : - Area : Navsari Date : 30/03/2023  
Sample Time : 30/03/2023 09:17 No : 16 Time : 12:04PM

## GGT TEST REPORT

Test	Findings	UOM	Normal Range
SERUM GGT	40	U/L	10-71 U/L



*P. Chandhari*  
Dr. PIYUSH B. CHAUDHARI  
M.D. Medicine  
Reg. No. G-21518

### Remarks

Designed By : Sarita Infotech Pvt. Ltd., Navsari

Yashfeen Cardiac Hospital

*Dr. Harbejee*  
Signature

*Thanks for Reference*

Technician





# YASHFEEN CARDIAC HOSPITAL™

At. & Po. Viraval, Navsari. 396 445. Phone (H) (02637) 235725

Website : www.yashfeenhospital.in E-mail : info@yashfeenhospital.in  
(For Laboratory Reports Only)



Patient Name : BIJALKUMARI ASHOKBHAI PATEL Age : 34 Years Sex : F  
Ref By Dr. : - Area : Navsari Date : 30/03/2023  
Sample Time : 30/03/2023 09:18 No : 16 Time : 12:04PM

## ROUTINE URINE ANALYSIS

Test	Findings	UOM	Normal Range
<b>PHYSICAL EXAMINATION</b>			
Quantity	-	-	
Colour	YELLOW	-	
Appearance	CLEAR	-	
Reaction	ACIDIC	-	
Sp. Gravity	1.005	-	
<b>CHEMICAL EXAMINATION</b>			
U.Albumin	NIL	-	
Sugar	NIL	-	
Acetone	NIL	-	
Bile Salt	NIL	-	
Bile Pigment	NIL	-	
Occult Blood	NIL	-	
<b>MICROSCOPIC EXAMINATION</b>			
Pus Cells	<b>2-3</b>	/hpf	
Epithelial cells	<b>2-3</b>	/hpf	
Red cells	ABSENT	/hpf	
Casts	-	/hpf	
Crystals	<b>AMORPHOUS SEEN</b>	/hpf	
Others	-	/hpf	



*P. Chaudhari*  
Dr. PIYUSH B. CHAUDHARI  
M.D. Medicine  
Reg. No. G-21518

### Remarks

Designed By : Sarita Infotech Pvt. Ltd., Navsari

Yashfeen Cardiac Hospital

*H. Patel*  
signature

Technician

Thanks for Reference



# YASHFEEN CARDIAC HOSPITAL™

At. & Po. Viraval, Navsari. 396 445. Phone (H) (02637) 235725

Website : www.yashfeenhospital.in E-mail : info@yashfeenhospital.in

(For Laboratory Reports Only)



Patient Name : BIJALKUMARI ASHOKBHAI PATEL Age : 34 Years Sex : F  
Ref By Dr. : - Area : Navsari Date : 30/03/2023  
Sample Time : 30/03/2023 09:36 No : 16 Time : 12:04PM

## HAEMOGLOBIN A1 C ESTIMATION

Test	Findings	UOM	Normal Range
Hb A1C	<b>7.1</b>	%	>8 :Action Suggested, 7-8 :Good Control, <7 :Goal, 6-7 :Near Normal Glycemia, <6 :Non-diabetic Level
<b>Technique</b> METHOD - HPLC		-	
Mean Blood Glucose	<b>157.7</b>	mg/dL	



*P. Chaudhari*  
Dr. PIYUSH B. CHAUDHARI  
M.D. Medicine  
Reg. No. G-21518

### Remarks

Designed By : Sarita Infotech Pvt. Ltd., Navsari

Yashfeen Cardiac Hospital

*Dr. Harbajee*  
Signature

*Thanks for Reference*

Technician





# YASHFEEN CARDIAC HOSPITAL™

At. & Po. Viraval, Navsari. 396 445. Phone (H) (02637) 235725

Website : www.yashfeenhospital.in E-mail : info@yashfeenhospital.in

(For Laboratory Reports Only)



Patient Name : BIJALKUMARI ASHOKBHAI PATEL  
Ref By Dr. : -  
Sample Time : 30/03/2023 09:16 No : 16

Age : 34 Years Sex : F  
Area : Navsari Date : 30/03/2023  
Time : 12:51PM

## BLOOD SUGAR TEST REPORT

Test	Findings	UOM	Normal Range
FASTING BLOOD SUGAR	<b>123.9</b>	mg/dL	70-110
FASTING URINE SUGAR	NIL	-	NIL
POSTPANDRIAL BLOOD SUGAR	<b>157.0</b>	mg/dL	70-140
POSTPANDRIAL URINE SUGAR	NIL	-	NIL



*P. Chaudhari*  
Dr. PIYUSH B. CHAUDHARI  
M.D. Medicine  
Reg. No. G-21518

### Remarks

Designed By : Sarita Infotech Pvt. Ltd., Navsari

Yashfeen Cardiac Hospital

*Dr. Chaudhari*  
Signature

*Thanks for Reference*

Technician



# YASHFEEN CARDIAC HOSPITAL™

MANAGED BY :- YASHFEEN FOUNDATION

VIRAVAL, NAVSARI. 396 445. PHONE : (H) (02637) 235725

Website : www.yashfeenhospital.in E-mail : info@yashfeenhospital.in

(Regd. No. E / 1390 / Navsari)

(Stationary For Report Only)

## 2D ECHO CARDIOGRAPHY COLOUR DOPPLER REPORT

Patient Name & No	: BIJALKUMARI ASHOKBHAI PATEL CH22052772	Age/Sex	UHID :	: 3324
Doctor	: Mohil Nagad	34/ F	No :	: 8212
Referred By	:		Date :	: 30/03/2023

### M-Mode findings

LVIDd : 40mm  
 LVIDs : 28mm  
 IVSd : 10mm  
 PWd : 10mm  
 EF : 60%  
 Aorta : 22mm  
 LA : 36mm

### 2D Imaging

Aortic Valve : Trileaflet, Normal  
 Mitral Valve : Thin, Pliable, Normal Mobility, Mild AML Prolapse, Mild MR.  
 Tricuspid Valve : Trivial TR, RVSP: 20+ RAP  
 Pulmonary Valve : Normal

=> : All cardiac chambers are normal sized.  
 => : No regional wall motion abnormality.  
 => : Normal LV systolic function.  
 => : Normal LV diastolic function.  
 => : IAS/IVS intact.  
 => : No obvious clots/ vegetations/ or effusion.  
 => : IVC Normal size.

### Doppler Findings

=> : No MS/Mild MR, No TS/Trivial TR, No AS/AR & No PS/PR  
 Mitral inflow Pattern : E > A  
 Tissue Doppler Findings : E' > A'

Impression : MVP, Normal LVEF:60%, No RWMA, Mild MR.



Report Prepared By

**DR. MOHIL NAGAD**  
 M.D. Medicine, D.M. Cardiology  
 Senior Consultant- Interventional Cardiology  
 Reg. No. G-12553 GDCC  
 YASHFEEN HOSPITAL, NAVSARI





# YASHFEEN CARDIAC HOSPITAL

## EYE DEPARTMENT

Chief Complaint :

Co Headache & Somnolence

Bijalkaman

Medical History : ~~DM / HT / Asthama / Allergy / Heart / Thyroid / .....~~

Ocular History :

Visual Acuity : PC  $\left\{ \begin{matrix} R 6/9 \\ L 6/9 \end{matrix} \right.$

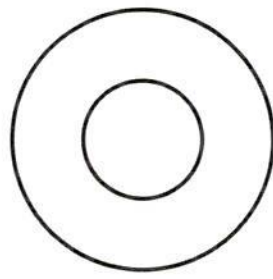
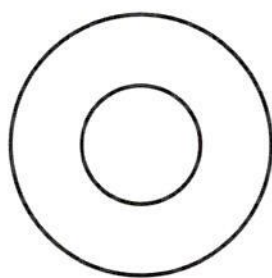
IOP :

30 MAR 2023 AM 11:37  
 SN: 4721938  
 REF. DATA  
 VD: 12.00 CYL: MIX  
 CDS 18  
 - 3.50 - 1.50 175  
 - 3.50 - 1.50 175  
 - 3.50 - 1.50 175  
 - 3.50 - 1.50 175  
 S.E. - 4.25  
 <L> S 0 A  
 - 4.25 - 1.25 15  
 - 4.25 - 1.25 15  
 - 4.25 - 1.25 15  
 - 4.25 - 1.25 15  
 S.E. - 5.00  
 PD: 64.5

	RIGHT EYE (PH.....)				LEFT E	
	Sph.	Cyl.	Axis	V/A	Sph.	
Distance	-3.50	-1.50	170	6/9	-4.00	
Near				pc		pc

Distance/Reading/Bi-Focal/Progressive/Separate Glasses

Qe :



R  
 9. Tearmees Eshy  
 000



# YASHFEEN IMAGING & RADIOLOGY DEPARTMENT

MANAGED BY :- YASHFEEN FOUNDATION

VIRAVAL, NAVSARI. 396 445. PHONE : (H) (02637) 235725

Website : [www.yashfeenhospital.in](http://www.yashfeenhospital.in) E-mail : [info@yashfeenhospital.in](mailto:info@yashfeenhospital.in)

Name	BIJALKUMARI ASHOKBHAJ PATEL	Age	34Y/F
Ref by Dr	SELF	Date	30/03/2023

## USG ABDOMEN & PELVIS (SCREENING)(TVS)

**Liver** appears normal in size & shape with normal echopattern.  
No e/o focal or diffuse lesion. IHBR appear normal.  
PV and CBD appear normal.

**Gall bladder** appears contracted. Adv: fasting scan.

**Pancreas** appears normal in size and echogenicity. No e/o focal or diffuse lesion.

**Spleen** appears normal in size and shows normal echopattern. No e/o focal lesion.

**Both Kidneys** appear normal in size and echopattern. CM Differentiation is preserved.  
No e/o calculus or hydronephrosis on either side.  
Perirenal spaces appear normal on either side.  
Suprarenal regions appear normal on either side. No e/o mass lesion.

**Bladder** is empty (due to non-compliance of patient). Adv: Follow up USG with normally distended bladder.

**Uterus** appears anteverted, normal in size & shows normal echopattern.  
Endometrial cavity is empty. ET- 8 mm. No e/o focal or diffuse mass lesion.

**Both ovaries** appear normal in size & echopattern.  
No e/o adnexal mass on either side.

RIF region appears normal.

No e/o ascites.

### IMPRESSION:

**No significant abnormality detected.**



Dr. DHARMESH DESAI

(M.D. Radiology)

Reg. No. G - 45284

Dr. Dharmesh Desai  
YASHFEEN GROUP OF HOSPITAL

Please contact immediately for any typographical error.

This is only professional opinion, not a final diagnosis. Kindly correlate clinically. Not valid for medicolegal purpose.



BIJALKUMARI ,  
ID:  
DOB:  
34 Years , ,  
Female ,Unknown  
Med.:  
Location:  
Referring Physician:  
Notes:

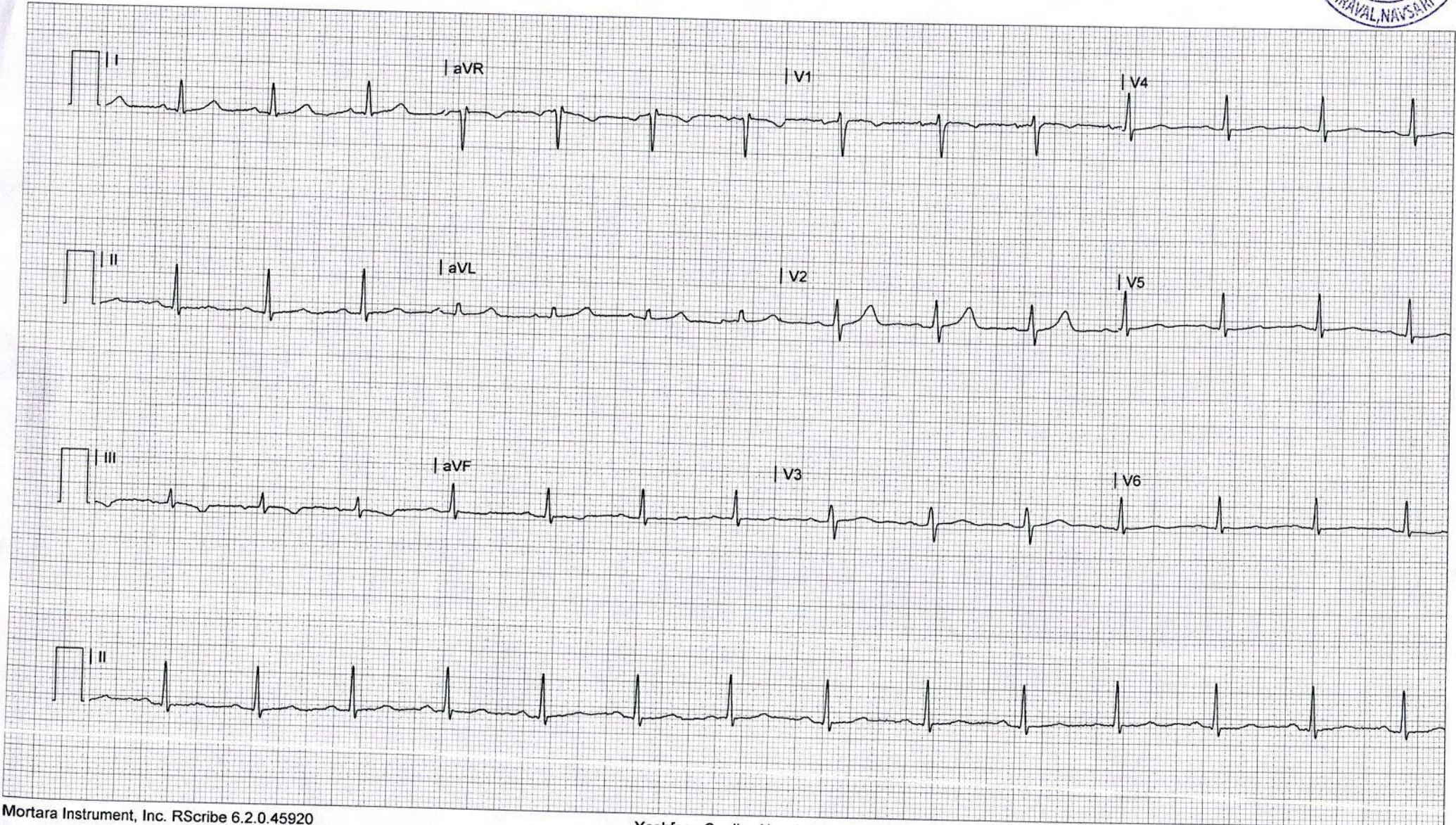
30-03-2023 09:38:26

Vent. Rate: 85 BPM  
PR int: 161 ms  
QRS dur: 75 ms  
QT/QTc: 340/382 ms  
P-R-T axes: 30 43 -10  
Avg. RR: 702 ms  
QTcB: 405 ms  
QTcF: 382 ms

SINUS RHYTHM  
LOW QRS VOLTAGE IN PRECORDIAL LEADS  
NONSPECIFIC T-WAVE ABNORMALITY  
BORDERLINE ECG

UNCONFIRMED REPORT  
Reviewed by:

Signed by:  
Date:





# YASHFEEN IMAGING & RADIOLOGY DEPARTMENT

MANAGED BY :- YASHFEEN FOUNDATION

VIRAVAL, NAVSARI. 396 445. PHONE : (H) (02637) 235725

Website : [www.yashfeenhospital.in](http://www.yashfeenhospital.in) E-mail : [info@yashfeenhospital.in](mailto:info@yashfeenhospital.in)

Patient's Name:	BIJALKUMARI A. PATEL	Age & Sex:	34Yrs/F
Ref. by Dr.	SELF	Date:	29-03-2023

## X RAY CHEST (PA VIEW)

Both lung fields appear normal.

Both hila appear normal.

Both CP angles appear clear.

Cardiac size appears within normal limit.

Both domes of diaphragm appear normal.

Bony thoracic cage appears normal.

### IMPRESSION:

- Normal X-ray chest (PA view).

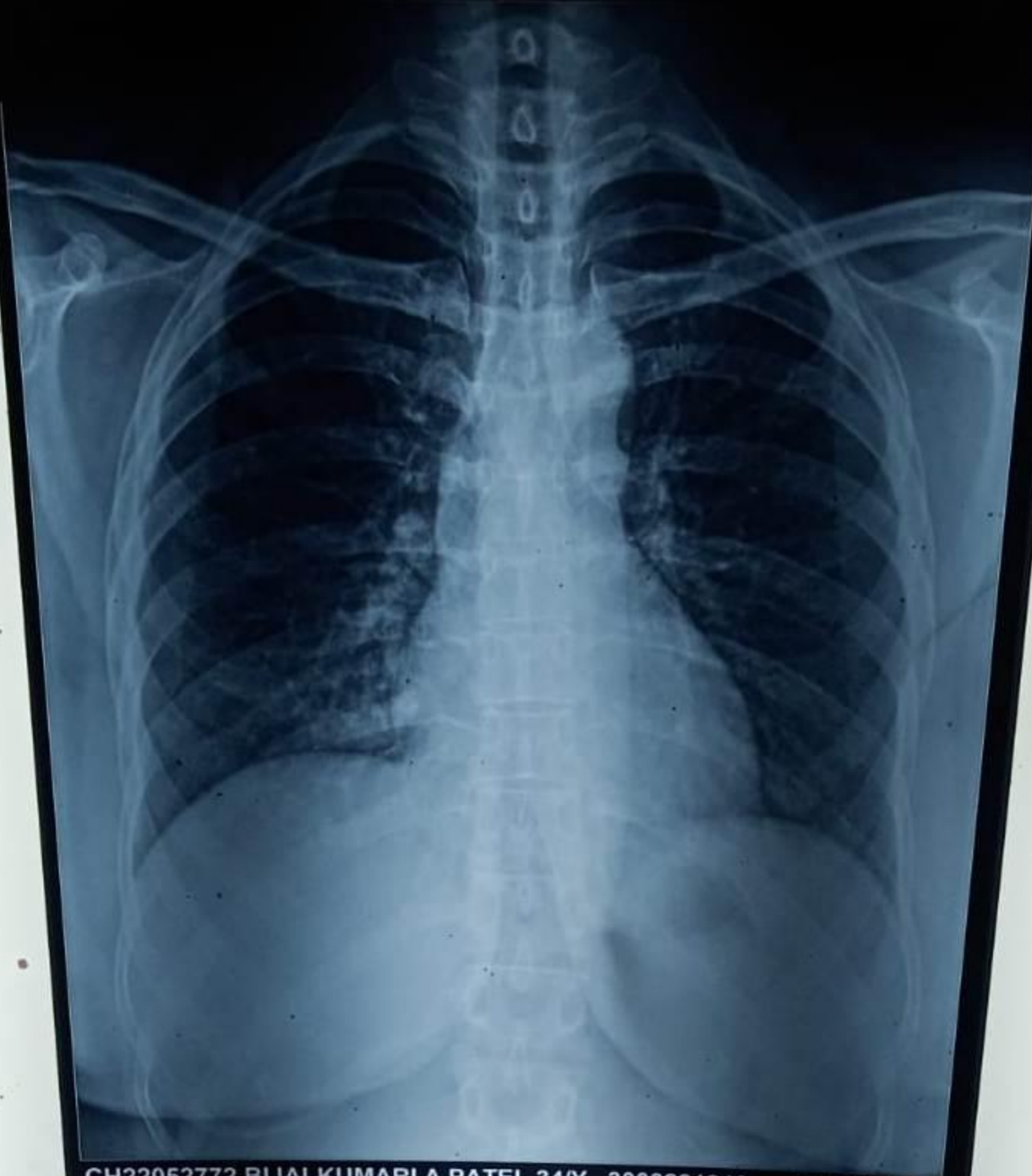

**Dr. Dharmesh Desai**  
Dr. Dharmesh Desai (Radiology)  
Reg. No. G - 45284  
YASHFEEN GROUP OF HOSPITAL

Please contact immediately for any typographical error.

This is only professional opinion, not a final diagnosis. Kindly correlate clinically. Not valid for medicolegal purpose.





CH22052772 BIJALKUMARI A PATEL 34/Y 3003231940 CHEST PA  
YASHFEEN GROUP OF HOSPITALS NAVSARI PH:9924047789